

## Case report

## Juvenile dermatomyositis in a 14-year old Nigerian girl

Rasaki Aliu<sup>\*,1,2</sup>, Lawan Ibrahim Aliyu<sup>2,3</sup>, Patience Ngozi Obiagwu<sup>4,5</sup>, Lukman Olatoke<sup>1,2</sup>, Joseph Kelechi Ebisike<sup>2</sup>

<sup>1</sup>Department of Pediatrics, Gombe State University, Gombe, Nigeria; <sup>2</sup>Federal Teaching Hospital, Gombe, Nigeria; <sup>3</sup>Department of Histopathology, Gombe State University Gombe, Nigeria; <sup>4</sup>Department of Pediatrics, Bayero University, Kano, Nigeria; <sup>5</sup>Aminu Kano Teaching Hospital, Kano, Nigeria

### Abstract

Juvenile Dermatomyositis is a rare idiopathic autoimmune and inflammatory myopathy and vasculopathy whose hallmarks are symmetrical proximal muscle weaknesses and a characteristic rash. Only few cases have been reported in West Africa subregion. We present a 14-year old Nigerian girl with clinical and histopathologic features of definitive juvenile dermatomyositis based on EULAR/ACR classification criteria but probable Juvenile dermatomyositis according to Bohan and Peter criteria. The patient had normal aspartate and alanine aminotransferase levels. Creatine kinase, Lactate dehydrogenase and aldolase which are not available in our center could not be evaluated. There was remarkable clinical improvement 3 weeks after the onset of systemic corticosteroid therapy. Our case highlights that relying on these normal enzyme values, especially where muscle biopsy and EMG are not available as is the case in most centers in developing countries, would have resulted in missed diagnosis using Bohan and Peter criteria.

**Keywords:** *juvenile dermatomyositis; autoimmune vasculopathy; muscle biopsy*

### Introduction

Juvenile dermatomyositis (JDM) is a rare systemic vasculopathy of childhood with an estimated annual incidence of 2-4 cases per million children annually in population-based studies [1, 2]. Although the average age of onset is 7 years, peak incidence ranges between 4-10 years with female sex preponderance as girls are affected 2-5 times more frequently than boys [3].

Although the clinical presentation of JDM is heterogeneous, proximal, usually progressive muscle weakness and classic skin rashes including, Gottron's papules or heliotrope

eyelid rash, are the hallmarks of JDM [4]. Diagnosis of JDM which was mostly based on Bohan and Peter criteria [5] has been recently replaced with clinical diagnostic criteria [6] because of the invasive natures of muscle biopsy and electromyography included in the Bohan and Peter criteria.

We present a case report of a patient who fulfilled the clinical diagnostic criteria [6] but whose case would have been probably missed using the Bohan and Peter diagnostic criteria as the enzymes were normal and EMG could not be done due to non-availability.

### Case report

Our patient was a 14-year old girl who presented to our facility with a 3-year history of itchy rash around the eyes, face and also on her trunk and limbs with associated swelling of the eyelids. There was also a 1-year history of progressive proximal muscle weakness with

Received: February 2020; Accepted after review: March 2020; Published: April 2020.

\*Corresponding author: Rasaki Aliu, Department of Pediatrics, Gombe State University and Federal Teaching Hospital, PMB 0037, postal code (760), Gombe, Gombe State, Nigeria.

Phone: +2348066536823

Email: [aliu.abdurrazaq11@gmail.com](mailto:aliu.abdurrazaq11@gmail.com)

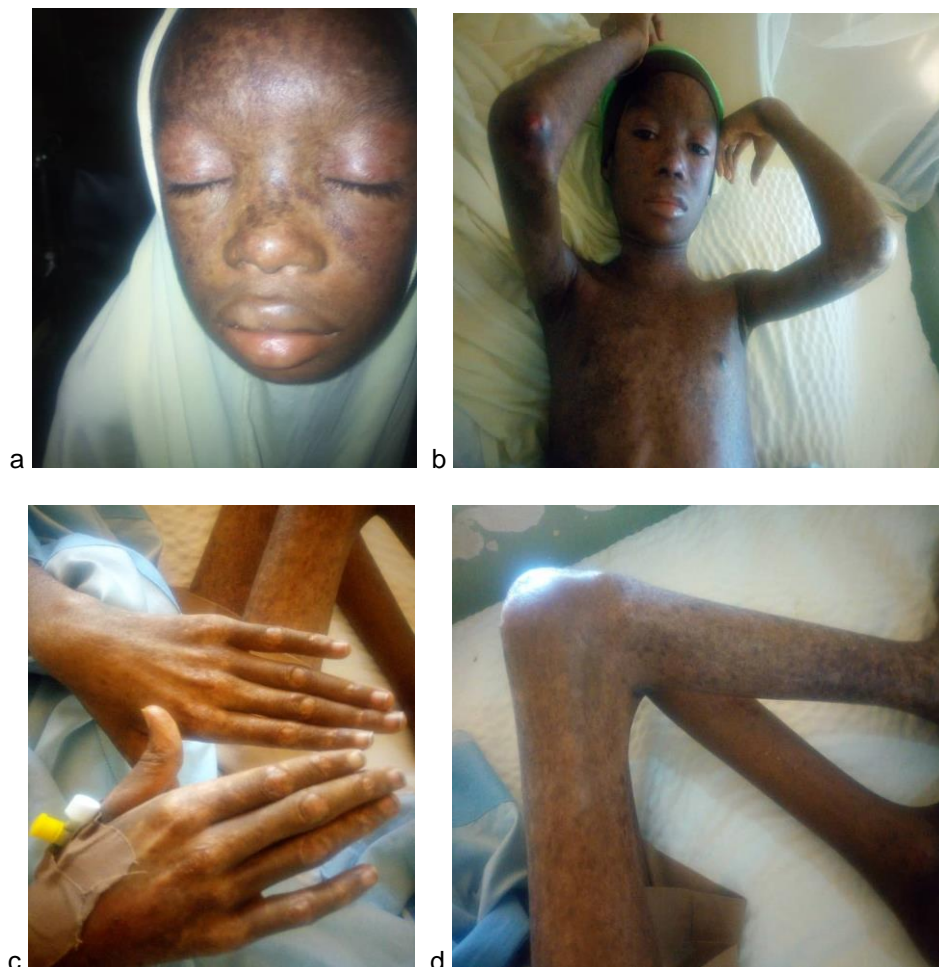

initial falls and subsequent inability to walk and difficulty raising the arms and a 5 months history of generalized body swelling, joint pains with swelling, stiffness. Loss of hair was also noted. There were neither genito-urinary symptoms nor yellow coloration of the eyes. There were no gastro-intestinal or respiratory symptoms.

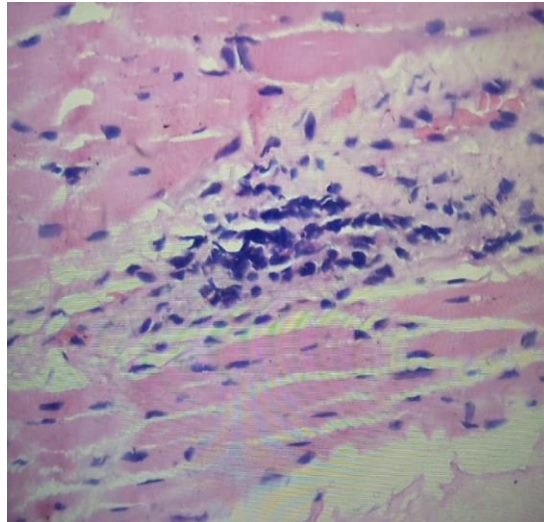
General physical examination revealed a chronically ill-looking child (weight 19 kg <3<sup>rd</sup> centile), pale, with multiple hypo- and hyperpigmented (poikilodermic) macules on the trunk and limbs, with accentuated redness around the neck and heliotrope rash above the upper eyelids, mild eyelid edema (Figure 1a), alopecia, and ulcer on the right elbow joint (Figure 1b).

Further skin inspection showed thick and pale papules over the proximal and distal

interphalangeal joints (Gottron's papules and signs) as shown in Figure 1c. Musculoskeletal examination revealed contracture of the knees and elbows (Figure 1d), the patient was unable to get up from supine position and had difficulty in raising her arms when seated up. The power in the shoulder and hip joints were 3/5 each, at least 4/5 in wrist and ankle joints. Assessing power in the elbow and knee joints was very difficult due to contractures. Deep tendon reflexes were unremarkable and no sensory level was recorded. Muscle bulk was proportionate with poor nutritional status of the patient. The muscle biopsy showed foci of perivascular lymphocytic infiltration and plasma cells with degeneration of muscle fascicles in tandem with juvenile dermatomyositis (Figure 2).



**Fig. 1.** Heliotrope rash: purple-reddish rash on the upper eyelids accompanied by eyelid swelling (a); Ulcer of the right elbow (usually indicates significant vasculopathy in JDM) (b); Gottron's papules and signs: papulosquamous and macular erythematous lesion over the dorsal surface of Knuckles (c); Contracture of joints (rigidity of the joints due to inflammation and hardening of muscles) (d)



**Fig. 2.** Juvenile dermatomyositis: skeletal muscle biopsy with characteristic perivascular mononuclear cell infiltrate (HE, x400)

Erythrocyte sedimentation rate was elevated 108 mm/h (0-20mm). Serum levels of aspartate aminotransferase 44 U/L (10-46), alanine aminotransferase 33 U/L (10-46) were in normal ranges. However, Creatine kinase, Lactate dehydrogenase and aldolase could not be tested as they are not available in our center. Urinalysis, electrolytes, urea and creatinine were within normal limit and retroviral screening was negative.

Electromyography and antinuclear antibody could not be done because of lack of availability in our facility and patient's financial constraints.

High dose pulse methylprednisolone (30 mg/kg) was commenced for 3-alternate-days, followed by daily oral prednisolone (2 mg/kg/day), weekly IV methotrexate (20 mg/m<sup>2</sup>), daily hydroxychloroquine (5 mg/kg/day), calcium supplement, and folic acid. Plastic surgeons declined the release of contracture procedure and advised physiotherapy which was commenced following resolution of muscle pain.

The patient improved remarkably within 3 weeks of treatment as evidenced by resolution of muscle pain, improvement in the stiffness of elbow and knee joints, and gradual disappearance of the scaly body rashes. However, after the clinical improvement, the

patient defaulted from the 6 weeks follow-up visit.

## Discussions

The diagnosis of JDM in children is rarely made in developing countries especially in Black Africans. It is worthy of note that of the 251 reported cases of definite or probable childhood JDM over 10 years by the UK JDM registry, the Black Africans accounted for 7 cases only whereas Caucasians accounted for 207 [7]. This is partly due to diagnostic challenge posed by unavailability of adequate diagnostic tools in the developing countries such as Nigeria and partly due to the application of Bohan and Peter diagnostic criteria [5]. Recently, the Bohan and Peter criteria have been replaced with a revised, validated, non-invasive set of diagnostic criteria for JDM which is based mainly on clinical grounds and thus more practical than Bohan and Peter criteria [6]. The European League Against Acute Rheumatism (EULAR) and American College of Rheumatology (ACR) proposed the internationally adopted diagnostic criteria for JDM (Table 1). The diagnosis of JDM in our patient was made using both the Bohan and EULAR/ACR criteria [5, 6].

Table 1. EULAR/ACR Diagnostic Criteria for Childhood Juvenile Dermatomyositis [6]

Variable	Features	No biopsy	With biopsy
<b>Age of onset</b>	<18 years	1.3	1.5
<b>Symmetric muscle weakness</b>	Proximal upper limb	0.7	0.7
	Proximal lower limb	0.8	0.5
	In the legs proximal muscles are relatively weaker than distal muscles	0.9	1.2
	Neck flexors are relatively weaker than neck extensors	1.9	1.6
<b>Classical skin rash</b>	Heliotrope rash	3.1	3.2
	Gottron papule	2.1	2.7
	Gottron sign	3.3	3.7
<b>Other clinical manifestation</b>	Dysphagia or esophageal dysmotility	0.7	0.6
<b>Elevated serum levels of muscle enzymes</b>	Creatine kinase OR Aspartate amino transferase OR Alanine amino transferase OR Lactate dehydrogenase	1.3	1.4
	Perivascular infiltration of mononuclear cells		1.2
	Rimmed vacuoles		3.1
	Perifascicular atrophy		1.9
<b>Muscle biopsy</b>	Endomysial infiltration of mononuclear cells surrounding, but not invading, myofibers		1.7

Bohan and Peter defined five criteria for the diagnosis of childhood JDM. These include the classic skin rash (heliotrope and Gottron's papules) and four features of muscle inflammation (proximal muscle weakness, elevated muscle enzyme, myopathic changes on electromyography, abnormal muscle biopsy finding) [5]. Diagnosis of definite JDM is made by the presence of classical skin rash plus three of the four muscle features while probable JDM is diagnosed by the presence of two of the four muscle features alongside the classical skin rash [5].

The EULAR/ACR developed and validated revised diagnostic criteria for JDM in 2017 [6]. This replaced the longstanding Bohan and Peter diagnostic criteria proposed in 1975 [5]. The EULAR/ACR include 4 clinical variables related to muscle weakness, three variables related to skin rashes and variables related to laboratory parameters. The muscle biopsy and electromyography that were crucial in Bohan and Peter criteria have been de-emphasized due to their invasive natures, and for the fact that many rheumatologists made definitive diagnosis of JDM without performing muscle

biopsy or electromyography in their common practice [5]. The variables in EULAR/ACR criteria were assigned score such that in a child with muscle weakness and classical skin rash of JDM with no other explanation, a score of greater than or equal to 7.5 is diagnostic of definitive JDM while a score less than 7.5 suggests probable JDM.

Although muscle biopsy was done in our patient, the non-availability of EMG in our center and indeed in many centers in developing countries would have suggested probable JDM or would have been completely missed according to the Bohan and Peter diagnostic criteria. This is despite the presence of gross proximal muscle weaknesses and obvious classical skin manifestation which are the most significant in JDM diagnosis after muscle biopsy [8]. In contrast, our patient had a score of 14.7 using EULAR/ACR criteria and this suggests definitive JDM [6]. The level of aspartate and alanine aminotransferase enzymes in our patient was found to be normal. This rare occurrence has been shown to be associated with a prolonged JDM duration of

more than four months prior to treatment as observed in our patient [9].

## Conclusions

Our case highlights that relying on these normal enzyme values, especially where muscle biopsy is not available as is the case in most centers in developing countries, would have resulted in missed diagnosis using Bohan and Peter criteria. This probably explains the reason JDM report from resource-scarce countries has been low. Thus, knowing that the muscle enzymes could be normal in a prolonged untreated case of JDM and the

application of validated EULAR/ACR JDM diagnostic criteria proposed in 2017 will enhance early and clinically objective diagnosis of childhood JDM, especially in resource-poor countries.

## Consent

Written informed consent was obtained from the patient's caregiver and the patient for publication of this case report and the accompanying images.

## Competing interests

The authors declare that they have no competing interests.

## References

1. Oddis C, Conte C, Steen V, Medsger TA Jr. Incidence of polymyositis-dermatomyositis: a 20-year study of hospital diagnosed cases in Allegheny County, PA 1963-1982. *J Rheumatol* 1990; 17(10):1329-1334.
2. Symmons DP, Sills JA, Davis SM. The incidence of juvenile dermatomyositis: results from a nation-wide study. *Br J Rheumatol* 1995; 34(8):732-736.
3. Mendez EP, Lipton R, Ramsey-Goldman R, et al. US incidence of juvenile dermatomyositis, 1995–1998: results from the National Institute of Arthritis and Musculoskeletal and Skin Diseases Registry. *Arthritis Rheum* 2003; 49(3):300-305.
4. Ramanan AV, Feldman BM. Clinical features and outcomes of juvenile dermatomyositis and other childhood onset myositis syndromes. *Rheum Dis Clin North Am* 2002; 28(4):833-857.
5. Bohan A, Peter JB. Polymyositis and dermatomyositis (second of two parts). *N Engl J Med* 1975; 292(8):403-407.
6. Lundberg IE, Tjärnlund A, Bottai M, et al. 2017 European League Against Rheumatism/ American College of Rheumatology classification criteria for adult and juvenile idiopathic inflammatory myopathies and their major subgroups. *Arthritis Rheumatol* 2017; 69(12):2271-2282.
7. Martin N, Krol P, Smith S, et al. Juvenile Dermatomyositis Research Group. A national registry for juvenile dermatomyositis and other paediatric idiopathic inflammatory myopathies: 10 years experience: the juvenile Dermatomyositis National (UK and Ireland) cohort biomarker study and repository for idiopathic inflammatory myopathies. *Rheumatology (Oxford)* 2011; 50(1):137–145.
8. Brown VE, Pilkington CA, Feldman BM, Davidson JE; Network for Juvenile Dermatomyositis, Paediatric Rheumatology European Society (PReS). An international consensus survey of the diagnostic criteria for juvenile dermatomyositis (JDM). *Rheumatology (Oxford)* 2006; 45(8):990-993.
9. Pachman LM, Abbott K, Sinacore JM, et al. Duration of illness is an important variable for untreated children with juvenile dermatomyositis. *J Pediatr* 2006; 148(2):247-253.