

Cerebral venous thrombosis in women of childbearing age: diagnosis, treatment, and prophylaxis during a future pregnancy

Büşra Durmuş, Laetitia Yperzeele and Susanna M Zuurbier 

Ther Adv Neurol Disord

2020, Vol. 13: 1–8

DOI: 10.1177/
1756286420945169

© The Author(s), 2020.
Article reuse guidelines:
sagepub.com/journals-
permissions

Abstract: Sex-specific risk factors for cerebral venous thrombosis (CVT) in women include oral contraceptives, pregnancy, puerperium, and hormone replacement therapy. The acute treatment of CVT is anticoagulation using therapeutic doses of low molecular weight heparin, which is also the preferred treatment in the post-acute phase in pregnancy and during breastfeeding. In patients with imminent brain herniation decompressive surgery is probably life-saving. A medical history of CVT alone is not a contraindication for future pregnancies. The optimal dosage of low molecular weight heparin as thrombosis prophylaxis during future pregnancies after a history of venous thrombosis including CVT is the topic of an ongoing trial.

Keywords: breastfeeding, cerebral venous thrombosis, diagnosis, pregnancy, puerperium, stroke, treatment, women

Received: 13 February 2020; revised manuscript accepted: 23 June 2020.

Introduction

The overall incidence of cerebral venous thrombosis (CVT) in adults is estimated at one per 100,000 people per year.¹ For women, a gradual increase in the incidence of CVT has been observed over time.² Between the ages of 31 and 50 years, the incidence of CVT in women is around three per 100,000 people per year.¹

General factors increasing the risk for CVT include genetic thrombophilia, systemic diseases, infections and cancer,³ but the most crucial additional risk factors in women are the use of oral contraceptives (80% of the cases), pregnancy and the postpartum period (5–20% of the cases).^{4–6} A case-control study by Zuurbier *et al.* showed obese women who use oral contraceptives to have a 30-times higher risk of CVT as compared with women with normal weight who do not use contraceptives.⁷ Regarding pregnancy-related CVT, the majority of events occur in the third trimester of pregnancy and in the first 6 weeks of the postpartum period (puerperium).⁵ According to a Taiwanese study, 73% of the CVT events occurred in the puerperium.⁸ Maternal hypertension, Caesarean delivery, intercurrent infections,

excessive vomiting during pregnancy and increasing maternal age were identified as independent risk factors for CVT in the puerperium period.⁹

The clinical presentation of CVT may mimic that of (pre)eclampsia and consists of a myriad of symptoms with most often a gradual onset. In the ISCVT study, a prospective International Study on Cerebral Vein and Dural Sinus Thrombosis, headache was the most common clinical feature (89%), followed by seizures (39%), mental status disorder (22%), stupor or coma (14%) and visual loss (13%).¹⁰ During pregnancy, some symptoms may be aspecific too, which can lead to a delay in the diagnosis of CVT as the symptoms may be attributed to the pregnancy itself.¹¹ Examples are headaches immediate postpartum being treated as postdural headache in the case of epidural analgesia or seizures that are treated with magnesium sulphate when eclampsia is suspected.¹²

The clinical outcome in women with sex-specific risk factors such as oral contraceptives, pregnancy, puerperium, and hormone replacement therapy is better compared with men.¹³ Overall, the mortality in CVT patients is decreasing, suggesting

Correspondence to:
Susanna M Zuurbier
Department of Neurology,
Antwerp University Hospital,
Wilrijkstraat 10, 2650
Edegem, Antwerp, Belgium
yvonne.zuurbier@uza.be

Büşra Durmuş
Department of Neurology,
Antwerp University
Hospital, Wilrijkstraat 10,
2650 Edegem, Antwerp,
Belgium

Laetitia Yperzeele
Department of
Neurology, Stroke Unit
& NeuroVascular Centre
Antwerp, Antwerp
University Hospital,
Wilrijkstraat 10, 2650
Edegem, Antwerp;
Belgium

Translational
Neurosciences Research
Group, Faculty of Medicine
and Health Sciences,
University of Antwerp,
Universiteitsplein, Wilrijk,
Antwerp, Belgium

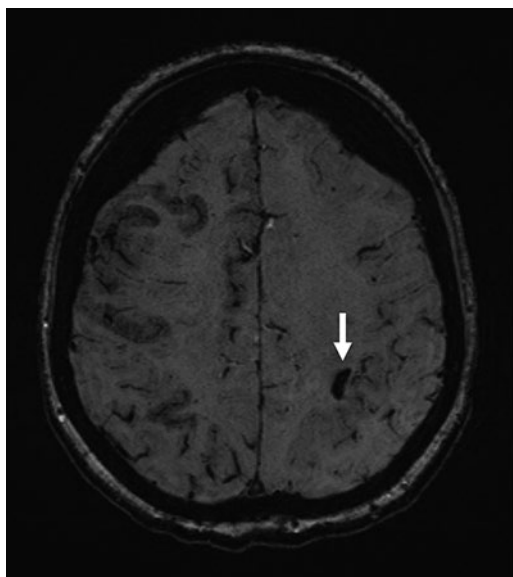


Figure 1. Magnetic resonance imaging scan of the brain (susceptibility weighted imaging) axial at the initial presentation of a woman showing a single juxtacortical haemorrhage located in the parietal lobe of the left hemisphere (arrow). The patient also had sulcal subarachnoid haemorrhage, especially in the right hemisphere.

improvement of diagnostic methods and better management of CVT over time.¹⁴ Both treatment options in the acute phase of pregnant CVT patients and management of the recurrent risk for future pregnancies are challenging issues in daily clinical practice for this particular population. Therefore, we present in this review clinical advice for the diagnosis and treatment options of CVT in women of childbearing age. Furthermore, we discuss long-term aspects of CVT and prophylactic concerns in (pregnant) women with prior CVT.

Diagnostic tools

D-dimers

The European Stroke Guidelines suggest to measure D-dimers before neuroimaging in patients with a high clinical suspicion of CVT, except in those with isolated headache or prolonged duration of symptoms (>1 week), because of the risk of false-negative results.¹⁵ Due to a lack of large well-defined studies regarding the use of D-dimers in specifically the pregnancy and puerperium periods no formal guidelines are available. There is only one study assessing the role of D-dimers in the diagnosis of CVT during puerperium, including

24 patients and 24 matched controls.¹⁶ It found that D-dimer levels were not useful during the puerperium.¹⁶ If CVT is suspected during pregnancy or puerperium, one can consider cerebral imaging instead of measuring D-dimers, as D-dimers are unspecific and tend to be increased due to the increased fibrinolysis following fibrin formation throughout pregnancy.

Cerebral imaging

CVT diagnosis in pregnant women is preferably made by using magnetic resonance imaging (MRI)/MR-venography due to the non-ionizing and non-invasive character. MR-venography using contrast is more sensitive than Time of Flight MR-venography, as the latter is more susceptible to artefacts. During pregnancy, however, the use of contrast should be limited and only used when the benefits outweigh the possible risks for the foetus.¹⁷ T2-weighted gradient recalled echo or susceptibility weighted imaging is recommended in order to visualize intraluminal thrombus.¹⁸ Parenchymal lesions in MRI include venous infarcts and intracerebral haemorrhages.¹⁰ The morphology of the intracerebral haemorrhages varies, ranging from subarachnoid haemorrhages, to small juxtacortical lesions to large haemorrhagic infarctions. Small non-traumatic juxtacortical haemorrhages are a very characteristic feature of CVT and are associated with thrombosis of the superior sagittal sinus (Figure 1).¹⁹

In non-pregnant women or pregnant women in critical condition with a high clinical suspicion of CVT, computed tomography (CT)/CT-venography can be considered when MRI is not available. CT-venography is assumed to be as accurate as MRI/MR-venography; however, studies comparing both are lacking.²⁰ Limitations of CT-venography should be kept in mind, such as the reduced sensitivity for detecting cortical vein thrombosis and parenchymal lesions.¹³

Treatment options

Non-invasive treatments

Types of anticoagulation. Standard treatment in the hyperacute phase of CVT for all patients is anticoagulation using low molecular weight heparin in subcutaneous form (LMWH) or intravenous unfractionated heparin (UFH). This recommendation is also considered for CVT patients with the presence

of intracranial haemorrhage(s). UFH has the advantage of a short half-life with dose adjustments based on activated partial thromboplastin time (APTT) and can be antagonized using protamine sulphate.¹⁵ Although UFH has been assumed to be safe in pregnancy,¹⁵ associations with increased risk of foetal bleeding and teratogenicity are also described.²¹ LMWH does not cross the placenta and has a good safety profile.¹² Hence, LMWH at therapeutic doses has been recommended during the hyperacute phase in pregnant CVT patients.

After the hyperacute phase, oral anticoagulation is indicated, using vitamin K antagonists. However, vitamin K antagonists are contraindicated during pregnancy, because they cross the placenta and can cause neurodevelopmental disorders and foetal bleeding.¹⁵ Direct oral anticoagulants (DOACs) – such as factor Xa inhibitors (apixaban, edoxaban, rivaroxaban) or thrombin inhibitors (dabigatran) – are also contraindicated because they are likely to cross the placenta and teratogenic risks are not well known. Therefore, LMWH is continued in pregnant CVT patients after the hyperacute phase.

Recently, a prospective randomized controlled trial comparing the efficacy and safety of dabigatran 150 mg *versus* dose-adjusted warfarin with an International Normalized Ratio (INR) between 2 and 3, during a 6 month period in 120 CVT patients with mild and moderate clinical severity was published.²² No recurrent venous thromboembolic events or death occurred in either group and the rate of systemic bleeding, new intracranial haemorrhage or haematoma expansion was low.²² However, neither non-inferiority nor superiority of either treatment option could be demonstrated. Furthermore, the broad exclusion criteria – such as pregnancy or planning to become pregnant while in the trial, cancer, major trauma, coma at presentation, central nervous system infections, National Institutes of Health Stroke Scale (NIHSS) >13, and myeloproliferative syndromes – limit the implementation of these results in clinical practice. Future publications in this field, such as the upcoming SECRET trial (efficacy and safety of rivaroxaban 20 mg *versus* unfractionated or low-molecular weight heparin with transition to warfarin in patients with CVT), will hopefully provide additional insights in this matter.

Duration of oral anticoagulation. There are no studies assessing the most optimal duration of anticoagulation in pregnant CVT patients.¹⁵

Therapeutic LMWH is typically continued for at least 6 weeks postpartum based on the known increased risk of CVT following delivery.²³ It is important to keep in mind that the peripartum period may be complicated by the use of anticoagulation due to the risk of bleeding during (Caesarean) delivery.²⁴

For non-pregnant women, a treatment period of 3–12 months can be advised as recommended by the European Stroke Organisation for the general population.¹⁵ The comparison of a short *versus* a long period of treatment is addressed in the ongoing EXCOA-CVT cluster trial, an international prospective multicentre randomized trial comparing the efficacy and safety of a treatment period of 3–6 months with a treatment period of 12 months within 30 days of CVT confirmation.²⁵ However, women of childbearing age without adequate contraceptive measures, pregnancy or breastfeeding are excluded in this trial, which will make the results of this trial not applicable for the target population of this review.

Patients with recurrent venous thromboembolisms or with an associated prothrombotic condition with high thrombotic risk may need lifelong oral anticoagulation with vitamin K antagonists.¹⁵ Bridging with LMWH during pregnancy may be necessary in these patients.

Lactation and (oral) anticoagulation. One should consider the mother's wish regarding breastfeeding in the case of a lifelong indication for anticoagulation after the puerperium period. LMWH is the gold standard during breastfeeding because it does not transfer easily into breastmilk. UFH and warfarin are also acceptable during lactation.¹⁵ DOACs should be avoided as no clinical data is available about their safety during lactation.

Medical treatment of CVT in antiphospholipid syndrome. Positive results for the three available laboratory tests (lupus anticoagulans, anticardiolipin antibodies, and anti-B2-glycoprotein I antibodies) are associated with the highest risk for developing thromboembolism events. Women with these laboratory results have increased risks of diverse pregnancy and obstetric complications, such as small for gestational age, premature birth, (recurrent) miscarriages, (pre)eclampsia and HELLP syndrome.²⁶ The main rationale in the treatment of antiphospholipid syndrome is secondary prevention of such events by the use of

vitamin K antagonists. Nevertheless, patients with triple-positive laboratory tests have a high risk for recurrence of thromboembolism events, even while in the therapeutic INR range.²⁷ However, the use of DOACs is not recommended in triple-positive patients with antiphospholipid syndrome, based on the results of the TRAPS trials. This trial, comparing the efficacy and safety of rivaroxaban 20 mg with dose adjusted warfarin, was terminated prematurely by the Advisory Board based on recommendations of the Adjudication and Safety Committee due to excess of arterial thromboembolism events in the rivaroxaban treatment arm. Possible explanations might be the inter individual variability of rivaroxaban plasma levels and the different mechanism of action between warfarin and rivaroxaban.²⁷

Invasive treatment

Brain herniation due to large haemorrhagic venous infarcts is the most common cause of death in the acute setting of CVT according to the same mechanism as seen in ischaemic strokes.²⁸ The European guidelines recommend decompressive surgery for CVT in patients with intraparenchymal lesions and imminent brain herniation in order to prevent death.¹⁵ There are a few examples available in the literature reporting decompressive surgery in quickly deteriorating women with CVT based on an identifiable risk factor.^{12,29–31} One case has recently been published in which a 22-year-old woman without any identifiable risk factor for CVT deteriorated quickly in early pregnancy and was treated with a life-saving decompressive craniectomy.¹¹ One month after admission to the hospital she was discharged without neurological deficits (mRS 0). Follow-up MRI imaging at 4 months showed complete recanalization of the sinuses. With regard to endovascular treatment, recently the results of the TO-ACT trial that evaluated the efficacy and safety of endovascular treatment in patients with a severe form of CVT have been published.³² The trial showed that endovascular treatment with standard medical care did not appear to improve functional outcome of patients with CVT. Only case reports of endovascular treatment in pregnant women with CVT have been published.¹²

Long-term aspects

Clinical outcome

There are only a few studies assessing the long-term clinical outcome after CVT. In the ISCVT

study – where both pregnant and non-pregnant patients were enrolled – women had a more favourable outcome compared with men (complete recovery 81% *versus* 71%, respectively),¹⁰ as prognosis of CVT is better when associated with sex-specific risk factors like oral contraceptives, pregnancy, puerperium, and hormone replacement therapy.¹³ The overall mortality rate was 7% at 6 months of follow-up. A total of 77 pregnant patients were included in this ISCVT study; however, no comparison was made of outcomes between pregnant and non-pregnant patients. Also, clinical outcomes of the pregnant patients were discussed only very briefly.¹² The available results show one patient with a seizure (1.3%) and three pregnancies that resulted in abortion (3.9%).

A pooled systematic review by Kashkoush *et al.*¹² – including 66 patients with CVT in pregnancy and puerperium – showed 94% of the women to have a mRS between 0 and 2 and 59% to have an mRS of 0 at 6 month follow-up. Clinical presentation with headache alone at the time of treatment with anticoagulation was related to a very good outcome. One patient died with underlying Budd–Chiari syndrome (2%).

Recanalization

The overall rate of venous recanalization in CVT patients using anticoagulation is around 85%.³³ Recanalization mainly occurs in the first few months after the diagnosis of CVT; however, this process may take up to 1 year, with an association between the rate of recanalization and clinical recovery.³³ Positive predictors of recanalization are female sex and thrombosis of the superior sagittal sinus. Negative predictors are hormonal treatment, increasing age, unknown aetiology of CVT, and multiple thromboses. In the systematic review by Kashkoush *et al.* 67% of the pregnant women had involvement of the superior sagittal sinus.¹² The average recanalization time was 39.8 (15.5–64.0) days. The duration of anticoagulation is not a predictor of recanalization.³³ Repetition of brain imaging may be needed during follow-up of CVT patients, to distinguish when symptoms are worsening or new symptoms occur in order to exclude recurrent CVT.

Recurrence risk

The estimated annual recurrence risk of CVT is 1–3% with the highest risk in the first year after

diagnosis.^{34,35} A recent observational prospective study by Palazzo *et al.* ($n=187$) confirmed an annual CVT recurrence risk of around 2% during a mean follow-up period of 80 months.³⁶ Women receiving hormonal therapy at the moment of the first CVT had a lower recurrence risk compared with women with other or unknown risk factors after discontinuation of the hormonal agents.³⁶ A multicentre cohort study including 203 patients – presenting with CVT over 14 years with a median follow-up of 36 months after stopping anticoagulant therapy – estimated an annual recurrence risk of 1–2% for CVT.³⁷ Of the participating patients 86% were female, of whom 93% were of child-bearing age, and 75% were using oral contraceptives or in puerperium when having the first CVT. Heterozygosity for Factor V Leiden was an independent risk factor for the recurrence of CVT.

Use of oral contraceptives

The advice is not to prescribe oestrogen-containing contraceptives in women with prior or active venous thromboembolism. Regarding the use of progestogen-only contraceptives data is lacking and no studies are available on the risk of recurrent venous thromboembolism in women using oral contraceptives at the moment of the prior CVT.¹⁵

Usually, women get hormonal therapy prescribed as anticonception but also in clinical practice in order to decrease the risk or treat active menorrhagia due to uterine bleeding. Therefore, stopping hormonal therapy and starting anticoagulation may increase the risk of menorrhagia in these women.³⁸ The 2010 guidelines of the World Health Organization postulated that there is an important health risk during anticoagulant treatment in women using oestrogen-containing contraceptives.³⁹ However, no difference has been found in the rate of recurrent venous thromboembolism in women treated with anticoagulants between those who use and those who do not use hormonal therapy.³⁸ The International Society on Thrombosis and Haemostasis advises against discontinuation of oestrogen-containing contraceptives in selected patients with a strong clinical indication during anticoagulant treatment.⁴⁰ The anticoagulant treatment may protect against the prothrombotic qualities of the oestrogen-containing contraceptives when both treatments are prescribed concomitantly. An alternative form of contraception should be looked for before stopping the anticoagulant therapy.

Pregnancy after first CVT

In women with prior CVT and subsequent pregnancy, occurrence of venous thromboembolism and adverse pregnancy outcomes were assessed in a systematic review of observational studies including a total of 217 pregnancies.⁴¹ The absolute risk for events was low with nine CVT and 27 non-cerebral venous thromboembolisms per 1000 pregnancies. However, compared with the pregnant women in the general population, there was a higher rate of recurrent CVT and non-cerebral venous thromboembolisms. The rate of spontaneous abortion in women with prior CVT was not significantly increased (18%, 95% confidence interval 13–24)⁴² compared with the rate of spontaneous abortion in the general population (10–15% and even 20% in self-reported data).⁴³ A medical history of CVT should not be assumed as a contraindication for future pregnancies. In pregnancies subsequent to CVT associated with thrombophilia, there is a higher risk of obstetrical complications such as miscarriage and late placenta-mediated complications.⁶

Thromboprophylaxis

A recent study in 25 women showed that thromboprophylaxis with LMWH in pregnant women with prior CVT seems to be safe and effective in preventing recurrent venous thromboembolism compared with pregnant women without prior CVT.⁶ Nevertheless, despite the thromboprophylaxis, these women had an increased risk to develop obstetrical complications, especially in late pregnancy. The risk of late obstetrical complications doubled in carriers of thrombophilia disorders compared with non-carriers.⁶

The current recommendation in women with prior CVT and a moderate to high risk for recurrence of venous thromboembolism is to start thromboprophylaxis with LMWH during the entire pregnancy and puerperium and to start LMWH as soon as possible when pregnancy has been confirmed. For women with a low risk of recurrence of venous thromboembolism, it has been recommended to start only thromboprophylaxis with LMWH during puerperium.⁴⁴

The optimal dose of LMWH in pregnant women with moderate to high risk of recurrence of venous thromboembolism is the subject of debate as there are no randomized controlled trials or clear evidence-based guidelines available. The current

practice is based on consensus guidelines and the results of a few retrospective studies. Prophylactic or intermediate doses of LMWH are currently two options, of which the prophylactic dose is the most often prescribed dose in the clinical setting. Therapeutic doses of LMWH are not widely accepted because of the possible bleeding risk during delivery.⁴⁴

Until the results of the Highlow study – an international open-label randomized trial that will explore the optimal dose of LMWH thromboprophylaxis – are published, prophylactic or intermediate doses of LMWH remain the two options as thromboprophylaxis for women with moderate to high risk for recurrence of venous thromboembolism.⁴⁴ The question remains whether women with thrombophilia benefit from intermediate or even therapeutic doses of thromboprophylaxis with LMWH in order to reduce the obstetric complications.

Conclusion

CVT in women of childbearing age is a diagnostic and therapeutic challenge, especially during pregnancy and shortly after delivery. In this review, we have presented advice on diagnosis, therapy in the (hyper) acute phase and thromboprophylaxis in women with prior CVT. The preferred diagnostic tool in pregnant women is MRI/MR-venography. Anticoagulation is still the preferred treatment option, using LMWH in both the hyperacute and the acute phase of CVT. Decompressive surgery in patients with imminent brain herniation is probably life-saving, even during pregnancy. Overall, women with sex-specific risk factors for CVT have a good clinical outcome with a low recurrence rate. A medical history of CVT alone is not assumed as a contraindication for future pregnancies. The type and duration of anticoagulation and the optimal dosage of thromboprophylaxis with LMWH, in women with moderate to high risk for recurrence of venous thromboembolism during pregnancy and the postpartum period, are actual topics of ongoing trials.

Conflict of interest statement

The authors declare that there is no conflict of interest.

Funding

This research received no specific grant from any funding agency in the public, commercial, or not-for-profit sectors.

ORCID iD

Susanna M. Zuurbier  <https://orcid.org/0000-0001-9288-9043>

References

1. Coutinho JM, Zuurbier SM, Aramideh M, *et al.* The incidence of cerebral venous thrombosis: a cross-sectional study. *Stroke* 2012; 43: 3375–3377.
2. Zuurbier SM, Middeldorp S, Stam J, *et al.* Sex differences in cerebral venous thrombosis: a systematic analysis of a shift over time. *Int J Stroke* 2016; 11: 164–170.
3. Silvis SM, Hiltunen S, Lindgren E, *et al.* Cancer and risk of cerebral venous thrombosis: a case-control study. *J Thromb Haemost* 2018; 16: 90–95.
4. Silvis SM, Middeldorp S, Zuurbier SM, *et al.* Risk factors for cerebral venous thrombosis. *Semin Thromb Hemost* 2016; 42: 622–631.
5. Silvis SM, Lindgren E, Hiltunen S, *et al.* Postpartum period is a risk factor for cerebral venous thrombosis. *Stroke* 2019; 50: 501–503.
6. Abbattista M, Capocchi M and Martinelli I. Pregnancy after cerebral venous thrombosis. *Thromb Res* 2019; 181(Suppl. 1): S15–S18.
7. Zuurbier SM, Arnold M, Middeldorp S, *et al.* Risk of cerebral venous thrombosis in obese women. *JAMA Neurol* 2016; 73: 579–584.
8. Jeng JS, Tang SC and Yip PK. Incidence and etiologies of stroke during pregnancy and puerperium as evidenced in Taiwanese women. *Cerebrovasc Dis* 2004; 18: 290–295.
9. Lanska DJ and Kryscio RJ. Risk factors for peripartum and postpartum stroke and intracranial venous thrombosis. *Stroke* 2000; 31: 1274–1282.
10. Ferro JM, Canhao P, Stam J, *et al.* Prognosis of cerebral vein and dural sinus thrombosis: results of the international study on cerebral vein and dural sinus thrombosis (ISCVT). *Stroke* 2004; 35: 664–670.
11. Gioti I, Faropoulos K, Poulas C, *et al.* Decompressive craniectomy in cerebral venous sinus thrombosis during pregnancy: a case report. *Acta Neurochir (Wien)* 2019; 161: 1349–1352.
12. Kashkoush AI, Ma H, Agarwal N, *et al.* Cerebral venous sinus thrombosis in pregnancy and puerperium: a pooled, systematic review. *J Clin Neurosci* 2017; 39: 9–15.

13. Coutinho JM, Ferro JM, Canhao P, *et al.* Cerebral venous and sinus thrombosis in women. *Stroke* 2009; 40: 2356–2361.
14. Coutinho JM, Zuurbier SM and Stam J. Declining mortality in cerebral venous thrombosis: a systematic review. *Stroke* 2014; 45: 1338–1341.
15. Ferro JM, Boussier MG, Canhao P, *et al.* European stroke organization guideline for the diagnosis and treatment of cerebral venous thrombosis - endorsed by the European academy of neurology. *Eur Stroke J* 2017; 2: 195–221.
16. Thammishetti V, Dharanipragada S, Basu D, *et al.* A prospective study of the clinical profile, outcome and evaluation of d-dimer in cerebral venous thrombosis. *J Clin Diagn Res* 2016; 10: OC07-10.
17. Committee on Obstetric Practice. Committee opinion no. 723: guidelines for diagnostic imaging during pregnancy and lactation. *Obstet Gynecol* 2017; 130: e210–e216.
18. Ferro JM and Aguiar de Sousa D. Cerebral venous thrombosis: an update. *Curr Neurol Neurosci Rep* 2019; 19: 74.
19. Coutinho JM, van den Berg R, Zuurbier SM, *et al.* Small juxtacortical hemorrhages in cerebral venous thrombosis. *Ann Neurol* 2014; 75: 908–916.
20. Coutinho JM and Stam J. How to treat cerebral venous and sinus thrombosis. *J Thromb Haemost* 2010; 8: 877–883.
21. Saposnik G, Barinagarrementeria F, Brown RD Jr, *et al.* Diagnosis and management of cerebral venous thrombosis: a statement for healthcare professionals from the American heart association/American stroke association. *Stroke* 2011; 42: 1158–1192.
22. Ferro JM, Coutinho JM, Dentali F, *et al.* Safety and efficacy of dabigatran etexilate vs dose-adjusted warfarin in patients with cerebral venous thrombosis: a randomized clinical trial. *JAMA Neurol* 2019; 76: 1457–1465.
23. Roth J and Deck G. Neurovascular disorders in pregnancy: a review. *Obstet Med* 2019; 12: 164–167.
24. Camargo EC, Feske SK and Singhal AB. Stroke in pregnancy: an update. *Neurol Clin* 2019; 37: 131–148.
25. Miranda B, Aaron S, Arauz A, *et al.* The benefit of extending oral anticoagulation treatment (EXCOA) after acute cerebral vein thrombosis (CVT): EXCOA-CVT cluster randomized trial protocol. *Int J Stroke* 2018; 13: 771–774.
26. Fischer-Betz R and Specker C. Pregnancy in systemic lupus erythematosus and antiphospholipid syndrome. *Best Pract Res Clin Rheumatol* 2017; 31: 397–414.
27. Pengo V, Denas G, Zoppellaro G, *et al.* Rivaroxaban vs warfarin in high-risk patients with antiphospholipid syndrome. *Blood* 2018; 132: 1365–1371.
28. Canhao P, Ferro JM, Lindgren AG, *et al.* Causes and predictors of death in cerebral venous thrombosis. *Stroke* 2005; 36: 1720–1725.
29. Ebke M, Jurgens KU, Tomandl B, *et al.* Surgical treatment of space occupying edema and hemorrhage due to cerebral venous thrombosis during pregnancy. *Neurocrit Care* 2011; 15: 166–169.
30. Han KH, Won YD, Na MK, *et al.* Postpartum superior sagittal sinus thrombosis: a case report. *Korean J Neurotrauma* 2018; 14: 146–149.
31. Yamamoto J, Kakeda S, Takahashi M, *et al.* Severe subarachnoid hemorrhage associated with cerebral venous thrombosis in early pregnancy: a case report. *J Emerg Med* 2013; 45: 849–855.
32. Coutinho JM, Zuurbier SM, Boussier MG, *et al.* Effect of endovascular treatment with medical management vs standard care on severe cerebral venous thrombosis: the to-act randomized clinical trial. *JAMA Neurol*. Epub ahead of print 18 May 2020. DOI: 10.1001/jamaneurol.2020.1022.
33. Aguiar de Sousa D, Lucas Neto L, Canhao P, *et al.* Recanalization in cerebral venous thrombosis. *Stroke* 2018; 49: 1828–1835.
34. Hiltunen S, Putaala J, Haapaniemi E, *et al.* Long-term outcome after cerebral venous thrombosis: analysis of functional and vocational outcome, residual symptoms, and adverse events in 161 patients. *J Neurol* 2016; 263: 477–484.
35. Miranda B, Ferro JM, Canhao P, *et al.* Venous thromboembolic events after cerebral vein thrombosis. *Stroke* 2010; 41: 1901–1906.
36. Palazzo P, Agius P, Ingrand P, *et al.* Venous thrombotic recurrence after cerebral venous thrombosis: a long-term follow-up study. *Stroke* 2017; 48: 321–326.
37. Pires GS, Ribeiro DD, Oliveira JAQ, *et al.* Risk factors associated with recurrent venous thromboembolism after a first cerebral venous thrombosis event: a cohort study. *Thromb Res* 2019; 178: 85–90.

38. Martinelli I, Lensing AW, Middeldorp S, *et al.* Recurrent venous thromboembolism and abnormal uterine bleeding with anticoagulant and hormone therapy use. *Blood* 2016; 127: 1417–1425.
39. Dinis da Gama A. [The unknown history of heparin's discovery]. *Rev Port Cir Cardiorac Vasc* 2008; 15: 25–30.
40. Baglin T, Bauer K, Douketis J, *et al.* Duration of anticoagulant therapy after a first episode of an unprovoked pulmonary embolus or deep vein thrombosis: guidance from the SSC of the ISTH. *J Thromb Haemost* 2012; 10: 698–702.
41. Aguiar de Sousa D, Canhao P and Ferro JM. Safety of pregnancy after cerebral venous thrombosis: a systematic review. *Stroke* 2016; 47: 713–718.
42. Aguiar de Sousa D, Canhao P, Crassard I, *et al.* Safety of pregnancy after cerebral venous thrombosis: results of the ISCVT (international study on cerebral vein and dural sinus thrombosis)-2 pregnancy study. *Stroke* 2017; 48: 3130–3133.
43. Buss L, Tolstrup J, Munk C, *et al.* Spontaneous abortion: a prospective cohort study of younger women from the general population in Denmark. Validation, occurrence and risk determinants. *Acta Obstet Gynecol Scand* 2006; 85: 467–475.
44. Bleker SM, Buchmuller A, Chauleur C, *et al.* Low-molecular-weight heparin to prevent recurrent venous thromboembolism in pregnancy: rationale and design of the Highlow study, a randomised trial of two doses. *Thromb Res* 2016; 144: 62–68.