

Aim of the study: The aim of this study is to research the contribution of radiothermometry (RTM) to the characterization of breast masses, the differentiation of malignant-benign masses and diagnosis of early stage breast cancer.

Material and methods: This prospective study comprised 182 cases of patients diagnosed with a breast mass and a control group of 55 cases: a total of 237.

Results: When histopathology is accepted as the gold standard among diagnostic methods, the sensitivity, specificity, and positive-negative predictive value for RTM were 90.9%, 20.8%, 61.2% and 62.5%, respectively. Consistency was 0.129. When compared with mammography the same values for RTM examination are 87%, 81.4%, 58% and 95.5%. Consistency was 0.582. Evaluating with respect to size of the mass accepting mammography as the gold standard, RTM examination had sensitivity, specificity, positive and negative predictive values for masses 2 cm and above of 88.9%, 83.3%, 88.9% and 83.3%. Consistency was 0.722. The consistency of RTM for lesion diagnosis in BI-RADS II breast structure is higher than the consistency of mammography.

Conclusions: Identification of lesions in the breast and presence of microcalcification by RTM shows that it is more trustworthy compared to mammography. When compared with mammography the validity results for RTM show there is a good level of conformity between the two methods. When evaluated based on the area below the ROC curve and compared to mammography, RTM is sufficiently successful at evaluating positive and negative cases.

Key words: radiothermometer, breast cancer, radiometry, mammography, ultrasonography.

Contemp Oncol (Pozn) 2014; 18 (3): 197–203
DOI: 10.5114/wo.2014.42721

Efficacy and safety of breast radiothermometry in the differential diagnosis of breast lesions

Sahnaz Caferova¹, Fatma Uysal^{1,2}, Pinar Balci¹, Serdar Saydam³, Tülay Canda⁴

¹Department of Radiology, Dokuz Eylül University, Izmir, Turkey

²Çanakkale Onsekiz Mart University, Çanakkale, Turkey

³Department of General Surgery, Dokuz Eylül University, Izmir, Turkey

⁴Department of Pathology, Dokuz Eylül University, Izmir, Turkey

Introduction

Breast cancer, the most common form of cancer in women together with lung cancer, continues to be an important cause of mortality and morbidity. According to the American Cancer Society, breast cancer is the most frequently diagnosed cancer in women in the US and is the second highest cause of cancer-related deaths in women [1, 2].

Mammography, with 90% sensitivity for screening and identifying breast lesions, is still the most basic method. However, in some cases, lesions that are palpable on clinical examination may remain hidden on mammography due to superposition of breast tissue. Sometimes mammography size was smaller than histopathological size [2]. Additionally, more than 75% of lesions identified on mammography are diagnosed as pathologically benign. The most important problem is that the sensitivity of mammography to identify lesions is reduced in situations with dense breast tissue due to history of radiotherapy or surgery, breast tissue adjacent to implants and dense breast tissue in the young population. In this situation the first method to investigate the breast is ultrasonography. This method is very successful for lesion identification, especially for differentiating cystic and solid masses; however, the most important limitation is that it cannot identify microcalcification and ductal carcinoma *in situ* [2–4].

A thermal imaging system, breast radiothermometry mammography (RTM), which measures and analyzes the breast surface (infrared thermometry) and internal temperature (microwave thermometry), is a sensitive method that aids the diagnosis of breast cancer. The RTM devices measure electromagnetic waves sent through the breast tissue to identify the diseased area. The microwave thermometry method is a new technology developed in recent years. This method can diagnose cancer using the thermal activity of cancer cells before they have caused any structural changes in breast tissue. It has the potential to distinguish between fibrocystic cell changes and cancer cell changes. Investigation does not involve radiation, and all areas can be imaged including the area where the breast meets the arm [5, 6].

There is no definite preventive method for breast cancer yet. The current aim is early diagnosis. Due to early diagnosis, many of the problems caused by breast cancer can be solved, reducing the damage to the patient population to a minimum and increasing duration and quality of life appreciably.

The aim of this study is to research the contribution of RTM to the characterization of breast masses, the differentiation of malignant-benign masses and diagnosis of early stage breast cancer.

Material and methods

This prospective study comprised 182 patients who applied to the Mammography unit of the Radiology Clinic of Dokuz Eylul University Medical Faculty Hospital and were diagnosed with a breast mass and a control group of 55 cases: a total of 237.

According to mammographic and ultrasonography evaluation 57 cases were pre-diagnosed with Breast Imaging-Reporting and Data System (BI-RADS) IV and BI-RADS V and were biopsied and histopathologic scans were completed. Sixty cases were diagnosed as BI-RADS II lesions and 65 cases were diagnosed as BI-RADS III and monitored.

Mammographic investigation used the "Hologic-Selenia Digital Mammography System" in the craniocaudal (CC) and mediolateral-oblique (MLO) positions. Extra positions for investigation were used for patients requiring them. Breast ultrasonography investigations used a (Philips HD11 USG) Doppler ultrasonography (US) device 5–12 MHz high-resolution linear probe and were completed simultaneously to mammography. After patients signed the informed consent form, radiothermometry examination was completed using a Computer Based Radiometer for Measuring Integral Internal Temperature (RTM-01-RES) device. Investigations were completed by an operator blind to the results of the mammography. Before examination, room temperature was fixed at 23–25°C. Patients removed clothing above the waist and lay supine with hands under the head for 10 minutes to adjust to the room temperature. Each breast was measured in 9 different regions and in the axilla region. As recommended in the literature [7], to attain body temperature the probe was first placed on the epigastrium. The probe axis was held perpendicular to the skin surface and the full surface was touched to the skin. It was held without pressure for 15 seconds. The start of the probe sensing temperature was shown by a line forming on the screen. Once the warning signal was heard the probe was placed on the other breast. Both breasts were measured at 15-second intervals. Of the total of 237 patients who underwent RTM examination a temperature increase was noted in 128 (55%) (Fig. 1).

Measured RTM results were shown on the monitor in diagram form. To image the areas of internal heat, the names of measured points were shown on the horizontal axis with the corresponding internal temperatures shown on the vertical axis.

Data were displayed on the monitor with different colors. The cool areas of the breast were shown with cold colors (e.g., blue) and warm areas were shown with warmer colors (e.g., red and orange). Heat abnormalities in the microwave region, especially, denote regions of cancer. After processing the images of the data were sent to a color printer.

In the study, accepting histopathologic diagnosis as the gold standard, the validity (sensitivity, specificity, positive predictive value, negative predictive value) and consistency κ values for mammography, US and RTM methods were measured.

We compared RTM results with X-ray mammography and the diagnostic value of RTM was statistically re-

searched. Under this heading the sensitivity, specificity, positive-negative predictive value and consistency of RTM and US were evaluated compared to mammography.

Again we compared RTM results with X-ray mammography, the diagnostic value of RTM for size of mass and presence of microcalcification compared to mammography was researched, and the success of RTM in identifying lesions in different breast densities was evaluated.

Statistical analysis

The statistical analysis descriptively presents the number and percentage distributions, mean \pm standard deviation, median, minimum and maximum values. Validity analysis was examined as sensitivity, specificity, positive predictive value and negative predictive value compared to the gold standard of the scanning tests. Consistency in measurements was examined using the κ value.

Results

The average age of patients was 48.5 \pm 10.3 and median age was 48 (28–81). Evaluating the breast parenchyma structure of patients with mammography 22% (52/237) were BI-RADS I, 49% (116/237) were BI-RADS II, 14% (34/237) were BI-RADS III and 15% (35/237) were BI-RADS IV.

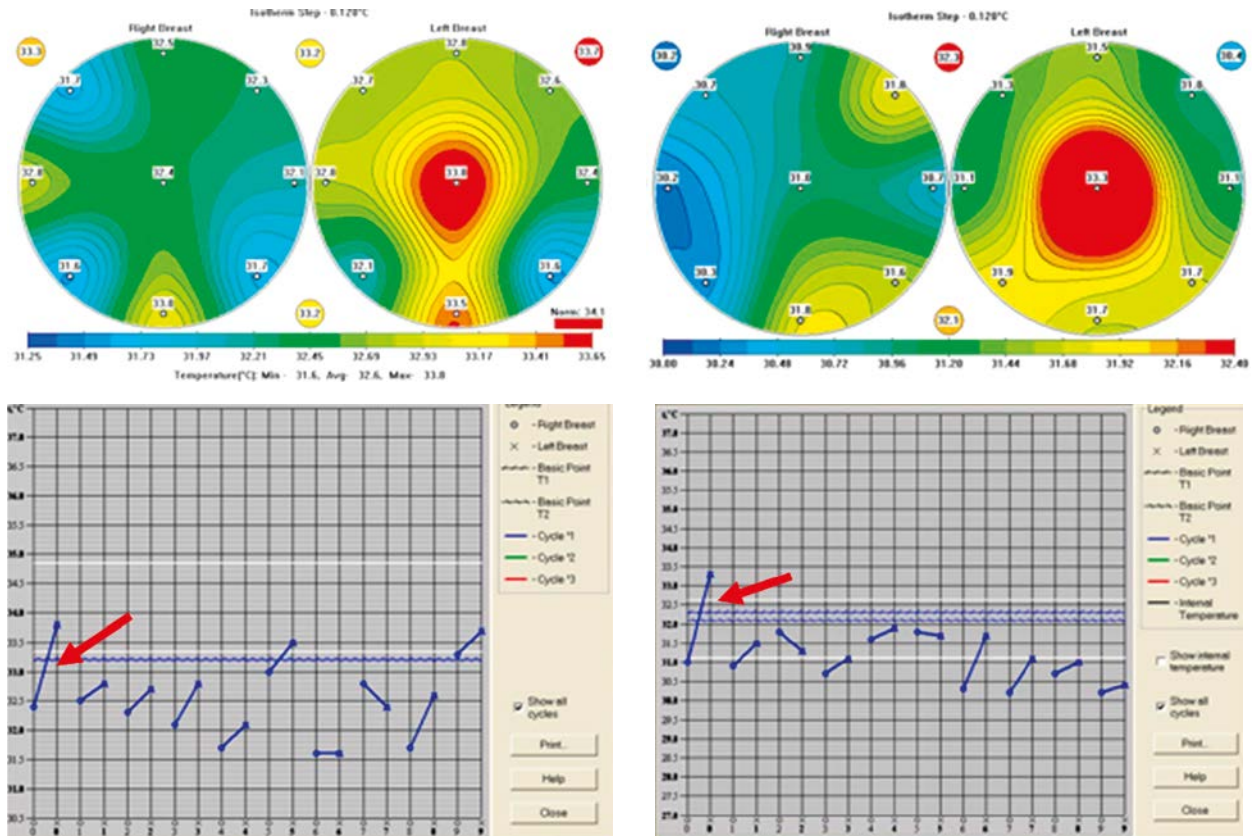
Of patients with biopsy taken 33 (57.9%) were malignant and 24 (42.1%) were benign histopathologically. Mammography and US examination diagnosed 16 cases as BI-RADS IV A, 21 as BI-RADS IV B, 4 as BI-RADS IV C and 16 as BI-RADS V.

When histopathology is accepted as the gold standard among diagnostic methods, the sensitivity, specificity, and positive-negative predictive value for RTM were 90.9%, 20.8%, 61.2% and 62.5%, respectively. Consistency was very low at 0.129. The same values for mammography were 93.9%, 43.3%, 57.4% and 33.3%, respectively. Consistency was evaluated as good at 0.622. Ultrasound examination values were 84.8%, 56.7%, 58.3% and 44.4%, respectively. Consistency was good at 0.717. For mammography and US in situations where a malignant mass was observed sensitivity, specificity, positive and negative predictive values were 96.7%, 60.8%, 47.7% and 65.8%, respectively, with consistency very good at 0.915 (Table 1).

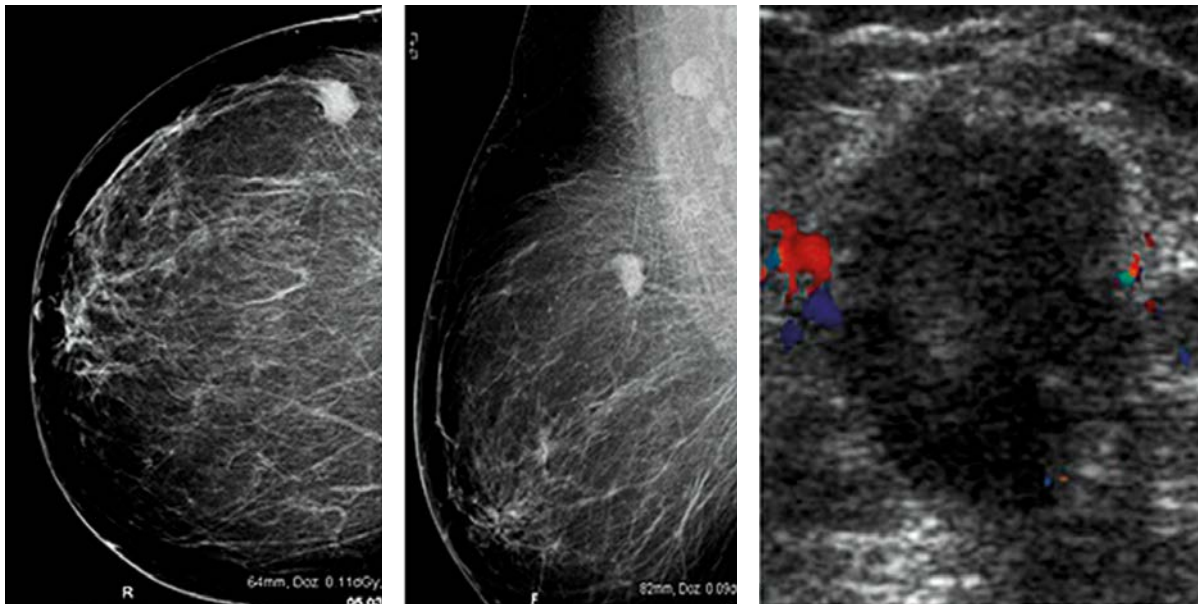
Accepting pathology as the gold standard an ROC curve was drawn for RTM and mammography methods. For RTM the area under the curve was 53.3% while mammography had 86.1% area under the curve. In other words, while a patient with breast cancer has an 86.1% possibility of having a suspicious positive on mammography, with RTM this rate is 53.3% (Fig. 2).

When we compared RTM results with X-ray mammography results, sensitivity, specificity, and positive-negative predictive values for RTM examination are 87%, 81.4%, 58% and 95.5%. Consistency is good at 0.582. For US examination the same values are 85.2%, 98.9%, 95.8% and 95.8%, respectively. Consistency is very high at 0.875 (Table 2).

When we compared RTM results with X-ray mammography results for microcalcification diagnosis, the sensitivity, specificity, and positive-negative predictive values for



RTM report: Increase of the temperature in the tissue and skin on the central part of the left breast. The temperature was measured as 34.5°C (red arrow).



Mammography and USG: In the left breast upper outer region, slightly irregular contours, approximate dimensions of 18 × 14 mm hypoechoic mass, in view of BI-RADS 4C lesion

Histopathological diagnosis: Invasive ductal carcinoma and invasive cribriform carcinoma in left breast

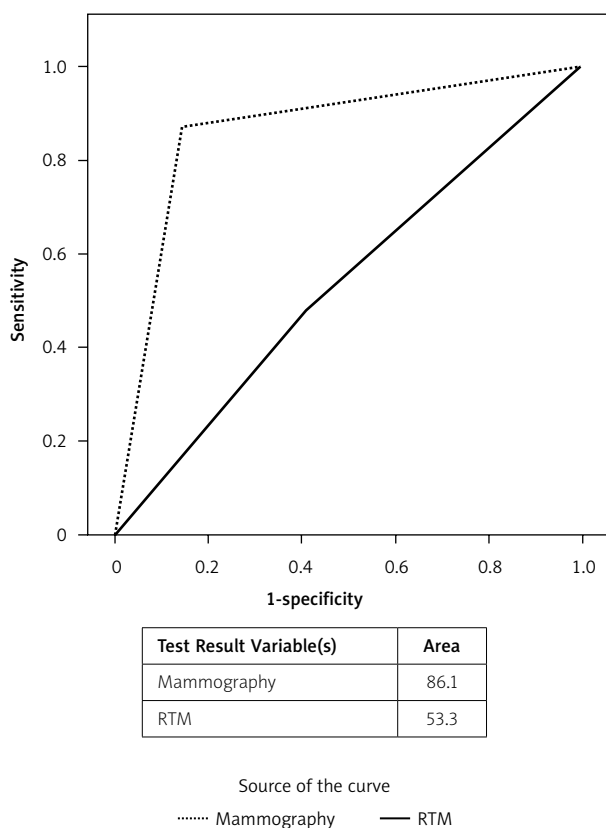
Fig. 1. A case: RTM positive 56-year-old patient

RTM were 86.7%, 80%, 92.9% and 66.7%. Consistency was at a good level of 0.625. The same values for RTM examination in the absence of microcalcification were recorded as 87.2%, 18.5%, 50.7% and 49.3%, respectively. Consisten-

cy was good at 0.536. That is, in patients with microcalcification the specificity, positive and negative predictive values for the RTM method were higher than for patients without microcalcification. Consistency in both cases was

Table 1. Diagnostic value of imaging methods according to histopathology results ($n = 57$)

Diagnostic method	Sensitivity (%)	Specificity (%)	Positive predictive value (%)	Negative predictive value (%)	κ value
RTM	90.9	20.8	61.2	62.5	0.129
Mammography	93.9	43.3	57.4	33.3	0.622
US	84.8	56.7	58.3	44.4	0.717
Mammography ve US	96.7	60.8	47.7	65.8	0.915

**Fig. 2.** ROC curves for RTM and mammography accepting pathology as the gold standard

at moderate levels, though higher for patients with microcalcification than for those without (Table 3).

The sensitivity, specificity, and positive-negative predictive values of RTM for determining lesions in different breast structure are as follows: BI-RADS I breast structure sensitivity 75%, specificity 77.8%, positive predictive value 60%, negative predictive value 87.5% and consistency good at 0.494. BI-RADS II breast structure sensitivity was 93.1%, specificity was 86.2%, positive predictive value was 69.2%, negative predictive value was 97.4% and consistency was at a good level of 0.711. BI-RADS III breast structure

sensitivity was 100%, specificity 100%, positive predictive value 25%, negative predictive value 94.1% and consistency low at 0.338. BI-RADS IV breast structure sensitivity was 85.7%, specificity 71.4%, positive predictive value 42.9%, negative predictive value 42.9% and consistency low at 0.416 (Table 4).

The consistency of RTM for lesion diagnosis in BI-RADS II breast structure is higher than the consistency of mammography. Mammography of dense breast tissue such as BI-RADS III and BI-RADS IV is at moderate to low levels.

The sensitivity, specificity, and positive-negative predictive values for US examination of different breast structures are as follows: BI-RADS I sensitivity 87.5%, specificity 100%, positive predictive value 100%, negative predictive value 94.7%. Consistency was very high at 0.906. BI-RADS II: sensitivity 89.7%, specificity 97.7%, positive predictive value 92.9%, negative predictive value 96.6% and consistency very good at 0.884. BI-RADS III: sensitivity 50%, specificity 100%, positive predictive value 100%, negative predictive value 97% and consistency good at 0.653. BI-RADS IV: sensitivity 71.4%, specificity 100%, positive predictive value 100%, negative predictive value 93.3% and consistency very good at 0.800 (Table 5).

Discussion

This study is the first study in the literature that evaluates RTM in relation to mass size. In our study we examined the sensitivity, specificity and positive-negative values for RTM according to mass size. The specificity and positive predictive value of RTM for masses 2 cm and above were higher than for those below 2 cm. For masses below 2 cm in size the negative predictive value of RTM was higher when compared with mammography.

The aim of breast imaging methods is to identify breast cancer in the early stages and to distinguish from different types of breast disease. In choosing a scanning method the most frequently used methods chosen by both clinicians and radiologists are mammography, ultrasonography and magnetic resonance imaging [2, 3, 8].

The thermal imaging system breast radiothermometry examination (RTM) measures and analyses the tempera-

Table 2. Sensitivity, specificity, and positive-negative predictive values of diagnostic methods according to mammography results ($n = 237$)

Diagnostic method	Sensitivity (%)	Specificity (%)	Positive predictive value (%)	Negative predictive value (%)	κ value
RTM	87.0	81.4	58.0	95.5	0.582
US	85.2	98.9	95.8	95.8	0.875

Table 3. Sensitivity, specificity, and positive-negative predictive values of RTM according to mass size accepting mammography as gold standard

Diagnostic method	Sensitivity (%)	Specificity (%)	Positive predictive value (%)	Negative predictive value (%)	κ value
RTM (mass size \geq 2 cm)* (n = 45)	88.9	83.3	88.9	83.3	0.722
RTM (mass size < 2 cm) (n = 123)	89.5	76.9	41.5	97.6	0.451
RTM (microcalcification – yes) (n = 20)	86.7	80	92.9	66.7	0.625
RTM (microcalcification – no) (n = 217)	87.2	18.5	50.7	49.3	0.536

*In cases with more than one mass, the size of the largest mass was noted

Table 4. Sensitivity, specificity, and positive-negative predictive values of RTM for identifying lesions in different breast structures (n = 237)

Diagnostic method RTM	Sensitivity (%)	Specificity (%)	Positive predictive value (%)	Negative predictive value (%)	κ value
BI-RADS I (n = 52)	75	77.8	60	87.5	0.494
BI-RADS II (n = 116)	93.1	86.2	69.2	97.4	0.711
BI-RADS III (n = 34)	100	100	25	94.1	0.338
BI-RADS IV (n = 35)	85.7	71.4	42.9	95.2	0.416

Table 5. Sensitivity, specificity, and positive-negative predictive values of US examination to identify lesions in different breast structures (n = 237)

Diagnostic method US	Sensitivity (%)	Specificity (%)	Positive predictive value (%)	Negative predictive value (%)	κ value
BI-RADS I	87.5	100	100	94.7	0.906
BI-RADS II	89.7	97.7	92.9	96.6	0.884
BI-RADS III	50.0	100	100	97.0	0.653
BI-RADS IV	71.4	100	100	93.3	0.800

ture of the breast surface (infrared thermometry) and the internal tissue (microwave thermometry) and is a method to aid in the diagnosis of breast cancer. The RTM device measures electromagnetic waves transmitted through breast tissue to identify the diseased area. Microwave thermometry is a technology developed in recent years which aims to diagnose cancer using thermal activity of cancer cells in breast tissue, before structural changes occur. It is reported that this method has the potential to differentiate between fibrocystic cell changes and cancer cell changes. Examination does not involve radiation. All areas, including the axilla, can be imaged [3–10].

Microwave radiometry was used as a heat method for breast examination for the first time by Barrett *et al.* In a study of 5000 patients the method was to expose tissue to heat at microwave frequencies. Sensitivity and specificity were 70%. While microwave thermography affects all breast tissue, infrared thermometry only affects the epidermis, making microwave thermography more produc-

tive. Combined use of RTM and infrared thermometry has a sensitivity of 90% while specificity is 50% [5, 9, 10].

While it may not be used widely in medical applications, the first study to use microwave radiometry as a diagnostic method for breast cancer was published in 1977 [11]. Many years later, developed from trustworthy and simple studies, a computer-based, always ready microwave radiometry device that does not require calibration was developed (RTM-01-RES) [11–13]. This device was the RTM device used in our study. It records the temperature increase caused by masses 3–5 cm deep in the breast tissue. In malignant masses a fast temperature increase is directly correlated with the speed of growth of the mass. On thermograms of breast cancer this is identified as hyperthermic areas, due to their high metabolic process and good vascularization. This method, in a study of 1000 patients, had sensitivity of 85–94% and specificity of 75–80%. Both methods, mammography and RTM, when used together can reduce false negative results by 1–3% [14–16].

The radiothermometry examination can be used not only for breast cancer, but also for diagnosis of urinary [17], anterior eye [18], and thyroid [19] diseases, and rheumatoid arthritis [20].

Burdina *et al.* [21] in a study of 1000 patients found that RTM results correlated with pathology; the sensitivity of this method was 85–94%, specificity was 75–80% and the RTM results overlapped with those of mammography. Avramenko *et al.* [15] studied non-palpable masses in 200 female patients using RTM scanning together with US and mammography. They concluded that the sensitivity of the three methods was 86.7%, 75.8% and 88.3% with specificity of 75.2%, 80.0% and 83%.

In this study, as in other studies, suspicious cases not only on RTM, but also on mammography and US, were sent for histopathologic diagnosis. As a result, positive results were expected to be higher. In other words, sensitivity and positive predictive values in this study were higher than specificity and negative predictive values. Similar results are seen in Table 5 where the specificity and negative predictive values between mammography and histopathology are lower than sensitivity and positive predictive values. This situation results from a higher proportion of malignant cases being directed for histopathologic diagnosis.

When we compared RTM results with X-ray mammography results, the validity results for RTM (sensitivity, specificity, positive and negative predictive values) are 87.0%, 81.4%, 58% and 95.5% respectively, with the consistency value at a good level of $\kappa = 0.582$. This result indicates that there is a high level of compliance between both diagnostic methods.

In other studies the high specificity value may be due to histopathologic diagnosis for suspicious cases based on clinical results and/or on RTM. In our study the criterion for the invasive method of biopsy was suspicion on mammography and US. As a result the moderate values for specificity and negative predictive values compared to other studies are natural [13–16, 21].

There are no studies in the literature that evaluate RTM in relation to mass size. In our study we examined the sensitivity, specificity and positive-negative values for RTM according to mass size. RTM examination had sensitivity, specificity and positive-negative values for masses 2 cm and above of 88.9%, 83.3%, 88.9% and 83.3%. For masses below 2 cm in size the sensitivity, specificity and positive-negative values for RTM were 89.5%, 76.9%, 41.5% and 97.6%. In conclusion, the specificity and positive predictive value of RTM for masses 2 cm and above were higher than for those below 2 cm. For masses below 2 cm in size the negative predictive value of RTM was higher. Sensitivity in both cases was similar. There is no study in the literature evaluating according to mass size.

Sensitivity, specificity and positive-negative values of RTM examination in the presence of microcalcification were 86.7%, 80.0%, 92.9% and 66.7%, respectively. In the absence of microcalcification the sensitivity, specificity and positive-negative values were 87.2%, 18.5%, 50.7% and 49.3%, respectively. The conclusion is that in cases with microcalcification the specificity, positive and negative predictive values were higher than in cases without

microcalcification. The reason for this may be the possibility that the lesion is large or that it may be late stage. However, there is no study in the literature that evaluates based on the presence of microcalcification.

Additionally, the sensitivity, specificity and positive-negative values of RTM in different breast structures were researched. The results for BI-RADS I breast density were sensitivity 75%, specificity 77.8%, positive predictive value 60% and negative predictive value 87.5%. For BI-RADS II breast density sensitivity was 93.1%, specificity 86.2%, positive predictive value 69.2% and negative predictive value 97.4%. BI-RADS III sensitivity was 100%, specificity was 100%, positive predictive value was 25% and negative predictive value was 94.1%. For BI-RADS IV breast density sensitivity was 85.7%, specificity 71.4%, positive predictive value 42.9% and negative predictive value 42.9%. The consistency of RTM for lesion diagnosis in BI-RADS II breast density was higher than for mammography. On mammography for dense breast tissue types such as BI-RADS III and BI-RADS IV values were moderate and low. The sensitivity, specificity, and positive-negative predictive values of US for lesion detection in different breast densities were higher than for RTM. There is no study in the literature with information on this topic.

Our study comprised 237 patients. Of these, only 57 were sent for histopathologic diagnosis of masses found on mammography and US. The low case number and low number of patients with histopathologic diagnosis by biopsy are important limitations. However, the research into sensitivity for lesion recognition based on breast density, presence of microcalcification and mass size is an advantage not found in the literature.

In conclusion, identification of lesions in the breast and presence of microcalcification by RTM shows that it is more trustworthy compared to mammography. Accepting mammography as the gold standard, the validity results for RTM show a good level of conformity between the two methods. When evaluated based on the area below the ROC curve and compared to mammography, RTM is sufficiently successful at evaluating positive and negative cases. These results show that RTM is not appropriate as a single scanning method. If this method is used, it is more appropriate to use it with basic scanning methods such as mammography and US. As the experience in this area is limited, we believe that studies with higher case numbers will further determine the diagnostic contribution of RTM.

The authors declare no conflict of interests.

References

1. Aberle DR, Chiles C, Gatsonis C, Hillman BJ, Johnson CD, McClellan BL, Mitchell DG, Pisano ED, Schnall MD, Sorensen AG; American College of Radiology Imaging Network. Imaging and cancer: research strategy of the American College of Radiology Imaging Network. *Radiology* 2005; 235: 741-51.
2. Niedźwiecki S, Piekarski J, Jeziorski A. Influence of the imaging method and histopathological features on preoperative size prediction of ductal carcinoma in situ (DCIS) of the breast. *Prz Menopausalny* 2013; 17: 459-63.

3. Popiela TJ, Kibil W, Herman-Sucharska I, Urbanik A. The use of magnetic resonance mammography in women at increased risk for developing breast cancer. *Wideochir Inne Tech Malo Inwazyjne* 2013; 8: 55-62.
4. Leung JW. Screening mamograhpy reduced morbidity of breast cancer treatment. *AJR Am J Roentgenol* 2005; 184: 1508-9.
5. Bardati F, Iudicello S. Modeling the visibility of breast malignancy by a microwave radiometer. *IEEE Trans Biomed Eng* 2008; 55: 214-21.
6. Fear EC. Microwave imaging of the breast. *Technol Cancer Res Treat* 2005; 4: 69-82.
7. Burdina LM, Vaisblat DS, Vesnin MA, Konkin AV, Lyashekov NG, Naumkina, NN et al. Detection of breast cancer with microwave radiometry. *Mammology* 1998; 3-12.
8. Berman CG. Recent advances in breast-specific imaging. *Cancer Control* 2007; 14: 338-49.
9. Burdina LM, Pinkhosevich IG, Khailenko VA, Vesnin SG, Tikhomirova NN. Experience of Using RTM-01-RES Radiometer for Breast Cancer Diagnosis Radiology' 2002. Proceedings of the III Russian Scientific Forum "X-Ray Diagnostics and X-Ray Therapy in Clinic of XXI", Moscow, Aviaizdat 2002; 49-50.
10. Gledo I, Pranjić N, Drljević K, Prasko S, Drljević I, Brzeziński P. Female breast cancer in relation to exposure to medical iatrogenic diagnostic radiation during life. *Contemp Oncol (Pozn)* 2012; 16: 551-6.
11. Barrett AH, Myers PC, Sadowsky NL. Detection of breast cancer by microwave radiometry. *Radio Sci* 1977; 12: 167.
12. Mashal A, Booske JH, Hagness SC. Toward contrast-enhanced microwave-induced thermoacoustic imaging of breast cancer: an experimental study of the effects of microbubbles on simple thermoacoustic targets. *Phys Med Biol* 2009; 54: 641-50.
13. Fogiel M, Zbroch T, Knapp P, Knapp P. Microwave thermography in the assessment of breast pathology. *Med Wieku Rozwoj* 2002; 6: 63-73. [Article in Polish].
14. Sdvigkov AM, Vesnin SG, Kartasheva AF, Bjahov MU, Gurtvoy II, Borisov VI, et al. Role of Microwave Radiometry in Mammology. *Actual Problems of Mammology* 2000; 28-40.
15. Avramenko GV. Use of radiothermometry in the screening of non-palpable breast neoplasms. *Vestn Rentgenol Radiol* 2007; 9-12.
16. Barrett AH, Myers PhC, Sadowsky NL. Microwave thermography in the detection of breast cancer. *AJR Am J Roentgenol* 1980; 134: 365-8.
17. Avdoshin VP, Andriukhin MI, Ol'shanskaia EV. Parenteral litholytic therapy of urate urolithiasis. *Urologiia* 2008; (4): 9-10, 12-3.
18. Orlov PI. Infrared radiothermometry in the differential diagnosis of dystrophic and inflammatory diseases of the anterior eye. *Vestn Oftalmol* 2008; 124: 19-22. [Article in Russian].
19. Vetshev PS, Chilingaridi KE, Zolkin AV, Vesnin SG, Gabaidze DI, Bannyi DA. Radiothermometry in diagnosis of thyroid diseases. *Khirurgiia (Mosk)* 2006; (6): 54-8. [Article in Russian].
20. Bazhanov NN, Semenova EV, Ginzburg LI. The use of radiothermometry in patients with rheumatoid arthritis. *Ter Arkh* 1992; 64: 93-6.
21. Burdina LM, Vaisblat AV, Vesnin SG, Tihomirova NN. Possibility to diagnose breast cancer by measuring natural electromagnetic radiation from tissues (radiothermometry). *Mammology* 1997; 17-22.

Address for correspondence

Fatma Uysal

Çanakkale Onsekiz Mart University
17100 Çanakkale, Turkey
e-mail: afatmauysal@gmail.com

Submitted: 28.10.2013

Accepted: 25.02.2014