

Vertebral column decortication for the management of sharp angular spinal deformity in Pott disease

Case report

Hong-Tao Hu, MD, Feng-Yu Liu, MM, Jin-He Yu, MM, Liang Ren, MM, Zhen-Fang Gu, MD, Xian-Ze Sun, MM*

Abstract

Rationale: Extremely sharp angular spinal deformity of healed tuberculosis can be corrected by vertebral column resection (VCR). However, the VCR techniques have many limitations including spinal column instability, greater blood loss, and greater risk of neurologic deficit.

Patient concerns: We described a new spinal osteotomy technique to correct sharp angular spinal deformity in Pott disease. A 52-year-old woman presented with back pain and gait imbalance.

Diagnosis: The kyphosis of healed tuberculosis was diagnosed based on history and imaging examinations.

Intervention: A new posterior VCR was designed to treat this disease.

Outcomes: The neurological function improved from Japanese Orthopedic Association scale 3 to 7. The back pain and neurological function were significantly improved. The Oswestry Disability Index decreased from 92 to 34. There was also a significant decrease in back pain visual analog scale from 9 to 2.

Lessons: For cases with extremely severe Pott kyphotic deformity, the technology of modified VCR offers excellent clinical and radiographic results.

Abbreviations: CT = computed tomography, JOA = Japanese Orthopedic Association, mVCR = modified vertebral column resection, ODI = Oswestry Disability Index, VAS = visual analog scale, VCR = vertebral column resection.

Keywords: kyphosis, osteotomy, vertebral column decortication

1. Introduction

Due to modern antituberculous drugs and imaging studies, there is a high rate of disease cure in spinal tuberculosis.^[1] Though complete disease cure may be achieved with chemotherapy, patients treated conservatively have an average increase of 15° in deformity and 3% to 5% of the patients end up with a deformity >60°.^[2] The patients will be present with persistent localized pain, late onset neurological deficit, spinal canal stenosis, pulmonary complications, and cosmetic deformity,^[3] and need surgery to correct the kyphotic deformity and remove spinal cord or nerve compression.

The surgical correction of severe thoracic kyphosis usually requires an osteotomy to realign the spine and long segment fixation for correction and stabilization.^[4] It can be corrected by an anterior instrumented fusion, a combined anterior–posterior procedure or a posterior only procedure.^[5] The vertebral column resection (VCR) techniques, which provides the greatest amount of multiplanar correction, may be the best option for the management of severe angular spinal deformity (more than 60°).^[6] However, the VCR techniques have many limitations including spinal column instability, greater blood loss, and greater risk of neurologic deficit.^[7]

To avoid these shortcomings, we have developed a new spinal modified vertebral column resection (mVCR). The goal of this study was to report the new osteotomy technique to correct kyphosis of healed tuberculosis.

1.1. Consent

Written informed consent was obtained from the patient for publication of this case report and any accompanying images. The study obtained ethics committee approval from the Third Hospital of Shijiazhuang.

2. Clinical presentation

We describe the clinical presentation of 1 case of kyphosis of healed tuberculosis and description of our technique.

A 52-year-old woman presented with back pain and gait imbalance. Neurological examination was hypesthesia below T6,

Editor: N/A.

The authors have no funding and conflicts of interest to disclose.

Department of Spine Surgery, The Third Hospital of Shijiazhuang, Shijiazhuang, China.

* Correspondence: Xian-Ze Sun, Department of Spine Surgery, The Third Hospital of Shijiazhuang, No. 15 Tiyu Street, Shijiazhuang 050000, China (e-mail: sunspine@163.com).

Copyright © 2017 the Author(s). Published by Wolters Kluwer Health, Inc. This is an open access article distributed under the Creative Commons Attribution-NoDerivatives License 4.0, which allows for redistribution, commercial and non-commercial, as long as it is passed along unchanged and in whole, with credit to the author.

Medicine (2017) 96:45(e8592)

Received: 11 September 2017 / Received in final form: 18 October 2017 /

Accepted: 23 October 2017

<http://dx.doi.org/10.1097/MD.0000000000008592>

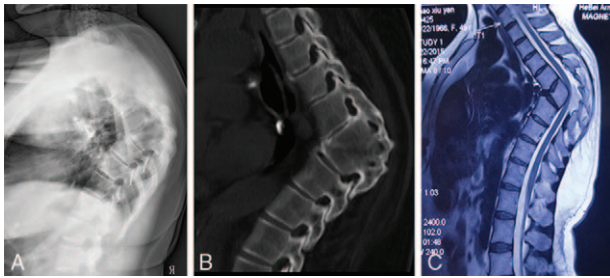


Figure 1. (A) Preoperative standing lateral radiograph showing thoracic kyphosis of 78°. (B) Preoperative computed tomography scans showing the vertebral body of T5–8 were fusion together. (C) Preoperative sagittal T2-weighted magnetic resonance imaging demonstrating draping of the spinal cord over the kyphotic apex.

3/5 strength, and ankle clonus in left lower extremities. Clinical outcome assessment was performed using Oswestry Disability Index (ODI) and visual analog scale (VAS) for back pain. The VAS is 9 and ODI is 92. The neurological function was evaluated by Japanese Orthopedic Association (JOA) scale and the JOA scale is 3. Standing lateral radiograph demonstrate 78° of kyphosis in the thoracic region (measured from T2 to T12). Computed tomography (CT) scans demonstrated that the vertebral of T5–8 are fusion together. Magnetic resonance imaging revealed a T5–8 vertebral dysplasia and spinal cord compressed severely (Fig. 1).

3. Operative techniques

3.1. Pedicle screw fixation

The patient is positioned prone on a radiolucent operating room table. The skin is opened midline, and a subperiosteal dissection is performed to expose the bony structures of the posterior elements. Then the pedicle screws were placed in T1–4 and T9–12. All pedicle screws are inserted via a free hand pedicle screw placement technique (Fig. 2).

3.2. mVCR technique

Prior to any bone removal, a pedicle preparatory hole can be placed at the level of the mVCR, to maintain orientation while the osteotomy is being carried out. C-arm fluoroscopy confirmed

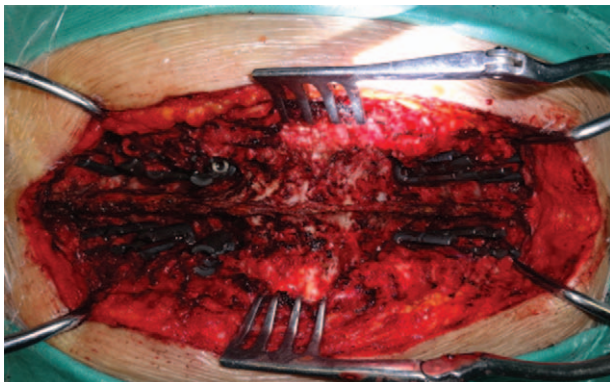


Figure 2. Intraoperative photograph demonstrating pedicle screws are inserted via a free hand pedicle screw placement technique.

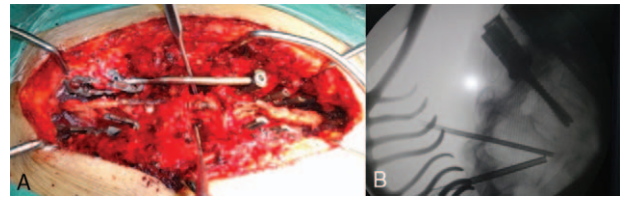


Figure 3. (A) The anterior, lateral, and posterior cortical bone of the vertebral body was resected and the central vertebral body was reserved. (B) Intraoperative C-arm fluoroscopy confirmed the pedicle of T6 and T7.

the pedicle of T6 and T7 (Fig. 3). First, the posterior elements of T5–8, including the spinous processes, and laminae were removed by high-speed drill and Kerrison rongeur. Then the facet joints, transverse process, and corresponding rib head were resected and bilateral nerve roots were ligated and dissected at T6 and T7. A high-speed drill was used to enlarge the pedicle hole from superior border of T6 pedicle to inferior border of T7 pedicle until the corresponding bilateral walls were penetrated, and from bilateral side to anteromedial so that the anterior cortical bone of vertebral body was thinned by drill. An angular forceps or curette was used to remove the residual pedicle bone of T6 and T7. After this, 3 to 5 mm cancellous bone were resected anterior to the posterior vertebral body cortical wall. Finally, the last part of resection is the posterior vertebral body cortical wall or floor of the spinal canal. It is essential in this step to control epidural bleeding with the judicious use of bipolar cauterization and so on. After a ventral epidural tissue plan is established, we prefer to remove the posterior vertebral body wall with the specialized impactor, which is utilized to impale the posterior wall into the ventral defect that has been created. It is imperative that the ventral spinal cord is completely free of any prominences to avoid impingement prior to kyphosis correction. The residual central cancellous bone were reserved as a “bony cage” to take place of metal mesh (Fig. 4).

3.3. Kyphosis correction

After mVCR, we choose the thoracic kyphosis which we wish to correct the spine, and the rods are then bent into the desired

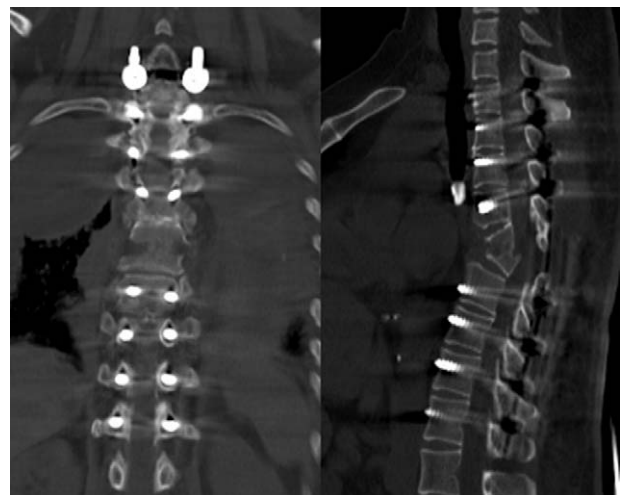


Figure 4. Computed tomography scans postoperatively shows that the residual cancellous bone was reserved as a “bony cage.”

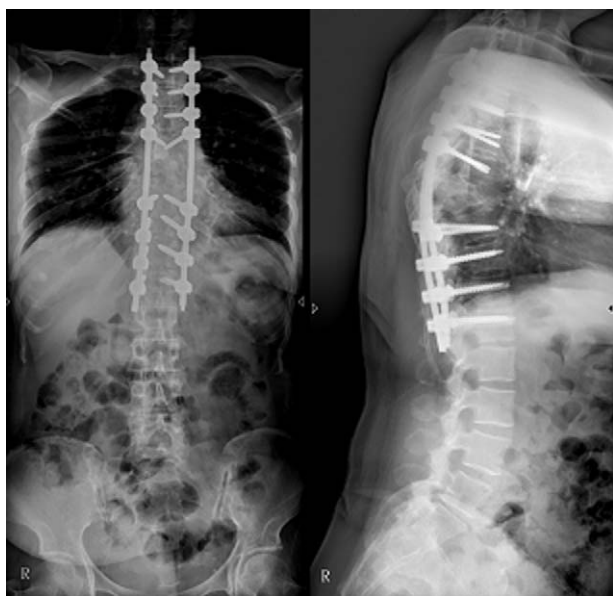

Figure 5. The kyphosis was corrected to 34° immediately after the surgery.

position. Osteoclasis of the anterior vertebral body was achieved by gentle manual close posterior wedge osteotomies, and the hinge of the correction was located at the posterior border of remaining cancellous bone. The degree of correction was controlled by the amount of residual bone. After confirmation of correction via fluoroscopy, final internal fixation was applied.

3.4. Fusion and closure

After thorough irrigation, the facet joint and remaining portions of the laminae were decorticated with a high-speed burr. The

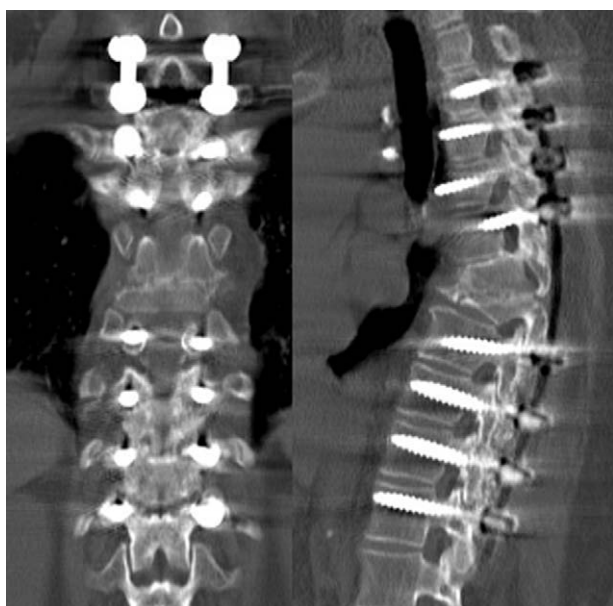

Figure 6. Computed tomography scans 6 months postoperatively show that the correction was maintained and solid fusion of resection site was achieved.

facet surface was burred to promote fusion. The removed spinous processes and laminae are cleaned of soft tissue and milled to be used for local autograft.

3.5. Outcomes

There were no intraoperative or postoperative complications. The back pain and neurological function were significantly improved. The patient's postoperative standing radiographs demonstrated her thoracic kyphosis improved from 78° to 34° (Fig. 5). At 1-month follow-up, the myelopathy and ability to ambulate improved as well. The neurological function improved from JOA scale 3 to 7. The back pain and neurological function were significantly improved. The ODI decreased from 92 to 34. There was also a significant decrease in back pain VAS from 9 to 2. And 6 months' postoperatively CT scans show that the correction was maintained and solid fusion of resection site was achieved (Fig. 6).

4. Discussion

Spinal tuberculosis can cause osteolysis and collapse of the vertebral bodies, which result in sharp angular kyphotic deformity. For this deformity, the lever arm of the center of the gravity line with respect to the wedged vertebra may increase, which leads to the anterior elements of the spine failing under compression and the posterior elements failing under tension. For patients, the risk of deformity, pain, and the potential for neurologic deficit may develop or increase. Therefore, sufficient restoration of alignment may not only result in better fusion, but also in better spinal canal decompression.

Various techniques have been used to describe to correct the kyphotic deformity associated with advanced Pott disease.^[8,9] Traditionally, an smith-petersen osteotomy requires a mobile disc space anteriorly, which is uncommon with rigid sharp angular spinal deformity.^[10] Though a pedicle subtraction osteotomy can be applied to patients with sharp angular kyphosis and anterior column fusion,^[3] the excessive shortening of the area may result in buckling of the dura and spinal cord, which is very dangerous, and authors have recommended limiting the correction to 30 or 40. For severe and rigid kyphoscoliosis, VCR osteotomies can be more effective.^[11] It can provide adequate canal decompression and excellent correction of the sagittal and coronal planes while shortening the length of the spinal column. However, the VCR technique requires complete removal of the deformed vertebrae to allow restoration of alignment and decompression, which endangers the stability of the anterior and medial columns. Also, the anterior column needs to be reconstructed with metal mesh filled with morselized bone after the osteotomy.^[12] The limitations of these techniques undoubtedly increase surgical-related complications, such as spinal instability, in addition to greater blood loss and higher risk of neurologic deficit.^[13]

Based on the previous research and technology, we have developed a new spinal osteotomy defined as mVCR. In our technique, the basic techniques were similar to those in the kyphosis correction. The difference was that the surrounding cortical bone and a little of cancellous of the deformed vertebrae were removed, and the central cancellous bone was retained. With the residual bone as a fulcrum, through posterior fixed pressure, the kyphosis was corrected. Compared with the traditional VCR, the correction procedure was more slowly and the risk of neurologic and spinal cord deficit was reduced. Furthermore, most cancellous bone were retained and the hemorrhage was more less. Rather than titanium mesh cage,

the 2 osteotomy planes were connected by vertebral body with the expectation of better bony fusion and better stability. It was confirmed by CT examination after 6 months follow-up.

5. Conclusion

For cases with extremely severe Pott kyphotic deformity, the technology of mVCR offers excellent clinical and radiographic results. However, long-term studies will be needed to prove the durability of the operation.

References

- [1] Moon MS. Tuberculosis of the spine, controversies and a new challenge. *Spine (Phila Pa 1976)* 1997;22:1791–7.
- [2] Tuli SM. Severe kyphotic deformity in tuberculosis of the spine. *Int Orthop* 1995;19:327–31.
- [3] Cheung WY, Luk KDK. Clinical and radiological outcomes after conservative treatment of TB spondylitis: is the 15 years' follow-up in the MRC study long enough? *Eur Spine J* 2013;22(suppl 4):S594–602.
- [4] Rajasekaran S, Rishi Mugesh Kanna P, Shetty AP. Closing-opening wedge osteotomy for severe, rigid, thoracolumbar post-tubercular kyphosis. *Eur Spine J* 2011;20:343–8.
- [5] Bradford DS, Tribus CB. Vertebral column resection for the treatment of rigid coronal decompensation. *Spine* 1997;22:1590–9.
- [6] Boachie-Adjei O, Papadopoulos EC, Pellisé F, et al. Late treatment of tuberculosis-associated kyphosis: literature review and experience from a SRS-GOP site. *Eur Spine J* 2013;22(suppl 4):S641–6.
- [7] Bridwell K. Decision making regarding Smith-Petersen vs. pedicle subtraction osteotomy vs. vertebral column resection for spinal deformity. *Spine* 2006;31:S171–8.
- [8] Charles YP, Schuller S. Vertebral column resection for thoracic hyperkyphosis in Pott's disease. *Eur Spine J* 2014;23:708–10.
- [9] Wang Y, Zhang Y, Zhang X, et al. Posterior-only multilevel modified vertebral column resection for extremely severe Pott's kyphotic deformity. *Eur Spine J* 2009;8:1436–42.
- [10] Boachie-Adjei O, Ferguson JI, Pigeon RG, et al. Transpedicular lumbar wedge resection osteotomy for fixed sagittal imbalance: surgical technique and early results. *Spine* 2014;31:485–92.
- [11] White AAIII, Panjabi MM. *Practical Biomechanics of Scoliosis and Kyphosis: Clinical Biomechanics of the Spine*. 2nd ed. 1990; JB Lippincott, Philadelphia, PA:pp. 127–168.
- [12] Pappou IP, Papadopoulos EC, Swanson AN, et al. Pott's disease in the thoracolumbar spine with marked kyphosis and progressive paraplegia necessitating posterior vertebral column resection and anterior reconstruction with a cage. *Spine* 2006;31:E123–7.
- [13] Wang Y, Lenke LG. Vertebral column decancellation for the management of sharp angular spinal deformity. *Eur Spine J* 2011;20:1703–10.