

Ultrasonographic findings of type IIIa biliary atresia

Seung-seob Kim, Myung-Joon Kim, Mi-Jung Lee, Choon-Sik Yoon, Seok Joo Han, Hong Koh

Department of Radiology, Research Institute of Radiological Science, Severance Hospital, Yonsei University College of Medicine, Seoul, Korea

ULTRASONOGRAPHY

ORIGINAL ARTICLE

<http://dx.doi.org/10.14366/usg.14016>
pISSN: 2288-5919 • eISSN: 2288-5943
Ultrasonography 2014;33:267-274

Purpose: To describe the ultrasonographic (US) findings of type IIIa biliary atresia.

Methods: We retrospectively reviewed a medical database of patients pathologically confirmed to have biliary atresia, Kasai type IIIa, between January 2002 and May 2013 (n=18). We evaluated US findings including the visible common bile duct (CBD), triangular cord thickness, gallbladder size and shape, and subcapsular flow on color Doppler US; laboratory data; and pathological hepatic fibrosis grades. We divided them into two groups—those with visible (group A) and invisible (group B) CBD on US—and compared all parameters between the two groups.

Results: CBD was visible on US in five cases (27.8%; group A) and invisible in 13 cases (72.2%; group B). US was performed at an earlier age in group A than in group B (median, 27 days vs. 60 days; P=0.027) with the maximal age of 51 days. A comparison of the US findings revealed that the triangular cord thickness was smaller (4.1 mm vs. 4.9 mm; P=0.004) and the gallbladder length was larger (20.0 mm vs. 11.7 mm; P=0.021) in group A. The gallbladder shape did not differ between the two groups, and the subcapsular flow was positive in all cases of both groups. There was no significant difference in the laboratory data between the two groups. Upon pathological analysis, group A showed low-grade and group B showed low- to high-grade hepatic fibrosis.

Conclusion: When CBD is visible on US in patients diagnosed with type IIIa biliary atresia, other US features could have a false negative status. A subcapsular flow on the color Doppler US would be noted in the type IIIa biliary atresia patients.

Keywords: Biliary atresia; Ultrasonography; Common bile duct

Received: March 24, 2014

Revised: May 2, 2014

Accepted: June 10, 2014

Correspondence to:

Myung-Joon Kim, MD, Department of Radiology, Research Institute of Radiological Science, Severance Hospital, Yonsei University College of Medicine, 50 Yonsei-ro, Seodaemun-gu, Seoul 120-752, Korea

Tel. +82-2-2228-7400

Fax. +82-2-393-3035

E-mail: mjkim@yuhs.ac

This is an Open Access article distributed under the terms of the Creative Commons Attribution Non-Commercial License (<http://creativecommons.org/licenses/by-nc/3.0/>) which permits unrestricted non-commercial use, distribution, and reproduction in any medium, provided the original work is properly cited.

Copyright © 2014 Korean Society of Ultrasound in Medicine (KSUM)

Introduction

Neonatal cholestasis has a variety of underlying causes. However, the two major causes accounting for 60%–90% of all neonatal cholestasis are neonatal hepatitis and biliary atresia [1]. Discrimination between these two entities is very important, since they require completely different treatment approaches—medical treatment for hepatitis and surgery for biliary atresia.

Among the three Kasai types of biliary atresia, type III (porta hepatis obstruction) is the most common—accounting for more than 90% of all biliary atresia patients, and has the worst prognosis [2–4]. The concept that a younger age at the diagnosis of and surgery for biliary atresia leads to



How to cite this article:

Kim SS, Kim MJ, Lee MJ, Yoon CS, Han SJ, Koh H. Ultrasonographic findings of type IIIa biliary atresia. *Ultrasonography*. 2014 Oct;33(4):267-274.

a better outcome has been generally accepted [1,5–14], while some of the published data have revealed that patient age has no significance or sometimes even a negative effect on the prognosis [15,16]. However, when it comes to type III biliary atresia, the negative effect of older age seems more obvious [9].

Among non-invasive imaging tools, it is well known that ultrasonography (US) has the highest diagnostic accuracy, which makes it possible to avoid unnecessary invasive procedures in many cases [1,17,18]. Further, many previous studies have reported several US findings to diagnose biliary atresia, including a triangular cord sign, abnormal gallbladder length and shape, invisible common bile duct (CBD), and subcapsular flow on color Doppler US [1,18–32]. However, some patients show equivocal US findings, requiring additional invasive diagnostic methods or leading to a delayed diagnosis. In particular, while visible CBD on US is generally regarded as a finding suggestive of the disease other than biliary atresia, it can be a possible finding of Kasai subtype IIIa (patent distal CBD) biliary atresia. Further, there have been only a few reports on the US findings of biliary atresia based on its types [33,34]. Therefore, the purpose of this study was to determine the US features of type IIIa biliary atresia.

Materials and Methods

Patients

The Institutional Review Board approved this retrospective study and waived the requirement of written informed consent from all patients.

We retrospectively collected data on patients who were confirmed as having biliary atresia by surgical pathology between January 2002 and May 2013. Further, one pediatric radiologist (MJK) reviewed the operative cholecystocholangiography performed in these patients, analyzed the Kasai type of biliary atresia, and selected type IIIa. A total of 18 patients (10 boys and 8 girls) were diagnosed with Kasai type IIIa biliary atresia. We reviewed their US findings along with the laboratory and pathological data. Patient ages at the US examination were recorded.

Ultrasonography

In our institution, all patients with neonatal cholestasis undergo US without being fed for at least 4 hours. A visualization of the CBD is recorded, and the triangular cord thickness is measured as the thickness of the echogenic anterior wall of the right portal vein just proximal to the right portal vein bifurcation site [26]. The maximal gallbladder length is measured, and the gallbladder shape is evaluated using a high-frequency transducer. When considering the gallbladder shape, a discontinuous or absent mucosal lining,

an indistinct wall, and an irregular outer margin are regarded as abnormal. On color Doppler US, a hepatic subcapsular flow is evaluated using the color box (height, 1 cm; width, 3–4 cm) positioned on the anterior surface around the falciform ligament [23]. In some patients, whether normal gallbladder contraction occurs after an oral feeding is also evaluated.

Images and Data Review

US findings of invisible CBD, triangular cord thickness of more than 4 mm, gallbladder length of less than 15 mm, abnormal gallbladder shape, and subcapsular flow on color Doppler US are regarded as the diagnostic criteria of biliary atresia. We retrospectively reviewed and recorded these US findings.

Laboratory data at the time of US were reviewed including total and direct serum bilirubin levels, aspartate transaminase (AST), alanine transaminase (ALT), gamma-glutamyl transpeptidase (γ -GT), and alkaline phosphatase (ALP).

Liver wedge biopsy specimens were routinely obtained from all the patients at the time of operation. Further, the liver fibrosis grades were determined according to the Metavir scoring system as follows: F0, no fibrosis; F1, portal fibrosis without septa; F2, portal fibrosis and few septa; F3, numerous septa without cirrhosis; F4, cirrhosis [35,36].

Statistical Analyses

We divided the patients into two groups on the basis of the US finding of CBD—those with visible CBD (group A) and those with invisible CBD (group B). All the parameters were compared between these two groups.

Categorical parameters such as sex, gallbladder shape on US, and subcapsular flow on color Doppler US were compared using a Fisher exact test. A Mann-Whitney U test was used to compare the continuous variables. Liver fibrosis grades were compared using Pearson chi-squared test. Statistical analyses were performed using the IBM SPSS ver. 20 (IBM Co., Armonk, NY, USA).

Results

US was performed at the age of 11–100 days with a median of 50 days in the 18 patients with Kasai type IIIa biliary atresia. CBD was visible on US in five cases (27.8%; group A) and invisible in 13 cases (72.2%; group B). There were four boys and one girl in group A and six boys and seven girls in group B without any difference between the two groups ($P=0.314$). US was performed at an earlier age in group A than in group B (median, 27 days vs. 60 days; $P=0.027$) with the maximal age of 51 days (Table 1).

Representative images of US and operative cholangiogram are

illustrated in Fig. 1 for group A patients and Fig. 2 for group B patients. On the US findings, the triangular cord thickness was significantly smaller in group A than in group B (median, 4.1 mm vs. 4.9 mm; $P=0.004$). When considering the cut-off value of the triangular cord sign to be 4 mm [26], two patients (2/5, 40%) showed a negative triangular cord sign in group A, and all patients showed a positive triangular cord sign in group B.

The gallbladder length was larger in group A than that in group B (median, 20.0 mm vs. 11.7 mm; $P=0.021$). When we use the cut-off value of an atretic gallbladder as 15 mm in length [22], all five patients (5/5, 100%) in group A and three patients (3/13, 23%) in group B were false negative.

With respect to the gallbladder shape, four cases had a normal gallbladder, and only one (1/5, 20%) demonstrated a discontinuous mucosal lining in group A. In group B, five cases (5/13, 38%) showed an abnormal gallbladder with a discontinuous or absent mucosal lining including one case combined with an indistinct wall. All gallbladders revealed a smooth outer margin in both groups.

However, the gallbladder shape was not significantly different between the two groups ($P=0.615$).

Three patients in group A and one patient in group B showed normal gallbladder contraction after an oral feeding, while whether the gallbladder contracted normally after an oral feeding was not evaluated in the remaining 14 patients (not shown in the tables).

On color Doppler US, all patients demonstrated a positive subcapsular flow in both groups.

Laboratory and pathological data in the two groups are also summarized in Table 1. The application of the upper normal limit values used in our institution (total bilirubin, 0.8 mg/dL; direct bilirubin, 0.4 mg/dL; γ -GT, 54.0 IU/L; and alkaline phosphatase, 341 IU/L) increased the total bilirubin, direct bilirubin, and γ -GT in all patients of both groups and increased alkaline phosphatase in three patients of group A and ten patients of group B. None of the laboratory data were significantly different between the two groups. In the pathological analysis of liver fibrosis, there were one case of F1 and four cases of F2 in group A, while there were nine cases

Table 1. Comparison between group A (visible CBD) and group B (invisible CBD) of clinical data, ultrasonographic findings, laboratory findings, and pathological results

Variable	Group A (n=5)	Group B (n=13)	P-value ^{a)}
Clinical data			
Sex (male: female)	4:1	6:7	0.314
Age (day)	27 (11–51)	60 (22–100)	0.027
Ultrasonographic findings			
Triangular cord thickness (mm)	4.1 (3.4–4.1)	4.9 (4.0–7.3)	0.004
Gallbladder length (mm)	20.0 (16.5–23.8)	11.7 (7.2–28.6)	0.021
Gallbladder mucosal lining: discontinuous/absent	1 (20)	5 (38.5)	0.615
Gallbladder wall: indistinct	0	1 (7.7)	>0.999
Gallbladder outer margin: irregular	0	0	–
Positive subcapsular flow	5 (100)	13 (100)	–
Laboratory data			
Total bilirubin (mg/dL)	8.7 (4.8–9.6)	7.7 (3.8–18.2)	0.805
Direct bilirubin (mg/dL)	6.2 (3.3–7.4)	6.3 (2.9–14.7)	0.430
Aspartate transaminase (IU/L)	57 (49–158)	149 (41–445)	0.084
Alanine transaminase (IU/L)	37 (34–101)	131 (11–360)	0.104
γ -glutamyl transpeptidase (IU/L)	270 (109–938)	282 (102–1,055)	0.730
Alkaline phosphatase (IU/L)	353 (232–505)	490 (298–1,001)	0.218
Pathological data (liver fibrosis grades)			
F1	1 (20.0)	0	
F2	4 (80.0)	9 (69.2)	
F3	0	2 (15.4)	
F4	0	2 (15.4)	

Values are presented as number (%) or median (minimum–maximum value).

CBD, common bile duct.

^{a)}P-values from Mann-Whitney U test for numerical variables and Fisher exact test for categorical variables except for liver fibrosis grades using Pearson chi-squared test.

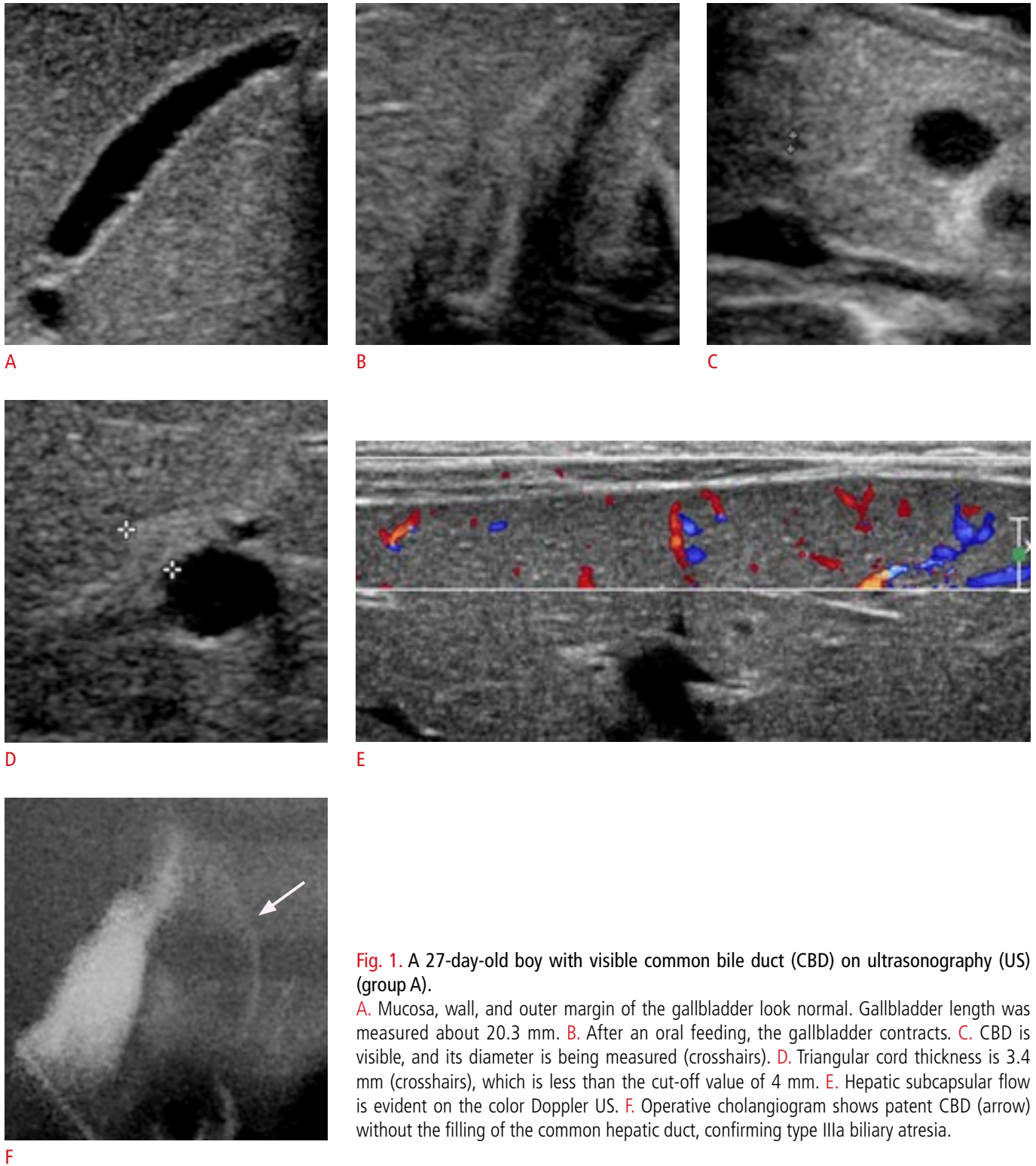


Fig. 1. A 27-day-old boy with visible common bile duct (CBD) on ultrasonography (US) (group A).

A. Mucosa, wall, and outer margin of the gallbladder look normal. Gallbladder length was measured about 20.3 mm. **B.** After an oral feeding, the gallbladder contracts. **C.** CBD is visible, and its diameter is being measured (crosshairs). **D.** Triangular cord thickness is 3.4 mm (crosshairs), which is less than the cut-off value of 4 mm. **E.** Hepatic subcapsular flow is evident on the color Doppler US. **F.** Operative cholangiogram shows patent CBD (arrow) without the filling of the common hepatic duct, confirming type IIIa biliary atresia.

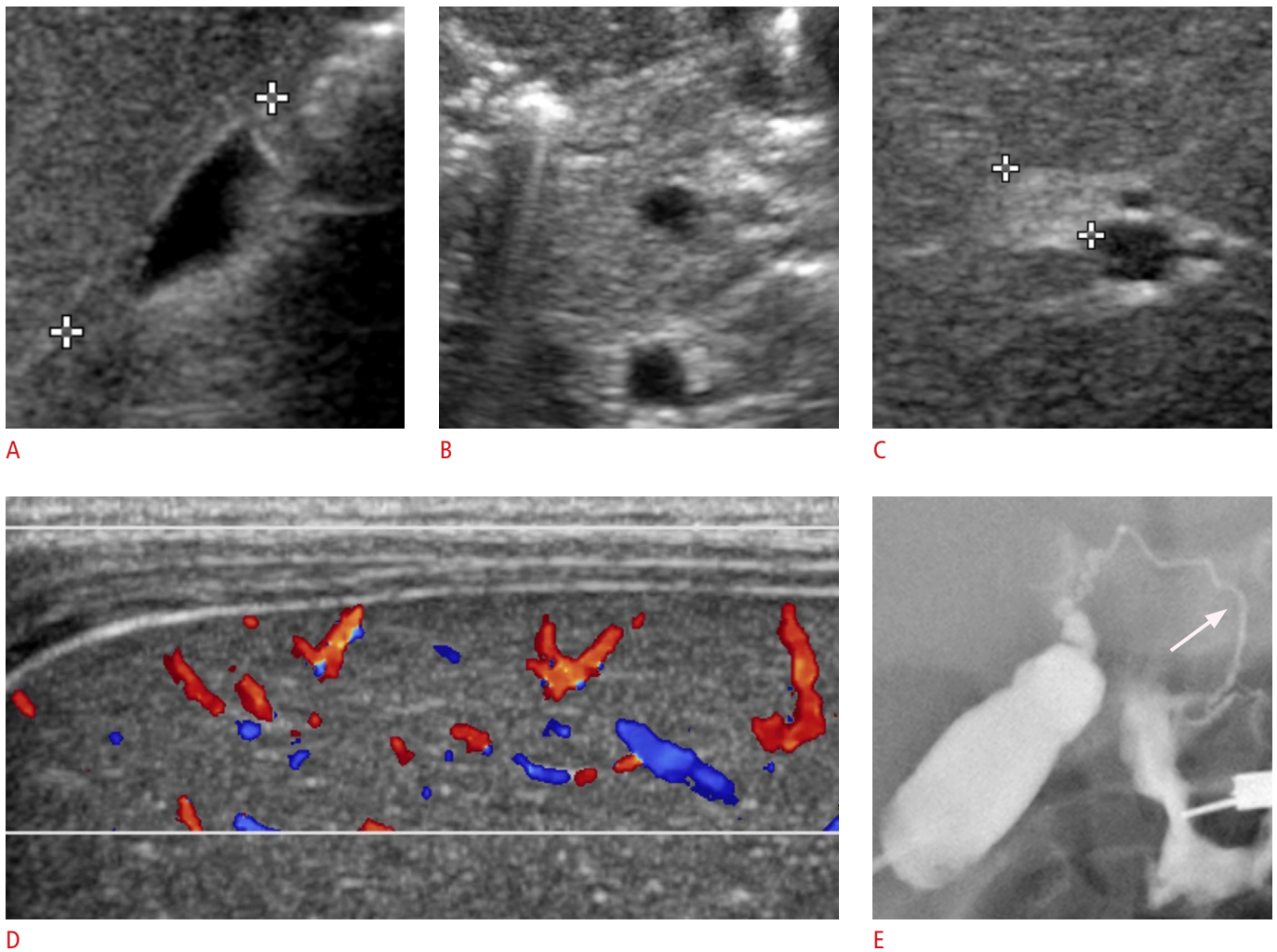


Fig. 2. A 49-day-old boy with invisible common bile duct (CBD) on ultrasonography (US) (group B). **A.** Gallbladder length is 12.8 mm (crosshairs). The mucosal lining and the outer margin of the gallbladder are relatively smooth with a distinct wall. Postprandial gallbladder evaluation was not done. **B.** CBD is invisible in the pancreatic head portion. **C.** Triangular cord thickness is 5.3 mm (crosshairs), which is larger than the cut-off value of 4 mm. **D.** Hepatic subcapsular flow is evident on the color Doppler US. **E.** Operative cholangiogram shows a patent CBD (arrow) without a visible common hepatic duct, confirming type IIIa biliary atresia.

of F2, two cases of F3, and two cases of F4 in group B, showing a greater tendency toward the advanced grades of liver fibrosis in group B. However, this distinction was not statistically significant ($P=0.246$).

Discussion

There have been many studies on the diagnostic US findings of biliary atresia. Tan Kendrick et al. [27] suggested a "gallbladder ghost triad" for the diagnostic US findings of biliary atresia—gallbladder length of <19 mm, indistinct gallbladder wall with a lack of a smooth or complete echogenic mucosal lining, and an irregular or lobular outer contour. Azuma et al. [21] reported that the absence

of an extrahepatic bile duct on the US exam can further increase the diagnostic accuracy of biliary atresia. Both the triangular cord sign and the hepatic subcapsular flow are also known as one of the diagnostic US findings of biliary atresia [19,23]. However, not all these US findings are always present in patients with biliary atresia.

Mittal et al. [1] stated that CBD can potentially be visible on US in certain types of biliary atresia with distal CBD sparing. According to the proposal by Kasai et al. [37], biliary atresia with a porta hepatis obstruction and patent distal CBD is classified into type IIIa. Therefore, patients with type IIIa biliary atresia might show visible CBD on US.

There have been only a few reports on the US findings of biliary atresia on the basis of its types [33,34]. Further, no study has

compared the US findings, including the visibility of CBD on US.

Among the 18 patients with type IIIa biliary atresia, CBD was not visible in 13 patients even though patent CBD was confirmed on operative cholangiography. In our study, one patient showed visible CBD at the age of 11 days and was included in group A. However, follow-up US, which was not included in this study, was performed 10 days later, and revealed that CBD was not visible. Therefore, one possible explanation for the invisible CBD is that the CBD started being affected by the disease process to become too small to be seen on US, and still insufficient to cause complete luminal obstruction. Another possible explanation is the decreased bile flow from the liver caused by the progression of the porta hepatis obstruction. This decreased bile flow subsequently causes the luminal collapse of CBD, making it difficult to be identified on US.

The triangular cord sign is defined as the triangular cord thickness of more than 4 mm [26] and has been proven to be highly specific for the diagnosis of biliary atresia by many other authors [1,17,18,22,24–26,29]. In contrast, the sensitivity of the triangular cord sign has been reported to vary from 14% to 100% [1,17,22,24–26,29]. Li et al. [28] suggested the following three possible explanations for a negative triangular cord sign and its low sensitivity: (1) no triangular cord at the porta hepatis, (2) triangular cord at the porta hepatis, but too small to be seen, and (3) insufficient experience of the US operator. In addition, Saxena et al. [38] pointed out that the triangular cord sign may initially be negative if the patient is very young and possibly become positive later. He reached this conclusion from the observation of a 22-day-old patient who showed a negative triangular cord sign at the initial US and then developed a positive triangular cord sign 2 weeks later.

In our study, group A showed a significantly smaller triangular cord thickness than group B, and two patients (2/5, 40%) in group A had a negative triangular cord sign, while all patients in group B had a positive triangular cord sign. This may be related to the suggestion of Saxena et al. [38] since the patient age at the time of US was significantly lower in group A than in group B. In particular, the two patients with a negative triangular cord sign were of the age of 20 days and 27 days, respectively, at the time of US, and were considerably younger than the others with a positive triangular cord sign.

According to Tan Kendrick et al. [27], all three findings of the "gallbladder ghost triad" were constantly positive in 97% of the infants with biliary atresia and showed no false positives. Recently, several studies have also demonstrated that the small size and the abnormal morphology of the gallbladder on US were useful in distinguishing biliary atresia from neonatal hepatitis [1,18,30–32]. According to our results, the gallbladder length was significantly greater in group A than in group B. The use of the cut-off value of

the atretic gallbladder of 15 mm (length) [22] revealed that all five patients (5/5, 100%) in group A and three patients (3/13, 23%) in group B were false negative. The evaluation of the gallbladder shape was helpful in only one patient (1/5, 20%) of group A and five patients (5/13, 38%) of group B. These results are quite inconsistent with those of the previous studies on the US features of the gallbladder, particularly in group A. One possible explanation is that the gallbladder length and shape might be within normal limits at an early stage of the disease and become affected as the disease progresses, considering the progressive nature of biliary atresia and the younger age of group A.

If the gallbladder contracts after an oral feeding, biliary atresia is generally considered unlikely [1,39]. However, several authors have already reported that normal gallbladder contraction was seen after an oral feeding in patients with type IIIa biliary atresia [33,34]. In our study, three patients in group A and one patient in group B showed normal gallbladder contraction after an oral feeding. In the remaining 14 patients, whether the gallbladder contracted normally after an oral feeding was not evaluated.

Lee et al. [23] defined a hepatic subcapsular flow as a hepatic arterial flow signal continuing to the liver capsular surface on color Doppler US and suggested it to be a diagnostic US finding of biliary atresia with high sensitivity (100%) and relatively low specificity (86%). Recently, El-Guindi et al. [29] supported their findings with a sensitivity of 96.3% and a specificity of 96.3%. In our study, the subcapsular flow was positive in all patients of both groups and was the only finding suggestive of biliary atresia in one patient of group A. Therefore, a hepatic subcapsular flow can be used to predict biliary atresia even when CBD is visible on US. Furthermore, when a hepatic subcapsular flow is not evident, the possibility of biliary atresia might be greatly lowered.

It is well known that conjugated hyperbilirubinemia cannot reliably discriminate between biliary atresia and neonatal hepatitis [40]. Total bilirubin, direct bilirubin, and γ -GT were increased in all patients of both groups, and alkaline phosphatase was increased in three patients of group A and ten patients of group B. However, laboratory data in our study were not statistically different between the two groups.

Although pathological liver fibrosis grades were not statistically different between the two groups, a tendency towards the advanced grades of liver fibrosis was noted in group B. This result is consistent with the progressive nature of biliary atresia in causing hepatic fibrosis, liver cirrhosis, and eventual liver failure sequentially unless appropriate treatment is given [2].

Several limitations of our study should be acknowledged. First, the sample size was small, and the sample distribution was uneven (group A: n=5 vs. group B: n=13), lowering the reliability of our

data. Further studies with larger samples are needed to support our results. Second, since it was retrospective study, the pathological correlation of the gallbladder and the CBD with their US findings could not be established. In order to understand the exact underlying mechanisms of the abnormal gallbladder morphology and the visibility of the CBD on the US, a correlation between the US images and the pathological results should be established in the future.

In conclusion, CBD can be either visible or invisible on US in patients diagnosed with type IIIa biliary atresia. When CBD was visible, other US features with respect to the triangular cord thickness and the gallbladder length and shape tended to more often show false negative results than when it was invisible. As the subcapsular flow on the color Doppler US was always noted in patients diagnosed with biliary atresia, Kasai type IIIa, a color Doppler study should be included in the routine US examination of neonatal cholestasis patients.

ORCID: Seung-seob Kim: <http://orcid.org/0000-0001-6071-306X>; Myung-Joon Kim: <http://orcid.org/0000-0002-4608-0275>; Mi-Jung Lee: <http://orcid.org/0000-0003-3244-9171>; Choon-Sik Yoon: <http://orcid.org/0000-0003-2010-6710>; Seok Joo Han: <http://orcid.org/0000-0001-5224-1437>; Hong Koh: <http://orcid.org/0000-0002-3660-7483>

Conflict of Interest

No potential conflict of interest relevant to this article was reported.

Acknowledgments

This study was supported in part by the Research Fund of the Korean Society of Ultrasound in Medicine.

References

- Mittal V, Saxena AK, Sodhi KS, Thapa BR, Rao KL, Das A, et al. Role of abdominal sonography in the preoperative diagnosis of extrahepatic biliary atresia in infants younger than 90 days. *AJR Am J Roentgenol* 2011;196:W438-W445.
- Nakamura K, Tanoue A. Etiology of biliary atresia as a developmental anomaly: recent advances. *J Hepatobiliary Pancreat Sci* 2013;20:459-464.
- Nio M, Ohi R, Miyano T, Saeki M, Shiraki K, Tanaka K, et al. Five- and 10-year survival rates after surgery for biliary atresia: a report from the Japanese Biliary Atresia Registry. *J Pediatr Surg* 2003;38:997-1000.
- Pinter AB, Farkas A, Par A, Kovesi T, Appelschoffer S. A long-term follow-up of five patients with atresia of the common bile duct. *J Pediatr Surg* 2004;39:1050-1054.
- Baumann U, Ure B. Biliary atresia. *Clin Res Hepatol Gastroenterol* 2012;36:257-259.
- Kasai M, Ohi R. Long-term follow-up results of patients with biliary atresia. *Indian J Pediatr* 1983;50:209-217.
- Ohi R. Surgery for biliary atresia. *Liver* 2001;21:175-182.
- Serinet MO, Wildhaber BE, Broue P, Lachaux A, Sarles J, Jacquemin E, et al. Impact of age at Kasai operation on its results in late childhood and adolescence: a rational basis for biliary atresia screening. *Pediatrics* 2009;123:1280-1286.
- Superina R, Magee JC, Brandt ML, Healey PJ, Tiao G, Ryckman F, et al. The anatomic pattern of biliary atresia identified at time of Kasai hepatoportoenterostomy and early postoperative clearance of jaundice are significant predictors of transplant-free survival. *Ann Surg* 2011;254:577-585.
- Lykavieris P, Chardot C, Sokhn M, Gauthier F, Valayer J, Bernard O. Outcome in adulthood of biliary atresia: a study of 63 patients who survived for over 20 years with their native liver. *Hepatology* 2005;41:366-371.
- Mieli-Vergani G, Howard ER, Portman B, Mowat AP. Late referral for biliary atresia: missed opportunities for effective surgery. *Lancet* 1989;1:421-423.
- Ohi R, Nio M, Chiba T, Endo N, Goto M, Ibrahim M. Long-term follow-up after surgery for patients with biliary atresia. *J Pediatr Surg* 1990;25:442-445.
- Serinet MO, Broue P, Jacquemin E, Lachaux A, Sarles J, Gottrand F, et al. Management of patients with biliary atresia in France: results of a decentralized policy 1986-2002. *Hepatology* 2006;44:75-84.
- Hung PY, Chen CC, Chen WJ, Lai HS, Hsu WM, Lee PH, et al. Long-term prognosis of patients with biliary atresia: a 25 year summary. *J Pediatr Gastroenterol Nutr* 2006;42:190-195.
- Davenport M, De Ville de Goyet J, Stringer MD, Mieli-Vergani G, Kelly DA, McClean P, et al. Seamless management of biliary atresia in England and Wales (1999-2002). *Lancet* 2004;363:1354-1357.
- Ibrahim M, Miyano T, Ohi R, Saeki M, Shiraki K, Tanaka K, et al. Japanese Biliary Atresia Registry, 1989 to 1994. *Tohoku J Exp Med* 1997;181:85-95.
- Humphrey TM, Stringer MD. Biliary atresia: US diagnosis. *Radiology* 2007;244:845-851.
- Jiang LP, Chen YC, Ding L, Liu XL, Li KY, Huang DZ, et al. The diagnostic value of high-frequency ultrasonography in biliary atresia. *Hepatobiliary Pancreat Dis Int* 2013;12:415-422.
- Choi SO, Park WH, Lee HJ, Woo SK. 'Triangular cord': a sonographic finding applicable in the diagnosis of biliary atresia. *J Pediatr Surg* 1996;31:363-366.
- Farrant P, Meire HB, Mieli-Vergani G. Ultrasound features of the gall bladder in infants presenting with conjugated hyperbilirubinaemia. *Br J Radiol* 2000;73:1154-1158.
- Azuma T, Nakamura T, Nakahira M, Harumoto K, Nakaoka T, Moriuchi T. Pre-operative ultrasonographic diagnosis of biliary atresia: with reference to the presence or absence of the

- extrahepatic bile duct. *Pediatr Surg Int* 2003;19:475-477.
22. Kanegawa K, Akasaka Y, Kitamura E, Nishiyama S, Muraji T, Nishijima E, et al. Sonographic diagnosis of biliary atresia in pediatric patients using the "triangular cord" sign versus gallbladder length and contraction. *AJR Am J Roentgenol* 2003;181:1387-1390.
 23. Lee MS, Kim MJ, Lee MJ, Yoon CS, Han SJ, Oh JT, et al. Biliary atresia: color Doppler US findings in neonates and infants. *Radiology* 2009;252:282-289.
 24. Park WH, Choi SO, Lee HJ. The ultrasonographic 'triangular cord' coupled with gallbladder images in the diagnostic prediction of biliary atresia from infantile intrahepatic cholestasis. *J Pediatr Surg* 1999;34:1706-1710.
 25. Kotb MA, Kotb A, Sheba MF, El Koofy NM, El-Karakasy HM, Abdel-Kahlik MK, et al. Evaluation of the triangular cord sign in the diagnosis of biliary atresia. *Pediatrics* 2001;108:416-420.
 26. Lee HJ, Lee SM, Park WH, Choi SO. Objective criteria of triangular cord sign in biliary atresia on US scans. *Radiology* 2003;229:395-400.
 27. Tan Kendrick AP, Phua KB, Ooi BC, Tan CE. Biliary atresia: making the diagnosis by the gallbladder ghost triad. *Pediatr Radiol* 2003;33:311-315.
 28. Li SX, Zhang Y, Sun M, Shi B, Xu ZY, Huang Y, et al. Ultrasonic diagnosis of biliary atresia: a retrospective analysis of 20 patients. *World J Gastroenterol* 2008;14:3579-3582.
 29. El-Guindi MA, Sira MM, Konsowa HA, El-Abd OL, Salem TA. Value of hepatic subcapsular flow by color Doppler ultrasonography in the diagnosis of biliary atresia. *J Gastroenterol Hepatol* 2013;28:867-872.
 30. Sun Y, Zheng S, Qian Q. Ultrasonographic evaluation in the differential diagnosis of biliary atresia and infantile hepatitis syndrome. *Pediatr Surg Int* 2011;27:675-679.
 31. Iorio R, Liccardo D, Di Dato F, Puoti MG, Spagnuolo MI, Alberti D, et al. Ultrasound scanning in infants with biliary atresia: the different implications of biliary tract features and liver echostructure. *Ultraschall Med* 2013;34:463-467.
 32. Aziz S, Wild Y, Rosenthal P, Goldstein RB. Pseudo gallbladder sign in biliary atresia: an imaging pitfall. *Pediatr Radiol* 2011;41:620-626.
 33. Ikeda S, Sera Y, Ohshiro H, Uchino S, Akizuki M, Kondo Y. Gallbladder contraction in biliary atresia: a pitfall of ultrasound diagnosis. *Pediatr Radiol* 1998;28:451-453.
 34. Weinberger E, Blumhagen JD, Odell JM. Gallbladder contraction in biliary atresia. *AJR Am J Roentgenol* 1987;149:401-402.
 35. Bedossa P, Poynard T. An algorithm for the grading of activity in chronic hepatitis C. The METAVIR Cooperative Study Group. *Hepatology* 1996;24:289-293.
 36. Kim SY, Seok JY, Han SJ, Koh H. Assessment of liver fibrosis and cirrhosis by aspartate aminotransferase-to-platelet ratio index in children with biliary atresia. *J Pediatr Gastroenterol Nutr* 2010;51:198-202.
 37. Kasai M, Sawaguchi S, Akiyama H, Saito S, Suruga K, Yura J, et al. A proposal of new classification of biliary atresia. *J Jpn Soc Pediatr Surg* 1976;12:327-331.
 38. Saxena AK, Mittal V, Sodhi KS. Triangular cord sign in biliary atresia: does it have prognostic and medicolegal significance? *Radiology* 2012;263:621-622.
 39. Green D, Carroll BA. Ultrasonography in the jaundiced infant: a new approach. *J Ultrasound Med* 1986;5:323-329.
 40. Sun S, Chen G, Zheng S, Xiao X, Xu M, Yu H, et al. Analysis of clinical parameters that contribute to the misdiagnosis of biliary atresia. *J Pediatr Surg* 2013;48:1490-1494.