

Clinical relevance of expression of B7-H1 and B7-H4 in ovarian cancer

MEI XU^{1*}, BEI ZHANG^{1*}, MENG ZHANG¹, YANG LIU¹, FENG-LING YIN¹, XIA LIU² and SHI-CHAO ZHUO²

Departments of ¹Obstetrics and Gynecology, and ²Pathology,
Central Hospital of Xuzhou, Xuzhou, Jiangsu 221009, P.R. China

Received January 26, 2016; Accepted March 2, 2016

DOI: 10.3892/ol.2016.4301

Abstract. The aim of the present study was to investigate the expression of B7-H1 and B7-H4 in ovarian neoplasm tissues and to examine their clinical relevance. A total of 112 ovarian biopsies were collected from patients with epithelial ovarian cancer (EOC) and 10 were taken from ovarian benign neoplasms. The samples were processed in paraffin tissue chips, and subjected to immunohistochemical staining and analysis. Associations of B7-H1 and B7-H4 expression with patients' clinical parameters, such as histological typing, cell grading, International Federation of Gynecology and Obstetrics staging, tumor size, and metastatic status, were examined by statistical analysis. Survival curves were constructed using the Kaplan-Meier method and the log-rank test. Independent prognostic factors were evaluated using the Cox regression model. The results showed an extremely low or negative expression of B7-H1 and B7-H4 in the 10 benign ovarian neoplasm tissues (control): By contrast, a positive expression of B7-H1 and B7-H4 was observed in 55.4% (62/112) and 37.5% (42/112) of the EOC tissues, respectively. The differences between the two groups were significant. In addition, the co-expression of B7-H1 and B7-H4 was found in 31.3% (35/112) of the EOC cases. Furthermore, the progression-free survival and overall survival were significantly lower in EOC patients with a high expression of B7-H1 and B7-H4 ($\chi^2=45.60$ and 37.99 , respectively). These results demonstrated that the expression of B7-H1 and B7-H4 in EOC tissues was significantly associated with poor prognosis and high relapse rate of EOC. The findings suggest that B7-H1 and B7-H4 is a negative prognostic marker for EOC and a potential immunotherapeutic target for patients with EOC.

Introduction

Ovary is located in the deep pelvic cavity. Ovarian cancer is one of the three malignant tumors in gynecology, that accounts for 3% of cancers among women. Although it causes a higher number of mortalities than any other cancer of the female reproductive system (1,2), the signs and symptoms of ovarian cancer, when present, are subtle and vague, which conceals early onset of the disease making early diagnosis difficult (3). Despite extensive ongoing research on ovarian cancer, there are presently no good screening tests or specific tumor markers (4). When patients exhibit symptoms and seek medical assistance, 70% of them have already reached an advanced stage of the disease, and their 5-year survival rate is $\leq 30\%$ (2). Therefore, it is crucial to identify effective diagnostic and management strategies for ovarian cancer.

Advances in modern biotechnology have led to progress in immunological research for the treatment of tumors. It has been reported that the B7 family, including B7-H1 (also known as PD-L1, or programmed death-1-ligand 1) and B7-H4 (also known as B7S1 and B7x), are important co-stimulatory molecules responsible for T-cell activation (5). Recent studies have suggested that they may act as negative regulatory factors in the antitumor immune response of the body (5-7).

The aim of the current study was to investigate the expression of B7-H1 and B7-H4 in ovarian cancer and their clinical relevance. To this end, we collected ovarian neoplasm tissues and relevant clinical characteristics from patients with epithelial ovarian cancer (EOC) and with ovarian benign neoplasm, and analyzed the expressions of B7-H1 and B7-H4. The expression level of B7-H1 and B7-H4 as an independent risk factor for EOC recurrence and death was examined using statistically analyses. Our findings provide new insights for potential ovarian tumor diagnosis and targeted immunotherapy.

Materials and methods

Specimens, patient information and clinical records. Approval for the present study was obtained from the ethics committee of the Central Hospital of Xuzhou (Jiangsu, China). Written informed consent for participation in the present study was obtained from the patients and/or their close relatives.

Biopsy samples taken from 112 patients with ovarian cancer were examined. The patients, aged 21-78 years (mean,

Correspondence to: Dr Mei Xu, Department of Obstetrics and Gynecology, Central Hospital of Xuzhou, 199 Jiefang South Road, Xuzhou, Jiangsu 221009, P.R. China
E-mail: xzxumei@163.com

*Contributed equally

Key words: epithelial ovarian cancer, neoplasm, B7-H1, B7-H4, co-stimulator

55.1±12.5 years), were hospitalized at the Department of Obstetrics and Gynecology between February 2005 and December 2009. The biopsy specimens used in the study were collected from the primary tumors. Of the 112 samples, 93 cases were classified as serous cystadenocarcinoma, 12 cases as mucinous cystadenocarcinoma, 3 cases as endometrioid adenocarcinoma, and 4 cases as clear cell carcinoma. The size of these tumors ranged from 1 to 4,000 cm³ (mean, 171.9±423.2 cm³). Tumors were classified according to the International Federation of Gynecology and Obstetrics (FIGO) as follows: 26 cases, stage I; 7 cases, stage II; 72 cases, stage III; and 7 cases, stage IV. In terms of cell differentiation staging, 9 cases were at stage I, 20 cases at stage II, 78 cases at stage III, and 5 cases were borderline tumors. In 65 cases, the tumors were located on both sites. In 24 cases, it was located on the right side only, and in 23 cases, on the left side only. In 82 cases CA125 was increased, and 85 cases had tumor metastasis. Another 10 biopsies taken from benign ovarian tumor patients surgery served as the control.

Patients' inclusion criteria were: i) Post-operative lifetime ≥3 months, ii) succumbed to ovarian cancer rather than other diseases, and iii) did not receive any chemotherapy or radiotherapy before undergoing ovarian biopsy. The patients' medical records were reviewed, and follow-up was performed by phone calls and/or clinic visits, over a period of 5-10 years, with the final follow-up terminating on 31 December 2014. Surgery day was defined as time 0 for computing survival. Progression-free survival (PFS) was defined as the duration between time 0 to the day when patients were diagnosed with tumor recurrence/exacerbation. Overall survival (OS) was defined as the duration between time 0 to the day when patients succumbed, underwent truncation or the final follow-up. PFS and OS were the indices used in the survival analysis by the Kaplan-Meier method.

Immunohistochemical staining. Paraffin blocks of the collected ovarian biopsies were processed into tissue chips by Shanghai Outdo Biotech Co., Ltd. (Shanghai, China). The primary antibodies, B7-H4 (animal origin, rabbit; dilution, PBS; catalog no.: NBP2-30536) and B7-H1 (animal origin, rabbit; dilution, PBS; catalog no.: NBP1-03220) were purchased from Novus Biologicals, Inc. (Littleton, CO, USA). The secondary antibody, mouse anti-human polyclonal antibody, was obtained commercially from Fuzhou Maixin Biotechnology Co., Ltd. (Fuzhou, China). Immunohistochemical staining was conducted using the mouse/rabbit EnVision™ detection system. Briefly, after the paraffin blocks were sliced, dewaxed and hydrated, the sections were immersed in citrate buffer (10 mmol/l) (MVS-0066, Fuzhou Maixin Biotechnology Co., Ltd., Fuzhou, China). The sections were heated in a water bath for 30 min, followed by antigen repair, after which the sections were cooled down in 3% H₂O₂ for 30 min. The sections were then rinsed with PBS three times, for 5 min each. The primary antibody (dilution of 1:400) was added, and the sections were kept at 4°C overnight. PBS was used to replace the primary antibody as the negative control, after three washes with PBS, 5 min each. Subsequently, the secondary antibody was added, and the sections were kept at room temperature (25°C) for 30 min. The remaining secondary antibody was then rinsed via PBS, and DAB was applied to develop color. Hematoxylin

was used to redye the sections, and 0.1% hydrochloric acid alcohol was applied to differentiate the stains. After dehydration with a gradient series of ethanol, the sections were sealed using neutral resin, and observed under a microscope (Beijing Boruishi Technology Co., Ltd., Beijing, China).

Immunohistochemical analysis. Representative microscopic images of stained sections were taken under a microscope, at a magnification of x400. Immunohistochemical analysis was performed by randomly selecting five regions of interest (ROI) for each section from the EOC group and examining the sections at a magnification of x200. The number of tumor cells with positive staining inside the cytoplasm/cytoplasmic membrane, and the number of total cells presented in each ROI were manually counted. The percentage of positive counts was calculated and the mean values were reported. Semi-quantitative assessment was performed using an immunohistochemical scoring system which was defined as follows: 0, no positive cells presented (0%); 1, 1-10% positive cells; 2, 11-50%; 3, 51-80%; and 4, 81-100%. In addition, the strength of positive cell staining was assessed and scored as follows: 0, negative; 1, weakly positive; 2, moderately positive; and 3-4, strong positive staining. The immunohistochemical score of ovarian benign lesions was defined as the multiplication of the above two parts: (-), 0 point; +, 1-4 points; ++, 5-8 points; and +++, 9-12 points. In the present study, scores of positive response cells <4 points were defined as weak or low expression, and scores >4 points signified high expression.

Statistical analysis. Data were analyzed using SPSS 17.0 statistical software package (SPSS, Inc., Chicago, IL, USA). Numerical data were presented by means ± standard deviation. The χ^2 test was applied to compare a high and low expression in the B7-H1 and B7-H4 groups. The log-rank test and Kaplan-Meier survival curve method were used for survival analysis. COX model analysis was performed to examine the correlations of the expression of B7-H1 and B7-H4 with multiple factors including patients' age, grade of cell differentiation, level of CA125, tumor size, metastatic status, and FIGO staging. P<0.05 was considered to indicate a statistically significant difference.

Results

Immunohistochemical characteristics. A positive expression of B7-H1 and B7-H4 was evidenced in 55.4% (62/112) and 37.5% (42/112) of cases, respectively, in collected ovarian carcinoma tissues, and their coinciding expression rate was 31.3% (35/112). A positive expression was located in the cytoplasm and/or cytoplasmic membrane in tumor cells, shown as brown particles or block mass (Fig. 1). By contrast, a low or negative expression of B7-H1 and B7-H4 was found in the 10 cases with benign ovarian cyst.

Association of B7-H1 and B7-H4 expression with patient clinical characteristics. Our study examined the association of B7-H1 and B7-H4 expression with the patient clinical characteristics, including age, histological type, tissue differential degree, FIGO clinical stage, tumor size, CA125 level and metastatic status. The results showed that the expression

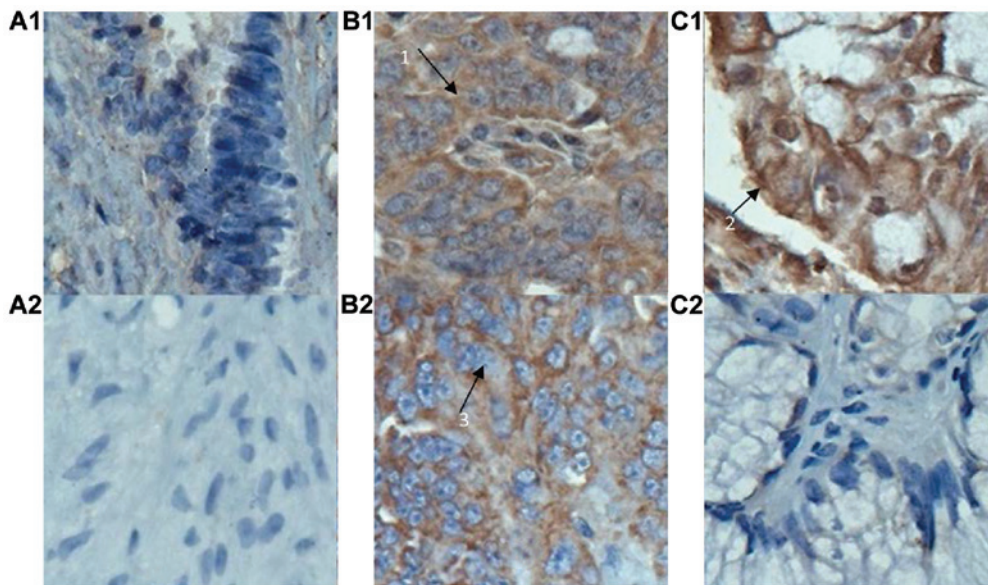


Figure 1. Representative microscopic images for the immunohistochemical detection of B7-H1 (upper panel) and B7-H4 (lower panel) expression in (A) benign ovarian cyst and (B and C) malignant ovarian tumor. (A1) and (A2) confirmed an extremely low or negative expression of B7-H1 and B7-H4 in benign ovarian cyst cells, respectively. A significant expression of B7-H1 was evidenced in (B1) serous cystadenocarcinoma and (C1) mucinous cystadenocarcinoma cells. A high expression of B7-H4 was also evident in (B2) serous cystadenocarcinoma cells, but not in (C2) mucinous cystadenocarcinoma cells. A positive expression of B7-H1 and B7-H4, shown as brown particles or mass, was localized in the ovarian cell membrane and/or cytoplasm [arrow 1 in (B1) and arrow 2 in (C1)], whereas the cell nucleus had no positive staining [arrow 3 in (B2)]. Original images were taken at a magnification of x400.

of B7-H4 was significantly correlated with histological type, clinical stage, tumor size and tumor metastasis (all at $P < 0.05$), but not with patients' age, cell differentiation and CA125 level (all $P > 0.05$, Table I). In addition, B7-H1 expression had no relationship with patients' age, cell differentiation, histological type, tumor size and CA125 level, but was relevant to clinical stage and tumor metastasis ($P < 0.05$, Table I).

Survival analysis and COX multi-factor regression. In the current study, 112 patients with ovarian cancer underwent 5-10 years follow-up. Fig. 2 compares the profiles of PFS in patients with a coinciding high expression of B7-H1 and B7-H4 to those without this expression. We found that the PFS of patients with a coinciding high expression of B7-H1 and B7-H4 was significantly shorter when compared to those without this expression (18.2 ± 139.5 vs. $2,108.2 \pm 153.7$ days, $P < 0.001$). Similarly, OS of patients with a coinciding high expression of B7-H1 and B7-H4 was $1,169.0 \pm 188.2$ days, in contrast to $2,612.2 \pm 133.3$ days for other patients (Fig. 3). The differences were statistically significant ($\chi^2 = 45.60$ and 37.99 , respectively, $P < 0.001$).

The results from the COX multi-factor regression analysis revealed that for the expression of B7-H1, the regression coefficient (B) was 0.74, and the relative risk (RR) was 2.10, with $P = 0.03$, while for the expression of B7-H4, B was 0.81, and RR was 2.25, with $P = 0.01$ (data not shown). These findings indicated that the expression of B7-H1 and B7-H4 was an independent prognostic factor that influenced the prognosis of patients with ovarian cancer.

Discussion

B7-H1 is the third member in the B7 family. Previous studies have indicated that B7-H1 plays an important role in inducing

tumor-specific T-cell apoptosis and tumor immune escape (8). B7-H4, a new member in the B7 family, negatively regulated the T-cell immunologic response by inhibiting cell proliferation, and obstructing the generation of cytokines as well as the progression of cell cycle (5). Recent findings have shown that a high expression of B7-H1 and B7-H4 in many malignant tumors was associated with occurrence, development and prognosis of tumors (8-10). Overexpression of B7-H1 and B7-H4 in tumor tissues may become a new tumor marker or target for immunotherapy. Previous findings have shown evidence of B7-H4 expression in ovarian carcinoma tissues, but reports on the expression of B7-H1 are lacking (11).

Wu *et al* (12) have conducted a study on the expression, clinical pathology and prognostic correlation of B7-H1. Their results showed that B7-H1 had no expression in normal stomach, mild expression in gastric adenoma, but a strong expression in 42.2% of gastric cancer tissues. Additionally, its expression degree was correlated with tumor size, depth of invasion, lymphatic metastasis, and patient survival. Thus, B7-H1 may serve as an independent factor in evaluating the prognosis of patients with gastric carcinoma. Hamanishi *et al* (13) reported that the expression level of B7-H1 in ovarian carcinoma tissues was negatively correlated with the number of CD8⁺T in tumor tissues and that B7-H1 was an independent factor in evaluating patient prognosis. The results from our study demonstrated that positive staining of B7-H1 was located in the cytoplasm and/or cytomembrane of tumor cells. A low expression of B7-H1 was observed in the 10 cases of benign ovarian cyst whereas 55.4% of the ovarian carcinoma (or 62 of 112 cases) had a high expression ($P < 0.05$). Our data showed a slightly higher incidence than that reported by Yu *et al* (11).

In another study, the expression of B7-H4 in ovarian cancers of different pathological types was compared to that in normal ovarian tissues (14). It was found that B7-H4 mRNA

Table I. Association of B7-H1 and B7-H4 expression in ovarian carcinoma tissue with clinical pathological parameters for patients with ovarian cancer.

Variable	Total cases	Cases with B7-H4 expression				Cases with B7-H1 expression			
		High	Low	χ^2	P-value	High	Low	χ^2	P-value
Age, years				0.56	0.46			0.55	0.46
<55	45	15	30			23	22		
≥ 55	67	27	40			39	28		
Histological typing				7.98	0.05 ^a			3.62	0.31
Serous	93	40	53			50	43		
Mucinous	12	1	11			6	6		
Endometrioid	3	1	2			2	1		
Clear cell cancer	4	0	4			4	0		
Cell grading				4.12	0.25			0.95	0.81
Borderline	5	1	4			2	3		
Poorly differentiated	78	34	44			6	3		
Moderately differentiated	20	5	15			11	9		
Highly differentiated	9	2	7			43	35		
FIGO staging				29.64	0.00 ^a			15.44	0.00 ^a
I	26	0	26			7	19		
II	7	2	5			5	2		
III	72	33	39			43	29		
IV	7	7	0			7	0		
Tumor size				5.30	0.02 ^a			0.28	0.60
<120 cm ³	79	35	44			45	34		
≥ 120 cm ³	33	7	26			17	16		
CA125				2.05	0.15			0.03	0.87
Normal	30	8	22			16	14		
Uprising	82	34	48			45	37		
Metastasis				17.34	0.00 ^a			12.47	0.00 ^a
Yes	85	41	44			55	30		
No	27	1	26			7	20		

^aP<0.05 comparing cases with a high to a low expression.

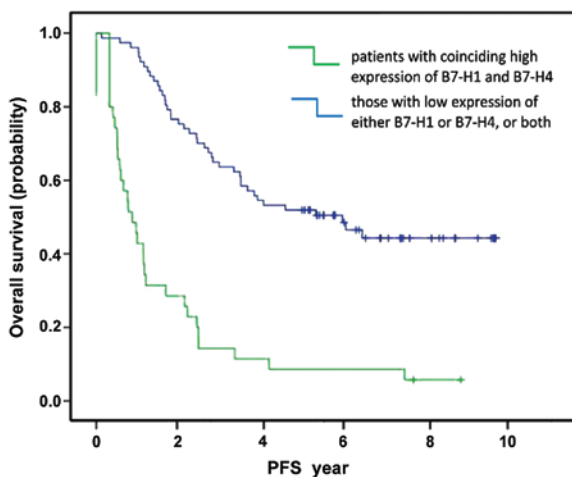


Figure 2. Comparison of progression-free survival (PFS) profiles in patients with a coinciding high expressions of B7-H1 and B7-H4 (green line) to those with an extremely low/negative expression of B7-H1 and/or B7-H4 (blue line). Patients with a high coinciding expressions of B7-H1 and B7-H4 had shorter PFS and were prone to relapse.

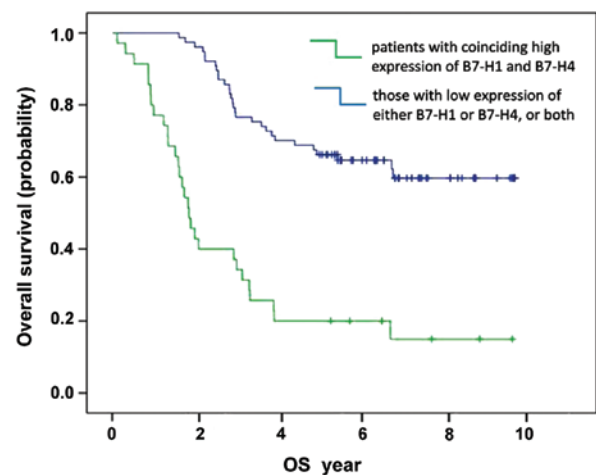


Figure 3. Comparison of overall survival (OS) profiles in patients with a coinciding high expression of B7-H1 and B7-H4 (green line) to those with an extremely low/negative expression of B7-H1 and/or B7-H4 (blue line). Patients with a high coinciding expression of B7-H1 and B7-H4 had shorter OS and higher mortality.

had a high expression in 87.5% of ovarian serous papillary adenocarcinoma tissues, which was ≥ 2 -fold higher than the average expression level in normal ovarian tissues. However, the expression level of B7-H4 mRNA in mucus and border ovarian tissues was equivalent to that in normal ovarian tissues. Based on these findings, we hypothesized that the expression of B7-H4 mRNA in ovarian cancers was tissue-specific and was located in the cell membrane. The results of the present study confirmed that the positive staining of B7-H4 was located in the cytoplasm and/or cytomembrane of tumor cells. B7-H4 showed a low expression in the 10 cases of benign ovarian cyst, in contrast to the positive, high expression rate (37.5% or 42/112) in the 112 cases of ovarian carcinoma tissues. Additionally, its expression in ovarian cancers had tissue specificity ($\chi^2=7.98$, $P=0.046$). Its expression rate reached 43% (40/93) in serous cystadenocarcinoma, but in mucinous cystadenocarcinoma, it was reduced (8.33% or 1/12). Furthermore, B7-H4 showed a high expression in 1 of the 3 endometrioid carcinoma cases, but had a low expression in the 4 subjects with clear cell carcinomas. By contrast, Tringler *et al* reported that B7-H4 had 100% expression in the primary ovarian serous carcinomas (32 cases), endometrioid carcinomas (12 cases), clear cell carcinomas (15 cases) and all of the metastatic serous carcinomas (23 cases) and metastatic endometrioid carcinomas (7 cases), while only 1 out of 11 cases with mucinous carcinomas had a positive B7-H4 expression (15). The discrepancy between their results and the results of the present study remain to be elucidated with regard to the specificity of B7-H4 expression on a larger scale.

Our results have shown that the expression levels of B7-H1 and B7-H4 were associated with FIGO stage and the occurrence of metastasis ($P<0.05$), but they were not significantly associated with cell differentiation, tumor site, occurrence of combined CA125 and patient age ($P>0.05$). In other words, the more advanced the FIGO stage, the higher the expression level. Compared with the low expression, a higher expression of B7-H1 and B7-H4 indicated a higher recurrence rate and mortality. Results from the COX regression analysis demonstrated that the expression levels of B7-H1 and B7-H4 were independent prognostic factors of patients with EOC. Thus, the immunoinhibitory B7-H1 and B7-H4 molecules are potential targets in EOC management.

Closing the channel of B7-H1/PD-1 may be used as a major joint antitumor treatment (16-18). By using the hybridoma technique, Zhang *et al* (16) prepared the monoclonal antibody MAb 5G3 which combined with the B7-H4 molecules and promoted the apoptosis of A549 lung carcinoma cells. Similarly, by using a specific siRNA targeting B7-H4, the expression of B7-H4 mRNA and its protein was knocked out, thereby inhibiting the growth of cancer by increasing tumor cell apoptosis and inhibiting Erk1/2 signal channels (19). The abovementioned investigations indicated the potential of this therapeutic target in treating cancer, particularly for EOC patients who had high incidence but poor prognosis.

In conclusion, the results of the present study have identified an extremely low or negative expression of B7-H1 and B7-H4 in benign ovarian neoplasm tissues, but a significantly high expression in EOC tissues. In addition, the co-expression of B7-H1 and B7-H4 was evident in $>30\%$ of the EOC cases. Patients with a high coinciding B7-H1 and B7-H4 expression

had lower survival, and were prone to relapse. These findings demonstrate that B7-H1 and B7-H4 expression in EOC tissues was significantly associated with poor prognosis and a high relapse rate of EOC, suggesting that B7-H1 and B7-H4 constitute negative prognostic markers for EOC and a potential immunotherapeutic target for patients with EOC.

References

1. Siegel R, Naishadham D and Jemal A: Cancer statistics, 2012. *CA Cancer J Clin* 62: 10-29, 2012.
2. Varughese E, Kondalsamy-Chennakesavan S and Obermair A: The value of serum CA125 for the development of virtual follow-up strategies for patients with epithelial ovarian cancer: A retrospective study. *J Ovarian Res* 5: 11, 2012.
3. Givens V, Mitchell GE, Harraway-Smith C, Reddy A and Maness DL: Diagnosis and management of adnexal masses. *Am Fam Physician* 80: 815-820, 2009.
4. Schummer M, Drescher C, Forrest R, Gough S, Thorpe J, Hellström I, Hellström KE and Urban N: Evaluation of ovarian cancer remission markers HE4, MMP7 and Mesothelin by comparison to the established marker CA125. *Gynecol Oncol* 125: 65-69, 2012.
5. He C, Qiao H, Jiang H and Sun X: The inhibitory role of b7-h4 in antitumor immunity: association with cancer progression and survival. *Clin Dev Immunol* 2011: 695834, 2011.
6. Mao Y, Li W, Chen K, Xie Y, Liu Q, Yao M, Duan W, Zhou X, Liang R and Tao M: B7-H1 and B7-H3 are independent predictors of poor prognosis in patients with non-small cell lung cancer. *Oncotarget* 6: 3452-3461, 2015.
7. Zhao LW, Li C, Zhang RL, Xue HG, Zhang FX, Zhang F and Gai XD: B7-H1 and B7-H4 expression in colorectal carcinoma: Correlation with tumor FOXP3(+) regulatory T-cell infiltration. *Acta Histochem* 116: 1163-1168, 2014.
8. Topalian SL, Drake CG and Pardoll DM: Targeting the PD-1/B7-H1(PD-L1) pathway to activate anti-tumor immunity. *Curr Opin Immunol* 24: 207-212, 2012.
9. Wang X, Wang T, Xu M, Xiao L, Luo Y, Huang W, Zhang Y and Geng W: B7-H4 overexpression impairs the immune response of T cells in human cervical carcinomas. *Hum Immunol* 75: 1203-1209, 2014.
10. Song X, Liu J, Lu Y, Jin H and Huang D: Overexpression of B7-H1 correlates with malignant cell proliferation in pancreatic cancer. *Oncol Rep* 31: 1191-1198, 2014.
11. Yu XW, Li CH, Zhang SL, *et al*: Study on the expression of PD-L1 in patients with ovarian cancer. *Chin J Lab Diagn* 14: 1854-1856, 2010.
12. Wu C, Zhu Y, Jiang J, Zhao J, Zhang XG and Xu N: Immunohistochemical localization of programmed death-1 ligand-1 (PD-L1) in gastric carcinoma and its clinical significance. *Acta Histochem* 108: 19-24, 2006.
13. Hamanishi J, Mandai M, Iwasaki M, Okazaki T, Tanaka Y, Yamaguchi K, Higuchi T, Yagi H, Takakura K, Minato N, *et al*: Programmed cell death 1 ligand 1 and tumor-infiltrating CD8+ T lymphocytes are prognostic factors of human ovarian cancer. *Proc Natl Acad Sci USA* 104: 3360-3365, 2007.
14. Salceda S, Tang T, Kmet M, Munteanu A, Ghosh M, Macina R, Liu W, Pilkington G and Papkoff J: The immunomodulatory protein B7-H4 is overexpressed in breast and ovarian cancers and promotes epithelial cell transformation. *Exp Cell Res* 306: 128-141, 2005.
15. Tringler B, Liu W, Corral L, Torkko KC, Enomoto T, Davidson S, Lucia MS, Heinz DE, Papkoff J and Shroyer KR: B7-H4 overexpression in ovarian tumors. *Gynecol Oncol* 100: 44-52, 2006.
16. Zhang N, Fang P and Gu ZJ: Preparation and characterization of monoclonal antibody against human B7-H4 molecule. *Monoclon Antib Immunodiagn Immunother* 33: 270-274, 2014.
17. Sznoł M: Blockade of the B7-H1/PD-1 pathway as a basis for combination anticancer therapy. *Cancer J* 20: 290-295, 2014.
18. Afreen S and Dermime S: The immunoinhibitory B7-H1 molecule as a potential target in cancer: Killing many birds with one stone. *Hematol Oncol Stem Cell Ther* 7: 1-17, 2014.
19. Qian Y, Hong B, Shen L, Wu Z, Yao H and Zhang L: B7-H4 enhances oncogenicity and inhibits apoptosis in pancreatic cancer cells. *Cell Tissue Res* 353: 139-151, 2013.