

Internal Mammary Artery and Vein Perforator Vessels as Troubleshooter Recipient Vessels

Hisham Fansa, MD, MBA*†

Summary: In autologous breast reconstruction, the internal mammary artery (IMA) and internal mammary vein (IMV) are the standard recipient vessels. Recently, the perforator vessels of the IMA and IMV were found to be a safe alternative as recipient vessels cause less morbidity and allow adequate flap. We describe 2 cases in which the IMA and IMV perforators were used as additional recipient vessels to overcome intraoperatively occurred complications. The IMA and IMV perforators have some advantages over the IMA/IMV: (1) the dissection is done superficially and directly from the mastectomy site. Flap positioning is facilitated. (2) There is no need to remove a rib, which reduces postoperative pain and possible contour deformities. (3) Possible injuries to the pleura are avoided. (4) The IMA is spared for possible cardiac revascularization. Disadvantages can be that (1) the IMA perforators are not always present with the required caliber, (2) the position of the perforators is not suitable to adequately position the flap, and (3) dissection of the IMA perforators and their anastomoses has a learning curve. In the presented cases, the IMA and IMV perforators have proven to offer a simple solution to avoid complications. The additional dissection is done from the same recipient site, and there is no further dissection or incision necessary at the axilla or to explore the cephalic vein. This keeps morbidity and operation time low. Therefore, we suggest keeping the IMA and IMV perforators in mind not only as primary recipient vessels but also as a possible solution for intraoperatively occurred complications. (*Plast Reconstr Surg Glob Open* 2019;7:e2148; doi: 10.1097/GOX.0000000000002148; Published online 20 March 2019.)

In autologous breast reconstruction, the internal mammary artery (IMA) and internal mammary vein (IMV) are the standard recipient vessels.^{1,2} They allow easy access, are safe, and offer a good flap positioning. Recently, the perforator vessels of the IMA and IMV have been further evaluated. They were found to be a safe alternative as recipient vessels cause less morbidity and allow adequate flap perfusion.³⁻⁷ Different techniques for anastomoses such as mismatch reducing techniques or end-to-side anastomoses have also been described.^{8,9}

Other recipient vessels are the lateral thoracic artery, the vessels from the subscapular vascular tree, and thoracoacromial vessels.¹⁰ The contralateral IMA and IMV were also described.¹¹ The caudal IMV (retrograde) and the cephalic vein were used to prevent venous congestion.¹²⁻¹⁴

From the *Center for Aesthetic Plastic Surgery and Reconstructive Breast Surgery, Prof. Fansa, Munich, Germany; and †Department of Plastic, Reconstructive and Aesthetic Surgery, Klinikum Bielefeld, Germany.

Received for publication October 27, 2018; accepted December 18, 2018.

Copyright © 2019 The Author. Published by Wolters Kluwer Health, Inc. on behalf of The American Society of Plastic Surgeons. This is an open-access article distributed under the terms of the Creative Commons Attribution-Non Commercial-No Derivatives License 4.0 (CCBY-NC-ND), where it is permissible to download and share the work provided it is properly cited. The work cannot be changed in any way or used commercially without permission from the journal.

DOI: 10.1097/GOX.0000000000002148

We describe 2 cases in which the IMA and IMV perforators were used as additional recipient vessels to overcome intraoperatively occurred complications.

Case 1: The patient had a prior breast reconstruction with an implant on the right side. She has received chemotherapy and radiation. Due to a capsular contracture after 5 years, she has asked for a conversion using a deep inferior epigastric perforator (DIEP) flap. The flap was harvested without problems. The IMA and IMV were dissected as recipient vessels. A rib was removed. The artery showed severe adhesions to the surrounding tissue and the pleura. But it was possible to dissect the IMA over a length of 1.5 cm. The vein was stuck to the pleura over a long distance; a dissection without injuring the pleura was not possible. Therefore, the IMA and IMV perforator vessels were explored medially at the level of the same intercostal space. The perforator artery was small, but the vein showed a good caliber. The deep inferior epigastric artery was anastomosed to the IMA. The deep inferior epigastric vein was coupled to the IMV perforator using a 2.5-mm coupler (Fig. 1). The healing was uneventful.

Disclosure: The author has no financial interest to declare in relation to the content of this article.

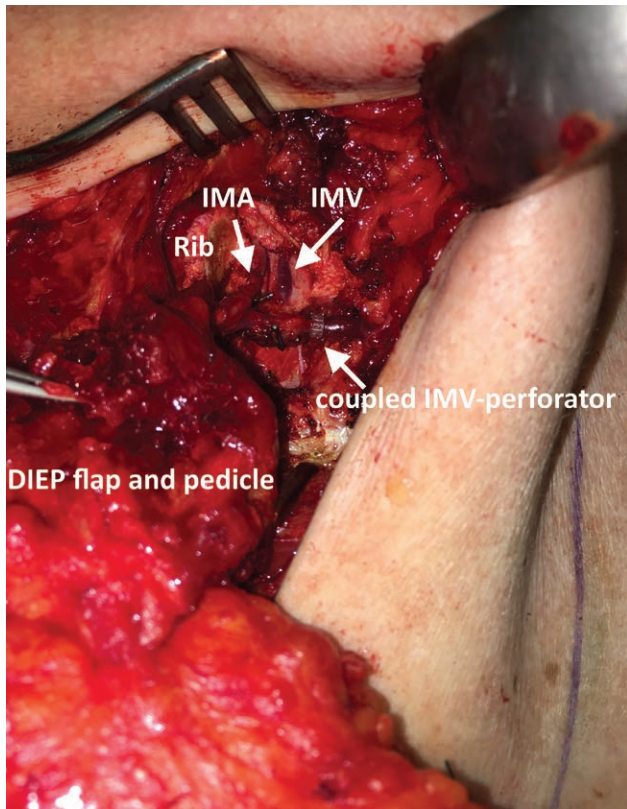


Fig. 1. Reconstruction with a DIEP flap on the right side. The patient had a prior implant reconstruction with capsular contracture, chemotherapy, and radiation. The IMA and IMV were explored by removing a rib. The IMA was suitable for anastomosis, but the vein could not be dissected and was stuck to the pleura. Therefore, the IMA and IMV perforator vessels were explored. The flap artery was anastomosed to the IMA and the flap vein to the IMV perforator.

Case 2: A delayed reconstruction with a DIEP flap on the left side was planned. The IMA and IMV were dissected using a rib-sparing approach. While harvesting the flap, the superficial veins at the lower abdominal incision showed a large caliber and filling. They were preventively harvested longer from the caudal incision (Fig. 2A). After harvesting the DIEP flap on 1 medial row perforator, the flap showed signs of venous congestion. First, the flap was trimmed by removing zone 4 completely and zone 3 partially as they were not necessary anyway. This maneuver did not significantly relieve the congestion. Apparently the superficial and deep venous system did not communicate adequately. A flap template, its pedicle, and superficial veins were drawn on the sterile glove paper. The template was positioned over the recipient site. It was seen that the good flap positioning for breast reconstruction allowed the DIEP pedicle to be anastomosed to the IMA and IMV and the superficial vein to the same position. Therefore, the recipient site was explored for IMA and IMV perforator vessels. Large caliber perforator vessels were found 1 intercostal space cranially (Fig. 2B). The DIEP flap pedicle was anastomosed to the IMA and IMV (using a 2.5-mm coupler). The superficial flap vein was anastomosed to the IMV perforator using a 3.0-mm coupler (Fig. 2C). The flap showed a quick decongestion, and healing was uneventful.

DISCUSSION

The IMA and IMV are routinely used as recipient vessels for autologous breast reconstruction. If apparent, we use the IMA and IMV perforator vessels for DIEP flaps, inner thigh flaps (transverse musculus gracilis [TMG] or profunda artery

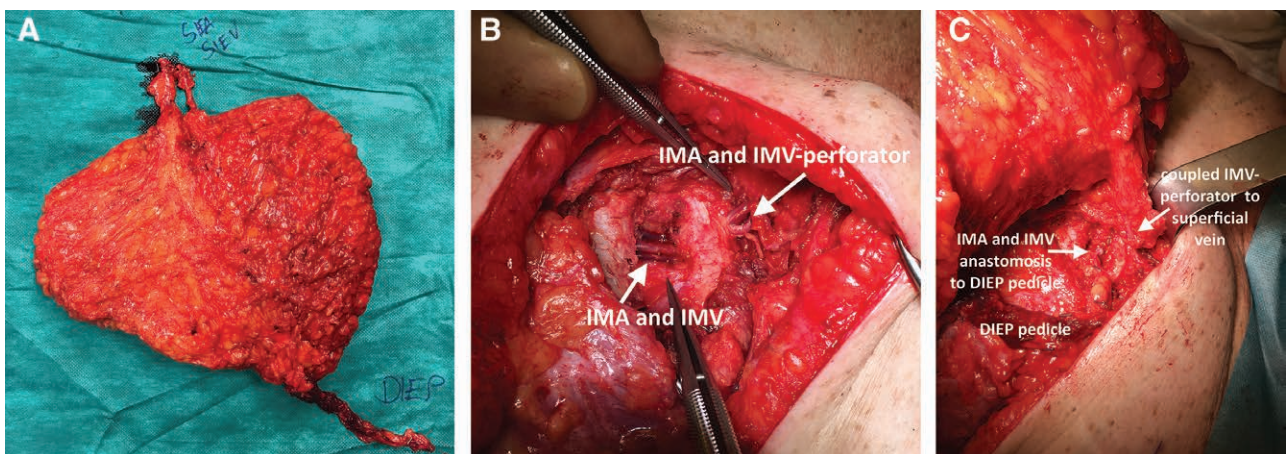


Fig. 2. Delayed reconstruction with a DIEP flap on the left side. The flap showed venous congestion. A, The DIEP pedicle and superficial veins were harvested. B, The IMA and IMV, rib-sparing approach. To connect the superficial vein, the recipient site was explored for IMA and IMV perforator vessels. Large caliber perforator vessels (IMA and IMV perforator) were found 1 intercostal space cranially. C, The DIEP flap pedicle was anastomosed to the IMA and IMV (using a 2.5-mm coupler). The superficial flap vein was anastomosed to the IMV perforator using a 3.0-mm coupler.

perforator [PAP] flap), fasciocutaneous infragluteal (FCI) flaps, and especially for superficial inferior epigastric artery (SIEA) flaps. There is neither an increased mastectomy flap necrosis nor a decreased flow to the flap itself. In a cohort study, we have previously described that the perforator vessels can be used not only in immediate reconstructions but also in secondary cases after previous radiation, implant reconstruction, or mastectomy.⁷ The artery usually shows a strong flow, and the vein has a large caliber. However, the IMV perforators have valves, which have to be respected when using the coupling device. The IMA and IMV perforators have advantages over the IMA/IMV¹: the dissection is done superficially and directly from the mastectomy site. Flap positioning is facilitated.² There is no need to remove a rib, which reduces postoperative pain and possible contour deformities.³ Possible injuries to the pleura are avoided.⁴ The IMA is spared for possible cardiac revascularization. Disadvantages can be that (1) the IMA perforators are not always present with the required caliber, (2) the position of the perforators is not suitable to adequately position the flap (eg, short flap pedicle and very cranial internal mammary artery perforator [IMAP] position), and (3) dissection of the IMA perforators and their anastomoses has a learning curve.

In the presented cases, the IMA and IMV perforators have proven to offer a simple solution to avoid complications. The additional dissection is done from the same site. This keeps morbidity and operation time low. Therefore, we suggest keeping the IMA and IMV perforators in mind not only as primary recipient vessels but also as a possible solution for intraoperatively occurred complications.

Hisham Fansa, MD, MBA

Center for Aesthetic Plastic Surgery
and Reconstructive Breast Surgery
Maximilianstrasse 38
80539 Munich, Germany
E-mail: info@fansa.de

REFERENCES

- Haddock NT, Teotia SS. Five steps to internal mammary vessel preparation in less than 15 minutes. *Plast Reconstr Surg.* 2017;140:884–886.
- Nahabedian MY. The internal mammary artery and vein as recipient vessels for microvascular breast reconstruction: are we burning a future bridge? *Ann Plast Surg.* 2004;53:311–316.
- Hamdi M, Blondeel P, Van Landuyt K, et al. Algorithm in choosing recipient vessels for perforator free flap in breast reconstruction: the role of the internal mammary perforators. *Br J Plast Surg.* 2004;57:258–265.
- Saint-Cyr M, Chang DW, Robb GL, et al. Internal mammary perforator recipient vessels for breast reconstruction using free TRAM, DIEP, and SIEA flaps. *Plast Reconstr Surg.* 2007;120:1769–1773.
- Follmar KE, Prucz RB, Manahan MA, et al. Internal mammary intercostal perforators instead of the true internal mammary vessels as the recipient vessels for breast reconstruction. *Plast Reconstr Surg.* 2011;127:34–40.
- Fansa H, Schirmer S, Cervelli A, et al. Computed tomographic angiography imaging and clinical implications of internal mammary artery perforator vessels as recipient vessels in autologous breast reconstruction. *Ann Plast Surg.* 2013;71:533–537.
- Vollbach FH, Heitmann CD, Fansa H. An appraisal of internal mammary artery perforators as recipient vessels in microvascular breast reconstruction—an analysis of 515 consecutive cases. *Plast Reconstr Surg Glob Open.* 2016;4:e1144.
- Saour S, Libondi G, Ramakrishnan V. Microsurgical refinements with the use of internal mammary (IM) perforators as recipient vessels in transverse upper gracilis (TUG) autologous breast reconstruction. *Gland Surg.* 2017;6:375–379.
- Apostolides JG, Magarakis M, Rosson GD. Preserving the internal mammary artery: end-to-side microvascular arterial anastomosis for DIEP and SIEA flap breast reconstruction. *Plast Reconstr Surg.* 2011;128:225e–232e.
- Santanelli Di Pompeo F, Longo B, Sorotos M, et al. The axillary versus internal mammary recipient vessel sites for breast reconstruction with diep flaps: a retrospective study of 256 consecutive cases. *Microsurgery.* 2015;35:34–38.
- Fansa H. Recipient Vessels. in Fansa H. and Heitmann C. Breast reconstruction with autologous tissue. Springer Nature Switzerland 2019, page 59–67.
- Chan RK, Przylecki W, Guo L, et al. Case report. The use of both antegrade and retrograde internal mammary vessels in a folded, stacked deep inferior epigastric artery perforator flap. *Eplasty.* 2010;10:e32.
- Salgarello M, Visconti G, Barone-Adesi L, et al. The retrograde limb of internal mammary vessels as reliable recipient vessels in DIEP flap breast reconstruction: a clinical and radiological study. *Ann Plast Surg.* 2015;74:447–453.
- Chang EI, Fearmonti RM, Chang DW, et al. Cephalic vein transposition versus vein grafts for venous outflow in free-flap breast reconstruction. *Plast Reconstr Surg Glob Open.* 2014;2:e141.