

HOSTED BY



ELSEVIER

Contents lists available at ScienceDirect

# Chinese Journal of Traumatology

journal homepage: <http://www.elsevier.com/locate/CJTEE>

## Case report

# A six months old neglected anterior shoulder dislocation managed by closed reduction and Latarjet procedure

Deepak Chaudhary, Deepak Joshi, Vineet Jain, Mukul Mohindra\*, Nitin Mehta

Sports Injury Center, Safdarjung Hospital and VMM College, New Delhi, India

## ARTICLE INFO

### Article history:

Received 20 September 2015

Received in revised form

12 February 2016

Accepted 23 March 2016

Available online 23 June 2016

### Keywords:

Shoulder dislocation

Humeral fractures

Latarjet procedure

## ABSTRACT

A neglected shoulder dislocation is a rarer entity and only few cases are reported in the literature. An anterior dislocation of the shoulder is rarely missed as patients present with limb in abduction and external rotation, an attitude very familiar to orthopaedic surgeon. Occasionally such cases are missed when they present with fracture of proximal humerus or when they receive treatment from unqualified practitioners who commonly practise in rural areas. Owing to very few reports there is paucity of literature and no standard treatment protocol exists for neglected anterior dislocation of the shoulder, though most such chronic cases are managed by open reduction. This case report describes a six months old neglected anterior dislocation with a significant Hill Sachs lesion, which was managed by closed reduction and Latarjet procedure.

© 2016 Daping Hospital and the Research Institute of Surgery of the Third Military Medical University.

Production and hosting by Elsevier B.V. This is an open access article under the CC BY-NC-ND license (<http://creativecommons.org/licenses/by-nc-nd/4.0/>).

## Introduction

Dislocations of the shoulder account for almost 45% of all dislocations that present to an orthopaedic surgeon with almost 90% being the anterior subtype.<sup>1</sup> A neglected shoulder dislocation is a rarer entity in orthopaedics, with only few cases being reported in the literature. Posterior dislocation of the shoulder is most commonly neglected due to presentation of the limb in adduction and internal rotation secondary to seizure or electric shock episode. Anterior dislocation of the shoulder is rarely missed as patients present with limb in abduction and external rotation. Occasionally such cases are missed or present with fracture of proximal humerus especially when they receive treatment from unqualified practitioners who commonly practise in rural areas. Owing to paucity of the literature, no standard treatment protocol exists for neglected anterior dislocation of the shoulder, though most such chronic cases are managed by open reduction.<sup>2</sup>

This article describes a six months old neglected anterior dislocation with a significant Hill Sachs lesion, which was managed by closed reduction and Latarjet procedure.

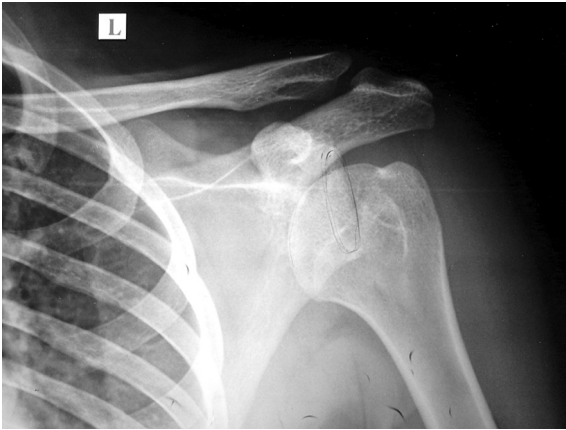
## Case report

A 24 years old male, manual labourer by profession, presented with a six months old neglected anterior shoulder dislocation, which he had sustained during road traffic accident. During the acute episode the patient was taken to an unqualified practitioner who did not attempt reduction and managed the injury with some topical application and arm sling. The prime complaint of the patient was mild to moderate pain and restricted range of motion, especially overhead abduction and internal rotation. On clinical examination, the limb was in an attitude of adduction and neutral rotation, there was loss of shoulder contour and Dugas test was positive. The head could be palpated on the anterior aspect of the shoulder with restriction of internal rotation. There was no distal neurovascular deficit. X-ray anteroposterior (AP) view of the shoulder followed by computed tomography (CT) scan and magnetic resonance imaging (MRI) were done for evaluation and planning appropriate management. X-ray (AP view) showed anterior shoulder dislocation (Fig. 1). CT scan (Figs. 2 and 3) showed anterior dislocation of the shoulder with posterior part of the humeral head engaged at anterior glenoid rim resulting in a significant Hill Sach lesion. Volumetric measurement of the humeral head revealed bone loss of 32% while anterior glenoid had 10% bone loss. MRI did not reveal any other concomitant soft tissue injury or bony defect. In view of six months old neglected dislocation and significant humeral bone loss, patient was planned for

\* Corresponding author. Tel.: +91 99 90092928.

E-mail address: [mukulmohindra@gmail.com](mailto:mukulmohindra@gmail.com) (M. Mohindra).

Peer review under responsibility of Daping Hospital and the Research Institute of Surgery of the Third Military Medical University.



**Fig. 1.** X-ray AP view of the shoulder showing dislocated anterior humeral head in a 24 years old male.

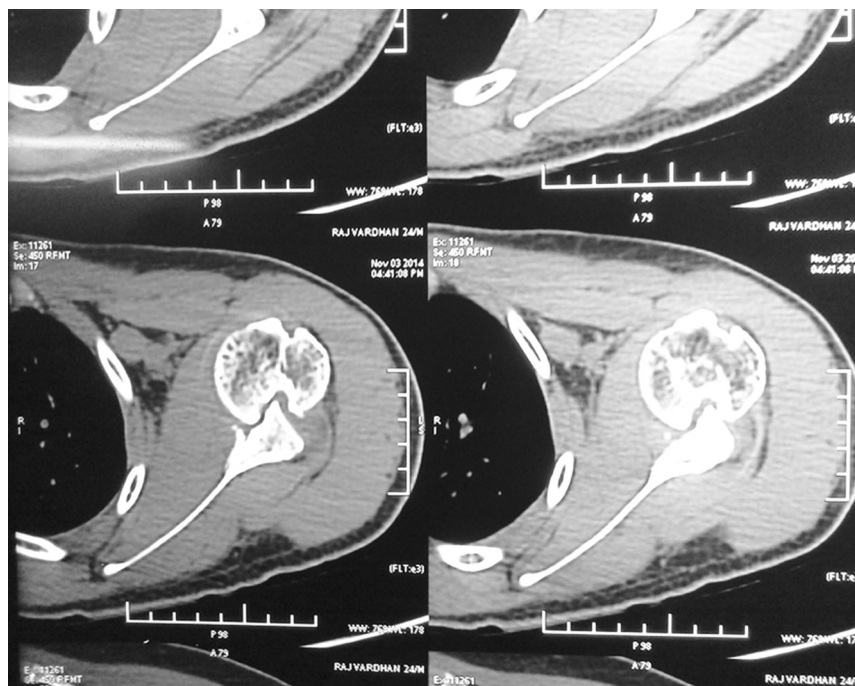
an open reduction and Latarjet procedure. Patient was prognosticated and informed consent for procedure was taken. Patient was given brachial block followed by general anaesthesia. A single gentle attempt was made to achieve closed reduction, which succeeded. The reduction was stable but considering the significant humeral bone defect and glenoid bone loss, Latarjet procedure was performed and coracoid fixation was done with two cannulated cancellous screws.

Postoperatively we followed the protocol as advocated by Mercier et al.<sup>3</sup> The limb was supported in a sling for 15 days to reduce pain. Mobilization in abduction (till 90°) and external rotation (till 25°) was allowed after the first week and after three weeks further range of motion was encouraged. Strengthening exercises of the biceps were delayed until three months to protect coracoid graft. The bone graft demonstrated early consolidation at around three months (Fig. 4) and after that patient was allowed to start with light work. Patient had no episode of dislocation at one year follow-up and had returned back to normal work as a manual labourer.

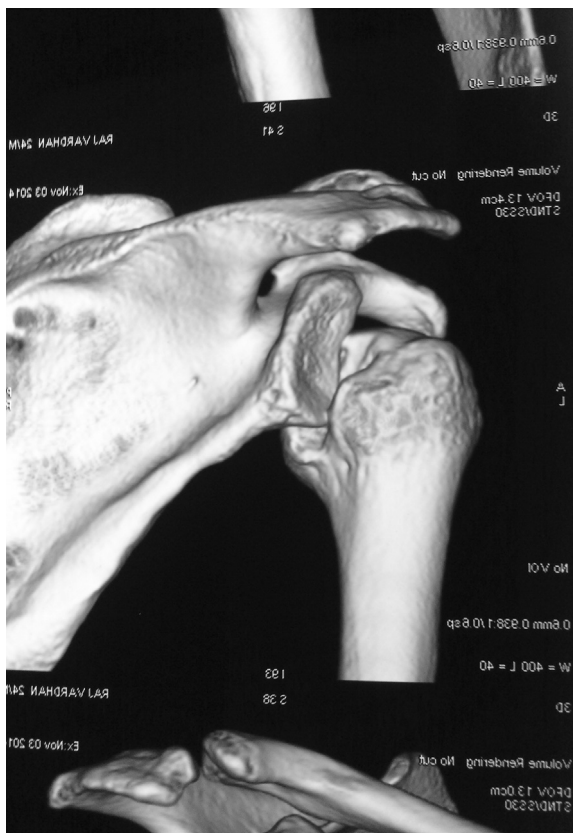## Discussion

Management of a neglected shoulder dislocation, especially with significant bony defects, is a dilemma. Most such cases in the literature have been reported in isolation or as short case series. Most such reports have recommended open reduction of the dislocation, if the time since injury has been more than four weeks, due to increased risk of concomitant fracture or cartilage injury.<sup>2,4</sup> Neviaser<sup>5</sup> performed the gleno-humeral transfixation with a screw while Rockwood et al<sup>6</sup> used smooth pins through the head into the glenoid for maintaining reduction in such chronic cases. Wilson et al<sup>7</sup> recommended the acromio-humeral transfixing pins for stability which was also the method used by Goga.<sup>8</sup> Mansat et al<sup>9</sup> recommended performing a simultaneous capsulo-labral repair after open reduction instead of transfixing the joint and reported more favourable results than metallic joint fixation in his report of five patients, with an average delay of 14 months post injury. Recently, Rouhani et al<sup>4</sup> also reported similar outcome after same procedure in their report of eight cases where average delay was 10 weeks. They advocated that joint transfixation halts joint motion for 3–4 weeks while early mobilization improves cartilage nutrition and hence gives better long term results.<sup>4</sup> Perniceni et al<sup>10</sup> described anterior shoulder complex reinforcement in three patients after neglected anterior shoulder dislocation but they used the Gosset technique,<sup>11</sup> which places a rib graft between the coracoid and the glenoid rim. Owing to rarity of cases and paucity of literature, treatment guidelines remain surgeon dependent, although most reports recommend open reduction of dislocation in cases more than four weeks old.<sup>2</sup> Since our case was more than 26 weeks old, he was planned up for open reduction but we were able to achieve a stable closed reduction with a single gentle attempt.

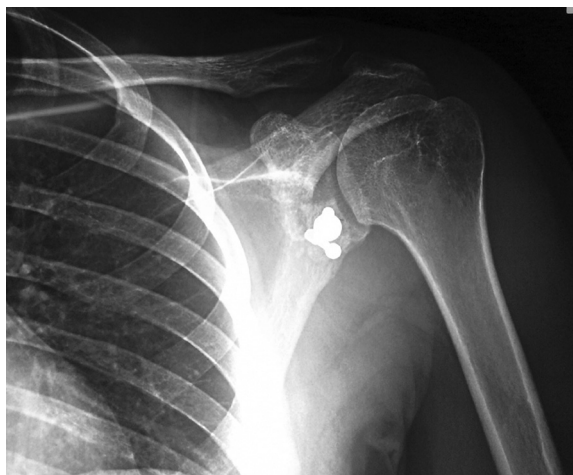These neglected cases generally tend to have significant bony defects due to constant motion of the dislocated head against the anterior border of glenoid, which was also the case with our patient. Although the possible role of bony defects as a cause of recurrent instability actually depends on their size and depth, Burkhart and Danaceau<sup>12</sup> identified recurrent instability in all



**Fig. 2.** Axial section of CT scan of neglected anterior shoulder dislocation showing an engaging Hill Sachs lesion.



**Fig. 3.** 3-D CT scan image showing neglected anterior shoulder dislocation with an engaging Hill Sachs lesion.



**Fig. 4.** X-ray AP view of the shoulder at 3 months postoperation showing consolidated coracoid graft.

patients with an engaging Hill Sachs lesion. It is recommended that Hill Sachs lesions involving up to 25% of humeral head may be left neglected, but if engaging, concurrent open/arthroscopic remplissage is generally the accepted treatment.<sup>2,13,14</sup> Abdelhady<sup>2</sup> has reported good outcome with his experience of performing open remplissage of Hill Sachs lesion with infraspinatus tendon in four such patients which had been left unreduced for 10–20 weeks. In defects more than 25% but less than 40%, anatomic

procedures like allograft reconstruction of the head, humeral head dis-impaction/humeroplasty and non-anatomic procedures like osseous or soft tissue (remplissage) transfer of the infraspinatus and Latarjet<sup>13,14</sup> are recommended. Latarjet provides stability by virtue of its ‘triple effect’<sup>15</sup> and enjoys greater familiarity with the surgeon than remplissage procedure.<sup>13</sup> Burkhart et al<sup>16</sup> reported excellent outcome of Modified Latarjet procedure in 102 patients, who either had more than 25% of glenoid bone loss or an engaging Hill Sachs lesion, with only 4.9% recurrence rate after a mean follow-up of 59 months. In defects that comprise more than 40%–50% of the head, rotational proximal humeral osteotomy in young patients and partial or total humeral head arthroplasty are recommended.<sup>13</sup> Gavriilidis<sup>17</sup> reported good mid-term results after shoulder arthroplasty in 12 patients he had managed, where average delay was 14 months. For Glenoid bone defects, Latarjet remains the main stay in most cases where defect is between 25% and 40%; in larger defects however, the loss has to be build up with allografts or grafts from the iliac crest.<sup>16</sup>

In our case there was a significant humeral bone loss of approximately 32% with a small associated glenoid bone defect and we managed the same with Latarjet procedure to prevent recurrent anterior instability.

In conclusion we would recommend even in chronic cases that a gentle attempt may be made to achieve closed reduction which may succeed. Transfixation of the joint is not required if one addresses associated bone loss that is common in such a setting. Latarjet is an effective procedure for management of significant humeral or glenoid bone loss in these chronic cases.

## References

- Koval K, Zuckerman J. *Glenohumeral Dislocations. Handbook of Fractures*. 3rd ed. Philadelphia: Lippincott Williams and Wilkins; 2009:147–165.
- Abdelhady AM. Neglected anterior shoulder dislocation: open remplissage of the Hill-Sachs lesion with the infraspinatus tendon. *Acta Orthop Belg*. 2010;76:162–165.
- Mercier N, Saragaglia D. Mini-open Latarjet procedure for recurrent anterior shoulder instability. *Adv Orthop*. 2011;2011:656205. <http://dx.doi.org/10.4061/2011/656205>.
- Rouhani A, Navali A. Treatment of chronic anterior shoulder dislocation by open reduction and simultaneous bankart lesion repair. *Sports Med Arthrosc Rehabil Ther Technol*. 2010;2:15. <http://dx.doi.org/10.1186/1758-2555-2-15>.
- Neviaser JS. Treatment of old unreduced dislocations of the shoulder. *Surg Clin North Am*. 1963;43:1671–1678.
- Rockwood C, Green DP. *Fracture*. Philadelphia: JB Lippincott; 1975:710–718.
- Wilson JC, McKeever FM. Traumatic posterior dislocation of the humerus. *J Bone Jt Surg Am*. 1949;31:160–172.
- Goga IE. Chronic shoulder dislocations. *J Shoulder Elb Surg*. 2003;12:446–450.
- Mansat P, Guity MR, Mansat M, et al. Chronic anterior shoulder dislocation treated by open reduction sparing the humeral head. *Rev Chir Orthop Reparatrice Appar Mot*. 2003;89:19–26.
- Perniceni T, Augereau B, Apoil A. Treatment of old unreduced anterior dislocations of the shoulder by open reduction and a reinforced rib graft. Discussion of 3 cases. *Ann Chir*. 1982;36:235–239.
- Gosset J. A technic for coraco-glenoid grafting in the treatment of recurrent dislocations of the shoulder. *Mem Acad Chir*. 1960;86:445–447.
- Burkhart SS, Danaceau SM. Articular arc length mismatch as a cause of failed bankart repair. *Arthroscopy*. 2000;16:740–744.
- Armitage MJ, Faber KJ, Drosdowech DS, et al. Humeral head bone defects: remplissage, allograft and arthroplasty. *Orthop Clin North Am*. 2010;41:417–425. <http://dx.doi.org/10.1016/j.ocl.2010.03.004>.
- Degen RM, Giles JW, Johnson JA, et al. Remplissage versus Latarjet for engaging Hill-Sachs defects without substantial glenoid bone loss: a biomechanical comparison. *Clin Orthop Relat Res*. 2014;(472):2363–2371. <http://dx.doi.org/10.1007/s11999-013-3436-2>.
- Patte D, Bernageau J, Bancel P. The anteroinferior vulnerable point of the glenoid rim. In: Bateman JE, Welsch RP, eds. *Surgery of the Shoulder*. New York: NY Marcel Dekker; 1985:94–99.
- Burkhart SS, De Beer JF, Barth JR, et al. Results of modified Latarjet reconstruction in patients with anteroinferior instability and significant bone loss. *Arthroscopy*. 2007;23:1033–1041.
- Gavriilidis I, Magosch P, Lichtenberg S, et al. Chronic locked posterior shoulder dislocation with severe head involvement. *Int Orthop*. 2010;34:79–84. <http://dx.doi.org/10.1007/s00264-009-0762-9>.