

Standardized Combined Plant Extract, RUG-com, Reduces Bacterial Levels and Suppresses Acute and Chronic Inflammation in Balb/c Mice Infected with CagA⁺ *Helicobacter pylori*.

Young Ik Lee¹, Jong Seok Kim², Jin Sook Cho¹, Hyun Kyu Kim³, and Ahtesham Hussain¹

¹Lee's Biotech Co., Ltd., Daejeon 34013, Korea

²Myunggok Medical Research Institute, College of Medicine, Konyang University, Daejeon 35365, Korea

³Kolmar BNH Co., Ltd., Sejong 30003, Korea

ABSTRACT: *Helicobacter pylori* are etiological agents in the development of gastritis, gastroduodenal ulcers, gastric cancer, and mucosa-associated lymphoid tumors. Our previous investigations demonstrated that standardized combined plants extracts (*Rubus crataegifolius* and *Ulmus macrocarpa*) inhibit the growth of *H. pylori* in *in vitro* experiments. Also, we demonstrated that *Gardenia jasminoides* is effective in preventing gastritis and gastric ulcers in animal experiments. In the present work, we tested the standardized combined three plant extract (RUG-com) on the mouse model of *H. pylori* infectious disease to examine the effects of RUG-com on both the prevention and curing on the stomachs of infected mice. After the final administrations, biopsy samples of gastric mucus were assayed for bacterial numbers, biochemical analysis, inflammatory scores, and histology. Treatment with standardized plants extracts, single or combined, reduced the *H. pylori* load compared with the control. Treatment also significantly ($P < 0.05$) reduced both acute and chronic mucosal and subacute inflammation, and epithelial cell degeneration and erosion induced by *H. pylori* infection. Further investigations demonstrated that *H. pylori*-induced inflammation was decreased by RUG-com extracts via down regulating cyclooxygenase-2 and inducible nitric oxide synthase pro-inflammatory gene expression. Our results suggest that RUG-com is useful to prevent *H. pylori* infection, *H. pylori*-induced inflammation and associated gastric damage.

Keywords: *Helicobacter pylori*, plant extracts RUG-com, anti-inflammation, gastritis, gastric lesion

INTRODUCTION

Helicobacter pylori is an etiological agent involved in the development of gastritis (National Institutes of Health, 1994), gastric ulcers (van der Linden, 1994), and gastric neoplasia, including gastric adenoma and gastric mucosa-associated lymphoid tissue lymphoma (Nakhaei, 2011; Mégraud and Lehours, 2007).

The prevalence of *H. pylori* is highly variable in relation to geography, ethnicity, age, and socioeconomic factors. *H. pylori* are a highly heterogeneous bacterial species, with high degree of genotypic and phenotypic heterogeneities, and are highly adapted for survival in the gastric niche (Haley and Gaddy, 2015). Following ingestion, the bacteria evade bactericidal activity of the gastric luminal contents and enter the mucus layer. After infection, *H. pylori* cause persistent infection and chronic inflammation in the majority of infected individuals (White et al., 2015).

A recent study showed that *H. pylori* infection increases the expression of cyclooxygenase-2 (COX-2) and inducible nitric oxide synthase (iNOS) in patients with gastric lesions, gastric infections, and gastric neoplasia (Zhang et al., 2015). Interleukin (IL)-17 and 18 are induced by *H. pylori* and demonstrate important roles in gastric mucosal inflammations and gastric cancer (Wang et al., 2014; Zhang et al., 2017).

As first line treatment for *H. pylori* infection, standard triple therapy, a proton pump inhibitor (PPI), clarithromycin and amoxicillin, metronidazole, or bismuth-based quadruple therapy (bismuth with PPI and two antibiotics) are recommended (Liou et al., 2016a). However, these therapies are not always effective. Despite the large number of studies, identifying an optimal regimen for *H. pylori* treatment remains a challenging clinical problem (Wang et al., 2014). Based on previous systematic reviews and meta-analyses, the primary causes of therapeutic failure

Received 10 July 2019; Accepted 23 August 2019; Published online 31 December 2019

Correspondence to Young Ik Lee, Tel: +82-42-860-4150, E-mail: yilee@kribb.re.kr
Author information: Jong Seok Kim (Professor)

Copyright © 2019 by The Korean Society of Food Science and Nutrition. All rights Reserved.

© This is an Open Access article distributed under the terms of the Creative Commons Attribution Non-Commercial License (<http://creativecommons.org/licenses/by-nc/4.0>) which permits unrestricted non-commercial use, distribution, and reproduction in any medium, provided the original work is properly cited.

are *H. pylori* resistance to antibiotics (Liou et al., 2016b). Since the adverse side effects of drug resistance and complications also occur beside antibiotics resistance, alternative medicines for eradication of *H. pylori* have been suggested, including those that include traditional usage of naturally occurring medicinal plants. Nature has been a source of medicinal agents since antiquity to date and an impressive number of modern drugs are isolated from natural sources (Cragg and Newman, 2005). Complementary and alternative modes of treatment, particularly non-toxic, natural, and inexpensive products, are attractive.

The Korean plants *Rubus crataegifolius* (RF) and *Ulmus macrocarpa* Hance (UL) show synergistic anti-*Helicobacter* effects *in vitro*, whereas *Gardenia jasminoides* (GJ) shows gastroprotection against various types of mucosal damage (Park et al., 2019). These plants may encourage researchers to explore their potential in novel therapies, such as phytotherapy, as an alternative approaches to cure *H. pylori*, or in novel alimentary regimens such as a plant-based diet containing compounds with chemoprotective and chemopreventive effects. Therefore, the aim of the present study was to investigate the anti-*H. pylori* and gastroprotective properties of combined three plant extracts (RUG-com) using an animal model of *H. pylori* infection.

MATERIALS AND METHODS

Ethical statement

All procedures were performed in compliance with the regulations and guiding principles of the care of animals, Animal Welfare Committee and Ethics Committee of Korea Research Institute of Bioscience and Biotechnology, Daejeon, Korea (KRIBB-AC-18176).

Reagents

Dimethyl sulfoxide, ethanol, formalin, HCl, amoxicillin, clarithromycin, omeprazole, and cimetidine were purchased from Sigma Aldrich Inc. (St. Louis, MO, USA). Roswell Park Memorial Institute 1640, fetal bovine serum (FBS), and trypsin-ethylenediaminetetraacetic acid were obtained from Invitrogen (Waltham, MA, USA). Brucella agar medium were purchased from Becton and Dickinson Company (Sparks, MD, USA). Assay kits for COX-2 and iNOS were from Jackson ImmunoResearch Inc. (West Grove, PA, USA). All other reagents were pharmaceutical or analytical grade.

Plant materials and preparation of extracts

The unripened fruit of RF, the stem bark of UL, and ripened fruit of GJ were purchased from Kyung Dong Medicinal Herb market (Seoul, Korea). The plant samples were kept in the herbarium of the Korea Research Institute of Bioscience and Biotechnology (KRIBB). The experimen-

tal extracts UL, RF, RF+UL, and RF+UL+GJ were obtained, concentrated, and prepared into an SD-spray by Sam Woo-Dayeon Company (Geumsan, Korea).

High performance liquid chromatography (HPLC) for standardization of RF, UL, and GJ

The unripened fruit of RF, the stem bark of UL and the ripened fruit of GJ were extracted separately with ethanol or hot water in round bottom flasks. The extracts were filtered (No. 1, Whatman, Little Chalfont, UK) and concentrated under vacuum, and the samples were dried. Each 50 mg sample (in powder form) were dissolved in water and then sonicated for 30 min. After that samples were filtered through a 0.22 μm polytetrafluoroethylene syringe filter. The filtrates were injected into the HPLC for analysis.

Quantification of RF, GJ, and UL was carried out using a HPLC analysis system (Agilent technologies 1260 Infinity, Agilent Technologies, Santa Clara, CA, USA) equipped with auto sampler (G1329B) and UV (G1316A) detector (Agilent Technologies). Chromatographic separations were achieved at 35°C using reverse-phase C18 (4.6 \times 150 mm, 5 μm) column with flow rate 0.8 mL/min, with a 10 μL injection volume. The wavelengths used for detection were 254 nm for the ellagic acid and geniposide, and 280 nm for catechin-7-*O*- β -D-apiofuranoside. Mobile phases were prepared as 0.1% aqueous trifluoroacetic acid (A) and acetonitrile (B) for ellagic acid and geniposide, and water/acetonitrile (95:5) (A) and water/acetonitrile (5:95) (B) for catechin-7-*O*- β -D-apiofuranoside analysis. The contents of ellagic acid, geniposide, and catechin-7-*O*- β -D-apiofuranoside were calculated for standardization. The contents were 14.2 mg/g, 15.6 mg/g, and 30.5 mg/g, respectively.

H. pylori strains and growth condition

Two reference strains (ATCC-43504, SS1), obtained from American Type Tissue Culture Collection (ATCC, Manassas, VA, USA), and four clinically isolated strains, obtained from the Department of Microbiology, Gyeongsang National University in Korea, were used for antibacterial assay. *H. pylori* [1×10^8 colony-forming unit (CFU), equivalent to 1 McFarland turbidity standard unit] were seeded in Brucella media containing 10% defibrinated FBS, and were incubated for 24 h in a 37°C incubator (85% N₂, 10% CO₂, and 5% O₂). After 3 days of incubation, the number of colonies was counted. Amoxicillin was used as a positive control.

Animals

Male Balb/c and C57BL/6 mice of weight 30~40 g were purchased from Orient Bio Animal Laboratories (Gyeonggi, Korea). Animals were acclimatized to standard laboratory conditions (24 \pm 2°C, 45 \pm 5% humidity, and 12-h

light/dark cycle) for 7 days.

***H. pylori* infection in C57BL/6 mice**

Following a pre-feeding period of one week, 100 mice were randomly divided into the following 10 groups: uninfected (negative control 1), *H. pylori* infection alone (negative control 2 and 3), triple antibiotics [ampicillin (AMX)+clarithromycin (CML)+omeprazole (OMP)], sample 1, RF (150 mg/kg), UL (150 mg), GJ (150 mg), RF+UL (75+75 mg/kg), RF+GJ (75+75 mg/kg), and RF+UL+GJ (75+25+50 mg/kg) treatment in *H. pylori* infected groups (samples 2~7, respectively). In this case, pathogen-free C57BL/6 male mice were inoculated 3 times by an oral gavage with CagA⁺ *H. pylori* SS1 (2×10^8 CFU/mouse). After 4 weeks, the level of *H. pylori* infection was assessed and mice were treated with plant extracts for 4 weeks.

Detection of *H. pylori* in infected stomach tissue

The presence of *H. pylori* in gastric mucosa was confirmed by direct bacterial culture, as previously described (Wittschier et al., 2009). For bacterial culturing, the tissue was rubbed across the surface of a plate with selective medium containing 10% bovine serum, 6 µg/mL vancomycin, 5 µg/mL trimethoprim, 10 µg/mL polymyxin B, 200 µg/mL bacteriocin, 8 µg/mL amphotericin B, and 10 µg/mL nalidixic acid. Plates were incubated at 37°C under microaerophilic conditions for 5~7 days. For quantitative analysis of *H. pylori* colonization, stomach tissue was homogenized in 200 µL Brucella broth by a hand homogenizer and the homogenate was diluted 10- and 100-fold in Brucella broth. Ten microliters of each dilution were plated on selective medium containing the antibiotics mentioned above. Plates were incubated at 37°C under microaerophilic conditions for 5 days. *H. pylori* strains were identified by gram staining and positive urease tests. *H. pylori* colonies were then counted to determine the number of CFU in the whole stomach tissue (Ricci et al., 2007).

Western blot analysis

The stomach tissue from each animal was homogenized using the bullet blender homogenization kit (Advance Inc., Newark, DE, USA). Tissue extracts were centrifuged at 13,000 rpm for 20 min at 4°C to remove insoluble materials. The total concentrations of extracted protein were determined using Bradford assays (PierceTM Detergent Compatible Bradford Assay Kit, Thermo Fisher Scientific, Waltham, MA, USA). Aliquots of each protein sample (50 µg) were separated on 8% sodium dodecyl sulfate polyacrylamide gels and transferred onto polyvinylidene fluoride membranes. After blocking for 10 min with Tris-HCl, 150 mM NaCl and 0.05% Tween-20 (TBST) (pH 7.6) containing 5% skim milk for 1 h at room

temperature (RT), the membranes were washed with TBST. Membranes were then incubated with diluted primary antibodies, including anti-iNOS and anti-COX-2, overnight at 4°C. The blots were subsequently incubated with horseradish peroxidase-conjugated goat anti-rabbit IgG (Jackson ImmunoResearch Inc.) for 1 h at RT. Blots were washed three times with TBST buffered saline, and the immunoreactive protein bands were visualized with enhanced chemiluminescence (Thermo Fisher Scientific).

Histopathological examinations

The stomach tissue samples of Balb/c mice were fixed in 10% buffered formaldehyde, embedded in paraffin, and sectioned. Sections 3~4 µm thick were stained with hematoxylin and eosin (H&E) and Giemsa for histological observations (Ricci et al., 2007; Wang et al., 2015). For H&E staining, sections were stained with hematoxylin for 3 min, washed and then stained with 0.5% eosin for 3 min. After washing with water, the slides were dehydrated in 70%, 90%, and 100% ethanol, and then in xylene. The degree of inflammation was assessed by microscopic observation and was expressed as described previously (Gibson-Corley et al., 2013): none (score 0; normal appearance of scattered inflammatory cells on the lamina propria, the same degree as in uninfected control mice), mild (score 1; moderate infiltration epithelium), moderate (score 2; moderate infiltration of inflammatory cells in the lamina propria and the submucosa and erosions in some parts of the epithelium), and severe (score 3; severe infiltration of inflammatory cells in the lamina propria and the submucosa erosions in many parts of the epithelium). For detection of *H. pylori* in the gastric epithelium, Giemsa staining was used. *H. pylori* on the gastric epithelium mucosa was shown by the appearance of blue spots. To score inflammation, the number of neutrophils and mononuclear cells infiltrating the lamina propria were counted in five high-power fields ($\times 200$ magnification). The density of the mononuclear cells and polymorphonuclear leukocytes in the lamina propria or submucosal layers were also scored using updated Sydney systems (Jang and Kim, 2013).

Statistical analysis

All experiments were performed three times. Data were expressed as means and the statistical significance was calculated by analysis of variance followed by unpaired Student's *t*-tests. The differences were considered statistically significant at *P*-values less or equal to 0.05.

RESULTS AND DISCUSSION

Treatment of *H. pylori* infection at the early stage reduces colonization and prevents gastric carcinogenesis. The an-

ti-*H. pylori* effects of several plants, including turmeric, parsley, borage, ginseng, and cranberry, have attracted much interest for studying the associated mechanisms (De et al., 2009; Bae et al., 2014; Debraekeleer and Remant, 2018). In the present study, we examined anti-*H. pylori* activity and gastroprotective effects of the plant extract RUG-com, in the established C57BL/6 mouse model of *H. pylori* infection. The quantities of RF, GJ, and UL used in the experiments were standardized by determining the amounts of ellagic acid, geniposide, and catechin-7-*O*- β -D-apiofuranoside using HPLC chromatography (Fig. 1).

For *H. pylori* infection experiments, test animals were fasted for 24 h and then *H. pylori* cultures were orally in-

oculated (2×10^8 CFU, $n=10$ for each group) three times, as shown in Fig. 2. The extent of *H. pylori* infection was assessed after 4 weeks; *H. pylori* infection was analyzed by *H. pylori* colonization and histological analysis (Fig. 2 and 3). After verifying *H. pylori* infection, plant extracts were administered for 4 weeks to analyze anti-*H. pylori* effects (Fig. 1). At 8 weeks after the inoculation with *H. pylori*, all animals were sacrificed under ether anesthesia; mouse stomachs were removed, opened along the greater curvature, and washed twice with saline. Stomachs were analyzed by direct observations and quantitative analysis of *H. pylori* colonization (Table 1). Half of the stomach was used for the histological analysis and inflammatory scoring, while half were used for detecting *H. pylori* (Fig.

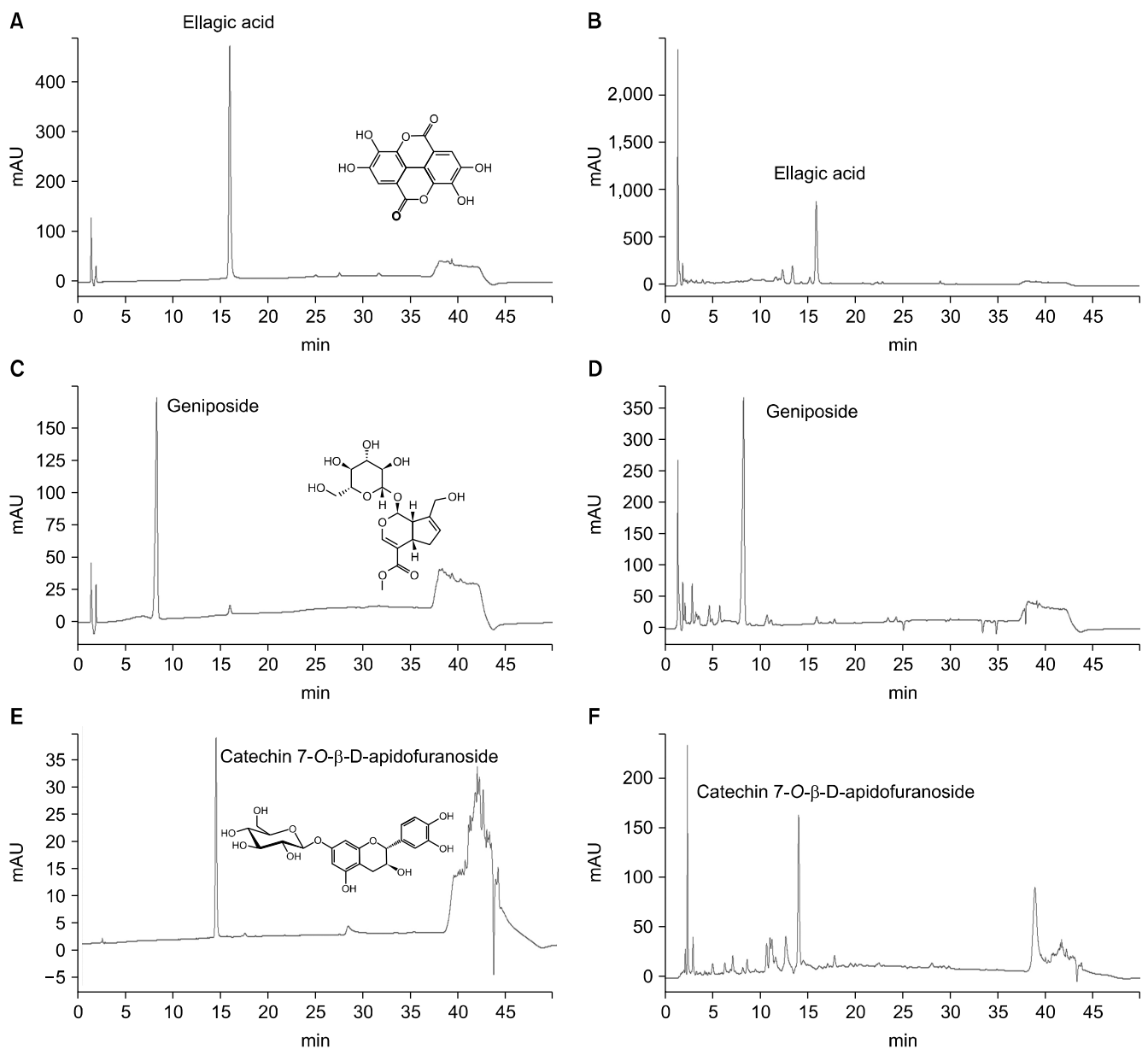


Fig. 1. High-performance liquid chromatography–diode-array detector chromatogram for sample standardization. (A) Ellagic acid standard at 254 nm, (B) *Rubus crataegifolius* extracts, (C) geniposide standard at 254 nm, (D) *Gardenia jasminoides* extracts, (E) catechin-7-*O*- β -D-apiofuranoside at 280 nm, and (F) *Ulmus macracarpa* extracts. The contents were standardized to contain 14.2 mg/g, 15.6 mg/g, and 30.5 mg/g, respectively.

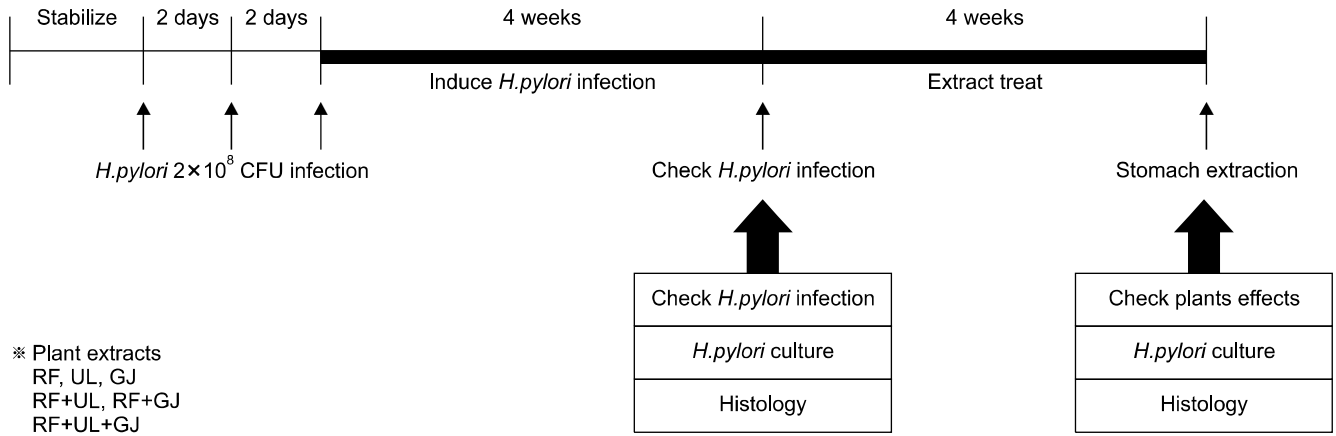


Fig. 2. Experimental schedule for *in vivo* evaluation of efficacy of plant extracts on anti-*Helicobacter pylori* activity. Time-points of *H. pylori* infection and plants extracts treatment in Balb/c mice. Balb/c mice were orally administered with *H. pylori* (2.0×10⁸ CFU) three times over 4 days. After 4 weeks, *H. pylori* treated mice were assessed for infection by sacrificing, followed histology analysis of *H. pylori* cultures. After confirming *H. pylori* infection, mice received plant extracts 4 weeks for recovery from *H. pylori* infection, as assessed by *H. pylori* counting and histology analysis. RF, *Rubus crataegifolius*; UL, *Ulmus macrocarpa* Hance; GJ, *Gardenia jasminoides* Ellis; OMP, omeprazole; AMX, ampicillin; CLM, clarithromycin; CFU, colony-forming unit.

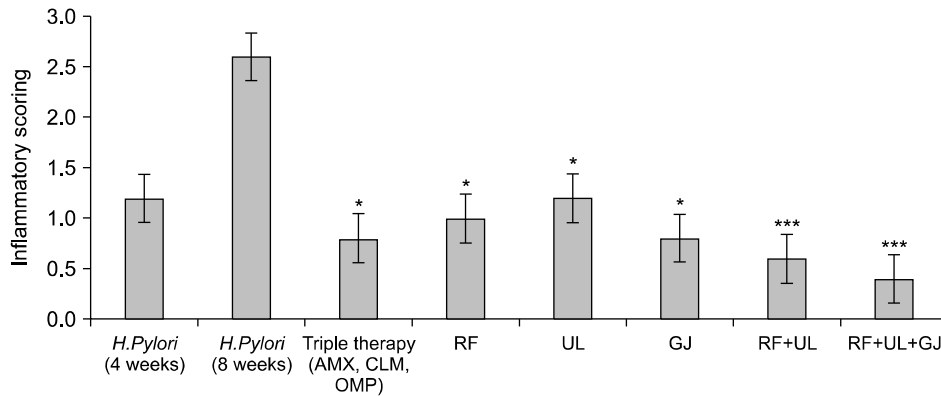


Fig. 3. Inflammatory scores of the stomachs of *Helicobacter pylori* infected Balb/c mice treated with single or complex plant extracts. Mouse stomach sections were stained with hematoxylin and eosin and graded to determine the amount of lymphocyte infiltrations. (This work was carried out by Dr. Moon Hyung Bae at Wonkwang Medical School, Iksan, Korea). RF, *Rubus crataegifolius*; UL, *Ulmus macrocarpa* Hance; GJ, *Gardenia jasminoides* Ellis; AMX, ampicillin; CLM, clarithromycin; OMP, omeprazole. The results were compared by Student's *t*-test (**P*<0.05 and ****P*<0.001). The error bars represent the SD.

Table 1. Inhibitory growth effect of plant extracts on *Helicobacter pylori* growth in *H. pylori*-infected Balb/c mice

Experimental groups	Conditions	Log ₁₀ CFU/stomach
Negative control 1	—	—
Negative control 2	<i>Helicobacter pylori</i> infection (4 weeks)	2.0×10 ⁸ CFU
Negative control 3	<i>H. pylori</i> infection (8 weeks)	2.0×10 ⁸ CFU
Sample 1	AMX+CLM+OMP	138+30+30 mg/kg
Sample 2	RF	150 mg/kg
Sample 3	UL	150 mg/kg
Sample 4	GJ	150 mg/kg
Sample 5	RF+UL	75+75 mg/kg
Sample 6	RF+GJ	75+75 mg/kg
Sample 7	RF+UL+GJ	75+25+50 mg/kg

RF, *Rubus crataegifolius*; UL, *Ulmus macrocarpa* Hance; GJ, *Gardenia jasminoides* Ellis; AMX, ampicillin; CLM, clarithromycin; OMP, omeprazole; CFU, colony-forming unit.

3, 4, and Table 1). The colonies grown on selective medium were identified as *H. pylori* by Gram staining and urease activities. In the infected group (Table 1; control

2, 3, and sample 1~7), all animals were successfully colonized with *H. pylori*, but no *H. pylori* colonies were detected in the uninfected control group (Table 1; control

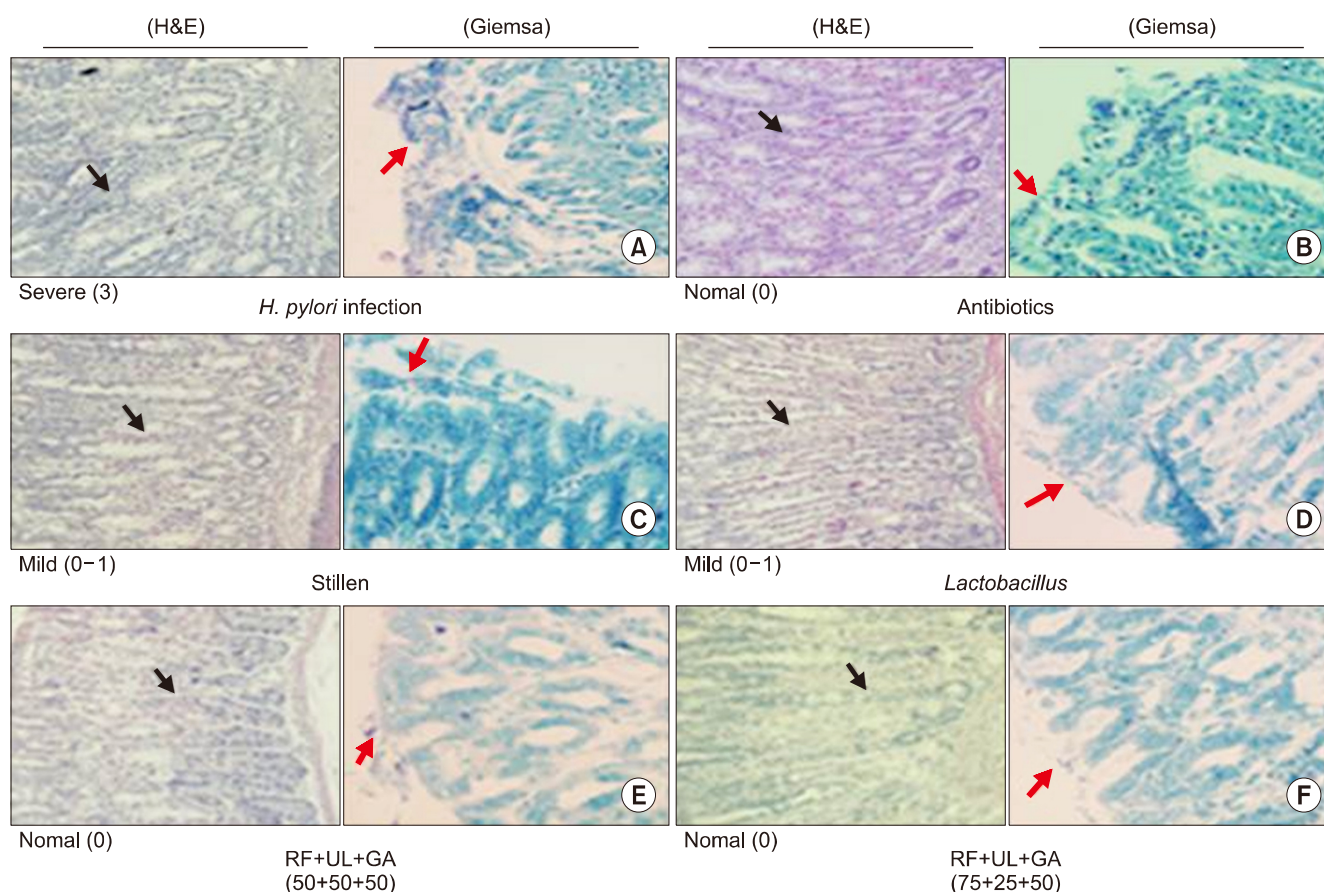


Fig. 4. Histological analysis (magnification $\times 40$). *Helicobacter pylori*-induced gastritis showed increased amounts of immune cells in the mouse stomachs (A. *H. pylori* infection). Treatment with and antibiotics (B) and plants extract (E and F) protected against inflammation. Stillen (C) and lactobacillus (D) were used as positive controls. In Giemsa staining, blue spots showed the presence of *H. pylori*. H&E, haematoxylin and eosin; RF, *Rubus crataegifolius*; UL, *Ulmus macrocarpa* Hance; GJ, *Gardenia jasminoides* Ellis.

1). By comparing control 2 and 3, gradual increase in the amounts of *H. pylori* were demonstrated, while decreasing numbers of *H. pylori* were detected after treating mice with plant extracts (RF, UL, and GJ) or combined plant extracts (RF+UL, RF+GJ, and RF+UL+GJ) (Table 1). All extracts were standardized with indicator substances (ellagic acid, geneposide, and catechin-7-O- β -D-apiofuranoside using HPLC chromatograms (Fig. 1). The RF group showed stronger anti-*H. pylori* effects compared with the UL or GJ groups (7.5×10^3 CFU vs. 4.3×10^4 CFU and 3.2×10^5 CFU/stomach, respectively). Moreover, the RF+UL (75+75 mg/kg) group (sample 5) showed stronger anti-*H. pylori* effect than other group (sample 6 and 7) (Table 1).

The degree of inflammation, expressed as score 0, 1, 2, and 3, was added to stained samples H and E (Fig. 3). Stomachs of mice infected with *H. pylori* showed severe infiltration of inflammatory cells in the lamina propria and the submucosa erosions in many parts of epithelium (Fig. 3, score 3; *H. pylori* infection) however, samples treated with triple antibiotics showed a normal appearance of scattered inflammatory cells on the lamina propria (the same degree as in uninfected control mice) (Fig. 3, score 0; antibiotics). For the two RF+UL+GJ group,

both samples showed a normal appearance of scattered inflammatory cells on the lamina propria (score 0) (Fig. 3). These results suggest that RF+UL+GJ treatment protect against *H. pylori*-induced severe (score 3) gastric status to restore normal (score 0) status; this therefore shows a protective role of RUG-com on *H. pylori* infection and related gastric damages (Fig. 3). Through Giemsa staining of mouse stomachs, we also observed decreasing amounts of *H. pylori* in stomachs treated with natural products (Fig. 3). Stillen and *Lactobacillus plantarum* were used a positive controls, since both show anti-*H. pylori* effects.

Inflammatory scoring of mouse stomachs showed treatment with plant extracts, in particular RF+UL+GJ, decreased the inflammatory score (Fig. 4). The stomach is an immunocompetent organ that is normally populated by a small number of inflammatory cells (T and B lymphocytes, macrophages, and mast cells). The immune response of the stomach is primarily T-cell mediated and this class of lymphocytes represents 90% of stomach lymphocytes both in epithelial and stromal compartments (Ricci et al., 2007). To determine whether RUG-com extracts have anti-inflammatory effects, we examined expression of COX-2 and iNOS in *Helicobacter*-infected

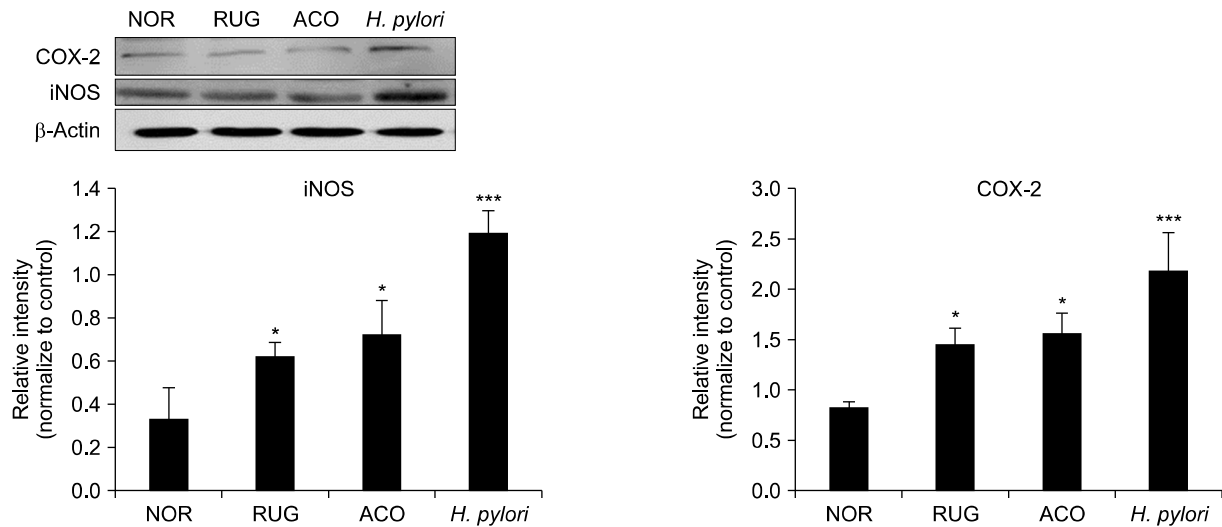


Fig. 5. Effect of standardized combined three plant extract (RUG-com) administration on expression of inducible nitric oxide synthase (iNOS) and cyclooxygenase-2 (COX-2) in the stomachs of *Helicobacter pylori* infected Balb/c mice. The expression of iNOS proteins and COX-2 proteins were determined by Western blotting using specific antibodies. β -Actin was used as an internal control. NOR, control group; RUG, RUG-com treated group; ACO, triplet antibiotics treated group; *H. pylori*, *H. pylori* treated group. The results were compared by Student's *t*-test (* $P < 0.05$ and *** $P < 0.005$). The error bars represent the SD.

mouse stomachs. iNOS was identified as the factor that generates reactive nitrogen species which cause cell damage (Gandhi et al., 2017; Morteau, 2000). COX-2 has been detected in all inflammatory cells in the epithelium and interstitial spaces, and is upregulated in proliferative inflammatory lesions of stomachs from *H. pylori*-infected mice (Tripathi et al., 2007). Many experimental reports have shown that COX-2 derived prostaglandin E2 is associated with increased inflammation, increased angiogenesis, greater metastatic and proliferative invasion, and reduced apoptosis (Morteau, 2000; Hämäläinen et al., 2008). Based on these findings, we examined the protein levels of iNOS and COX-2 in the stomach tissues of *H. pylori*-infected mice in order to investigate the effects of LC extracts on inflammation. As shown in Fig. 5, Western blot analysis revealed an increase in iNOS and COX-2 protein levels in the *H. pylori*-infected group, compared with the control group. However, the groups treated with AMX+CLM+OMP antibiotics and RUG-com exhibited decreased levels of iNOS and COX-2 protein. These results confirm that RUG-com shows anti-inflammatory effect in the stomachs of *H. pylori*-infected mice.

From our present observations, we determined that oral treatment with plant extracts significantly enhances anti-*H. pylori* effects, as shown in the antibiotic triplex (AMX+CLM+OMP) treated group. For this reason, plant extracts, especially *Rubus* containing mixed extracts, may show potential as a safe resource to control *H. pylori* infection and associated gastric diseases. Our results demonstrate that RUG-com treatment significantly reduces *H. pylori* colonization in the gastric mucus and shows gastric mucosal protection. These results are suggestive that RUG-com is useful for preventing *H. pylori* infection and

associated gastric damage.

ACKNOWLEDGEMENTS

This work was financially supported by Small and Medium Business Administration and Lee's Biotech Company, Korea.

AUTHOR DISCLOSURE STATEMENT

The authors declare no conflict of interest.

REFERENCES

- Bae M, Jang S, Lim JW, Kang J, Cha JH, Kim H. 2014. Protective effect of Korean red ginseng extract against *Helicobacter pylori*-induced gastric inflammation in Mongolian gerbils. *J Ginseng Res.* 2014. 38:8-15.
- Cragg GM, Newman DJ. International collaboration in drug discovery and development from natural sources. *Pure Appl Chem.* 2005. 77:1923-1942.
- De R, Kundu P, Swarnakar S, Ramamurthy T, Chowdhury A, Nair GB, et al. Antimicrobial activity of curcumin against *Helicobacter pylori* isolates from India and during infections in mice. *Antimicrob Agents Chemother.* 2009. 53:1592-1597.
- Debraekeleer A, Remant H. Future perspective for potential *Helicobacter pylori* eradication therapies. *Future Microbiol.* 2018. 13:671-687.
- Gandhi J, Khera L, Gaur N, Paul C, Kaul R. Role of modulator of inflammation cyclooxygenase-2 in gammaherpesvirus mediated tumorigenesis. *Front Microbiol.* 2017. 8:538.
- Gibson-Corley KN, Olivier AK, Meyerholz DK. Principles for valid histopathologic scoring in research. *Vet Pathol.* 2013. 50: 1007-1015.

- Haley KP, Gaddy JA. 2015. Metalloregulation of *Helicobacter pylori* physiology and pathogenesis. *Front Microbiol.* 2015. 6:911.
- Hämäläinen M, Lilja R, Kankaanranta H, Moilanen E. Inhibition of iNOS expression and NO production by anti-inflammatory steroids. Reversal by histone deacetylase inhibitors. *Pulm Pharmacol Ther.* 2008. 21:331-339.
- Jang SH, Kim KM. Assessment of gastritis using operative link for gastritis assessment system. *Korean J Helicobacter Up Gastrointest Res.* 2013. 13:20-24.
- Liou JM, Chen CC, Chang CY, Chen MJ, Chen CC, Fang YJ, et al. Sequential therapy for 10 days versus triple therapy for 14 days in the eradication of *Helicobacter pylori* in the community and hospital populations: a randomised trial. *Gut.* 2016a. 65:1784-1792.
- Liou JM, Wu MS, Lin JT. Treatment of *Helicobacter pylori* infection: where are we now?. *J Gastroenterol Hepatol.* 2016b. 31:1918-1926.
- Mégraud F, Lehours P. *Helicobacter pylori* detection and antimicrobial susceptibility testing. *Clin Microbiol Rev.* 2007. 20:280-322.
- Morteau O. Prostaglandins and inflammation: the cyclooxygenase controversy. *Arch Immunol Ther Exp.* 2000. 48:473-480.
- Nakhaei MM. *In vitro* Inhibition of *Helicobacter pylori* by some spices and medicinal plants used in Iran. *Global J Pharmacol.* 2011. 5:176-180.
- National Institutes of Health. *Helicobacter pylori* in peptic ulcer disease. NIH Consens Statement. 1994. 12:7-9.
- Park JU, Kang JH, Abdur Rahman MA, Hussain A, Cho JS, Lee YI. Gastroprotective effects of plants extracts on gastric mucosal injury in experimental Sprague-Dawley rats. *BioMed Res Int.* 2019. 2019:8759708.
- Ricci C, Holton J, Vaira D. Diagnosis of *Helicobacter pylori*: invasive and non-invasive tests. *Best Pract Res Clin Gastroenterol.* 2007. 21:299-313.
- Tripathi P, Tripathi P, Kashyap L, Singh V. The role of nitric oxide in inflammatory reactions. *FEMS Immunol Med Microbiol.* 2007. 51:443-452.
- van der Linden B. *Helicobacter pylori* in gastroduodenal disease. *Curr Opin Infect Dis.* 1994. 7:577-581.
- Wang F, Meng W, Wang B, Qiao L. *Helicobacter pylori*-induced gastric inflammation and gastric cancer. *Cancer Lett.* 2014. 345: 196-202.
- Wang YK, Kuo FC, Liu CJ, Wu MC, Shih HY, Wang SS, et al. Diagnosis of *Helicobacter pylori* infection: current options and developments. *World J Gastroenterol.* 2015. 21:11221-11235.
- White JR, Winter JA, Robinson K. Differential inflammatory response to *Helicobacter pylori* infection: etiology and clinical outcomes. *J Inflamm Res.* 2015. 8:137-147.
- Wittschier N, Faller G, Hensel A. Aqueous extracts and polysaccharides from liquorice roots (*Glycyrrhiza glabra* L.) inhibit adhesion of *Helicobacter pylori* to human gastric mucosa. *J Ethnopharmacol.* 2009. 125:218-223.
- Zhang H, Ding C, Suo Z, Kang Y. Effect of *Helicobacter pylori* on cyclooxygenase-2 and inducible nitric oxide synthase in patients with gastric precancerous lesions and its clinical significance. *Exp Ther Med.* 2015. 9:2364-2368.
- Zhang XY, Zhang PY, Aboul-Soud MAM. From inflammation to gastric cancer: role of *Helicobacter pylori*. *Oncol Lett.* 2017. 13: 543-548.