

Evaluation of estrogen expression of breast cancer using ¹⁸F-FES PET CT-A novel technique

ABSTRACT

Estrogen receptor (ER) expression in breast cancer is routinely studied on immunohistochemistry (IHC) of tissue obtained from core biopsy or surgical specimen. Sampling error and heterogeneity of tumor may incorrectly label a breast tumor as ER negative, thus denying patient hormonal treatment. Molecular functional ER imaging can assess the *in-vivo* ER expression of primary tumor and metastases at sites inaccessible for biopsy and also track changes in expression over time. The aim was to study ER expression using 16 α -¹⁸F-fluoro-17 β -estradiol or ¹⁸F-fluoroestradiol (¹⁸F FES) positron emission tomography (PET) computed tomography (CT). Twenty-four biopsy-proven breast cancer patients consenting to participate in the study underwent FES PET CT. Standard uptake value (SUV_{mean}) of maximum of 7 lesions/patient was analyzed, and tumor-to-background ratio was calculated for each lesion. Visual interpretation score was calculated for lesion on FES PET and correlated with the Allred score on IHC of tumor tissue samples for ER expression. The diagnostic indices of FES PET CT were assessed taking IHC as "gold standard." On FES PET CT, the mean SUV for ER+ tumors was 4.75, whereas the mean SUV for ER- tumors was 1.41. Using receiver operating characteristic curve, tumors with an SUV of ≥ 1.8 on FES PET could be considered as ER+. The overall accuracy of FES PET CT to detect ER expression was 91.66%, with two false negatives noted in this study. ¹⁸F-FES PET CT appears promising in evaluating ER expression in breast cancer. It is noninvasive and has potential to assess the *in-vivo* ER expression of the entire primary tumor and metastasis not amenable for biopsy.

Keywords: Breast cancer, estrogen receptor, fluoroestradiol positron emission tomography, positron emission tomography

INTRODUCTION

Breast cancer has been routinely staged in the clinical practice according to the American Joint Committee on Cancer (AJCC)/tumor node metastasis (TNM) classification. Over the past few years, it has been learned that the status of estrogen receptor (ER)/progesterone receptor (PR) as well as Her2/neu is known to affect the prognosis of breast cancer that is independent of tumor staging. The evolving knowledge of breast cancer biology and increased validation of these biomarkers of prognosis as well as prediction of response to treatment suggest that these biomarkers should be documented at the time of initial diagnosis. With these points in view, the recently revised AJCC 8th edition has tabulated the prognostic TNM staging classification that incorporates the anatomical TNM stage as well as the status of ER/PR and Her2/neu. Immunohistochemistry (IHC)


of tumor tissue obtained by core biopsy/wide local excision or mastectomy has been the conventional method of evaluating ER and PR expression in breast cancer. However, this conventional method of ER evaluation is associated with

VUTHALURU SEENU, ANKIT SHARMA, RAKESH KUMAR¹, SUHANI SUHANI, ARUN PRASHANTH¹, SANDEEP MATHUR², RAJINDER PARSHAD

Departments of Surgical Disciplines, ¹Nuclear Medicine and ²Pathology, All India Institute of Medical Sciences, New Delhi, India

Address for correspondence: Dr. Vuthaluru Seenu, Department of Surgical Disciplines, All India Institute of Medical Sciences, Room Number 5026, Teaching Block, New Delhi, India. E-mail: varnaseenu@hotmail.com

Submission: 01-Sep-19, **Accepted:** 13-Jan-20, **Published:** 22-Jul-20

| Access this article online | |
|--|---|
| Website: www.wjnm.org | Quick Response Code  |
| DOI: 10.4103/wjnm.WJNM_71_19 | |

This is an open access journal, and articles are distributed under the terms of the Creative Commons Attribution-NonCommercial-ShareAlike 4.0 License, which allows others to remix, tweak, and build upon the work non-commercially, as long as appropriate credit is given and the new creations are licensed under the identical terms.

For reprints contact: WKHLRPMedknow_reprints@wolterskluwer.com

How to cite this article: Seenu V, Sharma A, Kumar R, Suhani S, Prashanth A, Mathur S, *et al.* Evaluation of estrogen expression of breast cancer using ¹⁸F-FES PET CT-A novel technique. World J Nucl Med 2020;19:233-9.

the inherent disadvantage of sampling error and thereby may result in the denial of hormonal therapy to some patients. There is need for a technique that can overcome this disadvantage of sampling error by studying the tumor in entirety preferably noninvasively. In addition, in certain patients with metastases, tumor in metastatic sites may not be amenable for core biopsy. Molecular imaging techniques can be ideal for this purpose. As 5-fluorodeoxyglucose (FDG) lacks the specificity for ERs, radiolabeled analog of estradiol (16α - ^{18}F -fluoro- 17β -estradiol or ^{18}F -fluoroestradiol [^{18}F -FES]) is recommended for *in-vivo* positron emission tomography (FES PET) imaging to study the ER expression of breast cancer.^[1] With these points in focus, the present study was conducted to study the ER receptor expression of breast cancer using FES PET computed tomography (CT).

MATERIALS AND METHODS

In this prospective study that was conducted after obtaining approval from the institutional ethics committee (vide ref no. T-437/26-8-15, RT-15/28.10.15), consenting patients of early/locally advanced breast cancer (LABC) above the age of 18 years were included in the study. The informed consent included that for participation in the study as well as publication of data for academic and research purposes. FES PET CT was performed after obtaining tumor tissue by core biopsy for diagnosis and ER expression was confirmed by IHC. The time interval between performing core biopsy and PET scan ranged between 2 and 3 weeks. ER positivity was scored using Allred Scoring system, and Allred score of 3 or more was considered positive. In Allred system of scoring, score 0–5 is given to the cells depending on the proportion of cells which are stained (proportion score [PS]) and score 0–3 is given depending on the intensity of staining (intensity score [IS]). By adding the PS and IS, final Allred score is calculated as follows: $\text{PS} + \text{IS} = \text{AS}$.^[2]

Standard staging investigations followed by locoregional and systemic adjuvant treatment as deemed appropriate as per institute protocol were administered to all patients.

FDG PET CT and ^{18}F FES PET CT were performed in all patients using the same protocol at a minimum interval of 24 h.

Positron emission tomography computed tomography protocol

Synthesis of fluoroestradiol

Reagents and solvents for synthesis and purification were obtained from ABX Biochemicals, Sigma Aldrich Chemical Co., Mallinckrodt Baker, Radberg, Germany, or from USP suppliers and were used without further purification unless otherwise noted. ^{18}F was produced using either a Siemens Eclipse or

a Scanditronix MC-50 cyclotron. Quality control tests were performed immediately following each synthesis to evaluate radiochemical and chemical purity and to calculate specific activity of each dose. A typical injection of FES consisted of approximately 185 MBq (5.0 mCi) (range 103.6–296 MBq [2.8–8.0 mCi]) of radiopharmaceutical in 20 mL of isotonic phosphate-buffered saline containing <15% of ethanol by volume. The mass injected per unit patient weight ($\mu\text{mol}/\text{kg}$) was also recorded.

Positron emission tomography computed tomography imaging

All imaging were performed on a GE Advance tomograph (Waukesah, WI, USA).

Patient preparation

Focused relevant history was obtained from the patients. Oncologic history, history of diabetes mellitus, results of other scanning modalities, and renal functional assessment were noted. On the day prior to the tests, the patients were advised not to do heavy physical activity, observe overnight fasting, and maintain adequate prehydration with water. On the day of test, blood glucose levels were obtained before FDG injection.

Image acquisition

After proper patient preparation, ^{18}F -FDG in the dose $10 \mu\text{Ci}/\text{kg}$ was injected intravenously into the patients. The patients were asked to wait for a period of 45 ± 15 min (uptake time of the tracer). Scanning was done on SIEMENS Biograph PET-CT (mCT True Point, Germany). First, a CT scan was performed with 64 multidetector computed tomography (MDCT) using acquisition parameters of 120 KeV voltage, 200 mA current, 0.5 s/CT rotation, pitch of 0.8 ratio (or 1.4), and 0.5-mm slice thickness. After CT acquisition, PET emission images were acquired with the acquisition parameter of 3 min per bed position in three-dimensional mode from the vertex to the mid-thigh or foot if needed (according to the patients' suspected or confirmed diagnosis). Additional views were acquired in some patients if indicated. PET images were reconstructed with iterative reconstruction algorithm using Gaussian filter. All images in each scan were corrected for scatter, attenuation, and decay.

^{18}F FES PET CT was performed at a later date with the same protocol as for FDG PET CT (minimum interval – 24 h). Dosage of tracer used for FES PET was 6–7 mCi.

Image analysis

Standard uptake value (SUV) (mean) of a maximum of 7 lesions/patient was analyzed, and tumor-to-background ratio was calculated for each lesion. Tumor-to-background ratio was calculated for each lesion by comparing the

uptake of lesion and mediastinal blood pool at the level of descending aorta. Visual interpretation score was also calculated for lesion on FES PET CT and correlated with the Allred score on IHC. Visual grading of breast lesion on FES PET CT was done as follows: Grade 1 – no uptake on FES PET CT; Grade 2 – uptake of lesion less than mediastinal blood pool; Grade 3 – uptake of lesion similar to mediastinal blood pool; Grade 4 – well-defined lesion, uptake more than mediastinal blood pool/similar to liver [Figure 1a and b].

Histopathology of breast tumors

Tumor tissue samples obtained by core biopsy were subjected to IHC for determining ER expression using standard protocol status.

The investigator in nuclear medicine department was blinded to the results of IHC.

Statistical analysis

Diagnostic indices of FES PET CT were assessed in terms of sensitivity, specificity, positive predictive value (PPV), negative predictive value (NPV), and overall accuracy taking final IHC of tumor tissue sample as “gold standard.” Statistical tests: SUV ratio (tumor to background) was correlated to the Allred score on IHC using Spearman’s coefficient. SUV ratio above which a lesion is diagnosed positive on FES PET CT was done using the receiver operating characteristic curve (ROC). Comparison between mean SUV ratio of FES and FDG PET CT was done using paired *t*-test. $P < 0.05$ was considered statistically significant.

RESULTS

Between January 2015 and June 2017, 22 female and 2 male patients of early/LABC enrolled in the Breast Cancer Clinic of the Department of Surgical Disciplines, All India Institute of Medical Sciences, were included in the study. The age range of these patients was 32–83 years (median 55 years). TNM status was as follows: T2N0: ten patients; T2N1: nine

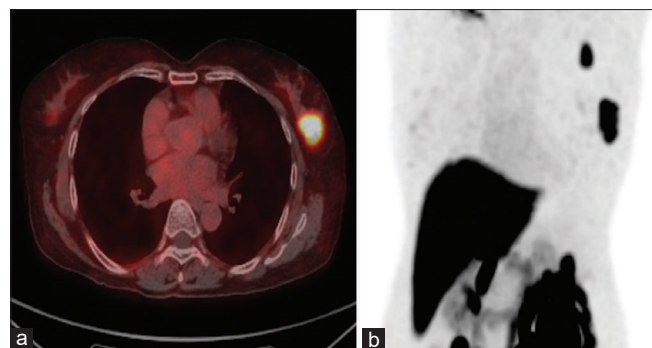


Figure 1: (a and b) Lesion in the left breast shows uptake higher than the mediastinal blood pool. Uptake is almost as high as that of the liver. Allred score on immunohistochemistry was 8/8

patients; T4bN0: one patient; and T4bN1: three patients. The details of each case with respect to FDG and FES PET CT are summarized in Table 1. One patient with clinical T4bN0 status had suspicious metastasis in D10 vertebra on FES PET CT. FDG PET CT and bone scan did not pick up the lesion. As FES PET CT has not come into routine practice, she underwent neoadjuvant chemotherapy (NACT) followed by surgery. Tumor type was invasive ductal carcinoma (no specific type) in 19 patients, invasive ductal carcinoma with ductal carcinoma *in situ* (DCIS) in two patients, and one patient each had high-grade DCIS and secretory carcinoma of the breast. On IHC, seven of these patients had ER-negative tumors and 16 had ER-positive tumors. On FDG PET CT, the mean SUV of breast lesion for ER-negative tumors was 16.19 and that for ER-positive tumors was 20.03. No statistically significant correlation was observed between SUV on FDG PET CT and ER expression by IHC of the primary tumor ($P = 0.1456$) [Table 2]. On FES PET CT, the mean SUV for ER-positive tumors was 4.75, whereas the mean SUV for ER-negative tumors was 1.41. FES PET CT and ER correlation is summarized in Table 3.

Correlation between ER and SUV of tumor, tumor-to-background ratio, and visual grading was statistically significant ($P < 0.05$), with correlation being weakest for SUV of lesion (0.5305) followed by tumor-to-background ratio (0.6640) and was strongest for visual grading (0.7737).

Using ROC curve [Figure 2], tumors with SUV of ≥ 1.8 on FES PET CT can be considered as ER+ (AUC = 0.8190, sensitivity = 73.33%, and specificity = 71.43%). On the other hand, cutoff value for tumor-to-background ratio on ROC curve [Figure 2] analysis was ≥ 1.24 for ER positivity (AUC = 0.8286, sensitivity = 80%, and specificity = 85.71%).

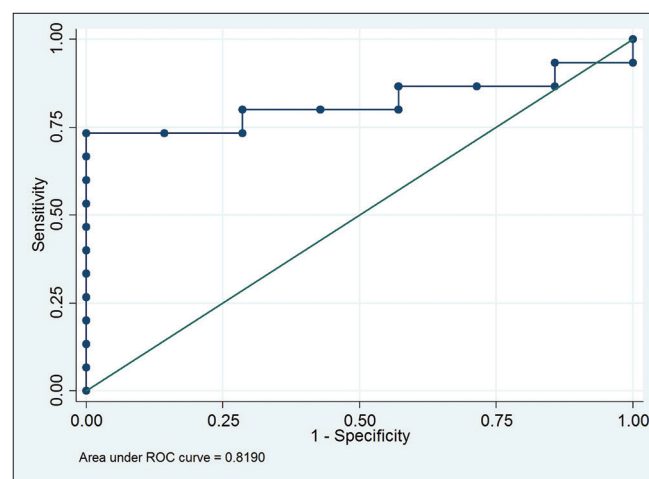


Figure 2: Receiver operating characteristic curve for standard uptake value on fluoroestradiol positron emission tomography/computed tomography for estrogen receptor expression

Table 1: Characteristics of all the patients (a) in association with 18F-fluoroestradiol positron emission tomography findings and (b) in association with 5-fluorodeoxy glucose positron emission tomography findings

| a. FES PET CT findings | | | | | | | | | | | | |
|------------------------|-----|--------|----|--------------------|------------|------------|-----------|----------------|---|-------|---------------------------|-------------------------------|
| Patient number | Age | Sex | ER | SUV of breast lump | SUV I/L LN | SUV C/L LN | SUV IM LN | SUV metastasis | Site of metastasis | MBP | Tumor-to-background ratio | |
| 1 | 47 | Female | 0 | 10 | 8.67 | 4.17 | | | | 2.65 | 3.77 | |
| 2 | 40 | Female | 0 | 15.04 | 16.20 | 1.39 | 3.45 | | | 1.33 | 11.30 | |
| 3 | 43 | Female | 0 | 13.5 | 11.20 | 4.5 | | 4.95 | Bone | 4.5 | 3 | |
| 4 | 56 | Female | 0 | 26.72 | 25.50 | | | | | 3.28 | 8.14 | |
| 5 | 46 | Female | 0 | | | | | | | | | |
| 6 | 48 | Female | 0 | 19.2 | 27.54 | | 5.86 | | | 1.223 | 15.69 | |
| 7 | 62 | Female | 0 | 12.73 | 12.80 | | | 2.87 | Lung | 3.4 | 3.74 | |
| 8 | 83 | Female | 3 | 25.4 | 26.50 | 11.7 | 14.3 | 5.4/13.6/17.8 | D11/abd LN/ liver lesion | 2 | 12.70 | |
| 9 | 58 | Female | 6 | 52.8 | 10.84 | | | 19.22 | Right supraclavicular | 2.58 | 20.46 | |
| 10 | 40 | Female | 7 | 9.09 | 1.10 | | | | | 3.33 | 2.72 | |
| 11 | 51 | Female | 7 | | | | | | | | | |
| 12 | 32 | Female | 8 | 6.21 | 3.93 | | 3.27 | | | 2.19 | 2.83 | |
| 13 | 50 | Female | 8 | | | | | | | | | |
| 14 | 55 | Female | 8 | | | | | | | | | |
| 15 | 60 | Female | 8 | 9.06 | 2.48 | | | | | 3.2 | 2.83 | |
| 16 | 46 | Female | 8 | | | | | | | | | |
| 17 | 55 | Female | 8 | 2.8 | 0.80 | | | | | 1.54 | 1.81 | |
| 18 | 65 | Female | 8 | 39.7 | 7.80 | | | | | 3.9 | 10.17 | |
| 19 | 65 | Female | 8 | 9.5 | 1.70 | | | | | 1.2 | 7.91 | |
| 20 | 72 | Male | 8 | 26.01 | 4.30 | | | 11.49 | Prevascular LN | 1.42 | 18.31 | |
| 21 | 56 | Male | 8 | | | | | | | | | |
| 22 | 60 | Female | 8 | 7.83 | 6.76 | | | | | 1.13 | 6.92 | |
| 23 | 60 | Female | 0 | 31.93 | 35.54 | 8.97 | 25.97 | | | 1.6 | 19.95 | |
| b. FDG PET CT findings | | | | | | | | | | | | |
| Patient | Age | Sex | ER | SUV tumor | SUV I/L LN | SUV C/L LN | SUV IN LN | SUV metastasis | Site of metastasis | MBP | Tumor-to-background ratio | Visual interpretation grading |
| 1 | 47 | Female | 0 | 1.55 | 1.04 | 00.5 | | | | 1.49 | 3.77 | 1 |
| 2 | 40 | Female | 0 | 1.22 | 0.76 | 00.73 | | | | 1.22 | 11.30 | 1 |
| 3 | 43 | Female | 0 | 1.8 | 1.5 | 11.18 | | 0.79 | Bone | 2 | 3 | 2 |
| 4 | 56 | Female | 0 | 1.58 | 1.7 | | | | | 2.01 | 8.14 | 2 |
| 5 | 46 | Female | 0 | 0.97 | 0.62 | | | | | 0.61 | | 1 |
| 6 | 48 | Female | 0 | 1.15 | 1.13 | | 1.26 | | | 1.6 | 15.69 | 2 |
| 7 | 62 | Female | 0 | 1.85 | 1.68 | | | 2.95 | Lung | 2.39 | 3.74 | 1 |
| 8 | 83 | Female | 3 | 1.9 | 1.6 | 11.1 | 0.9 | 1.7/2.9 | D11/abd LN/ liver lesion no comment | 2.1 | 12.70 | 2 |
| 9 | 58 | Female | 6 | 1.74 | 1.1 | | | 1.45 | Right supraclavicular | 1.4 | 20.46 | 3 |
| 10 | 40 | Female | 7 | 1.34 | 0.88 | | | | | 2.08 | 2.72 | 1 |
| 11 | 51 | Female | 7 | 5.88 | 1.31 | | | | | 1.73 | | 4 |
| 12 | 32 | Female | 8 | 3.81 | 4.12 | | 3.72 | | | 1.67 | 2.83 | 4 |
| 13 | 50 | Female | 8 | 1.05 | | | | | | 0.63 | | 4 |
| 14 | 55 | Female | 8 | 0.55 | | | | | | 1.43 | | 1 |
| 15 | 60 | Female | 8 | 5.84 | 10.1 | | | | | 1.3 | 2.83 | 4 |
| 16 | 46 | Female | 8 | 3.38 | 1.39 | | | | | 1.01 | | 4 |
| 17 | 55 | Female | 8 | 3.93 | 1.33 | | | | | 1.13 | 1.81 | 4 |
| 18 | 65 | Female | 8 | 2.1 | 0.1 | | | | | 0.37 | 10.17 | 4 |

Contd...

Table 1: Contd...

| Patient number | Age | Sex | ER | b. FDG PET CT findings | | | | | | | MBP | Tumor-to-background ratio |
|----------------|-----|--------|----|------------------------|------------|------------|-----------|----------------|--------------------|------|-------|---------------------------|
| | | | | SUV of breast lump | SUV I/L LN | SUV C/L LN | SUV IM LN | SUV metastasis | Site of metastasis | | | |
| 19 | 65 | Female | 8 | 3.03 | | | | | | 0.69 | 7.91 | 4 |
| 20 | 72 | Male | 8 | 5.78 | 1.4 | | 1.48 | | Prevascular LN | 1.53 | 18.31 | 4 |
| 21 | 56 | Male | 8 | 8.02 | | | | | | 1.21 | | 4 |
| 22 | 60 | Female | 8 | 23.04 | 18.69 | | | | | 1.74 | 6.92 | 4 |
| 23 | 60 | Female | 0 | 1.23 | 1.56 | 11.08 | 0.64 | 0.9 | Lung | 1.5 | 19.95 | 1 |

SUV: Standardized uptake value; LN: Lymph node; I/L LN: Ipsilateral LN; C/L LN: Contralateral LN; ER: Estrogen receptor; FDG: 5-fluorodeoxyglucose; PET: Positron emission tomography; CT: Computed tomography; IM: Internal mammary; FES: ¹⁸F-fluoroestradiol; MBP: Medistinal blood pool, abd: Abdomen

Table 2: (a) Correlation of standardized uptake value on 5-fluorodeoxyglucose positron emission tomography computed tomography and estrogen receptor expression on immunohistochemistry (b) correlation of standardized uptake value on ¹⁸F-fluoroestradiol positron emission tomography computed tomography and estrogen receptor expression on immunohistochemistry

| a. FDG PET CT - ER correlation | | | | | | | |
|--|-----------|------------|------------|-----------|----------------|---------------------------|-------------------------------|
| Variable | SUV tumor | SUV I/L LN | SUV C/L LN | SUV IM LN | SUV metastasis | Tumor-to-background ratio | |
| Correlation coefficient with ER score (Spearman's Rho) | -0.3808 | -0.7853 | 0.999 | -0.3162 | 0.8721 | -0.2117 | |
| P | 0.1456 | 0.0003 | 0.025 | 0.6838 | 0.0539 | 0.4311 | |
| b. FES PET CT - ER correlation | | | | | | | |
| Variable | SUV tumor | SUV I/L LN | SUV C/L LN | SUV IM LN | SUV metastasis | Tumor-to-background ratio | Visual interpretation grading |
| Correlation coefficient with ER score (Spearman's Rho) | 0.5305 | 0.2668 | 0.404 | 0.5000 | -0.1026 | 0.6640 | 0.7737 |
| P | 0.0111 | 0.2845 | 0.735 | 0.6667 | 0.8696 | 0.0008 | 0.0000 |

SUV: Standardized uptake value; I/L LN: Ipsilateral lymph node; C/L LN: Contralateral lymph node; ER: Estrogen receptor; FDG: 5-fluorodeoxyglucose; PET: Positron emission tomography; CT: Computed tomography; IM: Internal mammary; FES: ¹⁸F-fluoroestradiol

The results of ER expression on FES PET CT as compared to IHC are summarized in Table 2. The overall accuracy of FES PET CT to detect ER expression was 91.66%. There were two false negatives – one was a 55-year-old woman with metachronous early breast cancer that was triple positive. She previously had LABC in the left breast that was also triple positive. She was treated with NACT and trastuzumab followed by surgery, radiotherapy, and adjuvant trastuzumab therapy. She was receiving anastrozole at the time of diagnosis of metachronous breast cancer on the right side. Her ER expression was 7/8. However, uptake on FES PET CT was poor (0.55 for the breast lesion, visual grading 1). The second false-negative patient was a 55-year-old woman with LABC, in whom primary tumor in the breast lighted up on both FDG PET CT and FES PET CT. However, she had multiple non-FDG-avid subpleural lesions (~4 mm) that were also not picked up by FES PET CT. However, CT characteristics of the nodules were suggestive of metastases.

The correlation coefficient between FDG/FES PET CT score for SUV of the tumor, ipsilateral tumor, metastasis, and tumor-to-background ratio was not found to be statistically significant. The corresponding Spearman's Rho correlation coefficients were -0.4436, -0.0088, -0.4000, and -0.0613.

DISCUSSION

Conventionally, ER status of primary or metastatic breast tumor has been obtained by performing immunohistochemical evaluation of tumor tissue obtained by core or excision biopsy. However, sampling error and heterogeneity of tumor may result in wrongly labeling breast tumors as ER negative, thereby denying patients the important modality of antiestrogen therapy. In addition, tumor in some metastatic sites may not be amenable for biopsy. Molecular functional imaging using radiolabeled substance that can bind to ER can theoretically aid in overcoming the disadvantage of biopsy. Functional ER imaging also offers complementary information to biopsy, such as the ability to assess the entire tumor burden and can also track changes in expression over time.

This study demonstrates good accuracy for FES PET CT in identifying ER expression in breast cancer. Sensitivity, specificity, PPV, and NPV in identifying ER expression when compared with IHC of breast specimens as "gold standard" were 87.5%, 100%, 100%, and 80%, respectively. The overall accuracy for FES PET CT to identify ER expression was 87.5%.

Table 3: Comparison of results of estrogen receptor expression on ¹⁸F-fluoroestradiol positron emission tomography computed tomography and Immunohistochemistry

| Parameters | IHC ER +ve | IHC ER -ve | Result |
|----------------|-------------------|------------|-----------------|
| FES PET CT +ve | 14 (TP) | 0 (FP) | PPV=100% |
| FES PET CT -ve | 2 (FN) | 8 (TN) | NPV=80% |
| | Sensitivity=87.5% | | Accuracy=91.66% |

IHC: Immunohistochemistry; ER: Estrogen receptor; FES: ¹⁸F-fluoroestradiol; PET: Positron emission tomography; CT: Computed tomography; PPV: Positive predictive value; NPV: Negative predictive value; TP: True positive; FN: False negative; FP: False positive; TN: True negative

Mintun *et al.*^[3] reported the first study on the role of FES PET CT by studying ER expression in 13 patients with breast cancer. They quantified FES uptake from static images taken approximately 90 min after the injection of radiotracer. Their results showed excellent correlation between *in-vitro* tumor ER concentrations and FES uptake within the primary tumor ($r = 0.97$). Using dynamic FES PET CT imaging, Peterson *et al.* compared ER expression measured by *in-vitro* IHC with FES PET. Using a SUV of 1.1 as a cutoff for determining ER-positive versus ER-negative tumors, they reported an agreement rate of 94% (16 of 17 patients) between IHC results and ¹⁸F-FES uptake. In our study, we studied the correlation coefficient between ER status of tumor by IHC in relation to SUV of primary tumor, tumor-to-background ratio, and visual grading system. None of the earlier studies has compared the tumor-to-background ratio or visual grading system to the ER status of the breast tumor. The correlation coefficient between the lesion SUV and ER status of the tumor in our study was 0.5305 (Spearman's rho 0.53) and that between tumor-to-background ratio and ER expression (Allred Score) was 0.664 ($P = 0.0008$). The correlation between visual grading and ER expression was even stronger. Thus, though the correlation coefficient was significant for all the three measures (SUV, tumor-to-background ratio, and visual grading), the correlation between visual grading and ER expression was the strongest (Spearman's rho 0.7737; $P < 0.0001$).

FES PET CT has also been reported to be useful in predicting ER expression in male breast cancer patients. Among the 148 female and 8 male patients evaluated by FES, Peterson *et al.*^[5] reported no significant difference in mean SUV_{max} for FES in both sexes. In the two male patients in our study, the mean SUV for FES was similar to that in female patients and FES PET CT accurately predicted ER expression in both patients.

FES PET CT has been shown to aid in differentiating metastatic from inflammatory lesions that light up on FDG PET CT in ER-positive breast cancer. In our study, in one male patient with T2N0M0 breast cancer, FDG PET CT revealed FDG-avid mediastinal lymph nodes (prevascular, SUV 11.49). However,

FES PET CT did not show any uptake, and endobronchial ultrasound-guided FNA of the lymph nodes revealed reactive lymphadenitis, thereby confirming that there was no metastasis. Yamane *et al.*^[6] reported about an FDG-avid primary tumor and bilateral axillary lymph nodes in a patient with ER-positive breast cancer. However, subsequent FES PET CT in the patient revealed uptake only in primary tumor but not in axillary lymph nodes that were later confirmed to be inflammatory. Further, FES PET CT may be a noninvasive method of confirming/ruling out metastasis in areas that may not be accessible for tissue diagnosis.

One important limitation of FES PET CT is that it may fail to detect ER positivity of metastatic lesions in liver as ¹⁸F-FES has very high physiological tracer uptake in liver due to its hepatic metabolism. Hence, most liver lesions may appear relatively cold on ¹⁸F-FES PET-CT scan, despite modest tracer uptake. In our study, FES PET CT did not detect ER expression in two patients whose tumors on IHC were ER positive (false negative). In one of them, FES PET CT detected ER expression in primary tumor but not in lung lesions that were highly suspicious of cancer on CT characteristics. The reason could be these nodules were tiny and hence were missed out by both FDG PET and FES PET. The other patient was on anastrozole. Although the precise mechanism as to why FES PET CT failed to detect ER expression in this patient in whom IHC showed strong ER positivity (Allred score 7/8) cannot be explained, decrease in ER expression and SUV of FES PET CT in patients on aromatase inhibitors has been reported previously.^[7]

In this prospective study, majority of the patients had disease limited to breast and axilla and are not typically imaged by PET CT staging. This is in contrast to most studies in literature which evaluated patients with metastatic lesions. Using ROC curve for ¹⁸F FES uptake, we propose that the lesions with SUV of ≥ 1.8 can be considered positive for ER, and therefore will respond to hormonal therapy and carry better prognosis than tumors with a lower SUV. Though the correlation coefficient was significant for SUV, tumor-to-background ratio, and visual grading, correlation between visual grading and ER expression was the strongest. Hence, we propose the use of the visual grading system in addition to SUV of primary tumor alone to detect ER expression on FES PET CT.

Two important limitations of our study are small sample size and not performing biopsy of metastatic lesions at all sites. The reason for not performing biopsy was technical as all the PET CT-detected lesions were small (< 5 mm) or were in inaccessible sites and hence not amenable for guided biopsy. In one patient with lung metastasis, radiologists opined that

the multiple subpleural locations of lesions as seen on CT were characteristic of metastasis because of their classic location but were small (<4 mm) and hence not amenable for guided biopsy. One patient had suspicious metastasis – D10 vertebral metastasis on FES PET CT. However, FDG PET CT and bone scan did not pick up the lesion. As FES PET CT has not come into routine practice, no biopsy was performed, and she underwent NACT followed by surgery. In addition, the limited disease in the ten patients included in this study with early breast cancer could have impacted on the performance of FES PET/CT. This is more so as FES uptake in breast cancer is far lower compared with FDG uptake.

Potential clinical uses of FES PET CT include identifying patients whose tumors do not express ER indicating a lack of endocrine responsiveness, thereby acting as a surrogate pharmacodynamic marker for endocrine therapy and helping clinicians choose choice of therapy particularly in the metastatic setting. It is particularly useful in diagnosing ER-positive metastasis in sites not easily amenable to biopsy.

While ¹⁸F-FES-PET CT represents a promising advancement, barriers to more widespread use also exist. First, additional work is required to prospectively validate its role in different clinical contexts, similar to the process undertaken with ¹⁸F-FDG-PET CT. Moreover, its utility as one component in a multimarker approach to prognostication and management must be further understood. Larger studies are needed to understand the clinical applicability, particularly given the high associated costs and limited availability in most institutions and settings.

CONCLUSION

FES PET CT is a noninvasive *in-vivo* investigation to identify ER expression in breast cancer with high accuracy. It scores over the conventional *in-vitro* study of ER expression as FES PET CT takes care of the heterogeneous nature of tumor

and can also evaluate tumor at metastatic sites that may not be amenable for biopsy. It can also predict and monitor response to endocrine therapy, thus paving way toward more individualized therapy and personalized medicine. However, prospective studies including larger cohort of patients in multicenter settings with possible biopsy correlation of every lesion are essential to confirm these results.

Financial support and sponsorship

Nil.

Conflicts of interest

There are no conflicts of interest.

REFERENCES

1. Kiesewetter DO, Kilbourn MR, Landvatter SW, Heiman DF, Katzenellenbogen JA, Welch MJ. Preparation of four fluorine-18-labeled estrogens and their selective uptakes in target tissues of immature rats. *J Nucl Med* 1984;25:1212-21.
2. Allred DC, Bustamante MA, Daniel CO, Gaskill HV, Cruz AB Jr. Immunocytochemical analysis of estrogen receptors in human breast carcinomas. Evaluation of 130 cases and review of the literature regarding concordance with biochemical assay and clinical relevance. *Arch Surg* 1990;125:107-13.
3. Mintun MA, Welch MJ, Siegel BA, Mathias CJ, Brodack JW, McGuire AH, *et al.* Breast cancer: PET imaging of estrogen receptors. *Radiology* 1988;169:45-8.
4. Peterson LM, Mankoff DA, Lawton T, Yagle K, Schubert EK, Stekhova S, *et al.* Quantitative imaging of estrogen receptor expression in breast cancer with PET and ¹⁸F-fluoroestradiol. *J Nucl Med* 2008;49:367-74.
5. Peterson L, Manohar P, Wu V, Jenkins I, Novakova A, Specht J, *et al.* ¹⁸F-Fluoroestradiol (FES) and ¹⁸F-Fluorodeoxyglucose (FDG) PET imaging in male breast cancer. *J Nucl Med* 2018;59 Suppl 1:54.
6. Yamane T, Ueda S, Seto A, Kuji I. ¹⁸F-Fluoroestradiol PET/CT correctly diagnosed ¹⁸F-FDG-avid inflammatory lymph nodes in a patient with estrogen receptor-positive breast cancer. *Clin Nucl Med* 2018;43:379-80.
7. Linden HM, Kurland BF, Peterson LM, Schubert EK, Gralow JR, Specht JM, *et al.* Fluoroestradiol positron emission tomography reveals differences in pharmacodynamics of aromatase inhibitors, tamoxifen, and fulvestrant in patients with metastatic breast cancer. *Clin Cancer Res* 2011;17:4799-805.