

Bilateral costotransverse and local continuous chemotherapy approach for debridement, fixation, and fusion of contiguous multisegmental thoracic spinal tuberculosis

A retrospective study

Xinhua Yin, MD, Liang Yan, MD, Ming Yang, MD, Shichang Liu, MD, Baorong He, MD, Zhongkai Liu, MD*, Dingjun Hao, MD

Abstract

The study aims to evaluate the clinical efficacy of bilateral costotransverse debridement, transpedicular fixation, fusion, and local continuous chemotherapy in 20 patients of contiguous multisegmental thoracic spinal tuberculosis (CMTSTB). We analyzed 20 patients with contiguous thoracic spinal tuberculosis (TB) who underwent surgery via bilateral costotransverse debridement, fusion, posterior instrumentation, and postural drainage with local continuous chemotherapy. The clinical outcomes were evaluated in terms of kyphotic angle, bone fusion, neurologic status, erythrocyte sedimentation rate (ESR), and intraoperative and postoperative complications. All of the patients (8M/12F), averaged 45.8 ± 15.6 years old. The mean duration of postoperative follow-up was 30.7 ± 4.0 months. There was no recurrent TB infection. The values of ESR returned to normal levels at final follow-up. All patients got bony fusion within 8.1 ± 2.3 months after surgery. The average preoperative Cobb angle was $39.9^\circ \pm 8.6^\circ$, correcting to $9.8^\circ \pm 2.3^\circ$ postoperatively and $10.8^\circ \pm 2.3^\circ$ at the last follow-up. All patients with neurological deficit had dramatic improvement at the final follow-up. Our results showed that bilateral costotransverse surgery and local continuous chemotherapy are feasible and effective procedures in the treatment of CMTSTB. The approach can provide radical debridement, rebuild spinal stability, and cure TB.

Abbreviations: ASIA = American Spinal Injury Association, CMTSTB = contiguous multisegmental thoracic spinal tuberculosis, CT = computed tomography, ESR = erythrocyte sedimentation rate, STB = spinal tuberculosis, TB = tuberculosis, VAS = visual analog scale.

Keywords: bilateral costotransverse approach, contiguous multisegmental thoracic spinal tuberculosis, local continuous chemotherapy

1. Introduction

Tuberculosis (TB) is the ninth leading cause of death worldwide. According to a WHO report in 2017,^[1] there were an estimated 1.3 million TB deaths among HIV-negative people. Spinal tuberculosis (STB), which is the most common kind of extrapulmonary TB, is considered a catastrophic disease due to the associated probability of spinal cord compression and quadriplegia.^[2] The thoracic vertebra to be the most affected area

in spine, follow by lumbar vertebra.^[3] Thoracic spine TB is more prone to affect contiguous multisegmental vertebrae and diffuse subligamentously, which result in severe spinal cord damage and kyphotic deformity, higher morbidity seriously affects patients' health and quality of life.^[4,5] The treatment strategy of contiguous multisegmental thoracic spinal tuberculosis (CMTSTB) is basically derived from the experience in treating monosegmental STB. Anti-TB therapy is the cornerstone of treatment of spinal TB. Although patients with STB were treated using chemotherapy alone, the vertebrae collapse may progress it is until bony fusion occurs, and 3% to 5% of such patients finally ended up with a residual kyphosis up to 60°. Surgical treatments are sometimes required for the patients with severe neurologic deterioration, progressive instability, failure of conservative treatment, and acute onset.

Although anterior approach have been conventionally preferred, complicated anatomic layers, insufficient kyphosis correction, should not be overlooked. To overcome the shortcoming of anterior approach, a clinical study of posterior debridement and interbody thoracic fusion and fixation to treat thoracic TB have been reported. For patients with CMTSTB, the posterior approach failed to achieve satisfactory debridement. No consensus has been reached among surgeons about surgical methods for the treatment of CMTSTB. To our knowledge, there is a minority of research referring to the surgical treatment of CMTSTB by bilateral costotransverse and local continuous chemotherapy approach. The study aims to evaluate the

Editor: Yan Li.

This work was financially supported by Postdoctoral Science Foundation in Shanxi Province, China (2016BSHYDZZ41).

The authors have no conflicts of interest to disclose.

Department of Spine Surgery, Hong Hui Hospital, Xi'an Jiaotong University College of Medicine, Xi'an, China.

* Correspondence: Zhongkai Liu, Department of Spine Surgery, Hong Hui Hospital, Xi'an Jiaotong University College of Medicine, Xi'an, Shanxi 710054, PR China (e-mail: spine2020@163.com).

Copyright © 2018 the Author(s). Published by Wolters Kluwer Health, Inc. This is an open access article distributed under the terms of the Creative Commons Attribution-Non Commercial-No Derivatives License 4.0 (CCBY-NC-ND), where it is permissible to download and share the work provided it is properly cited. The work cannot be changed in any way or used commercially without permission from the journal.

Medicine (2018) 97:41(e12752)

Received: 8 July 2018 / Accepted: 17 September 2018

<http://dx.doi.org/10.1097/MD.00000000000012752>

Table 1**Clinical data on the patients.**

| | |
|---------------------------|----------------|
| Sex | |
| Male | 8 |
| Female | 12 |
| Age, y | 45.8 ± 15.6 |
| Involved vertebrae number | 4.7 ± 1.1 |
| Operation time, min | 366.8 ± 56.0 |
| Blood loss, mL | 1355.0 ± 366.7 |
| Duration of follow-up, mo | 30.7 ± 4.0 |
| Fusion time, mo) | 8.1 ± 2.3 |
| VAS | |
| Pre | 7.1 ± 1.0 |
| FFU | 1.0 ± 0.8 |
| ESR (mm/h) | |
| Pre | 65.4 ± 17.8 |
| FFU | 8.1 ± 1.4 |

ESR=erythrocyte sedimentation rate, FFU=final follow-up, pre=preoperative, VAS=visual analog scale.

effectiveness and safety of surgical management of patients with CMTSTB by bilateral costotransverse and local continuous chemotherapy approach.

2. Materials and methods

This research was approved by the Ethic Committee of the Hong Hui Hospital of Xi'an Jiaotong University College of Medicine. All of the 20 patients were confirmed radiologically as CMTSTB presenting to our hospital between February 2012 and June 2014, who received bilateral costotransverse debridement, transpedicular screw fixation, fusion, and local continuous chemotherapy. Patients having the following criteria were included: STB involves not <3 adjacent vertebrae and a minimum follow-up period of 24 months. Exclusion criteria were monosegmental STB, noncontiguous multifocal STB, patients lost to follow-up or death, previous thoracic STB surgery, and active pulmonary TB. In the series, vertebral damage was as follows: 5 cases had 3 affected segments, ten cases had 4 affected segments, and 5 cases had 5 or more affected segments.

All patients had symptoms of back pain, weight loss, low fever, and fatigue. The diagnosis of CMTSTB was based on clinical symptoms, imageological examination [spinal x-ray films, computed tomography (CT), magnetic resonance imaging], and hematological examination [erythrocyte sedimentation rate (ESR), liver and renal function tests, etc]. All the cases were confirmed histopathologically. The mean interval between symptom onset and clinical diagnosis was 5.6 ± 3.0 months (range, 2–12 months). The neurological deficit was assessed according to the American Spinal Injury Association (ASIA), and patients with incomplete paralysis (5 patients with ASIA B, 12 patients with ASIA C, 3 patients with ASIA D). The ESR of

Table 2**Clinical outcomes of surgical treatments for multisegmental thoracic spinal tuberculosis.**

| | |
|-----------------------------|------------|
| Cobb angle, ° | |
| Preoperative | 39.9 ± 8.6 |
| Postoperative | 9.8 ± 2.3 |
| Final follow-up | 10.8 ± 2.3 |
| Complications | |
| Pleural membrane laceration | 1 |

Table 3**The neurological function evaluated by the American Spinal Injury Association impairment scale.**

| ASIA scale | Pre | FFU |
|------------|-----|-----|
| A | 0 | 0 |
| B | 5 | 0 |
| C | 11 | 0 |
| D | 4 | 1 |
| E | 0 | 19 |

ASIA=American Spinal Injury Association, FFU=final follow-up, pre=preoperative.

patients ranged from 43 to 105 mm/h, with an average of 65.4 ± 7.8 mm/h. The preoperative Cobb angle of kyphotic deformity ranged from 31° to 60° , with an average of $39.9^\circ \pm 8.6^\circ$. The patients were treated with 4 drugs regime: isoniazid, rifampicin, ethambutol, and pyrazinamide. The chemotherapy was carried out preoperatively for 7 to 14 days. Correction of hypoproteinemia and anemia were carried out in all patients .

2.1. Surgical technique

All patients were in the prone position after general anesthesia. The exposure was performed through a posterior midline incision. And the exposure area include two to three vertebrae above and below tuberculosis lesion. The pedicle screws were placed at least two vertebrae at proximal and distal to the level of decompression. Bilateral costotransversectomy at 1 or more levels to drain prevertebral abscess and expose diseased vertebral bodies. After temporary stabilization, laminectomy, and corpectomy are carried out from both sides to permit circumferential decompression. A temporary rod is placed on the contralateral side in the position of deformity to prevent any inadvertent translator movements during the subsequent surgical step. After completion of the procedure an appropriately contoured rod is placed. Kyphosis correction by spinal column shortening and compression along the posterior implant is performed. During the posterior placement of grafts after osteotomy, it was necessary to sacrifice 1 or 2 adjacent nerve roots of one side to ensure better exposure, and provide enough space for the insertion of the titanium mesh or cage. Isoniazid (0.3g) was placed into the intervertebral area during the operation. Postural drainage tubes were placed in all patients, and a suitable infusion tube was placed at the lesion for daily local continuous chemotherapy (Fig. 1).

2.2. Postoperative management and follow-up

All patients were administered with the 4 drugs regimen mentioned above for 12 to 18 months postoperatively. The drain was usually pulled out when drainage flow was <30 mL/day. Continuous local chemotherapy was continued for 20 to 30 days for patients, after which the tubes were removed. Patients remained in bed for 3 to 5 days postoperatively, then patients were allowed to ambulate and rehabilitation was initiated. After surgery, the braces were used for a minimum period of 5 months in all patients. The laboratory examination (hepatic and kidney function, blood test, ESR) and imageological examination (x-ray) were carried out postoperatively at 3, 6, 12, 18, and 24 months and once a year. The statistical analysis was carried out using SPSS 20. The pre- and postoperative data were compared with paired sample *t* test. Differences were considered significant at $P < 0.05$. The results are recorded as mean ± standard deviation.

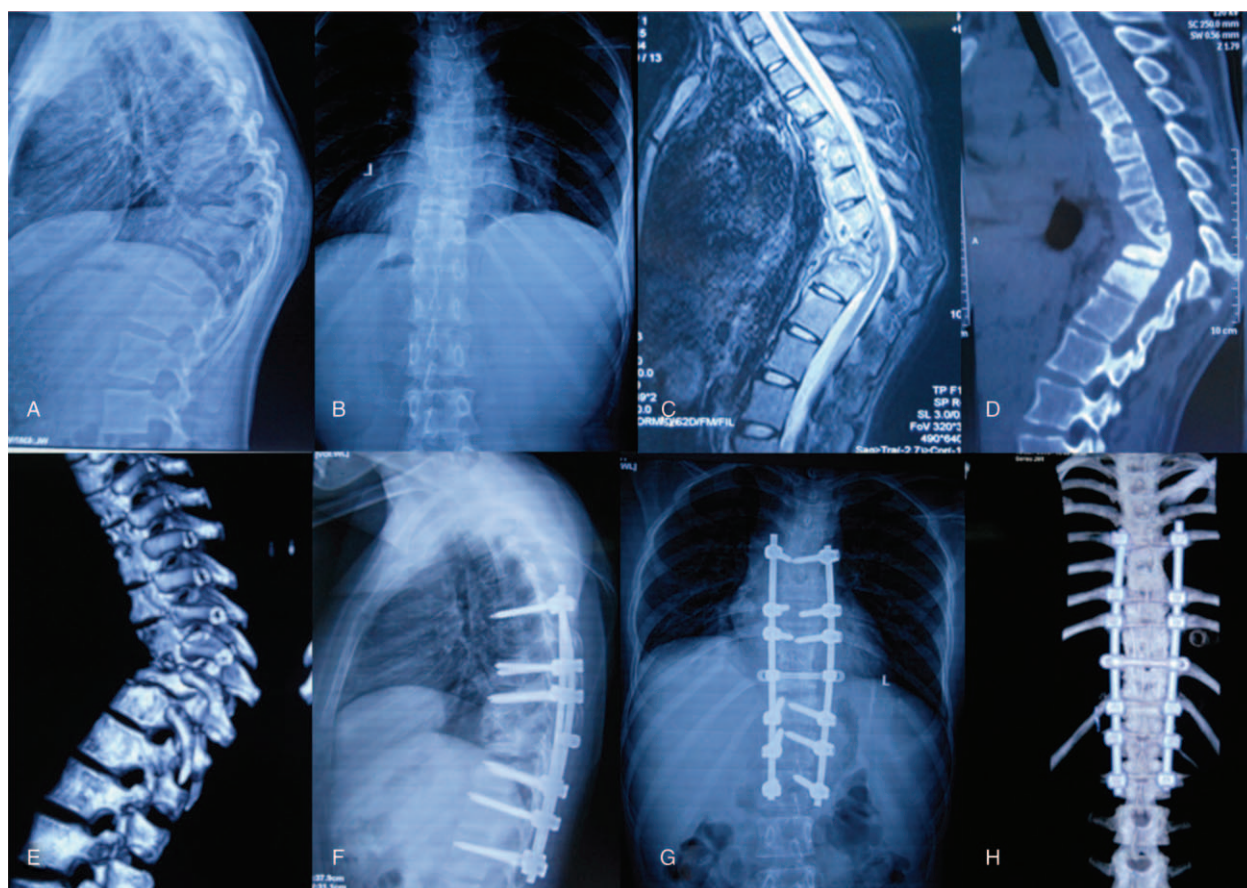


Figure 1. A 20-year-old woman was diagnosed as contiguous multisegmental thoracic spinal tuberculosis (CMTSTB). A–B, Preoperative x-ray showed contiguous multisegmental thoracic vertebral body collapse. C–E, Preoperative computed tomography (CT) and magnetic resonance imaging (MRI) found contiguous multisegmental vertebral bone destruction and paravertebral abscess formation at the area of thoracic spine. Bilateral costotransverse debridement, transpedicular fixation, fusion and local continuous chemotherapy were performed on the patient. F–H, X-ray and CT at the final follow-up found the kyphotic angle was corrected and good bone fusion.

3. Results

In all patients, the wounds were healed and no recurrence occurred. The duration of follow-up ranged from 24 to 48 months (mean 30.7 ± 4.0). All of the 20 patients (8M/12F), with an average of 45.8 ± 15.6 years (range 20–74 years). The average surgery time was 366.8 ± 56.0 minutes (range 261–450 minutes). The average amount of bleeding was 1355.0 ± 366.7 mL (range 950–2000 mL). The average hospitalization time was 14 days (range 10–16 days). The average ESR returned from 65.4 ± 17.8 mm/h preoperatively to 8.1 ± 1.4 mm/h at the last follow-up ($P < .01$). The kyphotic angle decreased from $39.9^\circ \pm 8.6^\circ$ to $9.8^\circ \pm 2.3^\circ$ postoperatively ($P < .01$), and became $10.8^\circ \pm 2.3^\circ$ at the final follow-up. The average preoperative visual analog scale was 7.1 ± 1.0 , which decreased to 1.0 ± 0.8 at the last visit. Bone fusion was observed within 8.1 ± 2.3 months in all patients. Except for 1 case with ASIA D, all patients with preoperative neurologic deficit were recovered to normal at the final follow-up. The pleural membrane laceration was detected in 1 case; it was sutured during operation. Postoperatively, the case had no complication. Relevant outcomes are shown in Tables 1, 2 and 3.

4. Discussion

CMTSTB is usually extensive, often involves multisegmental adjacent vertebrae and the intervening disc, while deep multiple abscesses are common, and have a high risk of kyphosis or spinal

cord compression. Several surgical approaches, which can be divided into anterior, posterior, and combined types, performed either in 1 or 2 stages, have been performed in STB. In 2013, Li et al^[6] reported good results of 4 different surgery procedures for the treatment of adjacent multisegmental STB. In their series, 7 patients underwent anterior surgery, 18 patients underwent posterior and anterior combined surgery, 18 patients underwent posterior surgery, and 5 patients underwent CT-guided drainage and combined with posterior operation. The result shows that the 4 surgery procedures have respective advantages and disadvantages in the management of CMTSTB. The surgical treatment of multisegmental STB results in more surgical trauma and complications than that of single focus TB. There are several controversies in the surgical treatment of patients with CMTSTB. Because the TB inflammation is usually located in the anterior column, the “Hong Kong operation” is the standard for anterior radical debridement with bone grafting.^[7] The advantages of the anterior approach include direct exposure of the TB and radical debridement, and decompression of the spinal cord. However, this procedure has not been successful in insufficient kyphosis correction or ineffective maintenance of deformity correction.^[8] Furthermore, it is not suited for patients with multiple-level involvement. In addition, the anterior exposure of the upper thoracic spinal region was blocked by thoracic bones, as well as the clavicle, costal bone, and superior mediastinum organs.^[9–11]

In view of these disadvantages of anterior approach, additional posterior fixation is performed to correct kyphotic deformities and to prevent correction loss and graft failure by some surgeons,^[12,13] although this combined procedure has a longer operation time, terrible higher surgical trauma, and longer healing duration.^[14] Moreover, anterior debridement requires a massive transection of muscle, rib, and going through the pleural cavity, causing great damage and probable severe perioperative complications such as respiratory insufficiency, hemothorax, pneumonia, and vascular injury.^[15] The patients of CMTSTB usually with poor condition and severe complication fail to tide over higher surgical trauma.

Given all of this, surgeons reported good results of posterior debridement, interbody graft fusion, and posterior instrumentation in the treatment of thoracic STB.^[16–18] The range of excision in the approach includes spinous process, unilateral facet joint, and the upper or lower costotransverse joint with a small fragment of ribs. The surgeons reported that the posterior-only approach has many advantages such as minor surgical invasion, effective kyphosis correction, and less complications. It is not denied that posterior surgery has many disadvantages; the posterior approach allows operation on the vertebral body at limited angle for debridement, and interbody fusion and the lesion may not be completely clear, especially the anteriolateral debridement was difficult to perform.^[19] In addition, there are aggravated risks of spinal cord injury with decompression. Ramdurg et al^[20] and Muthukumar et al^[21] deem that debridement using the posterior-only approach could lead to central nervous system complications of TB infection and intraspinal infection, such as TB meningitis.^[20,21] Furthermore, the indications posterior surgery was narrow, which is single thoracic TB with small paravertebral abscess. For patients with multisegmental thoracic STB and/or large prevertebral abscesses, it is difficult to cure by the posterior approach.

There was quite few research reported in surgical management of CMTSTB by bilateral costotransverse and local continuous chemotherapy approach. Allowing for such points above, in our series, we adopted bilateral costotransverse decompression, fusion, posterior instrumentation, and local continuous chemotherapy in the surgical treatment of CMTSTB. This approach far away from the thoracic cavity is characterized as the simple approach. It avoids the high anesthetic risk of anterior procedure with the possibility to develop postoperative severe complications. In addition, the approach resected 2 sides of costotransverse and small rib to get enough operating space, allowing operation on the vertebral body at a 360° angle under direct visualization of radical debridement. In our series, we thoroughly removed focal tissues, especially the caves, sclerotic walls, dead spaces, and so on, and reached the subnormal substance of bones between pathologic bones and normal cancellous bones.

CMTSTB is usually extensive, deep multiple abscess, which can result in an incurable or recurrent result for TB. More than 2 centuries ago, Potts observed that when sinuses formed and abscesses were drained, spine TB symptoms could be alleviated. As technologies have developed, percutaneous catheter drainage has become an important clinical form of treatment of STB. In 2015, we reported that 27 children suffering from STB were performed with percutaneous catheter drainage and local chemotherapy. And all cases were cured with an average follow-up of 31.00 ± 13.94 months.^[22] In addition, Zhang et al^[23] found that local application of large doses of chemotherapy drugs, such as isoniazid, could kill pathogenic

bacteria, and thus preventing the development of further pathological changes. In addition, Zhou et al^[24] reported that 109 patients with lumbar TB underwent 1-stage posterior debridement, bone grafting, and instrumentation. The patients were divided into 2 groups (without and with local continuous chemotherapy). All the patients achieve good clinical results. However, the fusion was significantly more rapid in local continuous chemotherapy group (6.4 ± 0.5 months) than no local continuous chemotherapy group 8.9 ± 0.6 months. They indicate that local chemotherapy and postural drainage can effectively eliminate infection lesion caused by abscess remnants and enhance reconstruction of segmental stability. In our study, all of the 20 patients were routinely undergoing percutaneous catheter drainage and local chemotherapy. The series healed without chronic infection, fistula formation, and recurrence at the long-term follow-up. In addition, the bilateral costotransverse approach creates enough operating space through resection of the 2 sides of the costosternal joints, diapophysis, and small rib portions, allowing operation at a 360° angle under direct visualization of performed debridement and bone graft. As we know, the excessive deformity correction is more likely to deteriorate neurological symptoms. The curvature of the rod determines the degree of deformity correction; thus, accurate contouring is necessary to avoid deterioration of neurological symptoms.

It is known that the early spinal stability, which is benefit to inhibit TB infection and create a stable microenvironment to control recurrence, hence, correction of spinal instability plays an important role in curing STB.^[25] Furthermore, rigid stabilization of spine has been demonstrated not only to achieve relief of pain because of spinal instability^[26,27] but also to promote neurological recovery.^[28–30] In our series, the kyphotic angle improved from $39.9^\circ \pm 8.6^\circ$ preoperatively to $10.8^\circ \pm 2.3^\circ$ during follow-up, there was obvious correction of kyphosis. There is no gainsaying the fact that reliable reconstruction of spinal stability is responsible for the bone graft in STB. Meanwhile, interbody fusion was considered as compulsory measure for correcting the instability of spine, promoting neurological recovery, and accelerating healing of TB.^[31,32] Autogenous bone was considered as an optimal choice for their biocompatibility, immune compatibility, and osteoinductive capability. Complications related to autogenous bone grafting have been reported, too. In the current study, 8 patients were treated with autogenous rib bone grafting. Owing to the resected autogenous rib was insufficient in volume or strength to meet the criterion for structural grafts, titanium mesh (autogenous rib bone and allograft) was used in 12 patients. Bone fusion was observed in all of the patients with 8.1 ± 2.3 months. Our results show the benefits of bone graft in conjunction with posterior fixation such as stable reconstruction of thoracic stability, the ability for exact trimming to the size of the defect, and absence of donor-site morbidity. However, limitation of our study should be noted, such as single-center study, its retrospective study nature, and small sample size. A much larger, randomized controlled trial could be performed to elucidate the treatment of consecutive multisegment thoracic TB in the future.

5. Conclusion

Our study suggests that bilateral costotransverse and local continuous chemotherapy are feasible and effective procedures in the treatment of CMTSTB. The approach can provide radical debridement, rebuild spinal stability, and cure TB.

Author contributions

Conceptualization: Zhongkai Liu.

Data curation: Zhongkai Liu.

Formal analysis: Liang Yan.

Funding acquisition: Liang Yan.

Investigation: Dingjun Hao.

Methodology: Dingjun Hao.

Project administration: Baorong He.

Resources: Baorong He.

Software: Ming Yang.

Supervision: Ming Yang.

Validation: Shichang Liu.

Visualization: Shichang Liu.

Writing – original draft: Xinhua Yin.

Writing – review and editing: Xinhua Yin.

References

- [1] World Health Organization Global tuberculosis report. *Global Tuberc Rep* 2017;6:12–3.
- [2] Wang YX, Zhang HQ, Liao W, et al. One-stage posterior focus debridement, interbody graft using titanium mesh cages, posterior instrumentation and fusion in the surgical treatment of lumbo-sacral spinal tuberculosis in the aged. *Int Orthop* 2016;40:1117–24.
- [3] Wang H, Li C, Wang J, et al. Characteristics of patients with spinal tuberculosis: seven-year experience of a teaching hospital in Southwest China. *Int Orthop* 2012;36:1429–34.
- [4] Wu P, Wang X, Li X, et al. One-stage posterior procedure in treating active thoracic spinal tuberculosis: a retrospective study. *Eur J Trauma Emerg Surg* 2015;41:189–97.
- [5] Zhang H, Sheng B, Tang M, et al. One-stage surgical treatment for upper thoracic spinal tuberculosis by internal fixation, debridement, and combined interbody and posterior fusion via posterior-only approach. *Eur Spine J* 2013;22:616–23.
- [6] Li L, Xu J, Ma Y, et al. Surgical strategy and management outcomes for adjacent multisegmental spinal tuberculosis: a retrospective study of forty-eight patients. *Spine (Phila Pa 1976)* 2014;39:40–8.
- [7] Hodgson AR, Stock FE, Fang HS, et al. Anterior spinal fusion. The operative approach and pathological findings in 412 patients with Pott's disease of the spine. *British J Surg* 1960;48:172–8.
- [8] Upadhyay SS, Saji MJ, Sell P, et al. The effect of age on the change in deformity after radical resection and anterior arthrodesis for tuberculosis of the spine. *J Bone Joint Surg Am* 1994;76:701–8.
- [9] Ikard RW. Methods and complications of anterior exposure of the thoracic and lumbar spine. *Arch Surg* 2006;141:1025–34.
- [10] McDonnell MF, Glassman SD, Dimar JR, et al. Perioperative complications of anterior procedures on the spine. *J Bone Joint Surg Am* 1996;78:839–47.
- [11] Stuli'k J, Vyskocil T, Bodla'k P, et al. Injury to major blood vessels in anterior thoracic and lumbar spinal surgery. *Acta Chir Orthop Traumatol Cech* 2006;73:92–8.
- [12] Laheri VJ, Badhe NP, Dewnany GT. Single stage decompression, anterior interbody fusion and posterior instrumentation for tuberculous kyphosis of the dorso-lumbar spine. *Spinal Cord* 2001;39:429–36.
- [13] Klockner C, Valencia R. Sagittal alignment after anterior debridement and fusion with or without additional posterior instrumentation in the treatment of pyogenic and tuberculous spondylodiscitis. *Spine (Phila Pa 1976)* 2003;28:1036–42.
- [14] He Q, Xu J. Comparison between the antero-posterior and anterior approaches for treating L5-S1 vertebral tuberculosis. *Int Orthop* 2012;36:345–51.
- [15] Pettiford BL, Schuchert MJ, Jeyabalan G, et al. Technical challenges and utility of anterior exposure for thoracic spine pathology. *Ann Thorac Surg* 2008;86:1762–8.
- [16] Gao Y, Ou Y, Deng Q, et al. Comparison between titanium mesh and autogenous iliac bone graft to restore vertebral height through posterior approach for the treatment of thoracic and lumbar spinal tuberculosis. *PLoS One* 2017;12:e0175567.
- [17] Zhang H, Huang S, Guo H, et al. A clinical study of internal fixation, debridement and interbody thoracic fusion to treat thoracic tuberculosis via posterior approach only. *Int Orthop* 2012;36:293–8.
- [18] Sahoo MM, Mahapatra SK, Sethi GC, et al. Posterior-only approach surgery for fixation and decompression of thoracolumbar spinal tuberculosis: a retrospective study. *J Spinal Disord Tech* 2012;25:E217–23.
- [19] Wu P, Wang XY, Li XG, et al. One-stage posterior procedure in treating active thoracic spinal tuberculosis: a retrospective study. *Eur J Trauma Emerg Surg* 2015;41:189–97.
- [20] Ramdurg SR, Gupta DK, Suri A, et al. Spinal intramedullary tuberculosis: a series of 15 cases. *Clin Neurol Neurosurg* 2009;111:115–8.
- [21] Muthukumar N, Venkatesh G, Senthilbabu S, et al. Surgery for intramedullary tuberculoma of the spinal cord: report of 2 cases. *Surg Neurol* 2006;66:69–74.
- [22] Xin HY, Hong QZ, Xiong KH, et al. Treatment of pediatric spinal tuberculosis abscess with percutaneous drainage and low-dose local antituberculous therapy: a preliminary report. *Childs Nerv Syst* 2015;31:1149–55.
- [23] Zhang XF, Yan WM, Shong-hua Xiao, et al. Treatment of lumbar and lumbosacral spinal tuberculosis with minimally invasive surgery. *Orthop Surg* 2010;2:64–70.
- [24] Zhou Y, Song Z, Luo J, et al. The efficacy of local continuous chemotherapy and postural drainage in combination with one-stage posterior surgery for the treatment of lumbar spinal tuberculosis. *BMC Musculoskelet Disord* 2016;17:66.
- [25] Huang J, Zhang H, Zeng K, et al. The clinical outcomes of surgical treatment of noncontiguous spinal tuberculosis: a retrospective study in 23 cases. *PLoS One* 2014;9:e93648.
- [26] Lee TC, Lu K, Yang LC, et al. Transpedicular instrumentation as an adjunct in the treatment of thoracolumbar and lumbar spine tuberculosis with early stage bone destruction. *J Neurosurg* 1999;91:163–9.
- [27] Kumar MN, Joseph B, Manur R. Isolated posterior instrumentation for selected cases of thoraco-lumbar spinal tuberculosis without anterior instrumentation and without anterior or posterior bone grafting. *Eur Spine J* 2013;22:624.
- [28] Fukuta S, Miyamoto K, Masuda T, et al. Two-stage (posterior and anterior) surgical treatment using posterior spinal instrumentation for pyogenic and tuberculous spondylitis. *Spine (Phila Pa 1976)* 2003;28:E302–8.
- [29] Broner FA, Garland DE, Zigler JE. Spinal infections in the immunocompromised host. *Orthop Clin North Am* 1996;27:37–46.
- [30] Altman GT, Altman DT, Frankovitch KF. Anterior and posterior fusion for children with tuberculosis of the spine. *Clin Orthop Relat Res* 1996;325:225–31.
- [31] Sun L, Song Y, Liu L, et al. One-stage posterior surgical treatment for lumbosacral tuberculosis with major vertebral body loss and kyphosis. *Orthopedics* 2013;36:e1082–90.
- [32] Pang X, Shen X, Wu P, et al. Thoracolumbar spinal tuberculosis with psoas abscesses treated by one-stage posterior transforaminal lumbar debridement, interbody fusion, posterior instrumentation, and postural drainage. *Arch Orthop Trauma Surg* 2013;133:765–72.