International Journal for Parasitology: Parasites and Wildlife 23 (2024) 100923

Contents lists available at ScienceDirect

International Journal for Parasitology: Parasites and Wildlife

journal homepage: www.elsevier.com/locate/ijppaw

Detection of *Sarcocystis albifronsi*, *Eimeria alpacae*, and *Cystoisospora felis* in Eurasian lynx (*Lynx lynx*) in northwestern China

Nannan Cui [a,1], Shiyi Wang [a,1], Ziqi Wang [a,1], Sándor Hornok [b], Huiqian Wang [a], Xiaobo Lu [c], Gang Liu [a], Yuanzhi Wang [a,*]

[a] *Key Laboratory for Prevention and Control of Emerging Infectious Diseases and Public Health Security, The XPCC, School of Medicine, Shihezi University, Shihezi City, Xinjiang Uygur Autonomous Region 832002, China*
[b] *Department of Parasitology and Zoology, University of Veterinary Medicine, Budapest, Hungary*
[c] *The First Hospital Xinjiang Medical University, Urmqi, China*

ARTICLE INFO

Keywords:
Eurasian lynx
Sarcocystis albifronsi
Eimeria alpacae
Cystoisospora felis
Northwestern China

ABSTRACT

Eurasian lynx (*Lynx lynx*) is widely distributed in various habitats in Asia and Europe, and it may harbor multiple pathogens. Currently, the information on protozoan infection in Eurasian lynx is scarce. In this study, we performed nested polymerase chain reaction (nPCR) analysis to detect intestinal protozoan infection in three dead Eurasian lynxes, in northwestern China. Three dead Eurasian lynxes, an adult female (#1), an adult male (#2), and a cub male (#3), were sampled in West Junggar Mountain, the northwestern region of Xinjiang Uyghur Autonomous Region. The intestine samples were analyzed using nPCR. We used primers targeting the cytochrome C oxidase subunit I gene (*COI*) for detection of *Sarcocystis* and *Eimeria* species and targeting the small subunit 18 S ribosomal RNA gene (*18S rRNA*) for detection of *Cystoisospora* species. The nPCR-positive products were sequenced, aligned, and phylogenetically analyzed. Three intestinal protozoa, *Sarcocystis albifronsi*, *Eimeria alpacae*, and *Cystoisospora felis*, were found in three Eurasian lynxes. The intestine sample of Eurasian lynx #2 was detected with *S. albifronsi* and *E. alpacae*. In addition, *C. felis* was only found in the intestine sample of Eurasian lynx #3. To the best of our knowledge, *S. albifronsi* and *E. alpacae* were detected in Eurasian lynx for the first time. In addition, *C. felis* was firstly found in Eurasian lynx in China. These findings extend our knowledge of the geographical distribution and host range of intestinal protozoa.

1. Introduction

Currently, 13 species of Felidae in six genera are distributed in China. Among these, five species in three genera of Felidae are found in the Xinjiang Uyghur Autonomous Region in northwestern China, namely *Felis silvestris* (Wild cat), *Felis bieti* (Chinese mountain cat), *Otocolobus manul* (Pallas's cat), *Lynx lynx* (Eurasian lynx) *and Panthera uncia* (Snow leopard). (Ablimit et al., 1998). The Eurasian lynx is a medium-sized wild felid species that lives in various habitats in Asia and Europe (Castelĺo et al., 2020). The habitat and food resources of the Eurasian lynx are threatened by increasing anthropogenic activities, resulting in a significant decline in its population (Premier et al., 2021). In China, illegal poaching and trade further endanger this species (Ke et al., 2023).

Pathogenic infection is an important mortality factor in lynx (Figueiredo et al., 2021). Previously, *Chlamydia felis*, *Joyeuxiella* spp., *Trichinella britovi*, *canine distemper virus*, and *Parvovirus* were detected in Eurasian lynx (Frey et al., 2009; Hosseini et al., 2020; Lombardo et al., 2023; Marti et al., 2019; Wasieri et al., 2009). Furthermore, intestinal protozoa were detected in *Lynx* genus, such as *Sarcocystis neurona* infection in Canadian lynx (*Lynx canadensis*) (Forest et al., 2000); *Cystoisospora rivolta*, *Giardia intestinalis*, *Blastocystis* spp., and *Cryptosporidium* spp. in Eurasian lynx (Segeritz et al., 2021); and *T. gondii* in Canadian lynx, Iberian lynx, and Eurasian lynx (Jokelainen et al., 2013; Simon et al., 2013; Sobrino et al., 2007). In the present study, we aimed to investigate the presence of *Sarcocystis*, *Eimeria*, and *Cystoisospora* spp. in Eurasian lynx.

* Corresponding author.
E-mail address: wangyuanzhi621@126.com (Y. Wang).
[1] Euqal contributors.

https://doi.org/10.1016/j.ijppaw.2024.100923
Received 5 January 2024; Received in revised form 3 March 2024; Accepted 3 March 2024
Available online 13 March 2024

2. Material and methods

2.1. Sample collection

A total of three Eurasian lynxes were included in this study. Two Eurasian lynxes, an adult female (#1) and an adult male (#2), were found dead during our field investigation in West Junggar Mountain in 2018 and 2019, respectively (Liu et al., 2021). The third one, a road-killed male cub (#3), was also collected in this region in 2019 (Gang et al., 2020). The intestine samples of three feline carcasses were collected and stored in a −80 °C refrigerator until DNA extraction.

2.2. DNA extraction

Genomic DNA was individually extracted from each sample using the TIANamp Genomic DNA Kit (TIANGEN, Beijing, China) following the manufacturer's instructions. The DNA extracted from each piece of small intestine specimen was eluted in 60 μL of Tris-EDTA buffer and stored at −80 °C under sterile conditions to prevent contamination until nested polymerase chain reaction (nPCR) analysis.

2.3. Polymerase chain reaction amplification

Genomic DNA extracted from each specimen was individually screened for the presence of *Sarcocystis* sp., *Eimeria* sp., and *Cystoisospora* sp. DNA using nPCR and sequence analyses. *Sarcocystis* and *Eimeria* were genotyped by amplifying fragments of the cytochrome C oxidase subunit I (*COI*) [*Sarcocystis COI*: 404 bp; *Eimeria COI*: 465 bp] (Ogedengbe et al., 2011; Yang et al., 2013). *Cystoisospora* was identified and genotyped by amplifying 450-bp fragments of the small subunit 18 S ribosomal RNA (*18S rRNA*) (Zhang et al., 2018). The primers and nPCR cycling conditions used in this study are shown in Additional File 1. The nPCR products were subjected to electrophoresis in a 1.5% agarose gel and visualized under UV light by staining the gel with Goldview (Biotopped, Beijing, China). Moreover, a negative control (distilled water) and a positive control from Mongolia pikas in our labs for *Eimeria* were included in each run of the amplification reaction for validation. All of the nPCR products were purified using the TIANgel Midi Purification Kit (TIANGEN, Beijing, China) and sequenced by Sangon Biotech Co., Ltd. (Shanghai, China).

2.4. Sequencing and data analyses

Sequencing data were subjected to Basic Local Alignment Search Tool (BLAST) searches (http://www.ncbi.nlm.nih.gov/blast/) and then aligned and analyzed with reference sequences downloaded from GenBank. Phylogenetic trees were constructed based on the sequence distance method using the neighbor-joining algorithms implemented in the Molecular Evolutionary Genetics Analysis MEGA 7.0 (http://www.megasoftware.net) software (Kumar et al., 2016).

3. Results

Three intestinal protozoa, namely, *Sarcocystis albifronsi*, *Eimeria alpacae*, and *Cystoisospora felis*, were found in three Eurasian lynxes. The nPCR and sequence analyses revealed that: (*i*) *S. albifronsi* and *E. alpacae* were found in Eurasian lynx #2, and (*ii*) *C. feils* was found in Eurasian lynx cub #3.

BLAST analyses showed that: (i) *S. albifronsi* detected in this study showed 99.28% identity (415/418 bp) with *S. albifronsi* detected in Lithuania from *Anser albifrons* (MH138310); (*ii*) *E. alpacae* showed 99.06% (421/425 bp) identity with imported alpaca (*Vicugna pacos*) in China (OQ628303); and (*iii*) *C. feils* showed 100% identity with domestic cats in Canada (KT184364). Phylogenetic trees analysis further confirmed these results (Figs. 1–3).

All sequences from this study were deposited in the GenBank (http://www. ncbi.nlm.nih.gov) database (*S. albifronsi COI*: OR498647; *E. alpacae COI*: OR576777; *C. feils 18S rRNA*: OR525854).

4. Discussion

In the present study, we detected *S. albifronsi*, *E. alpacae*, and *C. felis* in Eurasian lynx. Among these pathogens, *S. albifronsi* and *E. alpacae* were detected in Eurasian lynx for the first time, to the best of our knowledge. In addition, *C. felis* was firstly detected in Eurasian lynx in China.

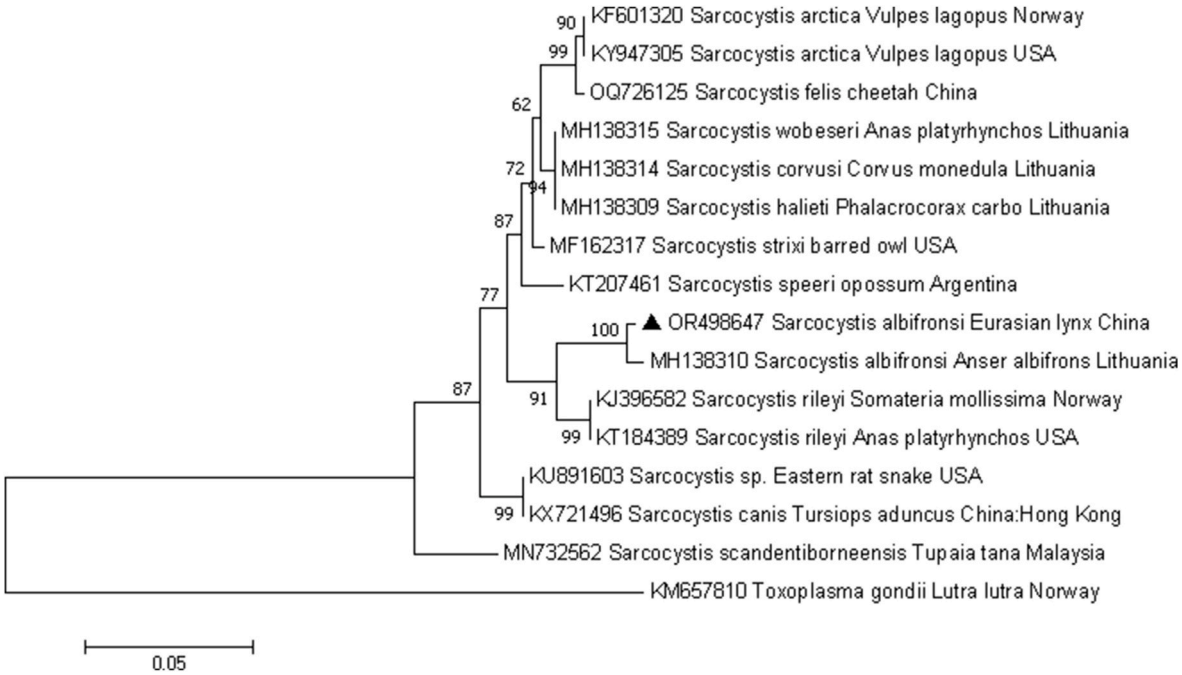

Fig. 1. Phylogenetic tree based on partial gene of the *COI* sequence of *Sarcocystis albifronsi* (▲) from Eurasian lynx #2 obtained in this study in northwestern China. The evolutionary history was inferred using the neighbor-joining method (bootstrap replicates: 1000) with MEGA 7.0.

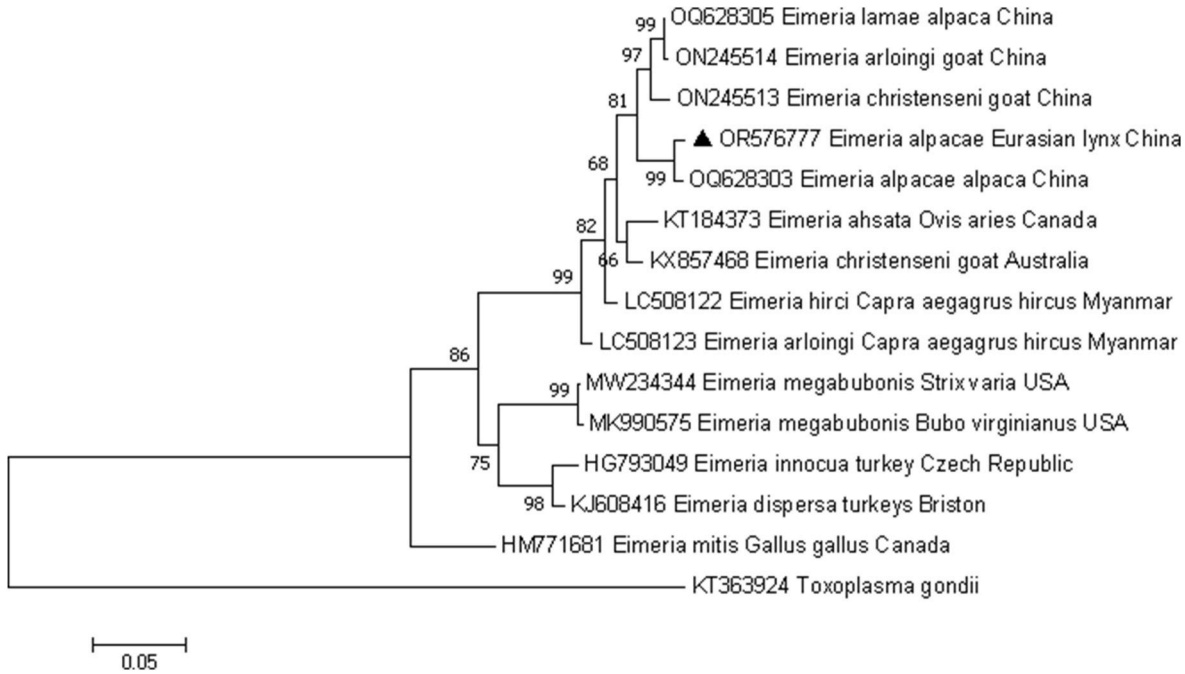

Fig. 2. Phylogenetic tree based on partial gene of the *COI* sequence of *Eimeria alpacae* (▲) from Eurasian lynx #2 obtained in this study in northwestern China. The evolutionary history was inferred using the neighbor-joining method (bootstrap replicates: 1000) with MEGA 7.0.

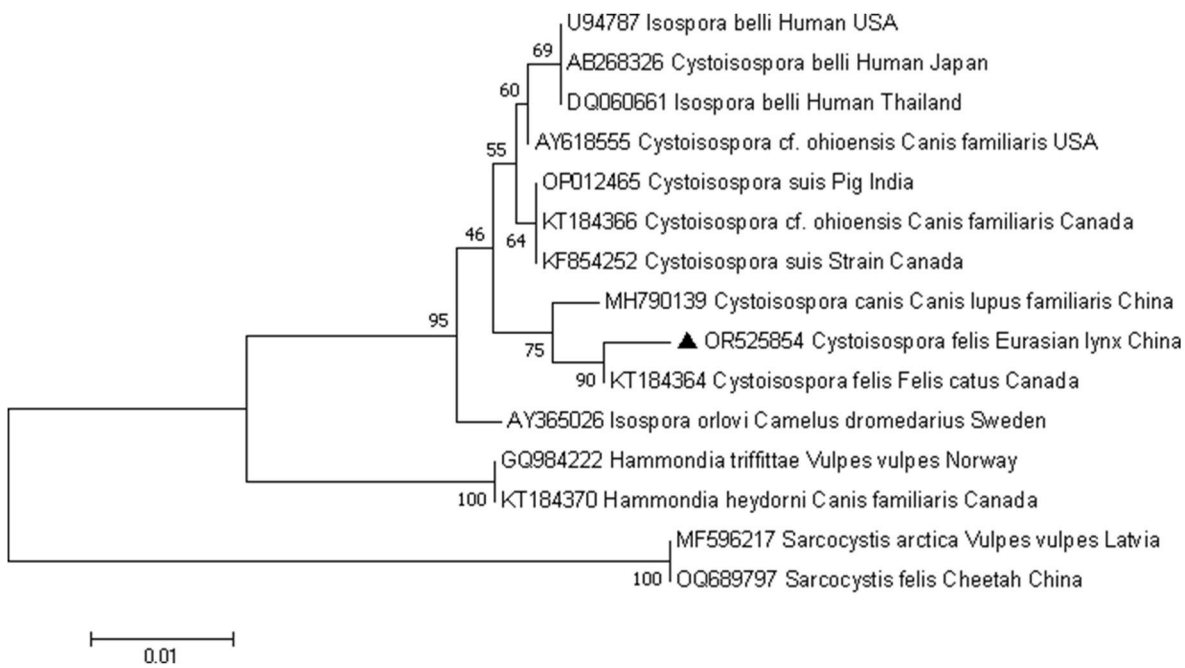

Fig. 3. Phylogenetic tree based on partial gene of the *18S rRNA* sequence of *Cystoisospora felis* (▲) from Eurasian lynx cub #3 obtained in this study in northwestern China. The evolutionary history was inferred using the neighbor-joining method (bootstrap replicates: 1000) with MEGA 7.0.

Previously, bobcats (*Lynx rufus*) were reported as intermediate host for *Sarcocystis* spp. (Verma, et al., 2015). *Sarcocystis* species are characterized by a heteroxenous life cycle, and they depend on the prey–predator relationship for their transmission (Dubey et al., 2015a). In previous studies conducted in feces of *Lynx* genus, *Sarcocystis neurona* in Canadian lynx (*Lynx canadensis*), and *S. neurona* and *Sarcocystis dasypi* in bobcat (*Lynx rufus*) were reported (Dubey et al., 2015b, 2023; Marchiondo et al., 2011; Watson et al., 1981). *S. albifronsi* infection is commonly found in birds (Máca and González-Solís, 2021; Prakas et al., 2023; Scioscia et al., 2017). In this study, *S. albifronsi* was detected in the small intestines of Eurasian lynx #2, which suggests that Eurasian lynx may be infected through feeding on infected birds, such as *Lyrurus tetrix, Tetrao urogallus*, *Alectoris chukar*, and *Tetraogallus himalayensis*, thus acting as definitive hosts (Premier et al., 2021). Therefore, a field survey on free-living birds in West Junggar Mountain should be conducted to understand the life cycle of *S. albifronsi*. Based on current knowledge, canids, mustelids, and felines are most likely the definitive hosts of *S. albifronsi*. Future studies should expand on these investigations by including more carnivores and even omnivores.

Eimeria species, belonging to Coccidiasina (Coccidia), are a group of

obligate intracellular parasites of great medical and veterinary importance as pathogens that cause various human and veterinary diseases worldwide (Shirley et al., 2005). All of the members of the Coccidia subclass replicate within the intestines of definitive hosts (e.g., *Cryptosporidium parvum*, *Toxoplasma gondii*, and *Neospora caninum*) through sequential rounds of asexual (schizogony) and sexual (gametogony) reproduction, culminating in the production of oocysts that are shed into the environment through feces (Lu et al., 2021). *E. alpacae*, an emerging protozoan pathogen, was previously found only in local and imported alpacas in Peru and Japan (Gomez-Puerta et al., 2021; Hyuga and Matsumoto, 2016). In this study, *E. alpacae* was found in adult male Eurasian lynx #2. Interestingly, in West Junggar Mountain, alpacas are not present, but animals that belong to *Felidae*, *Camelidae*, *Bovidae*, *Antelope*, *Leporidae*, and *Cervidae* are present. Thus, future studies should investigate the presence of *E. alpacae* in ruminants. Eurasian lynx is listed as the largest animal in the *Lynx* genus, and the weight of an adult male is approximately 18–30 kg (Viranta et al., 2016). The feces analysis of Eurasian lynx showed that its prey spectrum included mountain hare (*Lepus timidus*), cape hare (*Lepus capensis*), long-tailed ground squirrel (*Spermophilus undulatus*), and Siberian ibex (*Capra sibirica*) (Premier et al., 2021). In the future, an in-depth investigation into the presence of *Eimeria* spp. In felids in West Junggar Mountain should be conducted.

C. felis can cause clinical coccidiosis, characterized by severe diarrhea, which is dangerous, especially for young animals (Scorza et al., 2021). In this study, Eurasian lynx cub #3 was found to have yellow loose stools around its anus. Furthermore, Eurasian lynx cub #3 was found to be infected with *C. felis*. Previously, *C. felis* has been reported in various wild felids, such as jaguar cub (*Panthera onca*) in Mexico, domestic cats in Dubai and Nepal, African lion (*Panthera leo*) in Zimbabwe, leopard (*Panthera pardus*) in China (Adhikari et al., 2023; Guzmán-Lara et al., 2020; Hou et al., 2020; Mukarati et al., 2013; Schuster et al., 2009), and Eurasian lynx in Germany (Jokelainen et al., 2013). To the best of our knowledge, this study is the first to report on the detection of *C. felis* in Eurasian lynx in northwestern China. Future studies should investigate the presence of *C. felis* in felids in adjacent countries, such as Mongolia, Russia, Kazakhstan, Kyrgyzstan, Tajikistan, Afghanistan, Pakistan, and India.

In this study, although *S. albifronsi* and *E. alpacae* were detected in feces of Eurasian lynx #2, we still couldn't conclusively determine that this was a co-infection, as for the protozoans corresponding to the lynx's prey was possible. In the future, the detection in other organs of Eurasian lynx, such as heart muscle and brain, should be further done (Forest et al., 2000; Verma et al., 2015). To better understand the effect of these parasites on the health and conservation of Eurasian lynx, future studies should identify the pathogen profile through metagenomic next-generation sequencing.

It is necessary to acknowledge the limitations of this work, the morphological staining of three intestinal protozoa and histopathology of the intestine should be carried out to further confirm the protozoan infection of three Eurasian lynxes.

5. Conclusions

We detected three intestinal protozoa, namely, *S. albifronsi*, *E. alpacae*, and *C. felis*, in Eurasian lynx. One of the lynxes (Eurasian lynx #2) was detected with *S. albifronsi* and *E. alpacae*. To the best of our knowledge, *S. albifronsi* and *E. alpacae* were detected in Eurasian lynx for the first time. In addition, *C. felis* was detected in Eurasian lynx. These findings extend our knowledge of the geographical distribution and host range of intestinal protozoa. Further surveillance on protozoan infection of other mammalian wildlife in this region should be conducted.

Ethical approval and consent to participate

This study was reviewed and approved by the ethics committee of School of Medicine, Shihezi University in accordance with the medical regulations of China (Approval numbers 2015-063-01 and A2018-144-01).

Funding

This work was supported in part by the State Key Laboratory of Pathogenesis, Prevention and Treatment of High Incidence Diseases in Central Asia [grant numbers SKL-HIDCA-2022-GR1], the Natural Science Foundation of China [grant numbers 82260399 and 82260410], Natural Science Key Project of Xinjiang Uygur Autonomous Region [grant numbers 2022B03014], High-Level Talent Initiative Foundation of Shihezi University [grant numbers RCZK202369], and Key Scientific and Technological Projects in Key Areas of XPCC [grant numbers 2022AB014].

Availability of data and materials

The sequences obtained and analyzed during the present study are deposited in the GenBank database under the accession numbers OR498647 (*Sarcocystis albifronsi*), OR576777 (*Eimeria alpacae*) and OR525854 (*Cystoisospora felis*).

Consent for publication

Not applicable.

Declaration of competing interest

The authors declare that they have no competing interests.

Acknowledgements

The author would like to thank all the veterinarians who participated in the study as well as all the colleagues who contributed to sample collecting and sample preparation.

Appendix A. Supplementary data

Supplementary data to this article can be found online at https://doi.org/10.1016/j.ijppaw.2024.100923.

References

Ablimit, A., Hu, D.F., Ai, M., 1998. Study on the ecology, distribution, resource and protection strategies of Lynx lynx in Xinjiang. Arid Zone Res. 15, 38–43.

Adhikari, R.B., Dhakal, M.A., Ale, P.B., Regmi, G.R., Ghimire, T.R., 2023. Survey on the prevalence of intestinal parasites in domestic cats (*Felis catus* Linnaeus, 1758) in central Nepal. Vet. Med. Sci. 9 (2), 559–571.

Castelló, J.R., 2020. Felids and Hyenas of the World: Wildcats, Panthers, Lynx, Pumas, Ocelots, Caracals, and Relatives. Princeton University Press, Princeton and Oxford.

Dubey, J.P., Calero-Bernal, R., Rosenthal, B.M., Speer, C.A., Fayer, R., 2015a. Sarcocystosis of Animals and Humans, second ed. CRC Press.

Dubey, J.P., de Araujo, L.S., Gupta, A., Kwok, O.C.H., Lovallo, M.J., 2023. Sarcocystis and other parasites in feces of bobcats (LYNX rufus) from Mississippi. J. Parasitol. 109 (6), 638–642.

Dubey, J.P., Houk, A.E., Verma, S.K., Calero-Bernal, R., Humphreys, J.G., Lindsay, D.S., 2015b. Experimental transmission of *Cystoisospora* felis-like coccidium from bobcat (*Lynx rufus*) to the domestic cat (*Felis catus*). Vet. Parasitol. 211 (1–2), 35–39.

Figueiredo, A.M., de Carvalho, L.M., González, M.J.P., Torres, R.T., Pla, S., Núñez-Arjona, J.C., Rueda, C., Vallverdú-Coll, N., Silvestre, F., Peña, J., Carmena, D., Habela, M.A., Calero-Bernal, R., Fonseca, C., Nájera, F., 2021. Parasites of the reintroduced iberian Lynx (*Lynx pardinus*) and sympatric mesocarnivores in extremadura, Spain. Pathogens 10 (3), 274.

Forest, T.W., Abou-Madi, N., Summers, B.A., Tornquist, S.J., Cooper, B.J., 2000. *Sarcocystis* neurona-like encephalitis in a Canada lynx (*Felis lynx canadensis*). J. Zoo Wildl. Med. 31 (3), 383–387.

Frey, C.F., Schuppers, M.E., Müller, N., Ryser-Degiorgis, M.P., Gottstein, B., 2009. Assessment of the prevalence of *Trichinella* spp. in red foxes and Eurasian lynxes from Switzerland. Vet. Parasitol. 159 (3–4), 295–299.

Gang, L., Shuo, Z., Sándor, H., Meihua, Y., Wurelihazi, H., Xinli, G., Yuanzhi, W., 2020. *Rickettsia aeschlimannii* and *Wolbachia endosymbiont* in *Ctenocephalides canis* from Eurasian lynx (*Lynx lynx*) near the China-Kazakhstan border. Kafkas Univ. Vet. Fak Derg. 26 (5), 711–715.

Gomez-Puerta, L.A., Carrasco, J., Robles, K., Vargas-Calla, A., Cribillero, N.G., Arroyo, G., Castillo, H., Lopez-Urbina, M.T., Gonzalez, A.E., 2021. Coccidiosis in clinically asymptomatic alpaca (*Vicugna pacos*) crias from the Peruvian Andes. Parasitol. Int. 85, 102438.

Guzmán-Lara, M.D., Kruth, P.S., Rangel-Díaz, J., Juárez-Estrada, M.A., Soriano-Vargas, E., Barta, J.R., 2020. *Cystoisospora felis* infection in a captive jaguar cub (*Panthera onca*) in Michoacán, México. Vet. Parasitol., Region. Stud. Rep. 19, 100371.

Hosseini, S.M., Moshrefi, A.H., Esfandiyari, A., Youssefi, M.R., Nassiri, A., 2020. First report of *Joyeuxiella* spp. infection in eurasian Lynx and its histopathology study from Iran: a case report. Iran. J. Parasitol. 15 (2), 282–286.

Hou, Z., Peng, Z., Ning, Y., Liu, D., Chai, H., Jiang, G., 2020. An initial coprological survey of parasitic fauna in the wild Amur leopard (*Panthera pardus orientalis*). Integr. Zool. 15 (5), 375–384.

Hyuga, A., Matsumoto, J., 2016. A survey of gastrointestinal parasites of alpacas (*Vicugna pacos*) raised in Japan. J. Vet. Med. Sci. 78 (4), 719–721.

Jokelainen, P., Deksne, G., Holmala, K., Näreaho, A., Laakkonen, J., Kojola, I., Sukura, A., 2013. Free-ranging Eurasian lynx (*Lynx lynx*) as host of Toxoplasma gondii in Finland. J. Wildl. Dis. 49 (3), 527–534.

Ke, L., Yanlin, L., Sheng, L., 2023. The current distribution and prediction of suitable habitat of Eurasian lynx (*Lynx lynx*) in China. Acta Theriol. Sin. 43 (6), 652–663, 2023.

Kumar, S., Stecher, G., Tamura, K., 2016. MEGA7: molecular evolutionary Genetics analysis version 7.0 for bigger datasets. Mol. Biol. Evol. 33 (7), 1870–1874.

Liu, G., Zhao, S., Hornok, S., Chen, X., Wang, S., Tan, W., Gu, X., Wang, Y., 2021. *Taenia laticollis* and a potentially novel *Taenia* species from the Eurasian lynx (*Lynx*) in Northwestern China. Int. J. Parasitol. Parasites Wildlife 16, 183–186.

Lombardo, M.S., Mirolo, M., Brandes, F., Osterhaus, A.D.M.E., Schütte, K., Ludlow, M., Barkhoff, M., Baumgärtner, W., Puff, C., 2023. Case report: canine distemper virus infection as a cause of central nervous system disease in a Eurasian lynx (*Lynx lynx*). Front. Vet. Sci. 10, 1251018.

Lu, C., Yan, Y., Jian, F., Ning, C., 2021. Coccidia-microbiota interactions and their effects on the host. Front. Cell. Infect. Microbiol. 11, 751481.

Máca, O., González-Solís, D., 2021. *Sarcocystis cristata* sp. nov. (Apicomplexa, Sarcocystidae) in the imported great blue turaco Corythaeola cristata (Aves, Musophagidae). Parasites Vectors 14 (1), 56.

Marchiondo, A.A., Karpowitz, J., Conderb, G.A., 2011. Parasite S of the Bobcat (*Lynx rufus* Pallescens) in Central and Southern Utah.

Marti, I., Pisano, S.R.R., Wehrle, M., Meli, M.L., Hofmann-Lehmann, R., Ryser-Degiorgis, M.P., 2019. Severe conjunctivitis associated with *Chlamydia felis* infection in a free-ranging eurasian Lynx (*Lynx lynx*). J. Wildl. Dis. 55 (2), 522–525.

Mukarati, N.L., Vassilev, G.D., Tagwireyi, W.M., Tavengwa, M., 2013. Occurrence, prevalence and intensity of internal parasite infections of African lions (*Panthera leo*) in enclosures at a recreation park in Zimbabwe. J. Zoo Wildl. Med. 44 (3), 686–693.

Ogedengbe, J.D., Hanner, R.H., Barta, J.R., 2011. DNA barcoding identifies *Eimeria* species and contributes to the phylogenetics of coccidian parasites (*Eimeriorina, Apicomplexa, Alveolata*). Int. J. Parasitol. 41 (8), 843–850.

Prakas, P., Moskaliova, D., Šneideris, D., Juozaitytė-Ngugu, E., Maziliauskaitė, E., Švažas, S., Butkauskas, D., 2023. Molecular identification of *Sarcocystis rileyi* and *Sarcocystis* sp. (closely related to *Sarcocystis wenzeli*) in intestines of mustelids from Lithuania. Animals 13 (3), 467.

Premier, J., Gahbauer, M., Leibl, F., Heurich, M., 2021. In situ feeding as a new management tool to conserve orphaned Eurasian lynx (*lynx lynx*). Ecol. Evol. 11 (7), 2963–2973.

Schuster, R.K., Thomas, K., Sivakumar, S., O'Donovan, D., 2009. The parasite fauna of stray domestic cats (*Felis catus*) in Dubai, United Arab Emirates. Parasitol. Res. 105 (1), 125–134.

Scioscia, N.P., Gos, M.L., Denegri, G.M., Moré, G., 2017. Molecular characterization of *Sarcocystis* spp. in intestine mucosal scrapings and fecal samples of Pampas fox (*Lycalopex gymnocercus*). Parasitol. Int. 66 (5), 622–626.

Scorza, A.V., Tyrrell, P., Wennogle, S., Chandrashekar, R., Lappin, M.R., 2021. Experimental infection of cats with *Cystoisospora felis*. J. Vet. Intern. Med. 35 (1), 269–272.

Segeritz, L., Anders, O., Middelhoff, T.L., Winterfeld, D.T., Maksimov, P., Schares, G., Conraths, F.J., Taubert, A., Hermosilla, C., 2021. New insights into gastrointestinal and pulmonary parasitofauna of wild eurasian lynx (*Lynx lynx*) in the Harz mountains of Germany. Pathogens 10 (12), 1650.

Shirley, M.W., Smith, A.L., Tomley, F.M., 2005. The biology of avian *Eimeria* with an emphasis on their control by vaccination. Adv. Parasitol. 60, 285–330.

Simon, A., Bigras Poulin, M., Rousseau, A.N., Dubey, J.P., Ogden, N.H., 2013. Spatiotemporal dynamics of *Toxoplasma gondii* infection in Canadian lynx (*Lynx canadensis*) in western Québec, Canada. J. Wildl. Dis. 49 (1), 39–48.

Sobrino, R., Cabezón, O., Millán, J., Pabón, M., Arnal, M.C., Luco, D.F., Gortázar, C., Dubey, J.P., Almeria, S., 2007. Seroprevalence of *Toxoplasma gondii* antibodies in wild carnivores from Spain. Vet. Parasitol. 148 (3–4), 187–192.

Verma, S.K., Calero-Bernal, R., Lovallo, M.J., Sweeny, A.R., Grigg, M.E., Dubey, J.P., 2015. Detection of *Sarcocystis* spp. infection in bobcats (*Lynx rufus*). Vet. Parasitol. 212 (3–4), 422–426.

Viranta, S., Lommi, H., Holmala, K., Laakkonen, J., 2016. Musculoskeletal anatomy of the Eurasian lynx, *Lynx lynx* (Carnivora: *Felidae*) forelimb: adaptations to capture large prey? J. Morphol. 277 (6), 753–765.

Wasieri, J., Schmiedeknecht, G., Förster, C., König, M., Reinacher, M., 2009. Parvovirus infection in a Eurasian lynx (*Lynx lynx*) and in a European wildcat (*Felis silvestris silvestris*). J. Comp. Pathol. 140 (2–3), 203–207.

Watson, T.G., Nettles, V.F., Davidson, W.R., 1981. Endoparasites and selected infectious agents in bobcats (*Felis rufus*) from West Virginia and Georgia. J. Wildl. Dis. 17 (4), 547–554.

Yang, R., Brice, B., Bennett, M.D., Eliott, A., Ryan, U., 2013. Novel *Eimeria* sp. isolated from a King's skink (*Egernia kingii*) in western Australia. Exp. Parasitol. 133 (2), 162–165.

Zhang, X., Jian, Y., Li, X., Ma, L., Karanis, G., Karanis, P., 2018. The first report of *Cryptosporidium* spp. in *Microtus fuscus* (Qinghai vole) and *Ochotona curzoniae* (wild plateau pika) in the Qinghai-Tibetan Plateau area, China. Parasitol. Res. 117 (5), 1401–1407.

Glossary

COI: cytochrome C oxidase subunit I
18S rRNA: 18S Ribosomal RNA
XUAR: Xinjiang Uygur Autonomous Region