

Endovascular management of spontaneous vertebrovertebral arteriovenous fistula associated with neurofibromatosis 1

Randhi Venkata Narayana, Rajesh Pati, Sibasankar Dalai

Department of Neurology and Interventional Neuroradiology, Seven Hills Hospital, Visakhapatnam, Andhra Pradesh, India

Correspondence: Dr. Sibasankar Dalai, OP No: 12, First Floor, Seven Hills Hospital, Rockdale Layout, Visakhapatnam - 530 017, Andhra Pradesh, India. E-mail: sibasankar@gmail.com

Abstract

Extra cranial vertebrovertebral arteriovenous fistulas (VV AVF) are commonly associated with trauma. Their presentation may vary from palpable thrill and myelopathy or myeloradiculopathy. Sudden onset paraparesis is rare.

Key words: Embolization; neurofibromatosis type 1; NF 1; vertebrovertebral arteriovenous fistula

Introduction

Extracranial vertebrovertebral arteriovenous fistula (VV AVF) is a rare condition. It is commonly caused by trauma, but can be congenital, spontaneous, iatrogenic, idiopathic, or related to dysplastic syndromes. We describe a case of spontaneous VV AVF associated with neurofibromatosis Type 1. The patient presented to us with sudden-onset right arm weakness. He was successfully treated by endovascular embolization.

Case Report

History

A 42-year-old man with neurofibromatosis (NF) Type 1 presented with neck pain, weakness of both the arms, and humming sound on the right side of the neck for past 3 months. The weakness was more on the right arm.

He was admitted for further evaluation and management. His right upper limb power suddenly deteriorated during the hospital stay.

Clinical examination

General examination of the patient revealed multiple cutaneous neurofibromata, *café-au-lait* spots and Lisch nodules, palpable thrill, and a bruit on the right side of the neck. Neurological examination revealed 0/5 power in the right upper limb and 4/5 power in the left upper limb, with brisk deep tendon reflexes in all four limbs.

Investigations

Doppler ultrasonography (Voluson 730, GE) of the right side of the neck demonstrated a high-flow arteriovenous fistula. Computed tomography (CT) (Siemens, Erlangen, Germany) and magnetic resonance imaging (MRI) (Siemens-Symphony, Erlangen, Germany) of cervical spine were done. CT scan showed erosion of the right pedicle [Figure 1A] of C4 vertebra. MRI demonstrated large areas of flow void extending from C4 to C6 with cord compression [Figure 1B]. Detailed digital subtraction angiography (DSA) (Siemens, Erlangen, Germany) of cerebral circulation was done subsequently. DSA demonstrated a high-flow vertebrovertebral arteriovenous fistula (VV AVF) connecting the right vertebral artery (VA) at its origin to the vertebral venous

Access this article online

Quick Response Code:



Website:
www.ijri.org

DOI:
10.4103/0971-3026.150132

plexus [Figure 2A]. There were multiple intersegmental collaterals bilaterally, supplied via right ascending cervical arteries [Figure 2B]. There were large venous pouches with drainage into the intraspinal extradural and paraspinal venous plexus. The anterior cerebral circulation was normal in all phases of the angiogram. There was no filling of the fistula from the anterior circulation. The vertebrobasilar circulation was normal otherwise, except the VV AVF.

Treatment

The patient was planned for embolization of the VV AVF with detachable coils under general anesthesia. During intubation, the patient was found to have short mento-thyroid distance. Hence, fiberoptic bronchoscopy-assisted intubation was done. A 6-Fr femoral short sheath was placed into the right common femoral artery. A 6-Fr envoy-guiding catheter (Codman Neurovascular, Raynham, Massachusetts, USA) was placed into the right subclavian artery. The fistula was cannulated with Echelon 14 microcatheter and Xpedion 14 wire (ev3 Endovascular, Inc., Plymouth, MN, USA) through the guiding catheter. The fistula was coiled by placing Axiom 20 × 50 cm (ev3 Endovascular, Inc, Plymouth, MN, USA) as the first coil [Figure 3A]. The coil conformed well to the fistula, but there was no significant flow alteration. Ten more coils (Axiom 20 × 40 mm, 18 × 40 mm, 16 × 30 mm, 16 × 30 mm, 14 × 40 mm, 14 × 30 mm, 12 × 30 mm, 10 × 20 mm, 8 × 16 mm, and 6 × 15 mm) were serially placed into the fistula under roadmap guidance. The flow in the fistula was slower compared to the pre-embolization state. However, further coils could not be pushed with repeated attempts, as the microcatheter came out of the fistula during the placement of the last coil. Right subclavian artery angiogram as well as left VA angiogram demonstrated residual fistula. Second session of embolization was planned.

Stage II embolization

The patient was observed for 3 months. At the end of 3 months, there was only a partial improvement in neurological status with significant residual deficits. Hence, an angiogram with possible stage II embolization was planned. The fistula was cannulated from the left VA through the vertebrobasilar junction into the right VA with the combination of Echelon 14 microcatheter with Xpedion 14 microwire [Figure 3B]. The fistula was coiled by serial placement of four coils (Axiom 8 × 20 mm, 7 × 15 mm, 6 × 15 mm, and 5 × 12 mm) into the fistula and the adjacent VA. Check angiogram demonstrated residual filling of the fistula. subsequently it was decided to embolize the residual fistula with glue (*n*-butyl cyanoacrylate) and lipiodol from the ascending right cervical artery. For this, 66% glue was prepared by mixing appropriate amount of lipiodol. A total volume of 5 ml of glue was prepared and 3.5 ml of which was injected. The microcatheter was flushed with

5% dextrose. Under blank roadmap, the 66% glue was injected into the fistula in less than 45 sec. The check angiogram demonstrated complete exclusion of the fistula from the circulation [Figure 3C]. The final angiogram from the left VA and right subclavian artery demonstrated complete cure of the fistula with stable coil and glue mass [Figure 3D]. Patient was shifted to intensive care after the embolization and extubated after 6 h.

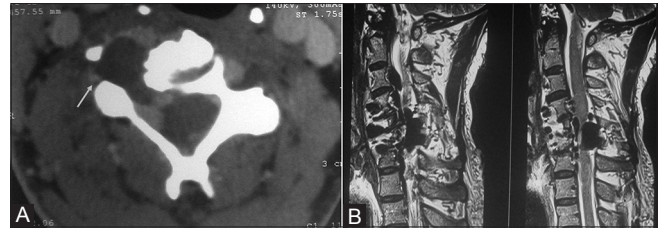


Figure 1 (A and B): (A) CT scan demonstrating defect in the pedicle due to erosion (B) MRI demonstrating the fistula with high flow voids with features of venous hypertension as suggested by high T2 signals in the cervicomedullary junction in the second panel

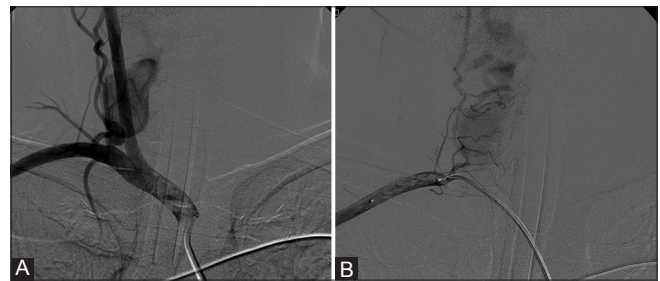


Figure 2 (A and B): (A) Right subclavian artery angiogram demonstrating the VV AVF supplied by right vertebral artery (B) VV AVF additionally supplied through right ascending cervical artery

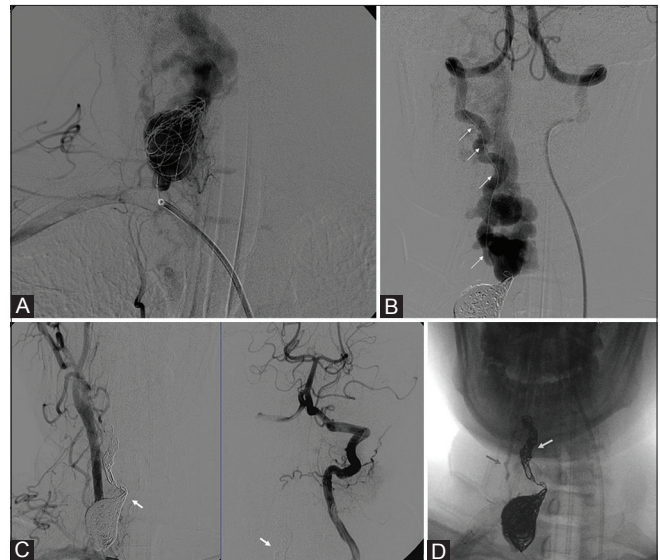


Figure 3 (A-D): (A) Coiling from right vertebral artery access, (B) Access of the fistula from left VA through vertebrobasilar junction, (C) Post embolization vertebral and brachiocephalic angiogram demonstrating complete cure of the fistula, (D) Coil mass in the fistula

Immediately after the procedure, there was no humming sound and the thrill disappeared. The right upper limb power improved to 4/5 and the left upper limb power to 5/5 over the next 72 h. The patient was discharged a week after the procedure and subsequently followed-up at 3, 6, and 12 months. There was no neurological deficit at follow-up. Doppler USG at the end of 3 months and 1 year showed no residual fistula.

Discussion

VV AVFs are classified either as segmental and intersegmental types or as upper and lower cervical groups. In the segmental type, the fistula involves the VA branch, and in the intersegmental type, VA itself is involved. Trauma is the commonest cause of VV AVF.^[1] Traumatic fistulas are most commonly of iatrogenic cause, secondary to internal jugular vein puncture or neck surgery. Spontaneous VV AVF is least common and is associated with various vascular dysplastic disorders like NF, fibromuscular dysplasia, Marfan's syndrome, or Ehlers-Danlos syndrome type IV.^[2-4] There are limited number of case reports of a spontaneous VVF associated with NF1. The majority of patients are female.^[5] Symptomatology of VV AVFs varies according to the site of the fistula and its flow pattern. Clinical manifestations may vary from a simple bruit to radiculopathy, myeloradiculopathy, and myelopathy. Our case was a spontaneous VV AVF associated with NF 1. The patient presented with features of cervical cord compression and a palpable thrill. The proposed pathogenesis of VV AVF in dysplastic syndromes is dysplastic smooth muscle proliferation in the vessel wall leading to vasculopathy, aneurysm formation, leakage, and rupture into the adjacent vein.^[4]

The goal of treatment should be occlusion of the fistula site. This can be achieved by endovascular means and is the treatment of choice in most cases. Surgical treatment is difficult and dangerous due to proximity of important neurovascular structures. Various endovascular techniques can be employed to occlude the fistula, such as transarterial detachable balloons,^[6] stent grafts, transarterial coiling, and trapping of parent vessel with coils.^[7,8] Combined transarterial, transvenous,^[9] and direct percutaneous embolization with coils and liquid embolics have been described for treatment of VV AVFs. A combination of coils and balloons or coils and glue/onyx can be used for successful occlusion of fistulas in some situations.^[10] Onyx is a newer liquid embolic agent and allows a longer injection time with high volume of embolic materials, hence producing more stable results with lesser complications.

We did transarterial embolization of the fistula from

both the VAs with a combination of coils and *n*-butyl cyanoacrylate (glue). A complete occlusion of the fistula could be achieved without any complications and with a good clinical outcome.

Conclusion

VV AVF is a rare condition of abnormal connection between VAs and/or its branches and vertebral venous plexus. Endovascular treatments of VV AVF are safe and efficacious. High-flow VV AVF needs detailed angiographic study and proper planning for successful endovascular treatment.

References

1. Gobin YP, Duckwiller GR, Viñuela F. Direct arteriovenous fistulas (carotid-cavernous and vertebral-venous). Diagnosis and intervention. *Neuroimaging Clin N Am* 1998;8:425-43.
2. Bahar S, Chiras J, Carpena JP, Meder JF, Bories J. Spontaneous vertebro-vertebral arterio-venous fistula associated with fibro-muscular dysplasia. Report of two cases. *Neuroradiology* 1984;26:45-9.
3. Kähärä V, Lehto U, Ryymin P, Helén P. Vertebral epidural arteriovenous fistula and radicular pain in neurofibromatosis type I. *Acta Neurochir (Wien)* 2002;144:493-6.
4. Hauck EF, Nauta HJ. Spontaneous spinal epidural arteriovenous fistulae in neurofibromatosis type-1. *Surg Neurol* 2006;66:215-21.
5. Patro SN, Gupta AK, Arvinda HR, Jolapara MB, Saini J. Combined transarterial and percutaneous coiling of a spontaneous vertebrovertebral fistula associated with neurofibromatosis Type 1. Case report. *J Neurosurg* 2009;111:37-40.
6. Beaujeux RL, Reizine DC, Casasco A, Aymard A, Rüfenacht D, Khayat MH, *et al.* Endovascular treatment of vertebral arteriovenous fistula. *Radiology* 1992;183:361-7.
7. Miralbes S, Cattin F, Andrea I, Bonneville JF. Vertebral arteriovenous fistula: Endovascular treatment with electrodetachable coils. *Neuroradiology* 1998;40:761-2.
8. Taylor CG, Husami Y, Colquhoun IR, Byrne JV. Direct cervical vertebro-venous fistula with radiculopathy and MRI changes resolving after successful endovascular embolisation: A report of two cases. *Neuroradiology* 2001;43:1118-22.
9. Benndorf G, Assmann U, Bender A, Lehmann TN, Lanksch WR. Vertebral arteriovenous fistula associated with neurofibromatosis type I misdiagnosed as a giant aneurysm. *Interv Neuroradiol* 2001;6:67-74.
10. Siddhartha W, Chavhan GB, Shrivastava M, Limaye US. Endovascular treatment for bilateral vertebral arteriovenous fistulas in neurofibromatosis 1. *Australas Radiol* 2003;47:457-61.

Cite this article as: Narayana RV, Pati R, Dalai S. Endovascular management of spontaneous vertebrovertebral arteriovenous fistula associated with neurofibromatosis 1. *Indian J Radiol Imaging* 2015;25:18-20.

Source of Support: Nil, **Conflict of Interest:** None declared.