


# Lipoprotein Lipase Deficiency in an Infant With Chylomicronemia, Hepatomegaly, and Lipemia Retinalis

Global Pediatric Health  
Volume 4: 1–4  
© The Author(s) 2017  
Reprints and permissions:  
sagepub.com/journalsPermissions.nav  
DOI: 10.1177/2333794X17715839  
journals.sagepub.com/home/gph  


Dinesha Maduri Vidanapathirana, MBBS, Dip Chem Path<sup>1</sup>,  
Thushara Rodrigo, MBBS, DCH<sup>1</sup>,  
Samantha Waidyanatha, MBBS, MD, MRCP(UK)<sup>1</sup>,  
Eresha Jasinge, MBBS, Dip Chem Path, MD<sup>1</sup>,  
Amanda J. Hooper, BSc(Hons), PhD<sup>2,3</sup>,  
and John R. Burnett, MBChB, MD, PhD, FRCPA<sup>2,3</sup>


Received March 21, 2017. Accepted for publication May 11, 2017

## Introduction

Lipoprotein lipase (LPL; EC 3.1.1.1.34) is a key enzyme needed for the hydrolysis of triacylglycerol in chylomicrons and very low density lipoproteins.<sup>1</sup> LPL deficiency is a rare autosomal recessive disorder with a prevalence of ~1 in 1 000 000 in the United States and higher in other regions of the world.<sup>2</sup> LPL deficiency is characterized biochemically by severe hypertriglyceridemia and clinically by features including failure to thrive, eruptive xanthomas, hepatosplenomegaly, recurrent pancreatitis, and lipemia retinalis.<sup>2</sup> Over 100 mutations in the *LPL* gene have been found in LPL deficiency. Dietary fat restriction is the mainstay of treatment.<sup>3</sup> We report an infant with one novel and one reported mutation within exon 6 of the *LPL* gene who presented with chylomicronemia, hepatomegaly, and lipemia retinalis.

## Case Report

A 1-year-old Sri Lankan boy presented to our pediatric service for evaluation and treatment of an upper respiratory tract infection. He was the second child born by normal vaginal delivery at 38 weeks of gestation following an uneventful pregnancy to healthy, nonconsanguineous parents. The birth and neonatal course was unremarkable, and he was exclusively breast fed. On clinical examination, the infant was found to have mild hepatomegaly with a palpable liver 2 cm below the right costal margin. During the assessment, blood samples were taken and were noted by the laboratory to be grossly lipemic. A lipid profile revealed a triglyceride concentration of 4910 mg/dL (normal 29-99), with a total cholesterol of 370 mg/dL (normal 114-203). The serum after standing overnight at 4°C in a refrigerator showed a creamy layer on top with



**Figure 1.** Lipemic serum on admission.

turbidity below, consistent with the diagnosis of chylomicronemia (Figure 1).

There were no eruptive xanthomas or epigastric abdomen pain; however, fundoscopy revealed the presence of lipemia retinalis. His elder sister was in good

<sup>1</sup>Lady Ridgeway Hospital, Colombo, Sri Lanka

<sup>2</sup>Royal Perth Hospital and Fiona Stanley Hospital Network, Perth, Western Australia, Australia

<sup>3</sup>University of Western Australia, Crawley, Western Australia, Australia

### Corresponding Author:

DineshaMaduriVidanapathirana, Department of Chemical Pathology, Lady Ridgeway Hospital, Colombo 08, 00800, Sri Lanka.  
Email: maduri129@yahoo.com



**Table 1.** Lipid Profiles of the Proband's Nuclear Family.

Analyte	Father	Mother <sup>a</sup>	Sister
Triglyceride (mg/dL)	173 (52-316)	71 (40-205)	69 (34-112)
Total cholesterol (mg/dL)	184 (142-267)	143 (139-249)	135 (112-200)
HDL cholesterol (mg/dL)	33 (29-62)	45 (34-82)	38 (36-76)
LDL cholesterol (mg/dL)	116 (81-189)	83 (75-172)	82 (63-129)
Total cholesterol/HDL ratio	5.58	3.18	3.55

Abbreviations: HDL, high-density lipoprotein; LDL, low-density lipoprotein.

Reference intervals are provided in brackets.

<sup>a</sup>Mother is currently on hypolipidemic drugs.

health. His mother gave a history of dyslipidemia diagnosed at 30 years of age for which she was receiving lipid-lowering therapy (Table 1).

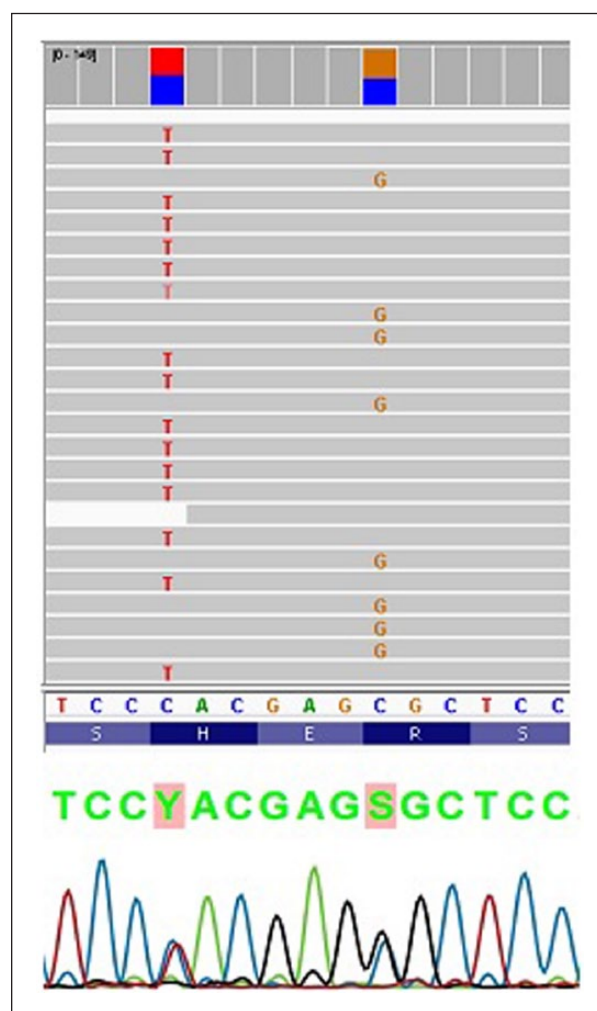
Liver function and renal function testing was normal, as was serum uric acid, but his plasma lactate was increased at 27.3 mg/dL (4.5-19.8). A full blood picture revealed a mild microcytic, hypochromic anemia. Abdominal ultrasonography confirmed mild hepatomegaly with a moderate degree of splenomegaly.

DNA was isolated from peripheral blood and the sample analyzed using massive parallel sequencing of lipid genes with targeted analysis of monogenic hypertriglyceridemia genes (*LPL*, *APOA5*, *APOC2*, *APOE*, *LMF1*, *GPIHBP1*, *APOC3*, *GPD1*) and common variants affecting plasma triglycerides. The patient was found to be compound heterozygous for 2 likely pathogenic *LPL* variants, c.802C>T (p.His268Tyr) and c.808C>G (p.Arg270Gly). The 2 variants were located only 6 nucleotides apart, and by inspection of the sequencing BAM file it was able to be determined that the 2 variants were present on different alleles, confirming that the patient was a true compound heterozygote (Figure 2). The patient was also found to be heterozygous for *APOA5* c.-644T>C, a common variant associated with an increased risk of hypertriglyceridemia.<sup>4</sup>

The infant was commenced on a low-fat diet along with fenofibrate 67 mg once daily and omega-3 fish oil one tablet daily. His regular follow-up includes the monitoring of growth parameters and lipid levels.

## Discussion

Familial chylomicronemia syndrome is an autosomal recessive disorder that results from LPL deficiency, apolipoprotein C-II deficiency, or other defects in the LPL pathway.<sup>2</sup> LPL is synthesized in myocytes and adipocytes and plays a role in multiple stages of lipid metabolism, including hydrolysis of chylomicrons and very low density lipoproteins. Mutations in *APOA5*, a co-factor for LPL, lipase maturation factor 1 (*LMF1*), required for the secretion of mature LPL, and glycosylphosphatidylinositol-anchored high-density lipoprotein-binding



**Figure 2.** *LPL* c.802C>T (p.His268Tyr) and c.808C>G (p.Arg270Gly), identified by massively parallel sequencing, occur on separate alleles (upper panel, reference sequence shown below) and were confirmed by Sanger sequencing of *LPL* exon 6 (lower panel).

protein 1 (*GPIHBP1*), which transports LPL to the capillary lumen, are associated with familial chylomicronemia syndrome.<sup>5</sup>

The clinical manifestations of LPL deficiency are heterogeneous. When triglyceride levels are >2000 mg/dL, eruptive xanthomas appear mostly on shoulders, buttocks, and extensor surfaces of the limbs.<sup>3</sup> Furthermore, lipemia retinalis is observed when triglyceride levels exceed 2500 mg/dL.<sup>6</sup> Abdominal pain and gastrointestinal hemorrhage have been attributed to hyperviscosity secondary to hypertriglyceridemia.<sup>7</sup> Pancreatitis is common in these patients and risk increases with triglyceride levels greater than 1000 mg/dL.<sup>8</sup> Most clinical signs and symptoms of LPL deficiency are attributed to the hypertriglyceridemia.<sup>3</sup> Our patient clinically had only lipemia retinalis and hepatomegaly.

In the presence of extremely elevated triglyceride levels and moderately elevated cholesterol levels, and lipemic serum with lipemia retinalis, the possibility of familial chylomicronemia syndrome was considered. Glycogen storage disease type 1 was also in the differential diagnosis given the hypertriglyceridemia, hepatomegaly, and elevated lactate, although the normal uric acid made this less likely. The absence of any neurological symptoms, despite the presence of hepatosplenomegaly, effectively excluded infantile onset Niemann-Pick disease type C.

Genetic studies revealed that the proband was a compound heterozygote for one novel and one previously reported pathogenic variant within exon 6 of the *LPL* gene. The novel missense variant *LPL* p.His268Tyr is predicted to be pathogenic according to in silico algorithms (PolyPhen2, SIFT, and Mutation Taster). The second variant, *LPL* p.Arg270Gly missense variant, is also predicted to be pathogenic by in silico algorithms, and is present at a very low frequency in the ExAC population database.<sup>9</sup> *LPL*Arg270Gly has previously been reported in a Sri Lankan child diagnosed with hyperlipidemia and hepatosplenomegaly, who was homozygous for this variant.<sup>10</sup> Other variants causing LPL deficiency have been reported at this same amino acid position—Arg270His and Arg270Cys.<sup>11</sup>

Dietary fat restriction remains the mainstay of treatment for LPL deficiency. While drug therapy using fibrates, omega-3 fatty acids, and orlistat may decrease triglyceride levels when combined with a fat-restricted diet, the use of these agents is controversial.<sup>3</sup> Promising treatment approaches currently under investigation include an orally administered diacylglycerol *O*-acyltransferase 1 (DGAT1) inhibitor (pradigastat), which catalyzes the final step in triglyceride synthesis and decrease chylomicron-triglyceride secretion, and evinacumab, a monoclonal antibody to angiopoietin-like protein 3 (ANGPTL3), an inhibitor of LPL and endothelial lipase.<sup>12,13</sup> An expensive LPL gene replacement therapy (Glybera) has been approved in Europe, although its use is currently restricted

to the most severely affected patients with LPL deficiency and recurrent pancreatitis.<sup>14</sup>

In summary, we report an infant with LPL deficiency due to one novel and one reported mutation within exon 6 of the *LPL* gene who presented with chylomicronemia, hepatomegaly, and lipemia retinalis.

## Acknowledgments

We thank Ms Lan Nguyen for assistance with DNA sequencing.

## Author Contributions

DMV: Substantially contributed to conception or design; drafted the manuscript; agrees to be accountable for all aspects of the work in ensuring that questions relating to the accuracy or integrity of any part of the work are appropriately investigated and resolved.

TR: Contributed to conception and design; contributed to acquisition and interpretation.

SW: Critically revised manuscript.

EJ: Critically revised manuscript; gave final approval.

AJH: Contributed to analysis and interpretation; drafted manuscript.

JRB: Contributed to analysis and interpretation; gave final approval.

## Declaration of Conflicting Interests

The author(s) declared no potential conflicts of interest with respect to the research, authorship, and/or publication of this article.

## Funding

The author(s) received no financial support for the research, authorship, and/or publication of this article.

## References

1. Nampoothiri S, Radhakrishnan N, Schwentek A, Hoffmann MM. Lipoprotein lipase deficiency in an infant. *Indian Pediatr*. 2011;48:805-806.
2. Brunzell JD. Familial lipoprotein lipase deficiency. *GeneReviews*. <https://www.ncbi.nlm.nih.gov/books/NBK1308/>. Accessed June 8, 2017.
3. Mohandas MK, Jemila J, Ajith Krishnan AS, George TT. Familial chylomicronemia syndrome. *Indian J Pediatr*. 2005;72:181.
4. Wang J, Ban MR, Zou GY, et al. Polygenic determinants of severe hypertriglyceridaemia. *Hum Mol Genet*. 2008;17:2894-2899.
5. Davies BS, Beigneux AP, Fong LG, Young SG. New wrinkles in lipoprotein lipase biology. *Curr Opin Lipidol*. 2012;23:35-42.
6. Zahavi A, Snir M, Kella YR. Lipemiaretinalis: case report and review of the literature. *J AAPOS*. 2013;17:110-111.
7. Rosenson RS, Shott S, Tangney CC. Hypertriglyceridemia is associated with an elevated blood viscosity. *Atherosclerosis*. 2002;161:433-439.

8. Yuan G, Al-Shali KZ, Hegele RA. Hypertriglyceridemia: its etiology, effects and treatment. *CMAJ*. 2007;176:1113-1120.
9. ExAC (Exome Aggregation Consortium). <http://exac.broadinstitute.org/>. Accessed June 8, 2017.
10. Sirisena ND, Neththikumara N, Wetthasinghe K, Dissanayake VH. Implementation of genomic medicine in Sri Lanka: initial experience and challenges. *Appl Trans Genom*. 2016;9:33-26.
11. Ma Y, Liu MS, Chitayat D, et al. Recurrent missense mutations at the first and second base of codon Arg243 in human lipoprotein lipase in patients of different ancestries. *Hum Mutat*. 1994;3:52-58.
12. Meyers CD, Tremblay K, Amer A, Chen J, Jiang L, Gaudet D. Effect of the DGAT1 inhibitor pradigastat on triglyceride and apoB48 levels in patients with familial chylomicronemia syndrome. *Lipids Health Dis*. 2015;14:8.
13. Gaudet D, Gipe DA, Pordy R, Sasiela W, Chan KC, Khoury E. Safety and efficacy of evinacumab, a monoclonal antibody to ANGPTL3, in patients with homozygous familial hypercholesterolemia receiving concomitant lipid-lowering therapies. *J Clin Lipidol*. 2016;10(3):715.
14. Scott LJ. Alipogene tiparvovec: a review of its use in adults with familial lipoprotein lipase deficiency. *Drugs*. 2015;75:175-182.