

Intradural extramedullary capillary hemangioma of the cauda equina: Case report and literature review

Jonathan J. Liu, Darrin J. Lee, Lee-Way Jin¹, Kee D. Kim

Departments of Neurological Surgery, University of California-Davis, 4860Y. Street, Suite 3740, ¹ Pathology, University of California-Davis, 2805 50th Street, Sacramento, CA. 95817, USA

E-mail: Jonathan J. Liu - jonathan.liu@ucdmc.ucdavis.edu; Darrin J. Lee - Darrin.lee@ucdmc.ucdavis.edu; Lee-Way Jin - lee-way.jin@ucdmc.ucdavis.edu,

*Kee D. Kim - kee.kim@ucdmc.ucdavis.edu

*Corresponding author

Received: 30 September 14 Accepted: 16 December 14 Published: 22 April 15

This article may be cited as:

Liu JJ, Lee DJ, Jin LW, Kim KD. Intradural extramedullary capillary hemangioma of the cauda equina: Case report and literature review. *Surg Neurol Int* 2015;6:S127-31.

Available FREE in open access from: <http://www.surgicalneurologyint.com/text.asp?2015/6/4/127/155701>

Copyright: © 2015 Liu JJ. This is an open-access article distributed under the terms of the Creative Commons Attribution License, which permits unrestricted use, distribution, and reproduction in any medium, provided the original author and source are credited.

Abstract

Background: Capillary hemangiomas are benign vascular tumors that rarely occur in the neuraxis. When encountered in the spine, prompt diagnosis and complete resection is crucial. On rare instances, these lesions can acutely hemorrhage, leading to sudden neurological decline. To date, there are only 16 reported cases of intradural capillary hemangiomas in the cauda equina.

Case Description: We report a case of an intradural extramedullary cauda equina capillary hemangioma that resulted in back pain and lower extremity motor deficit. Initial magnetic resonance (MR) imaging demonstrated a bilobular intradural L3-4 cauda equina lesion. The lesion was isointense on T1-weighted imaging, mildly hyperintense on T2-weighted images and avidly enhancing after gadolinium administration. Pathology confirmed the diagnosis of capillary hemangioma.

Conclusion: Early diagnosis and treatment of this patient resulted in complete resection of the tumor and return of lower extremity motor function. Capillary hemangiomas should be considered in the differential diagnosis of cauda equina lesions. En bloc resection of these lesions is the mainstay of treatment.

Key Words: Capillary hemangioma, cauda equine, intradural, lumbar

Access this article online

Website:

www.surgicalneurologyint.com

DOI:

10.4103/2152-7806.155701

Quick Response Code:



INTRODUCTION

Vascular malformations make up approximately 2–7% of all spinal space-occupying lesions.^[20,21] These include cavernous angiomas, arteriovenous malformations, capillary telangiectasias, and capillary hemangiomas.^[22,26] Capillary hemangiomas are most commonly encountered as cutaneous, subcutaneous, or mucosal soft tissue lesions involving the head and neck in children.^[7,26,27] When encountered in the spine, capillary hemangiomas most frequently involve the vertebral body. Extraosseous involvement of the spine is exceedingly rare.^[15,25]

When encountered in the neuraxis, they are usually seen occupying the epidural space, spinal cord, meninges, or cauda equina. Intradurally, they most commonly occur within the cauda equina or conus medullaris, intimately involved with the nerve roots. In rare cases, there is intraneural growth within the confines of the nerve root sheath.^[12,13,18,21-25] To date, there are only 16 reported cases of intradural capillary hemangiomas in the cauda equina. Here, we report the surgical management of an intradural, extramedullary cauda equina capillary hemangioma and review the literature on this rare entity.

CLINICAL PRESENTATION

Clinical history

A 53-year-old presented with a one year history of back pain and subjective weakness of his right leg. He also had gradual increase in right leg pain involving the posterior aspect of his leg down to his ankle with numbness of his entire right foot. He had no history of bowel incontinence but had complaints of impotence, increased urinary frequency throughout the day, and nocturia. On neurological examination, his motor strength was objectively full throughout the bilateral upper and lower extremities except for a 4+/5 left great toe extension. Deep tendon reflexes were notable for a hyporeflexic left achilles reflex. No pathological reflexes were present.

A magnetic resonance imaging (MRI) of the lumbar spine revealed a bilobular, intradural extramedullary cauda equina lesion at the L3-L4 level that displaced the cauda equina anteriorly. This lesion measured 19 × 12 mm in the sagittal view and 12 × 14 mm in the axial view. On T1-weighted images, the lesion was isointense to the cauda equina [Figure 1a]. After gadolinium administration, the lesion showed avid homogeneous enhancement [Figure 1b]. On T2-weighted imaging, the lesion appeared isointense to mildly hyperintense to the cauda equina [Figure 1c].

Surgery

The patient underwent a L3-4 laminectomy with a midline durotomy. Immediately after the dura was opened, the lesion was visualized. Once the lesion was exposed in all directions, a nerve root was noted to be coursing directly through the tumor. This traversing nerve root was stimulated with resultant right hip flexor firing. The decision was made to transect the intimately involved nerve root to help achieve a complete en bloc resection of the lesion.

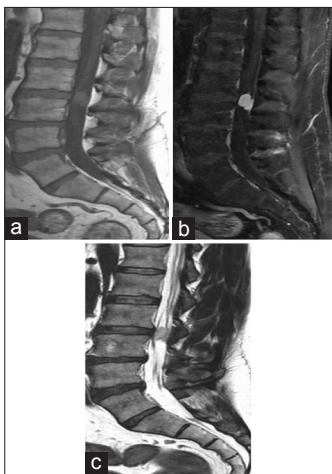


Figure 1: Preoperative sagittal MRI (a) T1 and (b) T1+ Gadolinium showing homogeneous enhancement (c) T2 showing an isointense to mildly hyperintense lesion

Postoperative course

Postoperatively, the patient did not experience any new neurological deficits despite sacrificing the intralaminar nerve root. He improved to full strength in his lower extremities including left great toe extension without new sensory deficits. Postoperative MRI of the lumbar spine showed a gross total resection of the intradural lesion [Figure 2a-d]. He was discharged home on postoperative day two after physical therapy clearance. During his follow-up clinic visit, the patient reported that the preoperative right leg radiculopathy was gone; however, his preoperative right foot numbness persisted.

Histopathology

Grossly, the lesion was tan to pink with an irregular architecture. Microscopic examination showed a well-encapsulated, highly vascular lesion [Figure 3a] that appeared lobulated by fibrous septae with numerous capillaries [Figure 3b]. The neoplasm was composed predominantly of small blood vessels lined by a single layer of oval cells, with sizes ranging from capillary-like to ectatic [Figure 3c]. A subset of neoplastic cells was more plump and showed mild atypia. Occasional mitotic figures were seen. The neoplastic cells were immunoreactive to CD31 [Figure 3d] and CD 34 [Figure 3e], confirming their endothelial nature. These findings were consistent with a histopathologic diagnosis of a capillary hemangioma. The neoplastic cells were negative for inhibin [Figure 3f] and epithelial membrane antigen (EMA), thus eliminating the possibility of hemangioblastoma and meningioma, respectively.

DISCUSSION

Intradural capillary hemangiomas of the cauda equina are exceedingly rare. Table 1 provides an overview of all reported intradural capillary hemangiomas occurring in

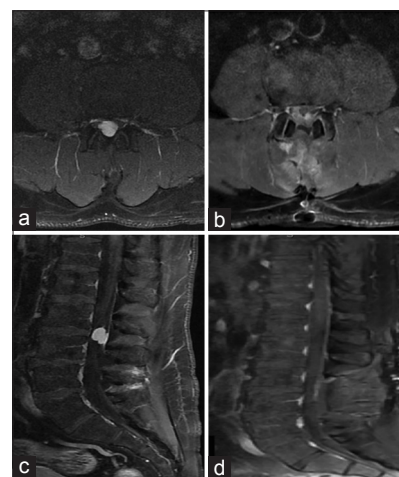


Figure 2: MRI T1+Gadolinium (a) Preoperative axial image (b) Postoperative showing gross total resection (c) Preoperative sagittal image (d) Postoperative image showing improved cauda equina mass effect

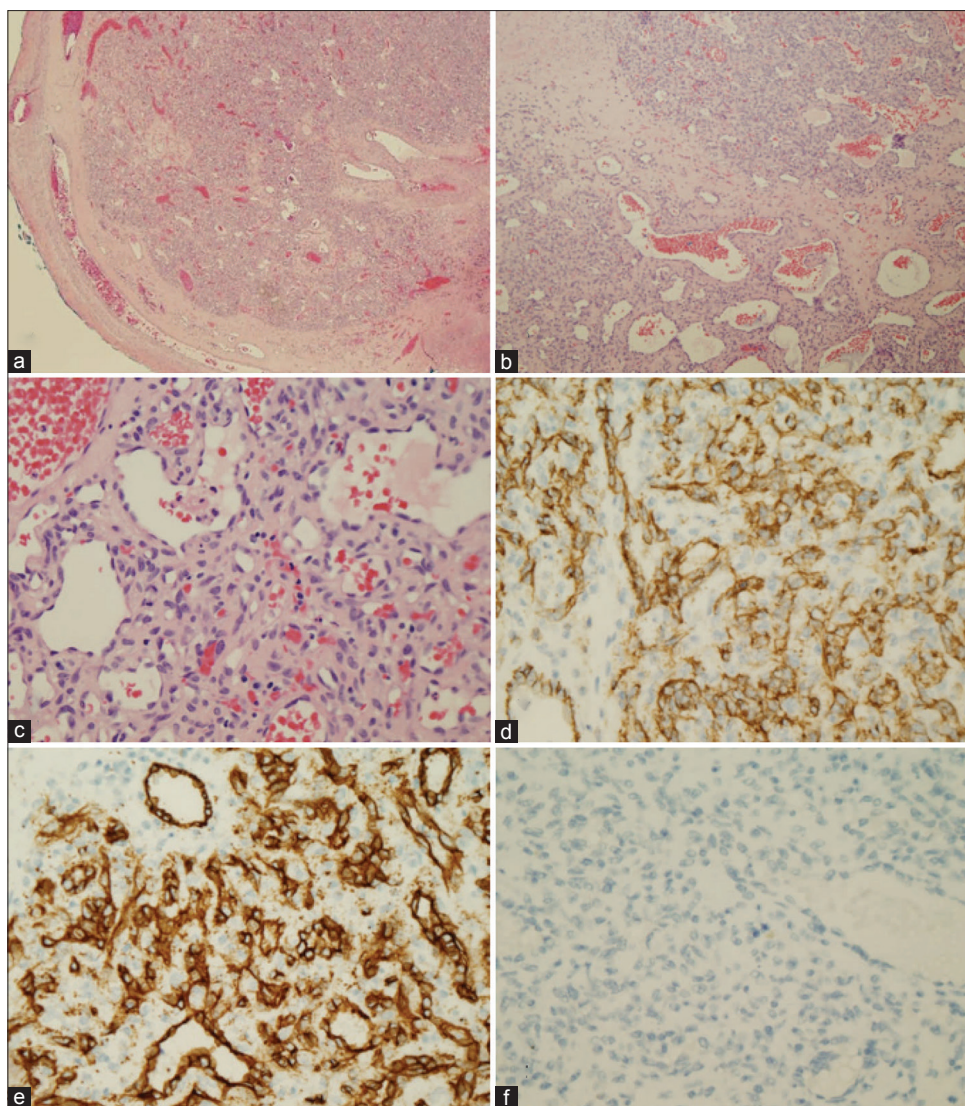


Figure 3: Histologic features of the neoplasm. (a-c) Hematoxylin and eosin stain. (d) CD31 immunostain. (e) CD34 immunostain. (f) Inhibin immunostain. Magnification: a: $\times 40$, b: $\times 100$, and c-f: $\times 400$

the spine, with the age ranging from 17 to 74. Of the 49 total cases occurring in the spine, only 16 cases were located in the cauda equina (L2-5). Diagnosis is usually made during the fifth to sixth decades of life without a reported sex predilection;^[22] our literature review, however, indicates a male predominance (3.5:1) for intradural capillary hemangiomas between the ages of 40 and 60 years. While intradural capillary hemangiomas are very rare, they are primarily distributed between the thoracic spine ($n = 23$) and cauda equina ($n = 16$), with few in the cervicothoracic ($n = 1$) or upper lumbar regions ($n = 9$; Table 1).^[1-8,10,11,13-21,23-25,27,29-32] Within the intradural space, it is postulated that capillary hemangiomas may arise from capillaries of the nerve root epineurium, the inner layer of the dura mater, or the pia mater of the spinal cord.^[7,20] Embryologically, these hemangiomas are believed to arise during angioblastic differentiation as a result of impaired mesodermal differentiation.^[22]

Radiographically, capillary hemangiomas characteristically show homogeneous enhancement after gadolinium administration on MRI.^[12,18,20-25,27] This finding on MRI is also typical of other intradural, extramedullary lesions such as schwannomas, meningiomas, or neurofibromas, making diagnosis challenging with imaging alone. The non-infiltrative encapsulated growth and microscopic appearance of lobules packed with capillary-sized vessels lined by a single layer of endothelium help to confirm the diagnosis of capillary hemangioma.^[9,12,13,18,22-25]

Given the rarity of spinal cord capillary hemangiomas, the natural history is not known. Furthermore, the recurrence or regrowth of central nervous system capillary hemangiomas is extremely rare.^[14,28] Typically, intradural tumors remain asymptomatic or cause nonspecific complaints. The most common symptoms in adults are pain and sensory loss. While capillary hemangiomas typically are associated with slowly progressive worsening

Table 1: Summary of reported intradural capillary hemangioma cases

Author and Year	Number of cases	Gender/Age	Level
Mastronardi <i>et al.</i> , 1997	1	M/41	L5
Zander <i>et al.</i> , 1998	1	F/51	L4-5
Holtzman <i>et al.</i> , 1999	1	F/56	L4
Roncaroli <i>et al.</i> , 1999	9	M (6), F (3)/40-62	T5 (1), cauda equina (8)
Nowak <i>et al.</i> , 2000	1	F/63	T12-L1
Roncaroli <i>et al.</i> , 2000	1	M/74	L2-3
Roncaroli <i>et al.</i> , 2000	4	M (3), F (1)/42-64	T10, T11 (2), conus
Shin <i>et al.</i> , 2000	1	F/66	T8-9
Choi <i>et al.</i> , 2001	3	M (3)/28-52	L1, T4-5, T5-6
Andaluz <i>et al.</i> , 2002	1	M/41	Conus medullaris
Bozkus <i>et al.</i> , 2003	2	M/55, F/37	T8, T5-6
Abe <i>et al.</i> , 2004	1	M/59	T11
Abdullah <i>et al.</i> , 2004	1	F/32	T9-10
Kelleher <i>et al.</i> , 2005	1	M/57	T9-10
Yu <i>et al.</i> , 2006	1	M/48	T6-7
Alakandy <i>et al.</i> , 2006	1	M/60	T9
Kim <i>et al.</i> , 2006	1	M/59	L1-2
Ghazi <i>et al.</i> , 2006	1	M/42	L3-4
Ganapathy <i>et al.</i> , 2008	1	M/17	L2-3
Kasukurthi <i>et al.</i> , 2009	1	M/47	T3
Miri <i>et al.</i> , 2009	1	M/20	L3
Chung <i>et al.</i> , 2010	1	M/47	T6-7
Sonawane <i>et al.</i> , 2012	1	M/35	T12
Kaneko <i>et al.</i> , 2012	1	M/48	T10-11
Melcher <i>et al.</i> , 2013	1	M/46	T6
Wu <i>et al.</i> , 2013	5	M (4), F (1)/18-63	Thoracic (4), cervicothoracic
Babu <i>et al.</i> , 2013	4	Mean age 53.5	Thoracolumbar (4)
Present case	1	M/53	L3-4

of symptoms,^[22] early treatment is important because hemorrhagic lesions may lead to sudden neurological deterioration. While they are thought to be slow-growing entities, given that there is a significant risk of hemorrhage, en bloc excision has been suggested.^[6,20,27] In fact, preoperative embolization of feeding arteries has been previously proposed.^[22] Complete surgical excision of capillary hemangiomas continues to be the mainstay of treatment, and offers patients the best possibility for neurological improvement.

REFERENCES

1. Abdullah DC, Raghuram K, Phillips CD, Jane JA Jr, Miller B. Thoracic intradural extramedullary capillary hemangioma. *AJNR Am J Neuroradiol* 2004;25:1294-6.
2. Abe M, Tabuchi K, Tanaka S, Hodozuka A, Kunishio K, Kubo N, *et al.* Capillary hemangioma of the central nervous system. *J Neurosurg* 2004;101:73-81.
3. Alakandy LM, Hercules S, Balamurali G, Reid H, Herwadkar A, Holland JP. Thoracic intradural extramedullary capillary haemangioma. *Br J Neurosurg* 2006;20:235-8.
4. Andaluz N, Balko MG, Stanek J, Morgan C, Schwetschenau PR. Lobular capillary hemangioma of the spinal cord: Case report and review of the literature. *J Neurooncol* 2002;56:261-4.
5. Babu R, Owens TR, Karikari IO, Moreno J, Cummings TJ, Gottfried ON, *et al.* Spinal cavernous and capillary hemangiomas in adults. *Spine* 2013;38:E423-30.
6. Bozkus H, Tanriverdi T, Kizilkilic O, Tureci E, Oz B, Hanci M. Capillary haemangiomas of the spinal cord: Report of two cases. *Minim Invasive Neurosurg* 2003;46:41-6.
7. Choi BY, Chang KH, Choe G, Han MH, Park SW, Yu IK, *et al.* Spinal intradural extramedullary capillary hemangioma: MR imaging findings. *AJNR Am J Neuroradiol* 2001;22:799-802.
8. Chung SK, Nam TK, Park SW, Hwang SN. Capillary hemangioma of the thoracic spinal cord. *J Korean Neurosurg Soc* 2010;48:272-5.
9. Enzinger F, Weiss S. *Benign tumors and tumor-like lesions of blood vessels.* In: Enzinger F, Weiss S, editors. *Soft tissue tumors.* St. Louis: Mosby; 1995. p. 581-6.
10. Ganapathy S, Kleiner LI, Mirkin LD, Hall L. Intradural capillary hemangioma of the cauda equina. *Pediatr Radiol* 2008;38:1235-8.
11. Ghazi NG, Jane JA, Lopes MB, Newman SA. Capillary hemangioma of the cauda equina presenting with radiculopathy and papilledema. *J Neuroophthalmol* 2006;26:98-102.
12. Hanakita J, Suwa H, Nagayasu S, Suzuki H. Capillary hemangioma in the cauda equina: Neuroradiological findings. *Neuroradiology* 1991;33:458-61.
13. Holtzman RN, Brisson PM, Pearl RE, Gruber ML. Lobular capillary hemangioma of the cauda equina. Case report. *J Neurosurg* 1999;90 (2 Suppl):S239-41.
14. Kaneko Y, Yamabe K, Abe M. Rapid regrowth of a capillary hemangioma of the thoracic spinal cord. *Neurol Med Chir* 2012;52:665-9.
15. Kasukurthi R, Ray WZ, Blackburn SL, Lusia EA, Santiago P. Intradural capillary hemangioma of the thoracic spine: Case report and review of the literature. *Rare Tumors* 2009;1:e10.
16. Kelleher T, Aquilina K, Keohane C, O'Sullivan MG. Intradural capillary haemangioma. *Br J Neurosurg* 2005;19:345-8.

17. Kim KJ, Lee JY, Lee SH. Spinal intradural capillary hemangioma. *Surg Neurol* 2006;66:212-4.
18. Mastronardi L, Guiducci A, Frondizi D, Carletti S, Spera C, Maira G. Intraneural capillary hemangioma of the cauda equina. *Eur Spine J* 1997;6:278-80.
19. Melcher C, Wegener B, Niederhagen M, Jansson V, Birkenmaier C. An intramedullary capillary hemangioma of the spine with an underlying plasmocytoma. *Spine J* 2013;13:e1-4.
20. Miri SM, Habibi Z, Hashemi M, Meybodi AT, Tabatabai SA. Capillary hemangioma of cauda equina: A case report. *Cases J* 2009;2:80.
21. Nowak DA, Gumprecht H, Stolze A, Lumenta CB. Intraneural growth of a capillary haemangioma of the cauda equina. *Acta Neurochir* 2000;142:463-7.
22. Nowak DA, Widenka DC. Spinal intradural capillary haemangioma: A review. *Eur Spine J* 2001;10:464-72.
23. Roncaroli F, Scheithauer BW, Deen HG Jr. Multiple hemangiomas (hemangiomatosis) of the cauda equina and spinal cord. Case report. *J Neurosurg* 2000;92 (2 Suppl):S229-32.
24. Roncaroli F, Scheithauer BW, Krauss WE. Capillary hemangioma of the spinal cord. Report of four cases. *J Neurosurg* 2000;93 (1 Suppl):148-51.
25. Roncaroli F, Scheithauer BW, Krauss WE. Hemangioma of spinal nerve root. *J Neurosurg* 1999;91 (2 Suppl):S175-80.
26. Russel D, Rubinstein L. Pathology of tumors of the nervous system. 5th ed. London: Edward Arnold; 1989.
27. Shin JH, Lee HK, Jeon SR, Park SH. Spinal intradural capillary hemangioma: MR findings. *AJNR Am J Neuroradiol* 2000;21:954-6.
28. Simon SL, Moonis G, Judkins AR, Scobie J, Burnett MG, Riina HA, et al. Intracranial capillary hemangioma: Case report and review of the literature. *Surg Neurol* 2005;64:154-9.
29. Sonawane DV, Jagtap SA, Mathesul AA. Intradural extramedullary capillary hemangioma of lower thoracic spinal cord. *Indian J Orthop* 2012;46:475-8.
30. Wu L, Deng X, Yang C, Xu Y. Intramedullary spinal capillary hemangiomas: Clinical features and surgical outcomes: Clinical article. *J Neurosurg Spine* 2013;19:477-84.
31. Yu Y, Fuhr J, Boye E, Gyorffy S, Soker S, Atala A, et al. Mesenchymal stem cells and adipogenesis in hemangioma involution. *Stem Cells* 2006;24:1605-12.
32. Zander DR, Lander P, Just N, Albrecht S, Mohr G. Magnetic resonance imaging features of a nerve root capillary hemangioma of the spinal cord: Case report. *Can Assoc Radiol J* 1998;49:398-400.