

RHINOLOGY

A clinical and histopathological comparison of saline, adrenaline and 2-mercaptoethanesulfonate (MESNA) in mucoperichondrial elevation: which is superior?

Studio comparativo istopatologico e clinico nello scollamento mucopericondrale mediante infiltrazione di soluzione salina, mercaptoetanesulfonato (MESNA): quale tecnica è migliore?

Zehra Çınar¹, Özgür Yiğit¹, Fulya Savran Turanoğlu¹, Sevim Baykal Koca²

¹ Department of Otorhinolaryngology-Head and Neck Surgery, Istanbul Training and Research Hospital, Istanbul, Turkey;

² Department of Pathology, Istanbul Training and Research Hospital, Istanbul, Turkey

SUMMARY

Objective. To determine whether submucosal mesna (2-mercaptoethane sodium sulfonate) infiltration is superior to normal saline or adrenaline + lidocaine in mucoperichondrial hydrodissection.

Methods. Twenty-one rabbits were administered adrenaline + lidocaine, saline or mesna. Bilateral septal mucoperichondrial flap elevations were performed following submucosal infiltration. The intraoperative bleeding amount, operation time, accessibility of the surgical plane, field quality and degree of mucoperichondrial injury were recorded. The three groups were compared histopathologically.

Results. The amount of bleeding and duration of the operation were significantly higher and the accessibility of the surgical plane score was significantly lower in the saline group vs. the other groups ($p < 0.05$). The mucosal damage rate was significantly higher in the saline group compared with adrenaline + lidocaine ($p < 0.05$). The surgical field quality was significantly lower in the saline group compared with adrenaline + lidocaine ($p < 0.05$). The accessibility of the correct surgical plane score was significantly lower in the saline group compared with the adrenaline + lidocaine and mesna groups ($p < 0.05$). The amount of bleeding, duration of operation, surgical field quality and accessibility of the surgical plane did not differ significantly between the adrenaline + lidocaine and mesna groups ($p > 0.05$). The perichondrium thickness was significantly lower in the saline group than the other groups. Cartilage thickness was significantly higher in the saline group compared with the mesna group ($p > 0.05$).

Conclusion. Use of mesna instead of normal saline or adrenaline + lidocaine in septoplasty was not more advantageous in terms of intraoperative parameters. The adrenaline + lidocaine group was superior to normal saline for all intraoperative parameters. In conclusion, the use of adrenaline may be more advantageous in facilitating septal mucoperichondrium elevation due to its widespread use, low cost and superiority to physiological saline.

KEY WORDS: adrenaline, mesna, saline, septoplasty, mucoperichondrial flap elevation

RIASSUNTO

Obiettivo. Determinare se l'infiltrazione sottomucosa di mesna (2-mercaptoetano sodico solfonato) è superiore nell'idrodissezione mucopericondrale.

Metodi. Ventuno conigli sono stati divisi in due gruppi a seconda del trattamento: adrenalina + lidocaina, soluzione salina e mesna. Sono stati eseguiti scollamenti mucopericondriali del setto per infiltrazione sottomucosa. Sono stati registrati la quantità di sanguinamento intraoperatorio, il tempo dell'intervento, l'accessibilità del piano chirurgico, la qualità del campo operatorio e il grado di lesione mucopericondrale. Questi tre gruppi sono stati confrontati istopatologicamente.

Risultati. La quantità di sanguinamento e la durata dell'operazione erano significativamente più alte, tuttavia l'accessibilità del piano chirurgico era significativamente inferiore

Received: June 13, 2020

Accepted: October 1, 2020

Correspondence

Zehra Çınar

Istanbul Training and Research Hospital, Department of Otorhinolaryngology & Head and Neck Surgery, Kasap İlyas Mah., Org. Abdurrahman Nafiz Gürman Cd., 34098 Fatih/Istanbul, Turkey
Tel. +90 212 459 60 00. Fax +90 212 459 61 45
E-mail: drzehraddonmez@hotmail.com

Funding

None.

Conflict of interest

The Authors declare no conflict of interest.

How to cite this article: Çınar Z, Yiğit O, Savran Turanoğlu F, et al. A clinical and histopathological comparison of saline, adrenaline and 2-mercaptoethanesulfonate (MESNA) in mucoperichondrial elevation: which is superior? Acta Otorhinolaryngol Ital 2021;41:51-58. <https://doi.org/10.14639/0392-100X-N0920>

© Società Italiana di Otorinolaringoiatria e Chirurgia Cervico-Facciale



OPEN ACCESS

This is an open access article distributed in accordance with the CC-BY-NC-ND (Creative Commons Attribution-NonCommercial-NoDerivatives 4.0 International) license. The article can be used by giving appropriate credit and mentioning the license, but only for non-commercial purposes and only in the original version. For further information: <https://creativecommons.org/licenses/by-nc-nd/4.0/deed.en>

nel gruppo trattato con soluzione salina rispetto agli altri gruppi ($p < 0,05$). Il tasso di lesione della mucosa era significativamente più alto nel gruppo trattato con soluzione salina rispetto al gruppo adrenalina + lidocaina ($p < 0,05$). La qualità del campo chirurgico era significativamente inferiore nel gruppo trattato con soluzione salina rispetto al gruppo adrenalina + lidocaina ($p < 0,05$). L'accessibilità del piano chirurgico era significativamente inferiore nel gruppo con soluzione salina rispetto ai gruppi adrenalina + lidocaina e mesna ($p < 0,05$). La quantità di sanguinamento, la durata dell'intervento, la qualità del campo chirurgico e l'accessibilità al piano chirurgico non differivano significativamente tra i gruppi adrenalina + lidocaina e mesna ($p < 0,05$). Lo spessore del pericondrio era significativamente inferiore nel gruppo salino rispetto agli altri gruppi. Lo spessore della cartilagine era significativamente più alto nel gruppo salino rispetto al gruppo mesna ($p < 0,05$). **Conclusione.** L'uso di mesna al posto della normale combinazione di soluzione fisiologica o lidocaina e adrenalina nella settoplastica non è risultato più vantaggioso in termini di parametri intraoperatori. Il gruppo trattato con lidocaina e adrenalina è risultato superiore rispetto al trattamento con soluzione salina normale in termini di tutti i parametri intraoperatori. In conclusione, l'uso dell'adrenalina può essere più vantaggioso nel facilitare l'elevazione del mucopericondrio settale a causa del suo uso diffuso, del basso costo e della superiorità alla soluzione salina fisiologica.

PAROLE CHIAVE: adrenalina, mesna, soluzione salina, settoplastica, elevazione del lembo mucopericondriale

Introduction

Nasal airway obstruction is a common complaint in otorhinolaryngology and has been described as a source of significant patient discomfort and financial burden¹. Diagnosis of nasal obstruction includes symptom assessment via the Nasal Obstruction Symptom Evaluation (NOSE) instrument and physical exam of the septum and the other nasal anatomical subunits². Nasal obstruction is associated with anatomical as well as mucosal conditions. The most frequent anatomical cause is a deviated nasal septum, which can be accompanied by hypertrophy of the turbinate contralateral to the deviation^{2,3}. Although the actual prevalence of nasal septal deviation is not known, one study reported a prevalence of 90%⁴. Septoplasty, i.e., surgical correction of the deviated nasal septum, is the most common ENT-operation in adults⁵. Indications for septoplasty are practice-based rather than evidence-based, and internationally accepted guidelines are lacking⁶. Septoplasty (with or without concurrent turbinate surgery) is performed to widen nasal passages and improve nasal airflow⁷.

Mucoperichondrial flap elevation is the first step of septoplasty and is used to lessen the amount of bleeding, obtain better vision of the surgical area, shorten the operation time and minimise mucosal damage^{8,9}.

Prior to mucoperichondrial flap elevation, vasoconstrictor agents combined with local anaesthetics are frequently used to reduce bleeding and increase the surgical field of view in nasal surgeries. Using increasing pressure, this hydrodissection technique aims to dissect the perichondrium from the nasal septum^{10,11}. There are also studies where only saline has been applied for hydrodissection¹². In these studies, it was concluded that vasoconstrictor agents were not superior to saline in terms of intraoperative parameters. Mesna, which is the sulphur salt of 2-mercaptoethanolsulphamic acid, received a patent for 'chemical assisted dissection' and enables de-adhesion between pathological and healthy tissues, thus facilitating healthy tissues in dissociating

from the surrounding tissues. Therefore, numerous surgical branches, from otolaryngology to gynaecology and orthopaedics, use mesna for intraoperative chemical dissection^{13,14}.

The effectiveness of mesna in facilitating dissection of the cholesteatoma matrix from surrounding tissues has been demonstrated¹⁵. It has been reported that mesna facilitates elevation of the tympanic membrane in atelectatic ears and adhesive otitis media¹⁶. It is also known to be used in acoustic neuroma, glomus tumour, meningioma and all other skull base tumours because it facilitates finding the right surgical plan between solid tissue and tumour tissue¹⁴. In severe septum deviations, mucoperichondrium elevation cannot always be as successful as expected. This situation increases the possibility of complications, such as septal mucoperichondrial perforation and need for revision surgery. The earlier we perform the elevation of the mucoperichondrium, which is the first stage of septoplasty, the easier we can perform surgery in conditions where bleeding and mucoperichondrial perforation are minimal: the rate of complications decreases and surgical success increases. In patients with traumatic septal deviation in whom mucoperichondrium elevation is expected to be difficult, we theorised that mesna could facilitate mucoperichondrium elevation, which is the first step of septoplasty.

Because vasoconstrictor agents and saline do not provide satisfactory outcomes regarding intraoperative parameters, we hypothesised that mesna would be superior to adrenaline and saline regarding the facilitation of the septal mucoperichondrial flap elevation. For this purpose, submucosal mesna infiltration was compared with submucosal saline and adrenaline in terms of intraoperative parameters and histopathological findings.

Materials and methods

Study design

Twenty-one adult female albino New Zealand rabbits (3000-4500 g, mean 3500 g) were equally divided into

three groups as follows: adrenaline + lidocaine (Jetokain 2 ml, Adeka İlaç, Istanbul, Turkey), physiological saline and mesna (Uromitexan 400 mg, Eczacıbaşı, Baxter İlaç, Istanbul, Turkey).

The study was approved by the Local Animal Ethics Committee of the Bezmi Alem Foundation University (Animal Care and Use) (2016/291). All applicable international, national and/or institutional guidelines for the care and use of animals were followed. All procedures performed in studies involving animals were in accordance with the ethical standards of the institution at which the studies were conducted. The protocol was blinded to the investigators performing the procedure. The same surgeon performed the operations, and each group underwent surgery on different days. For general anaesthesia, 40 mg/kg phenobarbital and 5 mg/kg xylazine were used. Afterwards, by using dental injectors and being assisted by the original 10th magnification of the dissection microscope (Imaging source, DFK 31AU03, Germany), adrenaline + lidocaine (total amount 0.5 ml; the dose of lidocaine and adrenaline that 20 mg/ml and 0.0125 mg/ml respectively), saline (total amount 0.5 ml) and mesna (total amount 0.5 ml), for the first, second and third group, respectively, were injected at multiple sides bilaterally through the anterior and posterior septal submucosal regions.

The open rhinoplasty technique was used to access the septum of rabbits (Fig. 1a). Microsurgical scissors were used to determine the caudal end of the nasal septum, which was accessed with a sharp dissection starting from the columellar region. Mucoperichondrial flap elevation was performed on both sides of the nasal septum using a blunt-tipped elevator. The surgical plane was advanced up to the nasal septal bone in the posterior region.

Maximum precautions were applied to prevent any possi-

ble trauma from affecting the septal cartilage. Following flap elevation, the flap was laid on the septal cartilage using the miniature Doyle splint (Fig. 1b). Doyle splints were placed bilaterally to reattach the mucoperichondrium onto the septal cartilage and were removed 48 hours later. The learning curve needed to be overcome. In each group, the operation duration was shortened after the first case.

The intraoperative evaluation criteria of this study were determined by referring to the study of Gungor V. et al.¹¹. During the operation, five parameters were recorded in all three groups: intraoperative septal mucoperichondrial injury, amount of bleeding, operation duration, surgical site quality and accessibility to the correct surgical plane. Septal mucoperichondrial injuries were defined as simple or severe. Unilateral septal mucoperichondrial tear without any mucosal loss was accepted as simple damage. Unilateral damage revealing the cartilage because of loss of mucoperichondrium and bilateral mucoperichondrial damage were considered serious injuries. The same surgeon rated the surgical site quality and accessibility of the correct surgical plane from 1 to 5. Regarding the surgical site quality, 1 was considered very poor (not suitable for a comfortable operation) and 5 was considered excellent (suitable for a comfortable operation). A surgical site quality of 5 means that there is no mucoperichondrial damage and bilateral septal mucoperichondrial tunnels are opened without any difficulty. Technically, a much more comfortable surgery is performed. A surgical site quality of 1 means that there is difficulty in opening bilateral submucoperichondrial tunnels due to multiple or severe mucoperichondrial damage and perforation, and therefore may cause interruption of intervention to the septal cartilage safely. Regarding the accessibility of the correct surgical plane, 1 was considered to be very poor (very difficult to find a convenient surgical

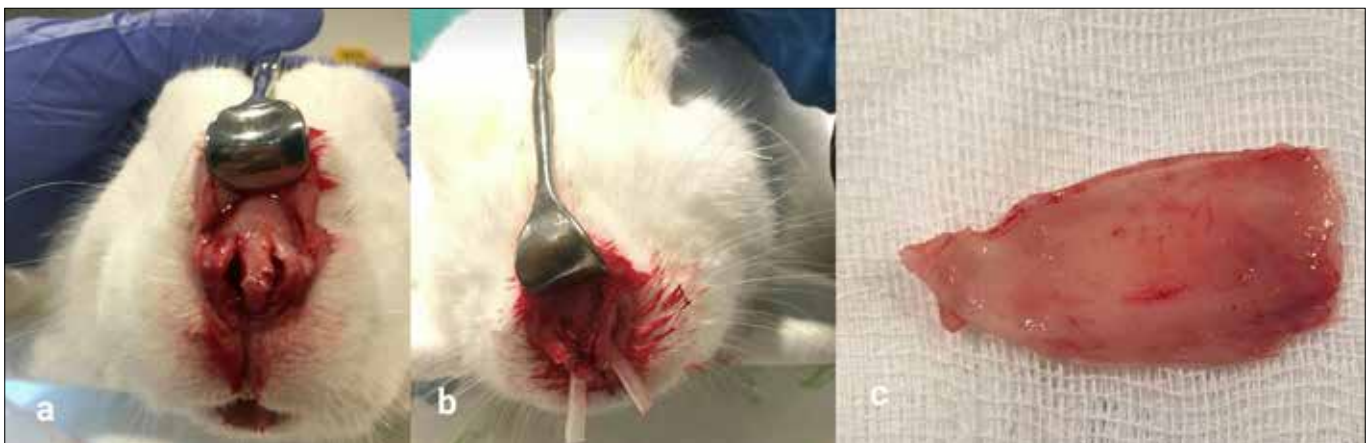

Figure 1. (A, B) An open septoplasty technique was used to reach the nasal septum in the rabbits. (C) Totally removed septal cartilage.

plane), and 5 was considered excellent (not hard to find a convenient surgical plane).

4.0 vicryl (Ethicon Inc., Somerville, NJ) was used to close the initial skin incision. Procaine penicillin (40,000 IU) was administered intramuscularly (IM) for 3 days for infection prophylaxis. Six weeks after the operation, the animals were sacrificed using 500 mg/g intracardiac phenobarbital following sedation with 40 mg/kg IM phenobarbital. The nasal tip was incised through the frontonasal suture line through the midline of the nasal dorsum. The nasal bone was cut using bone scissors, the septal cartilage was incised along the nasal base, the septum was separated from all the insertion points, and the bloc was removed (Fig. 1c). Specimens were fixed in 10% neutral buffered formol solution and sent for histopathological examination.

Histopathologic study

Specimens were fixed in 10% buffered neutral formaldehyde solution for 24 hours. Following fixation, nasal septums were sliced in parallel fashion along the long axis. Sliced tissues were placed in follow-up cassettes and embedded in paraffin blocks following a routine 16-hour tissue follow-up process. After follow-up, tissues were sectioned with a microtome into 3 mm sections, which were then stained with haematoxylin-eosin (H&E) for microscopic examination. Microscopic evaluations were performed using a binocular microscope (Olympus, BX53, Olympus Corp., Tokyo, Japan). All specimens were evaluated by the same pathologist (SBK).

The severity of inflammation in septum samples (0 = no change, 1 = mild, 2 = moderate, 3 = severe), localisation of the inflammation (E = epithelium, ES = epithelium and submucosa, ESC = epithelium, submucosa and cartilage), presence of mucosal erosion and ulceration (0 = none, 1 = visible), presence of foreign body reaction (0 = none, 1 = visible), chondrocyte necrosis and density (1-5% = 1, 6-25% = 2, 26-50% = 3, 51-100% = 4), mucosal, perichondrium and cartilage thicknesses were evaluated.

The severity of inflammation was scored as mild when a small number of inflammatory cells infiltrated the nasal septum epithelium only (Fig. 2), as moderate when more severe inflammatory cells infiltrated the epithelium and submucosa (Fig. 3) and severe when abundant inflammatory cells infiltrated septal cartilage and mucosa in full thickness (Fig. 4).

Mucosal, perichondrial and cartilage thicknesses were measured at 400x magnification using a linear micrometer (Eyepiece Graticule, Olympus Corp.). The other parameters as severity of inflammation, mucosal erosion and ulceration, chondrocyte necrosis (Fig. 5) and foreign body reaction were evaluated semi-quantitatively.

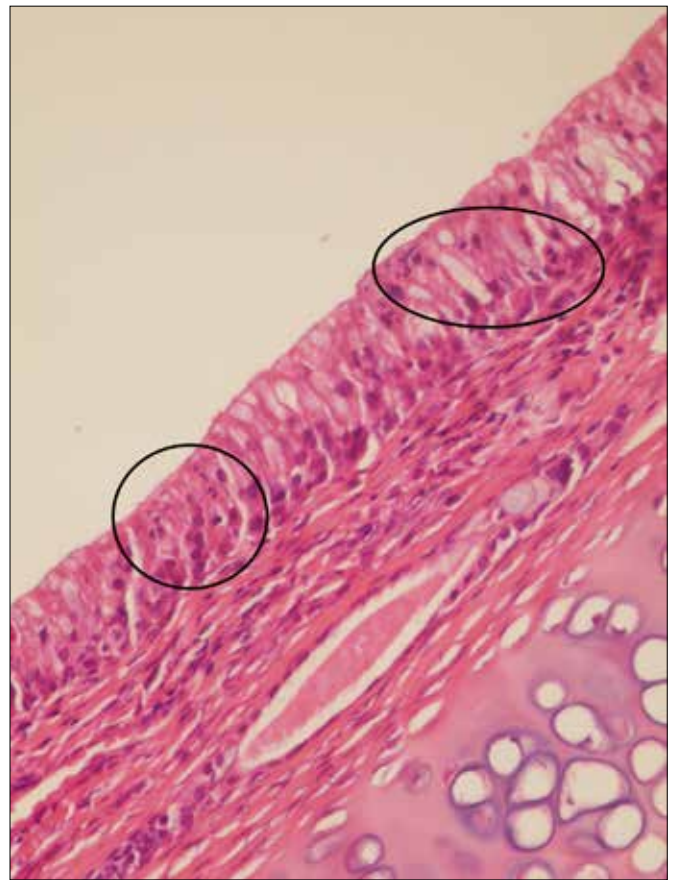


Figure 2. Inflammation limited to the mucosae (circle), Light microscopy, H-E X400. (H-E: Haematoxylin-Eosin).

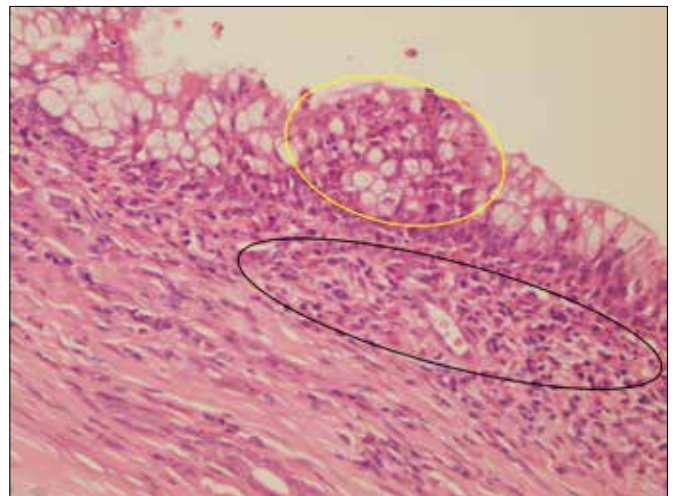


Figure 3. Severe inflammation in the mucosae (yellow circle) reached the submucosae (black circle), Light microscopy, H-E X400. (H-E: Haematoxylin-Eosin).

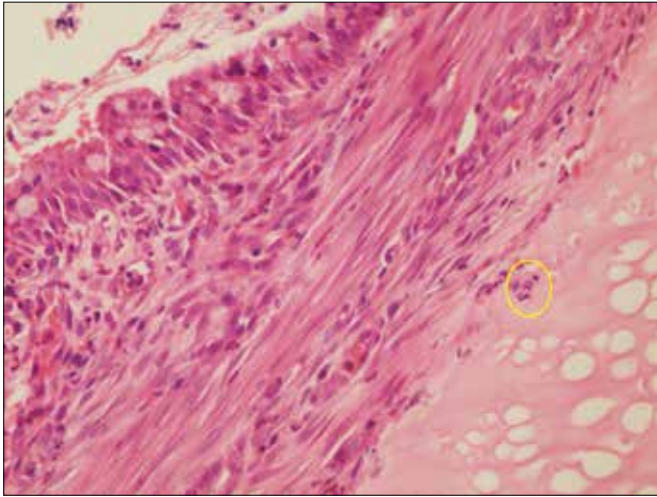


Figure 4. Cartilage affected by inflammation (circle) and chondrocyte necrosis, light microscopy, H-E X400. (H-E: Haematoxylin-Eosin).

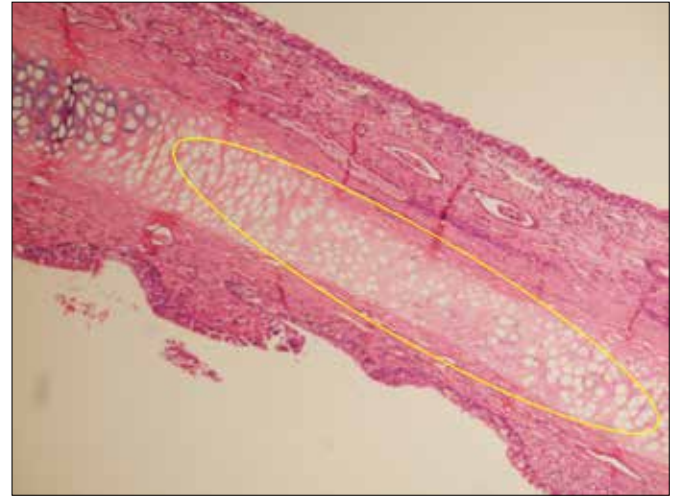


Figure 5. Chondrocyte necrosis area (yellow circle), light microscopy, H-E X400. (H-E:Haematoxylin-Eosin).

Statistical analysis

Regarding the descriptive statistics of the data, mean, standard deviation, median lowest, highest, frequency and ratio values were used. The distribution of the variables was measured with the Kolmogorov-Simonov test. In the analysis of quantitative independent data, Kruskal-Wallis and Mann-Whitney U tests were used. The chi-square test was used for analysis of qualitative independent data, and Fisher's test was used when the chi-square test conditions were not met. SPSS 22.0 was used for statistical analyses.

Results

Intraoperative findings

No deaths or side effects were observed during the study. The amount of bleeding and the duration of operation were

significantly higher in the saline group compared with the adrenaline + lidocaine and mesna groups ($p < 0.05$). The amount of bleeding and the duration of operation did not differ significantly between the adrenaline + lidocaine and mesna groups ($p > 0.05$) (Tab. I).

Mucosal damage was significantly greater in the saline group compared with the adrenaline + lidocaine group ($p < 0.05$). The mucosal damage in the mesna group did not differ significantly from the adrenaline + lidocaine and saline groups ($p > 0.05$) (Tab. I).

Surgical field quality was significantly poorer in the saline group compared with the adrenaline + lidocaine group ($p < 0.05$). In the mesna group, surgical site quality did not differ significantly from the adrenaline + lidocaine and saline groups ($p > 0.05$) (Tab. I).

The accessibility of the correct surgical plane score was

Table I. Amount of bleeding, operation time, surgical site quality, mucosal injury, finding the correct surgical plane for the study groups

			Adrenaline + Lidocaine		Mesna		Saline		p
Amount of bleeding (number of pads)	Med (I.Q-3.Q)/ Min-Max		1.0 (0.50-1.0)/ 0.50-1.50*		1.0 (1.0-1.0)/ 0.50-1.00*		1.5 (1.0-2.0)/ 1.00-3.50		0.010 ^k
Operation Time (Minutes)	Med (I.Q-3.Q)/ Min-Max		4.5 (3.5-7.0)/ 3.50-8.00*		7.0 (5.0-8.0)/ 3.50-9.00*		10.5 (6.0-16.5)/ 6.00-18.50		0.012 ^k
Surgical site quality (1-5)	Med (I.Q-3.Q)/ Min-Max		5.0 (5.0-5.0)/ 2.00-5.00		4.0 (3.0-5.0)/ 2.00-5.00		3.0 (2.0-4.0)/ 1.00-4.00		0.027 ^k
Finding the correct surgical plane (1-5)	Med (I.Q-3.Q)/ Min-Max		5.0 (3.0-5.0)/ 2.00-5.00*		4.0 (3.0-5.0)/ 3.00-5.00*		3.0 (2.0-3.0)/ 2.00-3.00		0.021 ^k
Mucosal Injury	None	n-%	6	85.7%*	2	28.6%	0	0.0%	$p < 0.05$ ^x
	Simple	n-%	0	0.0%	3	42.9%	5	71.4%	
	Serious	n-%	1	14.3%	2	28.6%	2	28.6%	

^k Kruskal-wallis (Mann-Whitney U test); ^x Chi-square test (Fisher's exact test); * Difference with saline group $p < 0.05$

significantly lower in the saline group compared with the adrenaline + lidocaine and mesna groups ($p < 0.05$). The accessibility of the correct surgical plane score did not differ significantly between the adrenaline + lidocaine and mesna groups ($p > 0.05$) (Tab. I).

Histopathological findings

The severity of inflammation, mucosal erosion and ulceration, mucosal thickness, chondrocyte necrosis and foreign body reactions did not differ significantly between the adrenaline + lidocaine, mesna and saline groups ($p > 0.05$) (Tabs. II, III).

The thickness of the perichondrium was significantly lower in the saline group compared with the adrenaline + lidocaine and mesna groups ($p < 0.05$). The thickness of the perichondrium did not differ significantly between the adrenaline + lidocaine and mesna groups ($p > 0.05$) (Tab. III).

Cartilage thickness was significantly higher in the saline group compared with the mesna group ($p < 0.05$). There was no significant difference regarding cartilage thickness in the adrenaline + lidocaine group compared with the mesna and saline groups ($p > 0.05$) (Tab. III).

Discussion

In the current study, only the amount of bleeding, operation duration and cartilage thickness were significantly higher in the saline group compared with the mesna and lidocaine+adrenaline groups, but the accessibility of the correct surgical plane score and the thickness of the perichondrium were found to be significantly lower. In terms of mucosal damage and surgical field quality, the saline group had significantly worse results compared with the adrenaline+lidocaine group. No significant difference was found between the mesna and adrenaline + lidocaine

groups regarding these two parameters. Based on these findings, mesna does not appear to be superior to adrenaline. However, saline should not be the first choice in the surgical field.

There are few studies evaluating the efficacy of adrenaline in septum surgery^{12,17,18}. In a clinical study, submucoperichondrial vasoconstrictor injection was compared with saline injection and was not superior to saline for intraoperative findings¹¹. In another study, adrenaline and saline infiltrations were compared, and no significant difference was detected at the surgical site¹². In contrast, adrenaline was shown to be superior to saline intraoperative findings, such as the amount of bleeding, operation duration, surgical site quality, mucosal damage and accessibility of the correct surgical plane in the current study.

Eren et al.¹⁹ demonstrated the superiority of mesna compared with saline in terms of intraoperative findings in septal surgery. In our study, operation time and amount of bleeding were significantly higher in the saline group compared with the other groups, and these findings were similar to the study by Eren et al. However, in their study mesna was compared with saline, although a comparison with other vasoconstrictor agents was not included. In our study, saline, vasoconstrictor agents (adrenaline and lidocaine) and mesna were compared histopathologically. In this respect, the current study is different from that by Eren et al.¹⁹.

The preservation of perichondrium integrity during septal surgery is important for prevention of scar tissue formation and cartilage viability²⁰⁻²². The thickness of the perichondrium increases as a result of the trauma, which is caused by the elevation of the nasal mucosal flap. This increase is due to scar tissue formation because of increased fibroelastic activity and trauma-induced oedema²⁰. Genç et al.²⁰ found an increase in perichondrium thickness in both the suture and nasal tamponade groups. In the current study, a min-

Table II. Inflammation and inflammation severity, localisation of inflammation for the study groups.

			Adrenaline + Lidocaine		Mesna		Saline		p
Inflammation	(-)	n-%	1	14.3%	1	14.3%	0	0.0%	$p > 0.05$ ^x
	(+)	n-%	6	85.7%	6	85.7%	7	100.0%	
Inflammation severity	I	n-%	3	42.9%	2	28.6%	4	57.1%	
	II	n-%	3	42.9%	4	57.1%	2	28.6%	
	III	n-%	0	0.0%	0	0.0%	1	14.3%	
Localization of inflammation	M	n-%	1	14.3%	1	14.3%	1	14.3%	
	MS	n-%	5	71.4%	5	71.4%	5	71.4%	
	MSC	n-%	0	0.0%	0	0.0%	1	14.3%	
Inflammation severity		Med (I.Q-3.Q)/ Min-Max	1.0 (1.0-2.0)/ 1.00-2.00		2.0 (1.0-2.0)/ 1.00-2.00		1.0 (1.0-2.0)/ 1.00-3.00		0.868 ^k

^x Chi-square test (Fisher's exact test). M: Mucosa; MS: Mucosa +Submucosa; MSC: Mucosa + Submucosa + Cartilage.

Table III. Mucosal erosion and ulceration, mucosal thickness, perichondrium thickness, cartilage thickness, chondrocyte necrosis, foreign body reaction for the study groups.

		Adrenaline + Lidocaine		Mesna		Saline		p	
Mucosal erosion and ulceration	(-)	n-%	6	85.7%	4	57.1%	6	85.7%	$p > 0.5^x$
	(+)	n-%	1	14.3%	3	42.9%	1	14.3%	
Mucosal thickness (mm)		Med (I.Q-3.Q)/ Min-Max	0.32 (0.25-0.40)/ 0.23-0.48		0.28 (0.23- 0.38)/ 0.18-0.43		0.31 (0.21- 0.43)/ 0.20-0.50		0.646 ^k
Perichondrium thickness (mm)		Med (I.Q-3.Q)/ Min-Max	0.04 (0.035-0.05)/ 0.03-0.08*		0.04 (0.03- 0.045)/ 0.03-0.06*		0.03 (0.025- 0.03)/ 0.02-0.03		0.025 ^k
Cartilage thickness (mm)		Med (I.Q-3.Q)/ Min-Max	0.98 (0.88-1.48)/ 0.86-1.48		1.30 (1.20- 1.70)/ 1.10-1.90*		0.98 (0.75- 1.15)/ 0.68-1.30		0.038 ^k
Chondrocyte necrosis	(-)	n-%	1	14.3%	4	57.1%	3	42.9%	$p > 0.5^x$
	I	n-%	4	57.1%	2	28.6%	3	42.9%	
	II	n-%	2	28.6%	1	14.3%	1	14.3%	
Foreign body reaction	(-)	n-%	6	85.7%	7	100.0%	7	100.0%	$p > 0.5^x$
	(+)	n-%	1	14.3%	0	0.0%	0	0.0%	

^k Kruskal-wallis (Mann-Whitney U test); ^x Chi-square test (Fisher's exact test); * Difference with saline group $p < 0.05$; Min: Minimum/Max: Maximum

ature Doyle nasal splint was placed in both nasal cavities. The perichondrium thickness was significantly lower in the saline group compared with the other groups. This leads to the question of whether the substances that are injected into the submucoperichondrial region cause chemical irritation in addition to the trauma caused by the mucoperichondrial flap elevation. Saline, which is very similar to human and animal plasma, has no irritant properties.

In the literature, numerous studies have been conducted to emphasise the need to preserve perichondrium integrity for cartilage viability^{21,22}. Verwoerd et al.²¹ showed that new cartilage formation started within 2 weeks after submucosal cartilage resection in young rabbits; they attributed this to the high reactivity of the perichondrium. Lee et al.²³ revealed that bilateral elevation of septal mucoperichondrium had no visible effect on chondrocyte viability, and also concluded that bilateral flap elevation caused a marked weakness in cartilage when performed with interventions to the septal cartilage.

In the current study, cartilage thickness was significantly higher and perichondrial thickness was significantly lower in the saline group compared with the mesna group, which was attributed to chemical irritation by mesna.

When comparing intraoperative parameters, we found that mesna had no significant differences compared to adrena-

line + lidocaine, which is much more widely used in septum surgery than mesna. We demonstrated that mesna, which is more commonly used in otologic surgery, especially for chemically assisted dissection in ENT practice, does not create enough hydrodissection to make itself preferable in septum surgery. The perichondrium was significantly thicker and the cartilage was significantly thinner in adrenaline + lidocaine and mesna groups. However, we think that this disadvantage will not cause problems in the stability and durability of septum in the long term. In the light of all these findings, we think that adrenaline, which is widely used for submucoperichondrial hydrodissection in septum surgery for many years, is preferable over mesna or saline. Because the study was performed using a small number of rabbits and because it is unethical to harvest a full-thickness septum in human studies to compare histopathological parameters with that of rabbits, these are limitations of our study. This is the first study to compare saline, adrenaline and mesna at the same time in septal mucoperichondrial flap elevation in terms of intraoperative parameters and histopathological effects of these agents on the septum.

Conclusions

The results of this experimental study showed that using mesna instead of normal saline or lidocaine + adrenaline

in septoplasty was not more advantageous in terms of objective parameters tested, amount of bleeding, duration of operation, mucosal injuries as well as surgical field quality and accessibility of the correct surgical plane during surgery. The combination of adrenaline and lidocaine was superior to normal saline for intraoperative parameters. Mesna was not superior to normal saline in terms of mucosal damage and surgical site quality. With all these findings, we conclude that the combination of lidocaine and adrenaline might be more advantageous in septoplasty since it is inexpensive, almost always available in every operating room, much easier access worldwide and reduces bleeding due to the vasoconstriction effect of adrenaline. Further studies on a larger sample size may be beneficial to provide additional information.

Acknowledgements

Presented at the 40th Turkish National Otorhinolaryngology and Head and Neck Surgery Congress, Antalya, Turkey, 07-11 November 2018.

References

- Spiekermann C, Savvas E, Rudack C, et al. Adaption and validation of the nasal obstruction symptom evaluation scale in German language (D-NOSE). *Health Qual Life Outcomes* 2018;16:172. <https://doi.org/10.1186/s12955-018-1004-x>
- Clark DW, Del Signore AG, Raithatha R, et al. Nasal airway obstruction: prevalence and anatomic contributors. *Ear Nose Throat J* 2018;97:173-6. <https://doi.org/10.1177/014556131809700615>
- Cantone E, Ricciardiello F, Oliva F, et al. Septoplasty: is it possible to identify potential “predictors” of surgical success? *Acta Otorhinolaryngol Ital* 2018;38:528-35. <https://doi.org/10.14639/0392-100X-2072>
- Mladina R, Cuić E, Subarić M, et al. Nasal septal deformities in ear, nose, and throat patients: An international study. *Am J Otolaryngol* 2008;29:75-82. <https://doi.org/10.1016/j.amjoto.2007.02.002>
- van Egmond MMHT, Rovers MM, Tillema AHJ, et al. Septoplasty for nasal obstruction due to a deviated nasal septum in adults: a systematic review. *Rhinology* 2018;56:195-208. <https://doi.org/10.4193/Rhin18.016>
- van Egmond MM, Rovers MM, Hendriks CT, et al. Effectiveness of septoplasty versus non-surgical management for nasal obstruction due to a deviated nasal septum in adults: study protocol for a randomized controlled trial. *Trials* 2015;16:500. <https://doi.org/10.1186/s13063-015-1031-4>
- Aaronson NL, Vining EM. Correction of the deviated septum: from ancient Egypt to the endoscopic era. *Int Forum Allergy Rhinol* 2014;4:931-6. <https://doi.org/10.1002/alf.21371>
- Aksoy F, Yıldırım YS, Demirhan H, et al. Structural characteristics of septal cartilage and mucoperichondrium. *J Laryngol Otol* 2012;126:38-42. <https://doi.org/10.1017/S0022215111002404>
- Vuyk HD, Olde Kalter P. Open septorhinoplasty. Experiences in 200 patients. *Rhinology* 1993;31:175-82.
- Tahery J, Belloso A, Zarod AP. New method for raising the mucoperichondrial flap in septal surgery: microscope assisted hydrodissection technique. *J Laryngol Otol* 2004;118:715-6. <https://doi.org/10.1258/0022215042244723>
- Gungor V, Baklaci D, Kum RO, et al. Infiltration with lidocaine and adrenaline instead of normal saline does not improve the septoplasty procedure. *Eur Arch Otorhinolaryngol* 2016;273:2073-7. <https://doi.org/10.1007/s00405-015-3870-8>
- Vanniasegaram I. Prospective study of the use of vasoconstrictor and saline in septal surgery for infiltration. *J Laryngol Otol* 1991;105:638-9. <https://doi.org/10.1017/s0022215100116895>
- Bogiati S, Pagonopoulou O, Simopoulou M, et al. The cytogenetic action of ifosfamide, mesna, and their combination on peripheral rabbit lymphocytes: an in vivo/in vitro cytogenetic study. *Cytotechnology* 2014;66:753-60. <https://doi.org/10.1007/s10616-013-9624-9>
- Casale M, Di Martino A, Salvinelli F, et al. MESNA for chemically assisted tissue dissection. *Expert Opin Investig Drugs* 2010;19:699-707. <https://doi.org/10.1517/13543784.2010.485192>
- Vincenti V, Magnan J, Saccardi MS, et al. Chemically assisted dissection by means of mesna in cholesteatoma surgery. *Otol Neurotol* 2014;35:1819-24. <https://doi.org/10.1097/MAO.0000000000000514>
- Yilmaz M, Goksu N, Bayramoglu I, et al. Practical use of MESNA in atelectatic ears and adhesive otitis media. *ORL J Otorhinolaryngol Relat Spec* 2006;68:195-8. <https://doi.org/10.1159/000091472>
- Thevasagayam M, Jindal M, Allsop P, et al. Does epinephrine infiltration in septoplasty make any difference? A double blind randomised controlled trial. *Eur Arch Otorhinolaryngol* 2007;264:1175-8. <https://doi.org/10.1007/s00405-007-0339-4>
- McClymont LG, Crowther JA. Local anaesthetic with vasoconstrictor combinations in septal surgery. *J Laryngol Otol* 1988;102:793-5. <https://doi.org/10.1017/s0022215100106474>
- Eren SB, Yenigun A, Tugrul S, et al. Effect of submucosal mesna application on mucoperichondrial elevation in septoplasty. *J Craniofac Surg* 2017;28:e94-6. <https://doi.org/10.1097/SCS.00000000000003307>
- Genç E, Ergin NT, Bilezikçi B. Comparison of suture and nasal packing in rabbit noses. *Laryngoscope* 2004;114:639-45. <https://doi.org/10.1097/00005537-200404000-00008>
- Verwoerd CDA, Verwoerd-Verhoef HL, Meeuwis CA, et al. Wound healing of the nasal septal perichondrium in young rabbits. *ORL J Otorhinolaryngol Relat Spec* 1990;52:180-6. <https://doi.org/10.1159/000276131>
- Verwoerd-Verhoef HL, ten Koppel PG, van Osch GJV, et al. Wound healing of cartilage structures in the head and neck region. *Int J Pediatr Otorhinolaryngol* 1998;43:241-51. [https://doi.org/10.1016/s0165-5876\(98\)00003-2](https://doi.org/10.1016/s0165-5876(98)00003-2)
- Lee DY, Kim DW, Mangoba DCS, et al. Morphological and histological changes of the septal cartilage after unilateral versus bilateral mucoperichondrial flap elevation. *Am J Rhinol Allergy* 2013;27:62-6. <https://doi.org/10.2500/ajra.2013.27.3843>