

Endoscopic Synovectomy of the Ulnar Bursa of the Palm of the Hand



Tun Hing Lui, M.B.B.S.(HK), F.R.C.S.(Edin), F.H.K.A.M., F.H.K.C.O.S., and Jeffrey Chun Yin Lee, M.B.B.S.(HK)

Abstract: Synovitis of the ulnar bursa is associated with tenosynovitis of the flexor tendons. Reported causes include suppurative or tuberculous infection, rheumatoid arthritis, and pigmented villonodular synovitis. Open synovectomy requires extensive soft-tissue dissection and may result in extensive scarring. The purpose of this Technical Note is to describe the technical details of endoscopic synovectomy of the ulnar bursa of the palm of the hand. This minimally invasive approach with small incisions allows aggressive postoperative hand therapy and avoids the complications of tendon adhesions, joint contractures, and hand stiffness.

The ulnar bursa of the palm envelops the superficial and deep tendons of the little, ring, long, and index fingers. The ulnar bursa communicates with the fifth flexor digitorum tendon sheath in 50% to 80% of cases but usually does not communicate with the other flexor tendon sheaths.¹ Synovitis of the bursa is associated with tenosynovitis of the flexor tendons. Reported causes include suppurative²⁻⁴ or tuberculous⁵ infection, rheumatoid arthritis,^{6,7} and pigmented villonodular synovitis.⁸ In the case of the suppurative condition, pus collection results in a vicious circle of infection and an increase in compartmental pressure that reduces perfusion of soft tissues and facilitates spreading of the infection.⁹

Suppurative infection of this deep-seated compartment is treated primarily with surgical drainage in association with rest, elevation, and appropriate systemic antibiotic therapy.¹⁰ Biopsy and synovectomy

are also indicated for tuberculous infection for planning of chemotherapy. Complete synovectomy is the treatment of choice for pigmented villonodular synovitis. Synovectomy is also indicated for a rheumatologic condition that is resistant to drug treatment. Classically, an operation on the ulnar bursa requires an open approach.⁹ This may result in extensive soft-tissue dissection and scarring. Recently, an endoscopic approach to the ulnar bursa has been reported.¹¹ This minimally invasive approach with small incisions allows aggressive postoperative hand therapy and avoids the complications of tendon adhesions, joint contractures, and hand stiffness.^{9,10}

The purpose of this Technical Note is to describe the technical details of endoscopic synovectomy of the ulnar bursa. It is indicated for suppurative or tuberculous infections of the ulnar bursa. It is also indicated for synovitis of the bursa associated with rheumatoid arthritis resistant to drug treatment. It is contraindicated in the case of pigmented villonodular synovitis that extends into the carpal tunnel. An open approach is needed to ensure complete synovectomy. The technique is also contraindicated if there is evidence of

From the Department of Orthopaedics and Traumatology, North District Hospital (T.H.L.), Sheung Shui; and Department of Orthopaedics and Traumatology, Tuen Mun Hospital (J.C.Y.L.), Tuen Mun, China.

The authors report that they have no conflicts of interest in the authorship and publication of this article. Full ICMJE author disclosure forms are available for this article online, as [supplementary material](#).

Received July 16, 2018; accepted August 3, 2018.

Address correspondence to Tun Hing Lui, M.B.B.S.(HK), F.R.C.S.(Edin), F.H.K.A.M., F.H.K.C.O.S., Department of Orthopaedics and Traumatology, North District Hospital, 9 Po Kin Road, Sheung Shui, NT, Hong Kong SAR, China E-mail: luithderek@yahoo.co.uk

© 2018 by the Arthroscopy Association of North America. Published by Elsevier. This is an open access article under the CC BY-NC-ND license (<http://creativecommons.org/licenses/by-nc-nd/4.0/>).

2212-6287/18883

<https://doi.org/10.1016/j.eats.2018.08.012>

Table 1. Indications and Contraindications of Endoscopic Synovectomy of Ulnar Bursa

Indications	Contraindications
Suppurative or tuberculous infections of ulnar bursa	Pigmented villonodular synovitis that extends into carpal tunnel
Synovitis of bursa associated with rheumatoid arthritis resistant to drug treatment	Compartment syndrome of hand

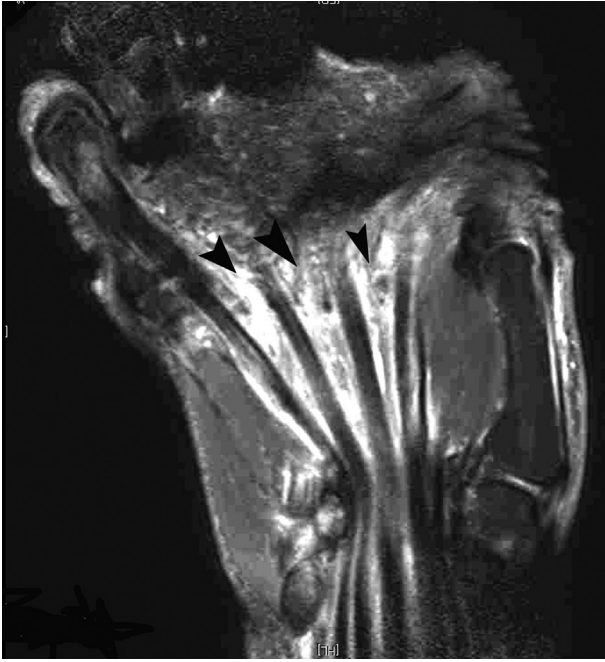

Fig 1. Endoscopic synovectomy of ulnar bursa in right hand. The patient is in the supine position with the hand on the side table. A coronal T2 magnetic resonance image of the palm of the illustrated case shows synovitis of the ulnar bursa (arrowheads).

compartment syndrome of the hand. Open release is a more appropriate treatment option (Table 1).

Technique

Preoperative Planning and Patient Positioning

Suppurative infection of the ulnar bursa is a surgical emergency, and treatment should not wait for imaging investigations.² In a subacute or chronic condition,

the pathology can be located with magnetic resonance imaging (Fig 1).

The patient is placed in the supine position with the hand on the side table. An arm tourniquet is applied to provide a bloodless surgical field. Fluid inflow is by gravity, and no arthropump is used. A 2.7-mm 30° arthroscope (Henke Sass Wolf, Tuttlingen, Germany) is used for this procedure.

Portal Placement

Two portals are used for this procedure. The ulnar palmar portal is on the volar side of the fifth metacarpal neck. The first web portal is at the dorsum of the first hand web just lateral to the second metacarpal neck (Fig 2). This is created with an inside-out technique.

Endoscopic Synovectomy of Ulnar Bursa

A 3- to 4-mm skin incision is made at the ulnar palmar portal. The palmar aponeurosis is also incised in an open manner. The trocar cannula is introduced through the ulnar palmar portal along the palmar surface of the flexor tendons at the level of the metacarpal necks to the first hand web with the thumb abducted. The first web portal is created over the trocar tip. Excessive force should be avoided in advancement of the trocar cannula. This can reduce the risk of injury to the superficial palmar arch. The distally placed portals allow access to the more proximal part of the ulnar bursa, which is funnel shaped.¹² The ulnar palmar portal and the first web portal can be used interchangeably as the viewing and working portals.

The ulnar palmar portal is the viewing portal, and the first web portal is the working portal. The ulnar bursa is identified, and gliding of the flexor tendons inside the bursa can be observed by passive motion of the fingers. The flexor tendon to the index finger can be easily dissected from the bursa because the bursa invaginates

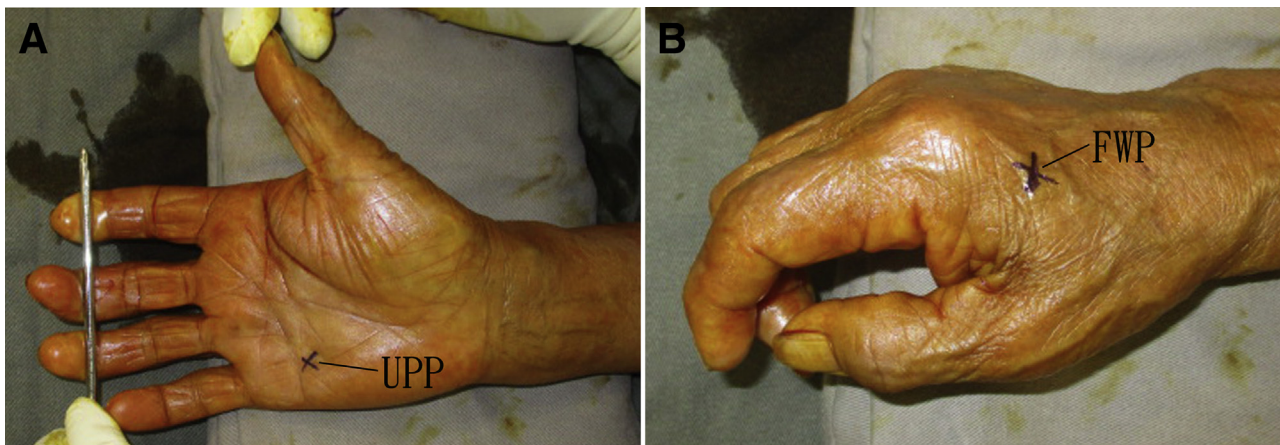


Fig 2. Endoscopic synovectomy of ulnar bursa in right hand. The patient is in the supine position with the hand on the side table. (A) The ulnar palmar portal (UPP) is on the volar side of the fifth metacarpal neck. (B) The first web portal (FWP) is at the dorsum of the first hand web just lateral to the second metacarpal neck.

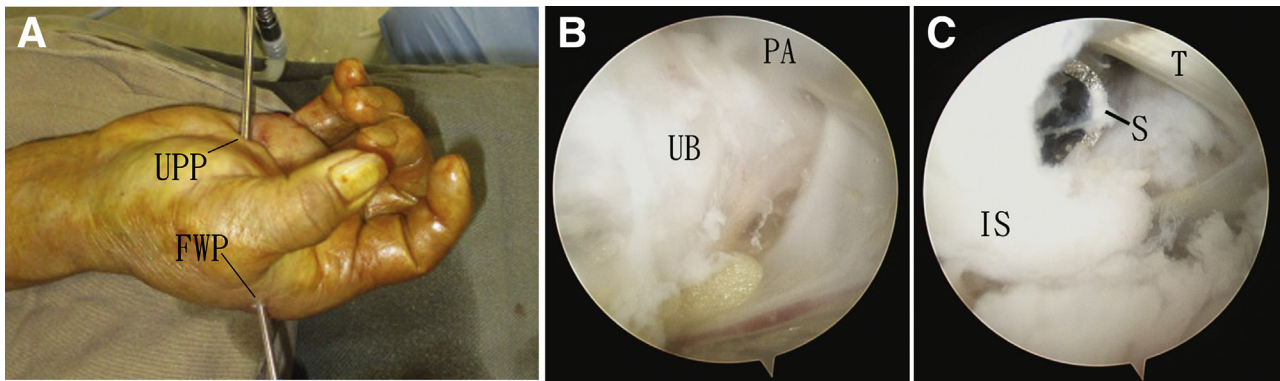


Fig 3. Endoscopic synovectomy of ulnar bursa in right hand. The patient is in the supine position with the hand on the side table. (A) Ulnar bursa endoscopy is performed through the ulnar palmar portal (UPP) and first web portal (FWP). (B) The ulnar palmar portal is the viewing portal. The ulnar bursa (UB) is identified underneath the palmar aponeurosis (PA). (C) The first web portal is the viewing portal. Inflamed synovium (IS) around the flexor tendon (T) is resected with an arthroscopic shaver (S).

the flexor tendon from the ulnar side.¹ Inflamed synovium around this tendon can be resected with an arthroscopic shaver (Dyonics; Smith & Nephew, Andover, MA) through the first web portal. During synovectomy on the ulnar side of the flexor tendon to the index finger, the flexor tendons to the long finger can be seen. Synovectomy can then be performed around these tendons until the flexor tendons to the ring finger are identified.

The arthroscope is switched to the first web portal. Synovectomy around the flexor tendons to the ring finger is performed with a shaver through the ulnar palmar portal. Finally, the flexor tendons to the little finger are identified, and synovectomy around the tendons is performed (Fig 3). It is important not to dissect toward the palmar aponeurosis to reduce the risk of injury to the superficial palmar arch and digital nerves. This completes synovectomy of the distal portion of the ulnar bursa. This step can also be referred

to as “transverse” synovectomy of the ulnar bursa, which is performed across the flexor tendons from the radial to ulnar side.

Proximal Synovectomy

The ulnar palmar and first web portals are interchangeable as the viewing and working portals. Each flexor tendon is traced proximally, and synovectomy around the tendons is performed proximally (Fig 4). The surgeon should be cautious not to breach the fascia covering the metacarpals and interossei to avoid injury to the deep palmar arch and deep branch of the ulnar nerve. This step is referred to as “longitudinal” synovectomy of the ulnar bursa, which is performed along the flexor tendons.

Confirmation of Complete Synovectomy

Both the ulnar palmar and first web portals can be used as the viewing portal. The flexor tendons are

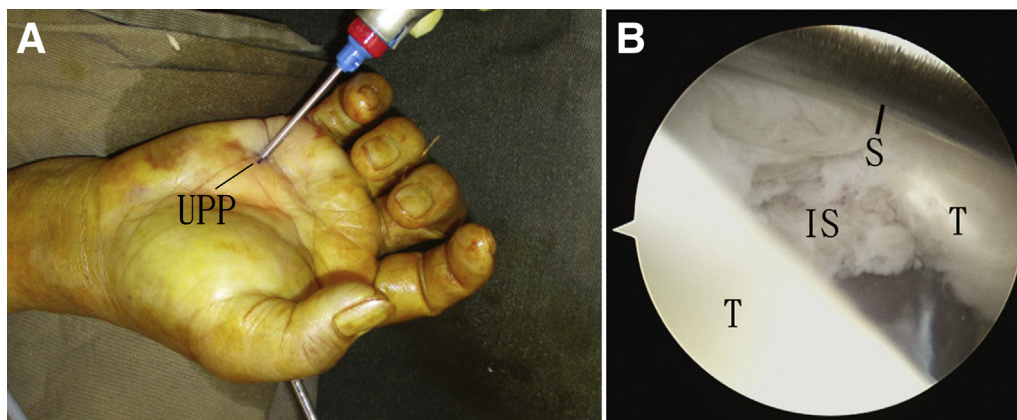


Fig 4. Endoscopic proximal synovectomy of ulnar bursa in right hand. The patient is in the supine position with the hand on the side table. (A) Proximal synovectomy is performed with the first web portal as the viewing portal and the ulnar palmar portal (UPP) as the working portal. (B) An endoscopic view shows proximal synovectomy along the flexor tendons. (IS, inflamed synovium; S, arthroscopic shaver; T, flexor tendons.)

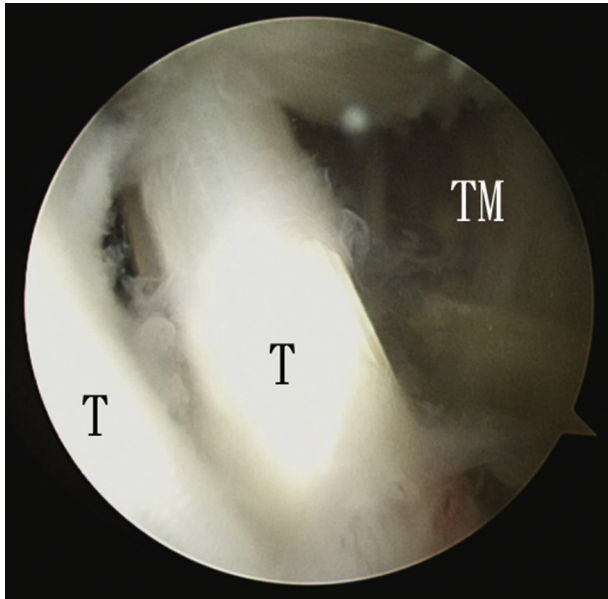


Fig 5. Endoscopic synovectomy of ulnar bursa in right hand. The patient is in the supine position with the hand on the side table. The ulnar palmar portal is the viewing portal. Complete synovectomy is confirmed. (T, flexor tendons; TM, thenar muscles.)

examined for any residual inflamed synovium (Fig 5, Video 1, Table 2). In the case of infection, a drain is inserted into the operative site through the portals.

Discussion

The transversely aligned ulnar palmar and first web portals allow instrumentation freedom and access to the entire palmar portion of the ulnar bursa. All other deep subfascial spaces of the palm can also be accessed through these 2 portals.¹¹ This is important if the exact location of suppurative infection of the palm is not certain.

Sequential transverse synovectomy and longitudinal synovectomy allow systematic synovectomy of the ulnar bursa of the palm. Although the portion of the ulnar bursa inside and proximal to the carpal tunnel

Table 2. Pearls and Pitfalls of Endoscopic Synovectomy of Ulnar Bursa

Pearls	Pitfalls
The portals are created at the level of the metacarpal necks.	The fascia covering the metacarpals and interossei should not be breached.
Dissection of the flexor tendons from the ulnar bursa is performed from the radial to ulnar direction.	Debridement toward the palmar aponeurosis should be avoided.
Transverse synovectomy followed by longitudinal synovectomy allows systematic synovectomy of the ulnar bursa.	

Table 3. Advantages and Risks of Endoscopic Synovectomy of Ulnar Bursa

Advantages	Risks
Better cosmesis	Injury to superficial and deep palmar branches
Less soft-tissue dissection	Injury to deep branch of ulnar nerve, digital nerves, and branches of superficial radial nerve
Less postoperative pain	Injury to flexor tendons
Complete assessment of subfascial spaces	Spread of infection among compartments
Avoidance of exposed tendons or nerves	
Adequate synovectomy	
Allowance of vigorous hand therapy immediately postoperatively	

can be approached with the longitudinally aligned portals for endoscopic carpal tunnel syndrome,¹³ we believe open surgery is a safer approach for synovectomy of the carpal tunnel.

The advantages of this arthroscopic technique include better cosmesis, less soft-tissue dissection, less postoperative pain, complete assessment of the subfascial spaces, avoidance of exposed tendons or nerves, adequate synovectomy, and allowance of vigorous hand therapy immediately postoperatively. The potential risks of this procedure include injury to the superficial and deep palmar branches, deep branch of the ulnar nerve, digital nerves, branches of the superficial radial nerve, and flexor tendons, as well as spread of infection among compartments (Table 3). This is a technically demanding procedure and should be attempted by experienced hand and wrist arthroscopists.

References

- Bouilleau L, Malghem J, Omoumi P, et al. Pseudotumoral ganglion cyst of a finger with unexpected remote origin: Multimodality imaging. *Skeletal Radiol* 2010;39:375-379.
- Ahlawat S, Corl FM, LaPorte DM, Fishman EK, Fayad LM. MDCT of hand and wrist infections: Emphasis on compartmental anatomy. *Clin Radiol* 2017;72:338.e1-338.e9.
- Chandrasekharan J, Sambandam SN, Cheriyaakara S, Mounasamy V. Tuberculous tenosynovitis presenting as finger drop: A case report and a systematic review of the literature. *Muscles Ligaments Tendons J* 2016;6:258-263.
- Naam NH. Flexor tenosynovial fistulas in the palm. *J Hand Surg Am* 2012;37:925-929.
- Lee SM, Lee WJ, Song AR. Tuberculous tenosynovitis and ulnar bursitis of the wrist. *Ann Rehabil Med* 2013;37:572-576.
- Wheen DJ, Tonkin MA, Green J, Bronkhorst M. Long-term results following digital flexor tenosynovectomy in rheumatoid arthritis. *J Hand Surg Am* 1995;20:790-794.

7. Millis MB, Millender LH, Nalebuff EA. Stiffness of the proximal interphalangeal joints in rheumatoid arthritis. The role of flexor tenosynovitis. *J Bone Joint Surg Am* 1976;58:801-805.
8. Mathews RE, Gould JS, Kashlan MB. Diffuse pigmented villonodular tenosynovitis of the ulnar bursa—A case report. *J Hand Surg Am* 1981;6:64-69.
9. Jamil W, Khan I, Robinson P, Thalava R. Acute compartment syndrome of the forearm secondary to infection within the space of Parona. *Orthopedics* 2011;34: e584-e587.
10. Jebson PJ. Deep subfascial space infections. *Hand Clin* 1998;14:557-566, viii.
11. Lui TH, Lee CH. Little finger flexor tendoscopy, endoscopy of the ulnar bursa and midpalmar space. *Arthrosc Tech* 2018;7:e817-e822.
12. Aguiar RO, Gasparetto EL, Escuissato DL, et al. Radial and ulnar bursae of the wrist: Cadaveric investigation of regional anatomy with ultrasonographic-guided tenography and MR imaging. *Skeletal Radiol* 2006;35: 828-832.
13. Osterwalder A, Reiner V, Reiner G, Lualdi P. Tissue absorption and distribution of ketoprofen after patch application in subjects undergoing knee arthroscopy or endoscopic carpal ligament release. *Arzneimittelforschung* 2002;52:822-827.