

Case report: mRNA COVID-19 vaccine-related acute pericarditis with evolution to myopericarditis

Craig Riddell ^{1*}, Nicola C. Edwards ¹, and Ralph Stewart ^{1,2}

¹Department of Cardiology, Green Lane Cardiovascular Service, Auckland City Hospital, 2 Park Road, Grafton, Auckland 1023, New Zealand; and ²School of Medicine, Faculty of Medical and Health Sciences, The University of Auckland, 85 Park Road, Grafton, Auckland 1023, New Zealand

Received 23 December 2021; first decision 7 February 2022; accepted 15 July 2022; online publish-ahead-of-print 25 July 2022

Background

Both acute pericarditis and myocarditis have been reported as rare complications following vaccination with the Pfizer-BioTech and Moderna mRNA COVID-19 vaccines.

Case summary

An 18-year-old man presented with clinical and electrocardiographic changes of acute pericarditis 2 days after receiving the second dose of the BNT162b2 (Pfizer–BioNTech) vaccine. His electrocardiogram also showed an incomplete right bundle branch block. Troponin T on presentation was normal (reference <14 ng/L) but subsequently increased to a peak 1080 ng/L by day 4 post vaccination. Evolving electrocardiographic changes and cardiac MRI findings were consistent with acute myopericarditis.

Discussion

This patient's clinical course was uncomplicated, which is consistent with studies indicating that post-COVID vaccine myocarditis usually has a mild course with a low chance of arrhythmia or heart failure. Troponin elevation is a part of the diagnostic criteria for myocarditis. This case is consistent with another report demonstrating that troponin levels can be within the normal range early in the clinical course of post-COVID vaccine myopericarditis. The incomplete right bundle branch block resolved by day 4 post-vaccination and thus may have represented early myocardial involvement at presentation. Further testing and monitoring should be considered in patients who present soon after COVID-19 mRNA vaccination with pericarditis features or minor conduction delays, in order to rule out progression to myopericarditis. Identifying myocardial involvement is clinically relevant as it indicates a risk of developing arrhythmia or heart failure, as well as having implications for physical activity advice and future booster vaccination.

Keywords

COVID-19 • COVID-19 vaccines • mRNA vaccine • Myocarditis • Pericarditis • SARS-CoV-2 • Case report

ESC Curriculum

6.6 Pericardial disease • 6.5 Cardiomyopathy

Learning points

- mRNA COVID vaccines have been temporally associated with an increased risk of acute pericarditis, myocarditis, and myopericarditis.
- Acute pericarditis usually has a benign clinical course. Myocarditis can have a benign course but can also be associated with arrhythmias, heart failure, and myocardial scarring.
- Diagnosing myocarditis is important to guide early management and for advice on physical activity and further vaccination.
- Patients presenting early with acute pericarditis may evolve to myopericarditis, suggesting further monitoring and repeat troponin testing is important.

* Corresponding author. Email: CraigR1@adhb.govt.nz

Handling Editor: Luca Arcari

Peer-reviewers: Vincenzo Nuzzi; Maria Mattioli

Compliance Editor: Abdelsalam Bensaud

Supplementary Material Editor: Tinka Julia van Trie

© The Author(s) 2022. Published by Oxford University Press on behalf of the European Society of Cardiology.

This is an Open Access article distributed under the terms of the Creative Commons Attribution-NonCommercial License (<https://creativecommons.org/licenses/by-nc/4.0/>), which permits non-commercial re-use, distribution, and reproduction in any medium, provided the original work is properly cited. For commercial re-use, please contact journals.permissions@oup.com

Introduction

Pericarditis, myopericarditis, and myocarditis are recognized rare associations of mRNA vaccines against COVID-19.¹ Studies have found a varying incidence based on population and methodology, with two major studies finding rates of myocarditis of approximately 4.1 and 12.9 per million vaccine doses.^{2,3} Males aged 12–39 years were found to have a four times higher incidence.² There is less data available on rates of pericarditis compared with myocarditis, but one study found pericarditis to have a relative incidence of 1.8 compared with myocarditis.⁴

Differentiating pericarditis and myocarditis is clinically challenging and relies on serum or imaging biomarkers. Pericarditis is considered more benign and pathways do not support routine hospitalization.⁵ We describe a patient who presented after their second dose of the Pfizer–BioNTech (BNT162b2) vaccine with pericarditis rapidly evolving to myopericarditis and discuss the clinical importance of recognizing this presentation.

Timeline

Time post second Pfizer mRNA vaccine	Event
15 h	Awoke with central chest pain.
30 h	Electrocardiogram (ECG) in primary care showed pericarditis.
32 h	Troponin 9 ng/L (normal < 15), C-reactive protein was 36 mg/L (reference <15 mg/L), temperature 38.5°C.
38 h	Troponin 31 ng/L.
3 days	Cardiac MRI consistent with low grade focal myocarditis.
4 days	Troponin peak at 1040 ng/L.
8 days	Troponin 18 ng/L, ECG changes resolving, clinically well.

Case presentation

An 18-year-old male with no previous health problems and an uncomplicated first dose of Pfizer–BioNTech (BNT162b2) vaccine developed central pleuritic chest pain 15 h after his second vaccination dose. Assessment in the emergency department 32 h after vaccination demonstrated pyrexia (38.5°C) and tachycardia (123 b.p.m.) with normal blood pressure (121/71 mmHg). A pericardial friction rub was not heard on initial examination but was auscultated by an experienced cardiologist 2 days post vaccination. There were no findings suggestive of decompensated heart failure on admission: jugular venous pressure was not elevated, the chest was clear to auscultation, and there was no pedal oedema. On admission, the C-reactive protein (CRP) was 24 mg/L (reference range <5 mg/L), and plasma troponin T was within the normal reference range at 9 ng/L (reference range <15 ng/L). The electrocardiogram (ECG) demonstrated mild global ST segment elevation and

an incomplete right bundle branch block with rSR' pattern in leads V1 and V2 and with maximal QRS complex duration of 114 ms (Figure 1). On the basis of the presentation and ECG findings, a clinical diagnosis of presumed vaccine-related pericarditis was made. No other viral cause for pericarditis was found, based on history and a full viral respiratory panel including for severe acute respiratory syndrome coronavirus 2 being negative. He was admitted due to ongoing pain control requirements, and a repeat troponin 3 h later had risen to 18 ng/L. Serial troponins demonstrated an increasing troponin with a peak of 1040 ng/L on days 4 post vaccination (Figure 2).

Transthoracic echocardiography performed on day 2 post vaccination demonstrated normal left ventricular ejection fraction (55–60%) and low-normal global longitudinal strain (–16.8%, Phillips CVx normal range $-18.8\% \pm 3.6$). Cardiovascular magnetic resonance imaging (CMR) performed on day 3 post vaccination confirmed normal left ventricular (LV) ejection fraction and no regional wall motion abnormality. High signal on T2-weighted fat saturated sequences was demonstrated in the sub-epicardial LV lateral wall with corresponding late gadolinium enhancement, consistent with a focal area of acute myocarditis (Figure 3). The remote myocardium and pericardium were normal, and there was no pericardial effusion. Investigations to exclude coronary artery disease as a cause for this patient's presentation were not performed due to their young age, absence of vascular risk factors ascertained on history, and lack of regional wall motion abnormalities found on echocardiogram and CMR. An endomyocardial biopsy was not performed as there was no evidence of heart failure and there were clear features of myocarditis seen on CMR.

The patient was managed on a general cardiology ward with telemetry facilities. His chest pain was managed with colchicine (500 mcg orally once daily) and ibuprofen (400 mg orally three times daily) with symptom resolution by day 4 post vaccination. Corticosteroids and intravenous immune globulins were not given. By day 4 post vaccination, there was still ST elevation in the lateral leads, but the incomplete right bundle branch block had resolved (Figure 4). There was no clinical evidence of heart failure and no arrhythmia on ECG monitoring. The C-reactive protein decreased towards the normal range by day 5 and preceded a downward trend in troponin T (Figure 2). ECG changes had normalized by day 8 at the time of discharge. The patient was discharged with a 3-month course of 500 mcg colchicine daily. On discharge, they were advised to avoid strenuous exertion for 3 months, defined as exertion such that they could not comfortably converse at the same time.

The patient was reviewed in clinic 5 weeks after discharge with no clinical sequelae and a normal ECG. At the time of clinic, there was a discussion on the risks and benefits of booster vaccination. It was recommended that the patient should not have an mRNA booster vaccine until clearer data was available on the risk of myocarditis recurrence. The patient later elected to have a non-mRNA booster vaccine and did not present with any complications following this. A follow-up cardiac MRI was requested 3 months post discharge to ensure resolution of myocarditis features, but the patient did not attend this appointment.

Discussion

High sensitivity assays for troponin T or I are sensitive and specific markers of myocardial injury.⁶ Troponin elevation is part of the

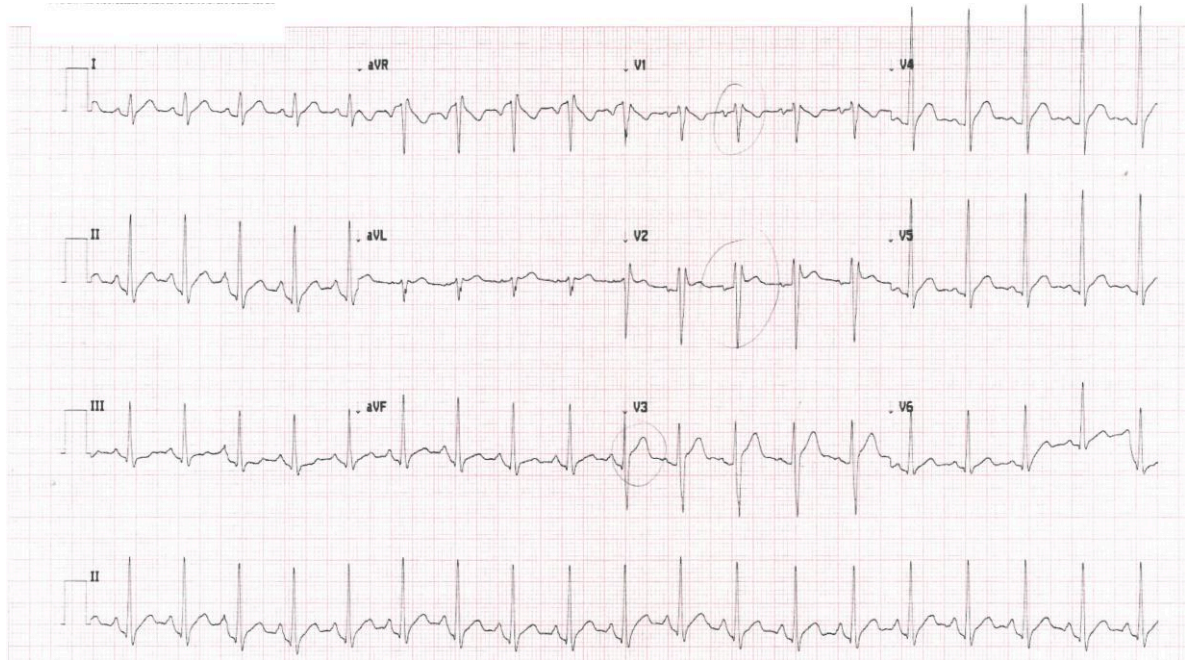


Figure 1 Electrocardiogram on presenting to hospital (32 h post-vaccination) demonstrating PR interval depression, incomplete right bundle branch block, and ST segment elevation.

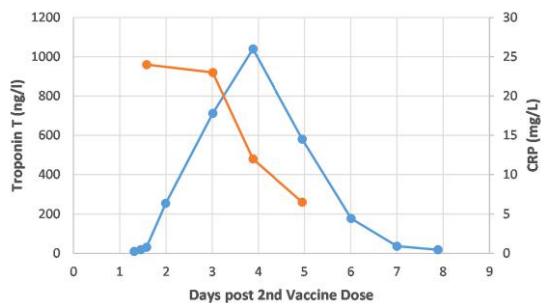


Figure 2 Troponin and CRP changes after vaccination.

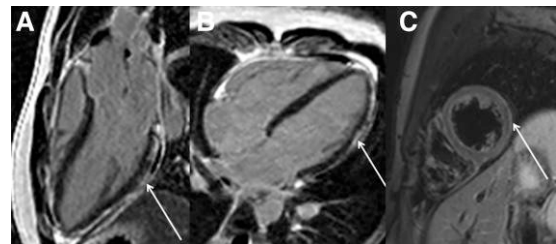


Figure 3 (A and B) Phase sensitive inversion recovery cardiac magnetic resonance images performed 3 days after 2nd dose of Pfizer–BioNTech vaccine (BNT162b2). Sub-epicardial late gadolinium enhancement (hyperintense signal arrows) is observed in the basal, mid, and apical lateral wall in a pattern consistent with myocarditis. (C) T2-weighted fat saturated image taken at a mid-left ventricular level showing focal areas of corresponding sub-epicardial high signal intensity indicative of myocardial oedema.

diagnostic criteria for acute myocarditis,⁵ which is unlikely if the troponin level is normal.⁷ Current guidelines suggest measuring troponin levels in patients presenting with possible pericarditis or myocarditis after an mRNA COVID vaccine.^{5,8} In the two largest cohort studies of post-COVID vaccine myocarditis, all 96 cases had elevated troponins.^{2,9}

This case is consistent with another report demonstrating that troponin levels can be within the normal range early in the course of post-COVID vaccine myopericarditis.⁷ The early chest pain with a later troponin rise suggests that pericarditis after an mRNA COVID-19 vaccine can progress to include myopericarditis. Thus, a single normal plasma troponin level at presentation may not be sufficient to exclude post-COVID vaccine myopericarditis. A similar delayed troponin rise has been observed in patients hospitalized with

COVID-19 who also had myocardial injury. One study found 8% had a normal troponin level within the first 24 h of admission, and then developed an elevated troponin level between 24 and 48 h.¹⁰

The temporal relationship between the second dose of an mRNA COVID vaccine and symptom onset indicates the vaccine as the most likely aetiology for this patient's myopericarditis. This is consistent with published data from large population studies, where myocarditis is more likely after a second vaccine dose and symptoms typically appear within a few days of vaccination.² However, currently there is no specific test to confirm the mRNA vaccine hypersensitivity myocarditis.

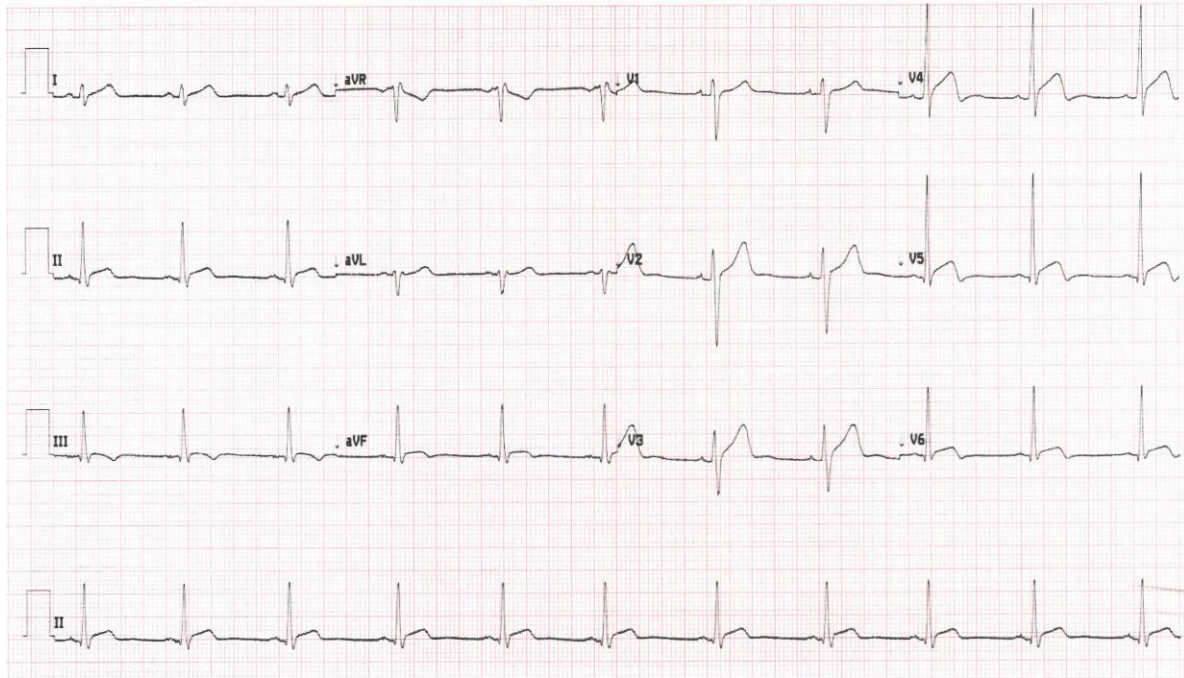


Figure 4 Electrocardiogram 4 days after vaccination showing ongoing ST elevation most prominently in the lateral leads (V4 to V6).

Differentiating pericarditis and myocarditis might be important. Over 80% of acute pericarditis is idiopathic or thought to have a viral cause.¹¹ Complications such as cardiac tamponade (1.2%) or constrictive pericarditis (0.5%) are rare in these patients during long-term follow-up.¹¹ Uncomplicated pericarditis is thus often managed without hospital admission if there are no concerning features found on assessment.¹² In contrast, acute myocarditis is associated with a higher risk of disease progression and complications including heart failure, ventricular arrhythmias, and death.¹³ Therefore, closer observation in hospital with ECG monitoring is usually recommended, as well as delaying return to exercise.¹⁴ Post-COVID vaccine myocarditis was found to have a mild clinical course in over 95% patients in one large study.³ However, there have been rare reports of fulminant myocarditis after mRNA COVID-19 vaccination.¹⁵ Given this, correct diagnosis of pericarditis versus myopericarditis or myocarditis is important to guide further investigation and monitoring in patients presenting post-COVID-19 mRNA vaccination.

Incomplete right bundle branch block can be a normal variant, which is not associated with adverse outcomes in otherwise healthy individuals.¹⁶ In this case, the incomplete right bundle branch block was transient. Though it was not recognized as significant on admission, the incomplete right bundle branch block may have represented an early sign of myocardial involvement as part of the post-COVID vaccine myopericarditis. Minor conduction delays may thus serve as an additional 'red flag' when deciding on the need for admission and a longer period of monitoring.

Cardiovascular magnetic resonance imaging (CMR) is important in the diagnosis of suspected myocarditis as it is non-invasive and has good diagnostic accuracy.¹⁷ In this case CMR was useful to confirm the diagnosis. Coronary artery imaging was not performed because the clinical presentation, electrocardiograms (ECGs),

echocardiogram, and CMR were considered to provide strong evidence for the diagnosis of myopericarditis, rather than coronary artery disease.

The patient's pericarditis symptoms were treated with a prolonged course of colchicine because there is evidence of reduced recurrence in patients with acute pericarditis from non-mRNA vaccine aetiologies.¹⁸ This patient's myocarditis component was mild, with no clinical complications during admission. The left ventricular ejection fraction was in the normal range and no arrhythmias occurred. Troponin T and C-reactive protein returned to near-normal within a week and the incomplete right bundle branch block resolved within the same timeframe. This clinical course is consistent with studies which suggest post-vaccine myocarditis usually has a mild course.³

The association of COVID-19 mRNA vaccines with both pericarditis and myocarditis contrasts with most cases of idiopathic pericarditis, which are often presumed to have a viral cause, and are usually not associated with myocarditis.¹² The mechanisms responsible, and the reasons why younger men are more likely to suffer pericarditis and myocarditis after mRNA vaccination, are currently uncertain. The risks of recurrence after further doses of the same vaccine are uncertain, but caution is advised.¹⁹ Current US Centre for Disease Control advice on vaccine boosters does not distinguish between patients who have had pericarditis and myocarditis post mRNA COVID vaccination.¹⁹

Conclusions

This case suggests that observation and repeat troponin testing (either as inpatient or outpatient) in patients who present with acute pericarditis is important, in order to ensure a diagnosis of

myopericarditis is not missed. This is likely more important in patients who are investigated early after the onset of pericarditis symptoms or who have evidence of conduction disease, as in this case study.

Lead author biography



Craig Riddell is a trainee physician based in Auckland, New Zealand. In addition to clinical experience, he has worked as a management consultant for Boston Consulting Group and has a Masters in Legal Studies focusing on healthcare policy issues. He is interested in cardiology research and hopes to train as a cardiologist.

Supplementary material

[Supplementary material](#) is available at *European Heart Journal – Case Reports* online.

Slide sets: A fully edited slide set detailing this case and suitable for local presentation is available online as [Supplementary data](#).

Consent: The authors confirm that written consent for submission of the case report including images and associated text has been obtained from the patient in line with COPE guidance.

Conflict of interest: None declared.

Funding: None declared.

References

- Gargano JW, Wallace M, Hadler SC, Langley G, Su JR, Oster ME, Broder KR, Gee J, Weintraub E, Shimabukuro T, Scobie HM, Moulia D, Markowitz LE, Wharton M, McNally VV, Romero JR, Talbot HK, Lee GM, Daley MF, Oliver SE. Use of mRNA COVID-19 vaccine after reports of myocarditis among vaccine recipients: update from the advisory committee on immunization practices—United States, June 2021. *MMWR Morb Mortal Wkly Rep* 2021;**70**:977–982.
- Bozkurt B, Kamat I, Hotez PJ. Myocarditis with COVID-19 mRNA vaccines. *Circulation* 2021;**144**:471–484.
- Mevorach D, Anis E, Cedar N, Bromberg M, Haas EJ, Nadir E, Olsha-Castell S, Arad D, Hasin T, Levi N, Asleh R, Amir O, Meir K, Cohen D, Dichtiar R, Novick D, Hershkovitz Y, Dagan R, Leitersdorf I, Ben-Ami R, Miskin I, Saliba W, Muhsen K, Levi Y, Green MS, Keinan-Boker L, Alroy-Preis S. Myocarditis after BNT162b2 mRNA vaccine against Covid-19 in Israel. *N Engl J Med* 2021;**385**:2140–2149.
- Diaz GA, Parsons GT, Gering SK, Meier AR, Hutchinson I V, Robicsek A. Myocarditis and pericarditis after vaccination for COVID-19. *JAMA* 2021;**326**:1210–1212.
- The Immunisation Advisory Centre, Australasian College for Emergency Medicine PR in EDIC. Australian and New Zealand guideline for assessment of possible vaccine-induced pericarditis/myocarditis in children and adolescents presenting to the ED.
- Collet J-P, Thiele H, Barbato E, Barthélémy O, Bauersachs J, Bhatt DL, Dendale P, Dorobantu M, Edvardsen T, Folliguet T, Gale CP, Gilard M, Jobs A, Jüni P, Lambrou E, Lewis BS, Mehili J, Meliga E, Merkely B, Mueller C, Roffi M, Rutten FH, Sibbing D, Siontis GCM, ESC Scientific Document Group. 2020 ESC guidelines for the management of acute coronary syndromes in patients presenting without persistent ST-segment elevation: the task force for the management of acute coronary syndromes in patients presenting without persistent ST-segment elevation of the European Society of Cardiology (ESC). *Eur Heart J* 2021;**42**:1289–1367.
- Luk A, Clarke B, Dahdah N, Ducharme A, Krahn A, McCrindle B, Mizzi T, Naus M, Udell JA, Virani S, Zieroth S, McDonald M. Myocarditis and pericarditis after COVID-19 mRNA vaccination: practical considerations for care providers. *Can J Cardiol* 2021;**37**:1629–1634.
- Myocarditis and pericarditis after COVID-19 vaccination: guidance for healthcare professionals - GOV.UK <https://www.gov.uk/government/publications/myocarditis-and-pericarditis-after-covid-19-vaccination/myocarditis-and-pericarditis-after-covid-19-vaccination-guidance-for-healthcare-professionals> (6 December 2021).
- Witberg G, Barda N, Hoss S, Richter I, Wiessman M, Aviv Y, Grinberg T, Auster O, Dagan N, Balicer RD, Kornowski R. Myocarditis after Covid-19 vaccination in a large health care organization. *N Engl J Med* 2021;**385**:2132–2139.
- Nuzzi V, Merlo M, Specchia C, Lombardi CM, Carubelli V, Iorio A, Inciardi RM, Bellasi A, Canale C, Camporotondo R, Catagnano F, Dalla Vecchia LA, Giovinazzo S, Maccagni G, Mapelli M, Margonato D, Monzo L, Oriecua C, Peveri G, Pozzi A, Provenzale G, Sarullo F, Tomasoni D, Ameri P, Gnechi M, Leonardi S, Agostoni P, Carugo S, Danzi GB, Guazzi M, La Rovere MT, Mortara A, Piepoli M, Porto I, Volterrani M, Senni M, Metra M, Sinagra G. The prognostic value of serial troponin measurements in patients admitted for COVID-19. *ESC Hear Fail* 2021;**8**:3504–3511.
- Imazio M, Brucato A, Maestroni S, Cumetti D, Belli R, Trincherio R, Adler Y. Risk of constrictive pericarditis after acute pericarditis. *Circulation* 2011;**124**:1270–1275.
- Imazio M, Gaita F, LeWinter M. Evaluation and treatment of pericarditis: a systematic review. *JAMA* 2015;**314**:1498–1506.
- Anzini M, Merlo M, Sabbadini G, Barbati G, Finocchiaro G, Pinamonti B, Salvi A, Perkan A, Di Lenarda A, Bussani R, Bartunek J, Sinagra G. Long-term evolution and prognostic stratification of biopsy-proven active myocarditis. *Circulation* 2013;**128**:2384–2394.
- Sinagra G, Anzini M, Pereira NL, Bussani R, Finocchiaro G, Bartunek J, Merlo M. Myocarditis in clinical practice. *Mayo Clin Proc* 2016;**91**:1256–1266.
- Verma AK, Lavine KJ, Lin C-Y. Myocarditis after Covid-19 mRNA vaccination. *N Engl J Med* 2021;**385**:1332–1334.
- Fernández-Lozano I, Brugada J. Right bundle branch block: are we looking in the right direction? *Eur Heart J* 2013;**34**:86–88.
- Lurz P, Luecke C, Eitel I, Föhrenbach F, Frank C, Grothoff M, de Waha S, Rommel K-P, Lurz JA, Klingel K, Kandolf R, Schuler G, Thiele H, Gutberlet M. Comprehensive cardiac magnetic resonance imaging in patients with suspected myocarditis: the MyoRacer-trial. *J Am Coll Cardiol* 2016;**67**:1800–1811.
- Alabed S, Cabello JB, Irving GJ, Qintar M, Burls A. Colchicine for pericarditis. *Cochrane Database Syst Rev* 2014;**8**:8–42.
- Centre for Disease Control. Interim Clinical Considerations for Use of COVID-19 Vaccines <https://www.cdc.gov/vaccines/covid-19/clinical-considerations/covid-19-vaccines-us.html> (6 December 2021).