

Air in unusual location after contrast-enhanced computed tomography

Ujjwal Gorski, Kushaljit S Sodhi, Budhi S Yadav¹, Niranjan Khandelwal

Departments of Radiodiagnosis and Imaging and ¹Radiotherapy, Postgraduate Institute of Medical Education and Research, Chandigarh, Haryana and Punjab, India

Address for correspondence: Dr. Ujjwal Gorski, Department of Radiodiagnosis and Imaging, Postgraduate Institute of Medical Education and Research, Sector-12, Chandigarh - 160 012, Haryana and Punjab, India. E-mail: ujjwalgorski@gmail.com

A 45-year-old woman, who was operated two years back for carcinoma left breast and had completed radiotherapy and chemotherapy underwent a contrast-enhanced computed tomography (CECT) scan for routine follow-up. A CT scan of the chest and abdomen was done, with oral and intravenous contrast. Non-ionic intravenous contrast (100 mL) was injected with a power injector, through the left antecubital vein. The CT scan revealed a patch of fibrosis in the upper lobe of the left lung, absent left breast, and hepatic steatosis. No locoregional or distant metastasis was seen. In addition, the radiologist conducting the study noticed the presence of air in an unusual location [Figures 1 and 2].

QUESTIONS

- Q1: Which structures show presence of air?
Q2: What is the probable source of this air?
Q3: What treatment does this patient need?

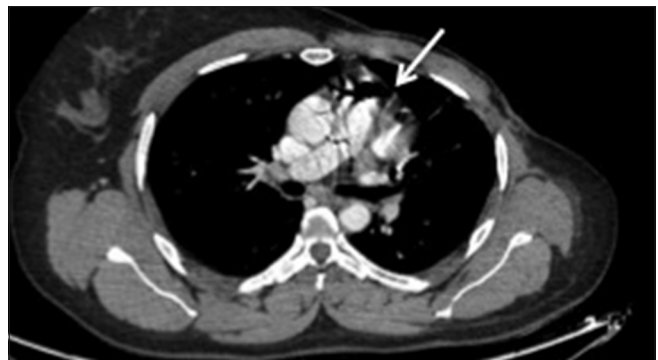

Figure 1: Axial multiplanar reformatted (MPR) image showing air in the main pulmonary artery (arrow)

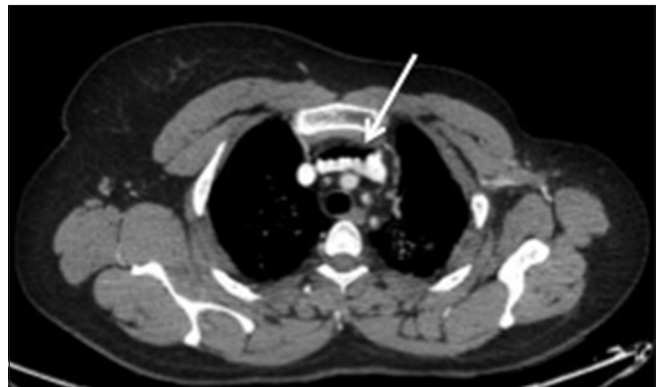


Figure 2: Axial multiplanar reformatted (MPR) image showing air in the brachiocephalic vein (arrow)

Access this article online	
Quick Response Code: 	Website: www.lungindia.com
	DOI: 10.4103/0970-2113.168124

ANSWERS

Answer 1: Air is visualized in the main pulmonary artery (arrow in Figure 1) and left brachiocephalic vein (arrow in Figure 2).

Answer 2: Air entered the venous system inadvertently during injection of the contrast medium by the power injector.

Answer 3: The patient did not receive any treatment, as she was asymptomatic and on clinical examination was found to be hemodynamically stable. Hence, she was discharged uneventfully later in the day, after being kept under observation.

DISCUSSION

Small (less than 1 cm in diameter) and medium (few small bubbles or 1 to 2 cm bubble-sized) venous air emboli (VAE) are reported to occur in 11 to 23% of the patients undergoing contrast-enhanced CT examination.^[1,2] Although massive VAE (200-300ml) can be fatal,^[3] most iatrogenic VAE cases, during CECT, involve injection of a few milliliters of air, and are clinically insignificant. Pham *et al.* have reported two non-fatal cases, where 135 ml of air was injected into the venous system by power injectors during CECT.^[4] Venous air embolism during a contrast-enhanced CT scan is being increasingly reported as a non-fatal event.^[1,5]

Three elements have to be present for a significant amount of air to enter the vascular system: (1) A source of air, which is usually the atmosphere; (2) a connection between the air source and the vascular system, and (3) a pressure gradient to allow air entry.^[6] During contrast administration air can enter the vascular system during cannula insertion, when connecting the cannula to the injector tube, and through microbubbles in the contrast.^[2]

Most of the time, small emboli are absorbed in the blood or the alveoli of the lungs without any inadvertent consequence and the patients remain asymptomatic. Larger emboli, however, can obstruct the right ventricle outflow, which may lead to circulatory failure. Multiple factors affect the severity of VAE, such as, the amount of air injected, the speed of the injection, the body position at the time of injection, and the patient's state of health. Clinical features that are uncommonly described with symptomatic VAE include acute shortness of breath, chest pain, a feeling of impending death, cyanosis, hypotension, pulmonary edema, paralysis, and seizures.^[4]

The main pulmonary artery and the axillary and subclavian veins are the most common locations for the entrapment of air^[1] and are easily detected on a CT scan as air bubbles or air-fluid levels.

Few medical conditions allow a VAE to enter the arterial circulation, increasing the risk of significant complications manifold. Such conditions include atrial or ventricular septal defects and conditions with arteriovenous malformation.^[4] A patent foramen ovale may be retained in approximately 25 to 35% of the general population, with an otherwise normal heart. This may allow the venous air embolism that reaches the heart to enter the arterial circulation, where it becomes significant as an air embolus, as small as 1 ml, which may get access into the brain or coronary arteries, causing clinically significant blockage.^[7] Extreme caution must be ensured to prevent air embolism, even during routine administration of intravenous contrast or fluids, in this selective group of patients.

Small to medium VAE do not require any treatment. In severe cases of VAE, placing the patient in the left lateral decubitus and Trendelenburg (Durant) positions is advised. This leads to trapping of air in the apex of the right ventricle and reduces the air-lock in the right ventricular outflow. These positions also minimize air embolism to the pulmonary arteries. Placing the patient on 100% oxygen may also be considered, to facilitate resorption of the trapped air in the vascular system.^[4]

CONCLUSION

This radiology quiz illustrates the awareness of this entity, which is important for emergency physicians and radiologists, so that it may not lead to a red herring signal and lead to many more invasive diagnostic tests, which may be unnecessary and only consume the limited emergency resources available.

REFERENCES

1. Woodring JH, Fried AM. Nonfatal venous air embolism after contrast-enhanced CT. *Radiology* 1988;167:405-7.
2. Groell R, Schaffler GJ, Reinmueller R, Kern R. Vascular air embolism: Location, frequency, and cause on electron-beam CT studies of the chest. *Radiology* 1997;202:459-62.
3. Yeakel AE. Lethal air embolism from plastic blood-storage container. *JAMA* 1968;204:267-9.
4. Pham KL, Cohen AJ. Iatrogenic venous air embolism during contrast enhanced computed tomography: A report of two cases. *Emerg Radiol* 2003;10:147-51.
5. Sodhi KS, Das PJ, Malhotra P, Khandelwal N. Venous air embolism after intravenous contrast administration for computed tomography. *J Emerg Med* 2012;42:450-1.
6. Orebaugh SL. Venous air embolism: Clinical and experimental considerations. *Crit Care Med* 1992;20:1169-77.
7. Petts JS, Presson RG Jr. A review of the pathophysiology of venous air embolism. *Anesthesiol Rev* 1991;18:29-37.

How to cite this article: Gorsi U, Sodhi KS, Yadav BS, Khandelwal N. Air in unusual location after contrast-enhanced computed tomography. *Lung India* 2015;32:644-5.

Source of Support: Nil, **Conflict of Interest:** None declared.