

Undetected displacement of a subcutaneous implantable cardioverter-defibrillator lead. Importance of performing a chest X-ray during the first weeks post-implant: a case report

Jose Apolo ^{1*}, Rodolfo San Antonio ^{1,2}, Lluís Mont ^{1,2,3}, and José María Tolosana^{1,2,3}

¹Arrhythmia Section, Cardiovascular Clinic Institute, Hospital Clínic, University of Barcelona, 170 Villarroel Street, 08036 Barcelona, Catalonia, Spain; ²Centro de Investigación Biomédica en Red Enfermedades Cardiovasculares (CIBERCV), Madrid, Spain; and ³Institut d'Investigacions Biomèdiques August Pi i Sunyer (IDIBAPS), Barcelona, Catalonia, Spain

Received 17 May 2019; first decision 13 June 2019; accepted 1 October 2019; online publish-ahead-of-print 22 October 2019

Background

In recent years, subcutaneous implantable cardioverter-defibrillator (S-ICD) implants have progressively increased and have been shown to be safe and highly successful, affording low reintervention rates regardless of the technique used.

Case summary

We present a case of S-ICD implantation in a patient diagnosed with idiopathic ventricular fibrillation. In the first follow-up consultation the patient showed appropriate detection parameters in the three configurations. However, chest X-ray revealed lead displacement with a tip migration from the manubrium area of the sternum to the xiphoid process.

Discussion

This case highlights the importance of performing at least one chest X-ray during the first weeks after S-ICD implantation, allowing the detection of a problem such as lead displacement, which can lead to undersensing of ventricular arrhythmias or S-ICD oversensing.

Keywords

Cardiac devices • S-ICD • X-ray • Case report

Learning points

- Lead dislodgement after subcutaneous implantable cardioverter-defibrillator (S-ICD) implantation is a rare complication.
- Routine device checks may be not sufficient to ensure adequate S-ICD performance.
- A chest X-ray within the first weeks after implantation is needed to assess correct lead position and complement device revision.

Introduction

Subcutaneous implantable cardioverter-defibrillators (S-ICDs) are alternatives to transvenous implantable cardioverter-defibrillators (ICDs) for preventing sudden cardiac death in patients who do not require bradycardia or antitachycardia pacing.¹ These devices were developed to eliminate the primary risks of transvenous ICDs, such as lead dysfunction or device infection, both associated with increased morbi-mortality.^{2,3}

* Corresponding author. Tel: +34 674991455, Email: joalejandrea@gmail.com

Handling Editor: Borislav Dinov

Peer-reviewers: Rami Riziq Yousef Abumualeq and George K. Andrikopoulos

Compliance Editor: Rahul Mukerjee

Supplementary Material Editor: Peregrine Green

© The Author(s) 2019. Published by Oxford University Press on behalf of the European Society of Cardiology.

This is an Open Access article distributed under the terms of the Creative Commons Attribution Non-Commercial License (<http://creativecommons.org/licenses/by-nc/4.0/>), which permits non-commercial re-use, distribution, and reproduction in any medium, provided the original work is properly cited. For commercial re-use, please contact journals.permissions@oup.com

The S-ICD implant procedure has been shown to be safe and the implant success rate high, accompanied by low reintervention rates regardless the technique used.^{4,5} In addition, the design of high-pass filters (SMARTpass filtering) has drastically reduced T-wave oversensing.⁶

Timeline

Day	Hour	Event
0		Subcutaneous implantable cardioverter-defibrillator (S-ICD) implant after aborted sudden death and normal cardiovascular studies.
13	10:30	First follow-up consultation and detection of electrode displacement.
16	08:30	Reintervention for S-ICD implant with the three incisions technique.
17	10:00	Device and X-ray control, patient discharge.
45	10:00	Follow-up consultation demonstrating normal functioning of the S-ICD.

Case presentation

A 29-year-old man with no previous history of cardiovascular disease (weight 76 kg; height 177 cm; body mass index 24) presented with out-of-hospital cardiac arrest. The rhythm initially recorded was ventricular fibrillation. He was admitted to another centre where a complete cardiac study (echocardiogram, cardiac magnetic resonance, ajmaline test, and coronary angiography) was performed. The specific cause of cardiac arrest was not identified. According to European Society of Cardiology (ESC) guidelines, implantable cardioverter-defibrillator (ICD) implantation is recommended for survivors of idiopathic ventricular fibrillation (Class of recommendation I; Level of evidence B)¹; therefore, an S-ICD (EMBLEM; Boston Scientific) was implanted using the two-incision technique. The secondary vector (distal-tip-to-can) was the chosen configuration, and the SMARTPass sensing filter was also activated. The patient was discharged and referred to our centre 13 days later for device and clinical follow-up.

At this 13-day follow-up, no clinical complications were revealed. Assessment of the S-ICD electrograms revealed unremarkable results (Figure 1). Neither arrhythmias nor oversensing episodes were identified, and the secondary vector continued as the configuration of choice to obtain adequate signal amplitude. The SMARTPass filter remained activated (Figure 2).

According to our institutional protocol, a chest X-ray was performed, which surprisingly revealed an important inferior lead displacement (by about 9 cm). This lead dislodgement had not been previously detected during device interrogation, because the distal electrode moved to the proximal electrode position, so the detection of the device remained unchanged (Figure 3).

The heart did not interpose between the coil and the ICD generator; therefore, the lead was replaced. During reintervention, an S-ICD lead was found to be stitched without sufficient firmness at the xiphoid level, allowing displacement of the distal electrode 2 cm above the xiphoid appendage. To reduce the risk of displacement of the new lead, the three-incision technique was performed, fixing the lead tip to the underlying fascia and muscle at the manubriosternal junction, 1 cm left of the midline. Further dislodgement was not subsequently observed (Figure 4).

Discussion

This case shows that S-ICD lead displacement can occur without detection by remote device monitoring (Latitude) or routine device revision. This should be kept in mind because important lead displacement can have important repercussions in the treatment of ventricular arrhythmias. Proper functioning of the S-ICD is directly related to the position of its components (device-electrode) in the thorax and their relationships with the heart in the presence of malignant arrhythmias.

The displacement of an S-ICD lead is a rare complication (0.8–1.7%), and its primary aetiology is inadequate fixation of the suture olive in the muscular plane. This migration usually manifests itself by producing inappropriate discharges as a result of extracardiac detection signals. Three circumstances necessitate intraoperative S-ICD lead repositioning: (i) when the defibrillation threshold is not met (failure of a defibrillation test); (ii) when sensing fails in the three vectors; and (iii) when the myocardium does not interpose between the coil and the generator.^{7–10}

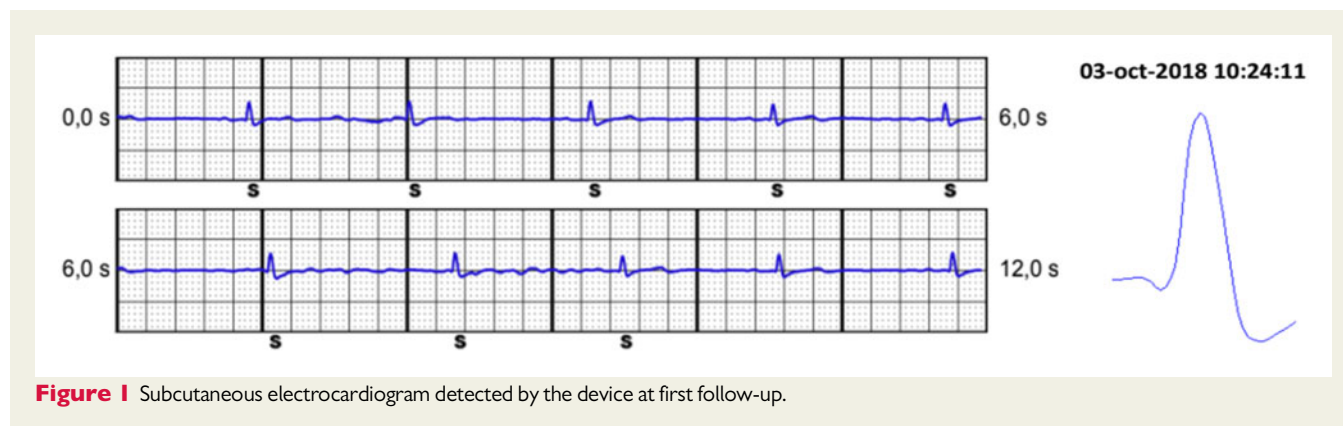


Figure 1 Subcutaneous electrocardiogram detected by the device at first follow-up.

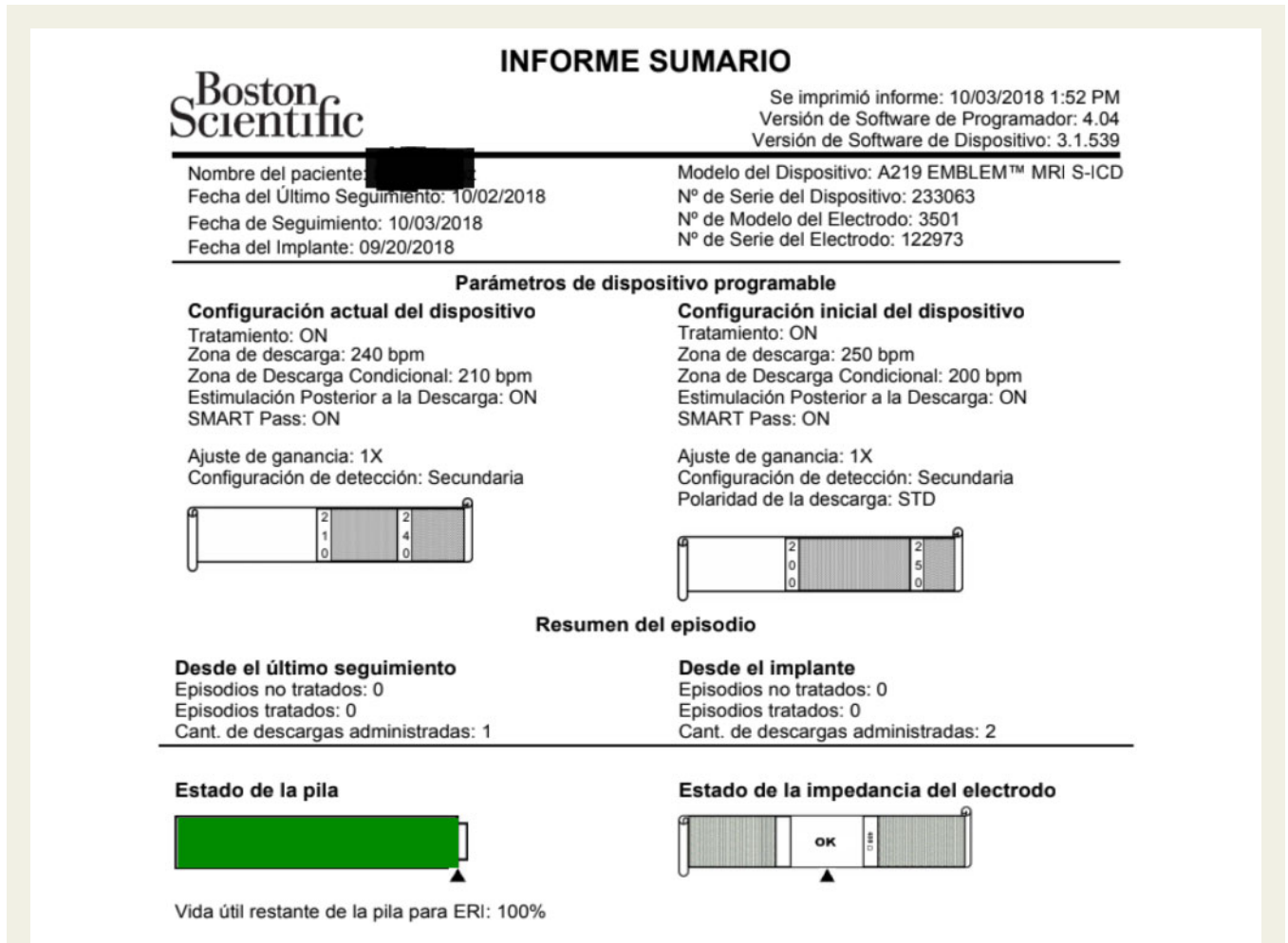


Figure 2 Thirteen days post-implant. Device interrogation does not show alerts; the SMARTPass is activated.

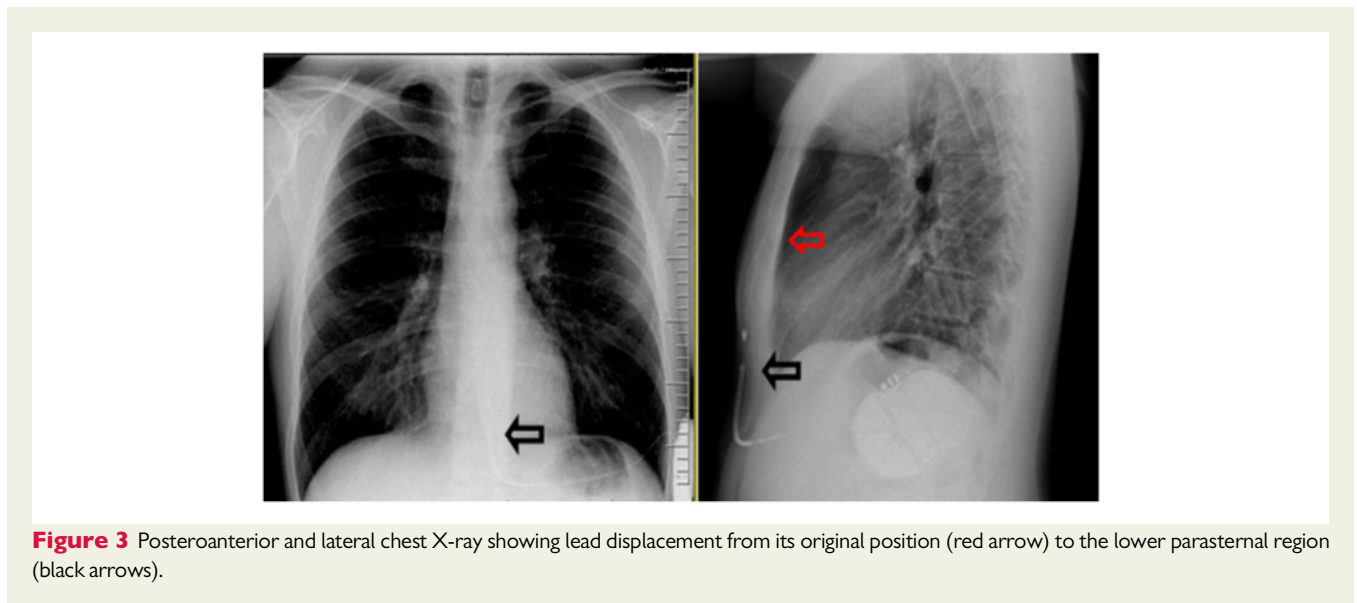


Figure 3 Posteroanterior and lateral chest X-ray showing lead displacement from its original position (red arrow) to the lower parasternal region (black arrows).

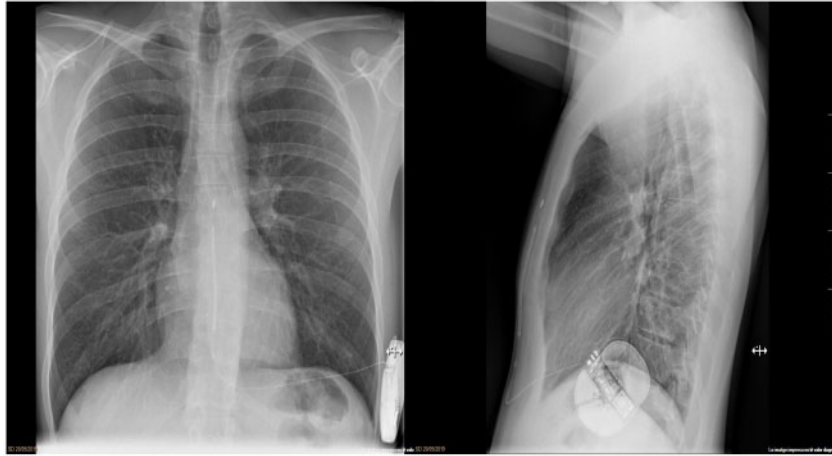


Figure 4 Position of the subcutaneous implantable cardioverter-defibrillator electrode after the three-incision technique.

Table 1 Comparison between S-ICD implant techniques

	Advantages	Disadvantages
Two incisions	<ul style="list-style-type: none"> • Shorter procedure time. • Greater comfort; aesthetically superior. 	<ul style="list-style-type: none"> • Poor distal lead support.
Three incisions	<ul style="list-style-type: none"> • Distal lead support. 	<ul style="list-style-type: none"> • Longer procedure time. • The high sternal wound is associated with superficial infections and discomfort.

In this case, the secondary configuration (tip-electrode-to-can) likely acted as a primary configuration (proximal-electrode-to-can), given that the distal electrode of the lead was placed where the proximal electrode had previously been. The excellent signal obtained in both positions did not produce inappropriate shocks, and the SMARTPass filter remained activated. However, in ventricular arrhythmia, the shock could have been ineffective, given that the coil was in a low position, thus excluding the cardiac structure between it and the can.

Since its initial description, the two-incision technique has been shown to provide technical and aesthetic advantages over the three-incision technique (Table 1)¹¹; however, it has not been shown to reduce the frequency of electrode displacement.² In our case, the three-incision technique was chosen at reintervention to provide greater distal support to the electrode.

In the S-ICD System IDE Clinical Investigation, device interrogations and chest X-rays were performed at hospital discharge and at 30, 90, and 180 days after implantation.¹³ However, in other studies performed in a real-world setting, no information about performing

chest X-rays during follow-up was provided.^{2,4,12,13} Our protocol specifies two X-rays during follow-up (at 4 weeks and again between the 6th and 12th months).

Conclusions

This case highlights the importance of performing at least one chest X-ray during the first weeks after implantation of an S-ICD, allowing detection of a problem such as lead displacement, which can lead to undersensing ventricular arrhythmias or S-ICD oversensing. Real-world, multicentre registries are needed to better explore the causes and best management of S-ICD complications.

Lead author biography



Jose Apolo is a cardiologist and EP fellow of the arrhythmia section of Hospital Clinic-Barcelona, he has worked in training and research programmes at the Álvaro Cunqueiro Hospital-Vigo and Clinico San Carlos Hospital-Madrid, currently, he is focused on the cardiac devices and atrial fibrillation research.

Supplementary material

Supplementary material is available at *European Heart Journal - Case Reports* online.

Slide sets: A fully edited slide set detailing this case and suitable for local presentation is available online as [Supplementary data](#).

Consent: The author/s confirm that written consent for submission and publication of this case report including image(s) and associated text has been obtained from the patient in line with COPE guidance.

Conflict of interest: none declared.

References

1. Priori SG, Blomstrom-Lundqvist C, Mazzanti A, Mazzanti A, Blom N, Borggrefe M, Camm J, Elliott PM, Fitzsimons D, Hatala R, Hindricks G, Kirchhof P, Kjeldsen K, Kuck KH, Hernandez-Madrid A, Nikolaou N, Norekvål TM, Spaulding C, Van Veldhuisen DJ; ESC Scientific Document Group. 2015 ESC Guidelines for the management of patients with ventricular arrhythmias and the prevention of sudden cardiac death: the task force for the management of patients with ventricular arrhythmias and the prevention of sudden cardiac death of the European Society of Cardiology (ESC). Endorsed by: Association for European Paediatric and Congenital Cardiology (AEPC). *Eur Heart J* 2015;**36**:2793–2867.
2. Lambiasi PD, Barr C, Theuns DA, Knops R, Neuzil P, Johansen JB, Hood M, Pedersen S, Käåb S, Murgatroyd F, Reeve HL, Carter N, Boersma L; EFFORTLESS Investigators. Worldwide experience with a totally subcutaneous implantable defibrillator: early results from the EFFORTLESS S-ICD Registry. *Eur Heart J* 2014;**35**:1657–1665.
3. San Antonio R, Guasch E, Chipa-Ccasani F, Apolo J, Pujol-Lopez M, Fernandez H, Trotta O, Niebla M, Borràs R, Trucco E, Arbelo E, Roca-Luque I, Brugada J, Mont L, Tolosana JM. Failure-free survival of the Riata implantable cardioverter-defibrillator lead after a very long-term follow-up. *Indian Pacing Electrophysiol J* 2019;**19**:140–144.
4. Burke MC, Gold MR, Knight BP, Barr CS, Theuns DAMJ, Boersma LVA, Knops RE, Weiss R, Leon AR, Herre JM, Husby M, Stein KM, Lambiasi PD. Safety and efficacy of the Totally Subcutaneous Implantable Defibrillator: 2-year results from a pooled analysis of the IDE Study and EFFORTLESS Registry. *J Am Coll Cardiol* 2015;**65**:1605–1615.
5. Brouwer TF, Miller MA, Quast A-FBE, Palaniswamy C, Dukkupati SR, Reddy V, Wilde AA, Willner JM, Knops RE. Implantation of the subcutaneous implantable cardioverter-defibrillator: an evaluation of 4 implantation techniques. *Circ Arrhythm Electrophysiol* 2017;**10**:e004663.
6. Tachibana M, Nishii N, Banba K, Fujita S, Ikeda E, Okawa K, Morita H, Ito H. SMART pass will prevent inappropriate operation of S-ICD. *J Arrhythmia* 2019;**35**:86–91.
7. Dabiri Abkenari L, Theuns DA, Valk SD, Van Belle Y, de Groot NM, Haitsma D, Muskens-Heemskerk A, Szili-Torok T, Jordaens L. Clinical experience with a novel subcutaneous implantable defibrillator system in a single center. *Clin Res Cardiol* 2011;**100**:737–744.
8. Aydin A, Hartel F, Schlüter M, Butter C, Köbe J, Seifert M, Gosau N, Hoffmann B, Hoffmann M, Vettorazzi E, Wilke I, Wegscheider K, Reichenspurner H, Eckardt L, Steven D, Willems S. Shock efficacy of the subcutaneous ICD for prevention of sudden cardiac death: initial multicenter experience. *Circ Arrhythm Electrophysiol* 2012;**5**:913–919.
9. Kobe J, Reinke F, Meyer C, Shin DI, Martens E, Kaab S, et al. Implantation and follow-up of totally subcutaneous versus conventional implantable cardioverter-defibrillators: a multicenter case-control study. *Heart Rhythm* 2013;**10**:29–36.
10. Sugumar H, Tung MK, Lee AJ, Bashir J, Lane C. Subcutaneous ICD lead position affects defibrillation threshold. *HeartRhythm Case Rep* 2018;**4**:29–30.
11. Knops RE, Olde Nordkamp LR, de Groot JR, Wilde AA. Two-incision technique for implantation of the subcutaneous implantable cardioverter-defibrillator. *Heart Rhythm* 2013;**10**:1240–1243.
12. Weiss R, Knight BP, Gold MR, Leon AR, Herre JM, Hood M, Rashtian M, Kremers M, Crozier I, Lee KL, Smith W, Burke MC. Safety and efficacy of a totally subcutaneous implantable-cardioverter defibrillator. *Circulation* 2013;**128**:944–953.
13. Bettin M, Rath B, Ellermann C, Leitz P, Reinke F, Köbe J, Eckardt L, Frommeyer G. Follow-up of the first patients with a totally subcutaneous ICD in Germany from implantation till battery depletion. *Clin Res Cardiol* 2019;**108**:16–21.