






Article

Early Bowel Lengthening Procedures: Bi-Institutional Experience and Review of the Literature

Elisa Negri ^{1,2,*} , Riccardo Coletta ^{2,3} , Lynette Forsythe ⁴, Francesca Gigola ^{1,2} , Maria Chiara Cianci ^{1,2} 
and Antonino Morabito ^{1,2} 

¹ Department of Neuroscience, Psychology, Drug Research and Child Health (NEUROFARBA), University of Florence, 50121 Florence, Italy; francesca.gigola@unifi.it (F.G.); mariachiara.cianci@unifi.it (M.C.C.); antonino.morabito@unifi.it (A.M.)

² Department of Pediatric Surgery, Meyer Children's Hospital, University of Florence, 50139 Florence, Italy; riccardo.coletta@meyer.it

³ School of Environment and Life Science, University of Salford, Salford M5 4NT, UK

⁴ Royal Manchester Children's Hospital, Manchester University NHS Foundation Trust, Manchester M13 9WL, UK; lynette.forsythe@mft.nhs.uk

* Correspondence: elisa.negri@unifi.it

Abstract: Early bowel lengthening procedure (EBLP) has been defined as any bowel lengthening procedure performed before six months of age. The purpose of this paper is to compare our experience with literature on this subject to identify common indications. A bi-institutional retrospective analysis was performed. Diagnosis, type of surgery, age at procedure and outcomes were analysed. Eleven EBLP were performed in Manchester and Florence from 2006 to 2021. The median age at surgery was 126 days (102–180), pre-operative median short bowel (SB) length was 28 cm (17–49) with a post-operative median increase of 81%. Furthermore, a PubMed/Embase search was undertaken regarding bowel lengthening procedures performed in the last 40 years. Sixty-one EBLP were identified. The median age was 60 days (1–90). Serial transverse enteroplasty (STEP) was the most frequent procedure used, with a median increased bowel length of 57%. This study confirms that no clear consensus on indication or timing to perform early SB lengthening is reported. According to the gathered data, EBLP should be considered only in cases of actual necessity and performed in a qualified intestinal failure centre.

Keywords: early bowel lengthening; short bowel syndrome; autologous intestinal reconstructive surgery



Citation: Negri, E.; Coletta, R.; Forsythe, L.; Gigola, F.; Cianci, M.C.; Morabito, A. Early Bowel Lengthening Procedures: Bi-Institutional Experience and Review of the Literature. *Children* **2022**, *9*, 221. <https://doi.org/10.3390/children9020221>

Academic Editor: Jurgen Schleeff

Received: 23 December 2021

Accepted: 3 February 2022

Published: 7 February 2022

Publisher's Note: MDPI stays neutral with regard to jurisdictional claims in published maps and institutional affiliations.



Copyright: © 2022 by the authors. Licensee MDPI, Basel, Switzerland. This article is an open access article distributed under the terms and conditions of the Creative Commons Attribution (CC BY) license (<https://creativecommons.org/licenses/by/4.0/>).

1. Introduction

Short bowel syndrome (SBS) is a severe multi-systemic disorder resulting from losing a significant amount of small bowel. The incidence of severe SBS is estimated to be 25/100,000 live births; most sufferers are infants and young children [1].

The debate about the correct definition of SBS is still open. Bowel length of less than half expected for gestational age is considered abnormal [2]. According to different authors, generally <40 cm requires therapy [3]. The most frequent causes of SBS are necrotizing enterocolitis (NEC), small intestinal volvulus in intestinal malrotation, gastroschisis and small bowel atresia. In SBS, the residual intestine is inadequate to permit absorption/digestion of nutrients to maintain body weight, transit time is shortened, absorption of nutrients becomes ineffective and malnutrition, dehydration and electrolyte deficiency can develop [4]. In this condition, the bowel adapts, crypts deepen, and villi become hypertrophic through a slow process that usually results in massive dilatation of the bowel. In dilated intestines, muscle constrictions are ineffective and the peristalsis becomes insufficient, and stationary bowel leads to translocation of bacteria and sepsis [5].

The management of SBS has evolved tremendously over the past two decades, improving patients' survival rates. This has mainly been due to surgical techniques and

improvements in total parenteral nutrition (TPN). However, complications of TPN still represent a major challenge to paediatric intestinal rehabilitation teams [6]. Outcomes are influenced by different factors, including the site of the small bowel resected, quality of residual bowel, presence of the ileocecal valve, length of remaining colon and the presence of potential for intestinal continuity. Initial results published by Bianchi showed a survival of approximately 45% [7]. In more recent works, an improved survival rate of 92% has been reported, with 58–96% of TPN weaning [2,8].

Different bowel lengthening techniques have been used in recent years, often causing much controversy with varying results. The type of surgery is case specific and the remaining bowel length and degree of bowel distension are important factors to consider when choosing the best procedure for the patient. In case of un-dilated bowel, there can be a period of 20–24 weeks before performing an AGIR procedure, in which a tube stoma system can be applied to allow bowel expansion. [2,5] Oral nutrition is generally preferred to stimulate the swallowing mechanism and to avoid food aversion during this period [9].

The most frequently chosen autologous gastrointestinal reconstructions (AGIR) are longitudinal intestinal lengthening and tailoring (LILT), proposed by Bianchi in 1980 [10], and serial transverse enteroplasty (STEP), proposed by Kim in 2003 [11]. Both procedures provide a better outcome if intestinal dilatation has occurred. More recently, the spiral intestinal lengthening and tailoring technique (SILT) has been introduced, which allows lengthening of an intestinal segment with a lesser degree of bowel dilatation [12]. Other techniques, such as anti-peristaltic reverse segment or the more recently introduced transverse flap duodenoplasty, can be applied in combination with older techniques [13].

Despite there being no consensus about the correct timing to perform a lengthening procedure, some years ago it was suggested that early surgical intervention took advantage of normal growth and development [6]. Some authors suggested a benefit of earlier adaptation when AGIR surgery is offered during the first 365 days of life [14], while others recommended surgical intervention only after a period of bowel adaptation [15].

Several studies have demonstrated that a multidisciplinary approach to SBS dramatically improves the surgical and medical outcomes of these patients [16,17]. Modern intestinal rehabilitation centres can offer these patients the most updated options to achieve the best possible results such as an unstructured pathway that includes medical, surgical and psychological support [6] tailored to individual patient needs [18,19].

A structured pathway for managing these patients was proposed by the Manchester Children's Hospital team in 2012 [6]. However, the timing of intervention in patients with short bowel syndrome is still debated.

The purpose of this review about early small bowel lengthening (elongation procedures performed before six months of life) is to examine outcomes in combination with our experience.

2. Materials and Methods

Children with short bowel syndrome treated at Royal Manchester Children's Hospital and at Meyer Children's Hospital of Florence between 2006 and 2021 were retrospectively analysed by personal reference and review of medical records.

A comprehensive literature review was conducted in November 2021 in accordance with the 2020 Preferred Reported Items for Systematic reviews and Meta-Analysis (PRISMA) [20]. Two different reviewers independently extracted data, with discrepancies resolved by consensus. A PubMed/Embase search for all the children who underwent bowel lengthening procedures before 6 months of age was performed. Research terms were: short bowel syndrome, intestine, lengthening, neonatal, and children. Reviews and papers not in English were excluded from this investigation. Data were recorded in a Microsoft Excel dataset in chronological order.

We analysed papers' characteristics: type of article, number of cases described, number of early procedures; and patient's characteristics: primary diagnosis, age at procedure, reason for early lengthening, small bowel length before and after surgery, type of procedure,

number of cases in which parenteral nutrition was stopped and its duration, number of deceased patients, and complications after surgery.

Numerical data are presented as median \pm interquartile range. This study was conducted in accordance with the International Conference for Harmonization Good Clinical Practice (ICH-GCP) and with the current revision of the Declaration of Helsinki.

3. Results

From 2006 to 2021, 11 EBLP were performed by the same surgeon at the Royal Manchester Children's Hospital and at Meyer Children's Hospital of Florence (out of a total of lengthening procedures); five were males and six females. Median gestation at birth (weeks) was 34 (32.5–34), and median age at surgery was 126 days (102–180). The primary diagnoses were six gastroschisis, three NEC, one intestinal atresia with volvulus and one multiple atresia.

Indications for early lengthening were re-dilatation following primary anastomosis, failure of enteral nutrition, and allowing for natural SB growth. Survival rate was 90.9%; none of the patients required repeated lengthening. Four reached full enteral autonomy and four partial home parenteral nutrition. The breakdown of the type of lengthening procedures performed at the hospital were: three LILT, three STEP, three SILT, one LILT and STEP, and one STEP and reverse interposition. Pre-operative median SB length was 28 cm (17–49), while post-operative median SB length was 51 cm (25–70), with a median increased bowel length of 81%.

Searching the literature, 100 papers were reviewed to reveal more than 400 lengthening procedures performed over a 40-year period. Twenty-one papers matched our criteria, including 10 single centre studies and 11 case reports. Sixty-one early short bowel lengthening procedures were recorded (Figure 1).

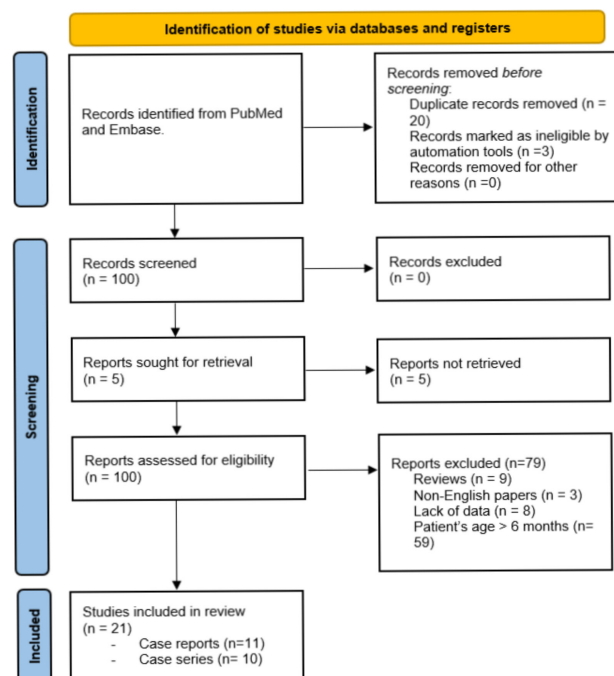


Figure 1. PRISMA flow diagram [20].

The AGIR procedures reported were: STEP (36), LILT (20), anterior flap (4) and duodenal flap (1). The main reason for the early lengthening procedure was excessive dilatation due to SB atresia (22 cases), followed by failure of enteral feeding (3), failure of enteral feeding with Sepsis (1), failure of enteral feeding with bowel dilatation (1), high stool output (5) and a very short bowel (1). In the remaining cases, it was not possible to determine the clinical indication to perform an EBLP from the article (N/A).

Median age at lengthening was 60 days (1–90). Median initial SB length was 40 cm (20–62.5), and median length achieved was 63 cm (47–85), with a median increased bowel length of 57%. Parenteral nutrition was stopped after a median time of 180 days (90–247.5). Fifteen patients (25%) weaned off PN (Table 1).

Table 1. Literature review and personal experience.

	Literature Review	Personal Experience
Age at surgery (days; IQR)	60 (1–90)	126 (102–180)
Pre-operative SB length (cm)	40 (29–62.5)	28 (17–49)
Post-Operative SB length (cm)	63 (49–85)	51 (25–70)
% Increased length	57%	81%
Procedures		
• STEP	35	3
• LILT	20	3
• SILT	0	3
• LILT & STEP	0	1
• STEP & Reverse	0	1
• Anterior Flap	4	0
• Duodenal Flap	1	0

Post operative complications reported were sepsis (19), re-STEP procedure due to excessive dilatation (15), intestinal failure-associated liver disease (IFALD) (3), bowel obstruction (3), enterocutaneous fistulas (2), cholestasis (1), low body weight after procedure (1), anastomosis leakage (1), and transaminase elevation (1). Eight patients underwent intestinal transplantation, while one required liver transplantation. Overall, 25% of patients died due to liver failure (9), unspecified “SBS complications” (2), sepsis with liver failure (1), sepsis (1), heart disease (1) and upper gastrointestinal haemorrhage (1). Papers and patients’ characteristics are summarized in Table 2.

Table 2. Results of literature review. Papers and patients’ characteristics.

N° EBLP	Diagnosis	Indication	Mean Age (days)	Pre-OP SB (cm)	Technique	Post-OP SB (cm)	Stop PN (Time in Days)	N° of Death (Cause)	Complications (n°)
1 [21]	1	Gastroschisis and SBA	FEF	33	28	LILT	56	1 (180)	Anastomotic leakage (1)
2 [22]	1	SBA and MV	Very SB	1	12	LILT	21	1 (UGIH)	
3 [23]	1	SBA	N/A	90	10	LILT	15	1 (Sepsis)	
4 [24]	1	SBA	FEF	90	48	LILT	58	1 (180)	
5 [25]	1	MV	FEF and Dilatation	90	15	LILT	NA	1(900)	
6 [26]	14	SBA, Gastroschisis, MV, NEC	N/A	N/A	N/A	LILT	N/A	1	Sepsis (14) IT (5)
7 [27]	1	Gastroschisis and SBA	Dilatation	1	22	STEP	51	N/A	
8 [28]	4	SBA	N/A	18	90 60 106 150	STEP (4)	67 128 118 198	N/A	Sepsis and LF (2) Heart disease (1) IT (7) Bowel obstruction (2) IT (1)
9 [29]	8	SBA (2), Internal hernia (1) MV(3) Intestinal ischemia (1) Gastroschisis (1)	High stool output	88 (mean)	67 (mean)	STEP	NA	1(60)	2 (SBS complications) Enterocutaneous fistula (1)
10 [16]	1	Gastroschisis and SBA	FEF and septic episodes	150	40	LILT	80	1 (270)	Sepsis and bowel stenosis (1)
11 [30]	1	SBA	Dilatation	60	30	STEP	48		Feeding intolerance, sepsis and re/dilatation (1)

Table 2. *Cont.*

	N° EBLP	Diagnosis	Indication	Mean Age (days)	Pre-OP SB (cm)	Technique	Post-OP SB (cm)	Stop PN (Time in Days)	N° of Death (Cause)	Complications (n°)	
12	[31]	1	Gastroschisis and SBA	FEF	120	42,5	STEP (3 times)	112	1 (>5 years)	Feeding intolerance, bowel obstruction, re-dilatation and IT at 5 years old (1) Grow and Vit D deficiency (1)	
13	[32]	1	SBA	NA	3	15	STEP (2 times)	20	1 (N/A)		
14	[33]	1	SBA		1	35	STEP (2 times)	50	1		
15	[34]	15	Gastroschisis (5) SBA (9) MV(1)	Dilatation	1	32 (mean)	STEP (15) re-STEP)	47 (mean)	3 (N/A)	1 (IFALD)	IFALD (2), ITL(1)
16	[35]	1	SBA	Dilatation	12	N/A	STEP	N/A	N/A		
17	[36]	1	MV	NA	180	35	Duodenal STEP	90	1 (750)		
18	[37]	4	SBA	Dilatation	2	50 55 65 60	Anterior flap	60 63 75 68	4 (< 30 days)		Cholestasis (1)
19	[38]	1	Gastroschisis and SBA	Dilatation	21	90	STEP	100	1 (30)		Enterocutaneous fistula (1)
20	[13]	1	SBA	Dilatation and slow transit	60	9	Duodenal Flap	12			
21	[39]	1	Gastroschisis and SBA	N/A	180	20	STEP	N/A			

EBLP (Early bowel lengthening procedures); FEF (Failure of enteral feeding); SBA (Short bowel atresia); MV (midgut volvulus), LILT (longitudinal intestinal lengthening), STEP (serial transverse enteroplasty); UGIH (Upper gastro intestinal haemorrhage); SB (short bowel); LF (liver failure); IT (intestinal transplantation; IFALD (intestinal failure associated liver disease); ITL (intestinal and liver transplantation).

4. Discussion

Current management of children with short bowel syndrome is known to be a complex, prolonged process where the paediatric surgeon is constantly facing difficult challenges to overcome all the nutritional and social problems related to this condition.

Our data show that the early intestinal lengthening procedures seem to have high rates of post-operative complications and re-intervention, with less-than-optimal rates of intestinal stretch compared to our experience.

Moreover, more patients needed parenteral nutrition than recent analyses, with a similar PN duration [2,18,40–42]. In fact, only fifteen patients (25%) weaned off PN and achieved enteral autonomy. In those patients who weaned off PN, the time to achieve enteral autonomy varied widely (30–900 days), with a duration of PN comparable to that of the same of the studies [2,40].

We have confirmed that LILT and STEP procedures are the most popular surgical techniques used for AGIR, while they may be perceived as technically challenging and they are not the best option in mildly dilated small bowel (2–5 cm). Interestingly, our study confirms that LILT and STEP successfully elongated the bowel up to 100 and 75%, respectively [3].

Initially, LILT procedures were mainly carried out by the Manchester team. The introduction of other techniques such as STEP subsequently allowed a broadening of the therapeutic options and to the possible combination of different surgical procedures. The advent of new techniques such as SILT and duodenal flap will probably contribute to further modifying these percentages and outcomes. Furthermore, we observed that patients who underwent surgery in Manchester/Florence were older and had better outcomes, probably due to both the timing of intervention and to greater team experience in managing these patients.

While some years ago early structured intervention appeared to improve the clinical outcome of infants with SBS by reducing the morbidity and mortality associated with PN [14], our data seems to be in agreement with some authors who recommended surgical intervention only after a period of bowel adaptation, as the natural process may obviate

the need for any other interventions [43]. We know, in fact, that outcomes mostly depend on the ability of the residual gastrointestinal tract to adapt functionally [17].

This literature review revealed that a high rate of re-STEP procedures and sepsis episodes occur in the post-operative period. This can be explained by an excessive rapid bowel dilatation with consequent bacterial overgrowth. This involves a subsequent, second surgery in the post-operative period, with high anaesthesiologic and surgical risks for the newborn child, and does not allow for a gradual bowel adaptation, one of the main goals in SBS patients.

However, our study has some limitations. The literature review was limited by the great variability in the availability of data reported in different articles selected. We could speculate that the elevated number of deaths reported could be reflective of unreported co-morbidities as well as possible lacks of clinical data. Moreover, the study retrospectively compares an historical cohort of patients, with a group of children who underwent surgery in more recent times in specialized centres (Table 1).

5. Conclusions

In conclusion, SBS patients are difficult to treat from the first days of life. While previously there was the belief that we had to intervene aggressively as quickly as possible to allow better intestinal adaptation, our data report a high rate of complications and a difficulty to wean off PN. Previously, the main indication for intervention was the impossibility of feeding these patients enterally, but progress in the production of specific parenteral formulations has made it possible to reduce surgical procedures. Therefore, we believe that early lengthening procedures should be carefully considered and offered only in selected circumstances. We believe that excessive intestinal dilatation associated with severe obstructive symptoms and recurrent episodes of sepsis could be one of these.

A multidisciplinary team (MDT) with gastroenterologists, paediatric surgeons, nutritionists, radiologists, anaesthesiologists and other figures, remains of fundamental importance in improving the management and short- and long-term results of these patients. The MDT approach will clearly help patients' selection and overall outcomes.

Author Contributions: Conceptualization: A.M.; L.F., writing—original draft preparation: E.N.; A.M.; R.C., writing—review and editing: A.M.; E.N.; R.C.; M.C.C.; F.G., supervision: A.M. All authors have read and agreed to the published version of the manuscript.

Funding: This research received no external funding.

Institutional Review Board Statement: Not applicable.

Informed Consent Statement: Informed consent was obtained from caregivers of all subjects involved in the study.

Data Availability Statement: The data that support the findings of this study are available on request from the corresponding author [E.N].

Conflicts of Interest: The authors declare no conflict of interest.

References

1. Mutanen, A. Liver Disease in pediatric Onset Intestinal Failure. PhD Thesis, University of Helsinki, Helsinki, Finland, 2014.
2. Khalil, B.A.; Ba'ath, M.E.; Aziz, A.; Forsythe, L.; Gozzini, S.; Murphy, F.; Carlson, G.; Bianchi, A.; Morabito, A. Intestinal rehabilitation and bowel reconstructive surgery: Improved outcomes in children with short bowel syndrome. *J. Pediatr. Gastroenterol. Nutr.* **2012**, *54*, 505–509. [[CrossRef](#)]
3. Soden, J.S. Clinical assessment of the child with intestinal failure. *Semin. Pediatr. Surg.* **2010**, *19*, 10–19. [[CrossRef](#)]
4. Bianchi, A.; Morabito, A. The dilated bowel: A liability and an asset. *Semin. Pediatr. Surg.* **2009**, *18*, 249–257. [[CrossRef](#)] [[PubMed](#)]
5. Murphy, F.; Khalil, B.A.; Gozzini, S.; King, B.; Bianchi, A.; Morabito, A. Controlled tissue expansion in the initial management of the short bowel state. *World J. Surg.* **2011**, *35*, 1142–1145. [[CrossRef](#)] [[PubMed](#)]
6. Ba'ath, M.E.; Almond, S.; King, B.; Bianchi, A.; Khalil, B.A.; Morabito, A. Short bowel syndrome: A practical pathway leading to successful enteral autonomy. *World J. Surg.* **2012**, *36*, 1044–1048. [[CrossRef](#)] [[PubMed](#)]
7. Bianchi, A. Experience with longitudinal intestinal lengthening and tailoring. *Eur. J. Pediatr. Surg.* **1999**, *9*, 256–259. [[CrossRef](#)] [[PubMed](#)]

8. Pederiva, F.; Sgrò, A.; Coletta, R.; Khalil, B.; Morabito, A. Outcomes in patients with short bowel syndrome after autologous intestinal reconstruction: Does etiology matter? *J. Pediatr. Surg.* **2018**, *53*, 1345–1350. [[CrossRef](#)] [[PubMed](#)]
9. Bianchi, A. From the cradle to enteral autonomy: The role of autologous gastrointestinal reconstruction. *Gastroenterology* **2006**, *130*, 138–146. [[CrossRef](#)] [[PubMed](#)]
10. Bianchi, A. Intestinal loop lengthening—A technique for increasing small intestinal length. *J. Pediatr. Surg.* **1980**, *15*, 145–151. [[CrossRef](#)]
11. Kim, H.B.; Fauza, D.; Garza, J.; Oh, J.T.; Nurko, S.; Jaksic, T. Serial transverse enteroplasty (STEP): A novel bowel lengthening procedure. *J. Pediatr. Surg.* **2003**, *38*, 425–429. [[CrossRef](#)] [[PubMed](#)]
12. Cserni, T.; Takayasu, H.; Muzsnay, Z.; Varga, G.; Murphy, F.; Folaranmi, S.E.; Rakoczy, G. New idea of intestinal lengthening and tailoring. *Pediatr. Surg. Int.* **2011**, *27*, 1009–1013. [[CrossRef](#)]
13. Alberti, D.; Righetti, L.; Bianchi, A.; de'Angelis, G.L.; Boroni, G. Transverse flap duodenoplasty (TFD): A new technique in autologous bowel reconstructive surgery. *Pediatr. Surg. Int.* **2018**, *34*, 567–571. [[CrossRef](#)]
14. Wood, S.J.; Khalil, B.; Fusaro, F.; Folaranmi, S.E.; Sparks, S.A.; Morabito, A. Early structured surgical management plan for neonates with short bowel syndrome may improve outcomes. *World J. Surg.* **2013**, *37*, 1714–1717. [[CrossRef](#)] [[PubMed](#)]
15. Figueroa-Colon, R.; Harris, P.R.; Birdsong, E.; Franklin, F.A.; Georgeson, K.E. Impact of intestinal lengthening on the nutritional outcome for children with short bowel syndrome. *J. Pediatr. Surg.* **1996**, *31*, 912–916. [[CrossRef](#)]
16. Buluggiu, A.; Haddad, M.; Coste, M.; Louis-Borrione, C.; Ughetto, F.; Guys, J.M.; De Lagausie, P. Intestinal loop lengthening: Early treatment of vanishing bowel. *Pediatr. Surg. Int.* **2009**, *25*, 449–450. [[CrossRef](#)] [[PubMed](#)]
17. Massironi, S.; Cavalcoli, F.; Rausa, E.; Invernizzi, P.; Braga, M.; Vecchi, M. Understanding short bowel syndrome: Current status and future perspectives. *Dig. Liver Dis.* **2020**, *52*, 253–261. [[CrossRef](#)]
18. Joly, F.; Mayeur, C.; Messing, B.; Lavergne-Slove, A.; Cazals-Hatem, D.; Noordine, M.L.; Cherbuy, C.; Duée, P.H.; Thomas, M. Morphological adaptation with preserved proliferation/transporter content in the colon of patients with short bowel syndrome. *Am. J. Physiol.-Gastrointest. Liver Physiol.* **2009**, *297*, 116–123. [[CrossRef](#)]
19. Pereira-Fantini, P.M.; Thomas, S.L.; Wilson, G.; Taylor, R.G.; Sourial, M.; Bines, J.E. Short- and long-term effects of small bowel resection: A unique histological study in a piglet model of short bowel syndrome. *Histochem. Cell Biol.* **2011**, *135*, 195–202. [[CrossRef](#)]
20. Page, M.J.; McKenzie, J.E.; Bossuyt, P.M.; Boutron, I.; Hoffmann, T.C.; Mulrow, C.D.; Shamseer, L.; Tetzlaff, J.M.; Akl, E.A.; Brennan, S.E.; et al. The PRISMA 2020 statement: An updated guideline for reporting systematic reviews. *BMJ* **2021**, *372*, 71. [[CrossRef](#)]
21. Aigrain, Y.; Cornet, D.; Cezard, J.P.; Boureau, M. Longitudinal Division of Small Intestine: A Surgical Possibility for Children with the Very Short Bowel Syndrome. *Eur. J. Pediatr. Surg.* **1985**, *40*, 233–236. [[CrossRef](#)]
22. Kosloske, A.M.; Jewell, P.F. A technique for preservation of the ileocecal valve in the neonatal short intestine. *J. Pediatr. Surg.* **1989**, *24*, 369–370. [[CrossRef](#)]
23. Thompson, J.S.; Pinch, L.W.; Murray, N.; Vanderhoof, J.A.; Schultz, L.R. Experience with intestinal lengthening for the short-bowel syndrome. *J. Pediatr. Surg.* **1991**, *26*, 721–724. [[CrossRef](#)]
24. Weber, T.R.; Powell, M.A. Early improvement in intestinal function after isoperistaltic bowel lengthening. *J. Pediatr. Surg.* **1996**, *31*, 61–64. [[CrossRef](#)]
25. Katz, S.; Erez, I.; Litmanovitz, I.; Lazar, L.; Raz, A.; Dolfin, Z. Bowel-lengthening in a newborn with short bowel syndrome. *Harefuah* **1998**, *135*, 578–580, 655, 656. [[PubMed](#)]
26. Bueno, J.; Guiterrez, J.; Mazariegos, G.V.; Abu-Elmagd, K.; Madariaga, J.; Ohwada, S.; Kocoshis, S.; Reyes, J. Analysis of patients with longitudinal intestinal lengthening procedure referred for intestinal transplantation. *J. Pediatr. Surg.* **2001**, *36*, 178–183. [[CrossRef](#)]
27. Javid, P.J.; Heung, B.K.; Duggan, C.P.; Jaksic, T. Serial transverse enteroplasty is associated with successful short-term outcomes in infants with short bowel syndrome. *J. Pediatr. Surg.* **2005**, *40*, 1019–1024. [[CrossRef](#)]
28. Wales, P.W.; de Silva, N.; Langer, J.C.; Fecteau, A. Intermediate outcomes after serial transverse enteroplasty in children with short bowel syndrome. *J. Pediatr. Surg.* **2007**, *42*, 1804–1810. [[CrossRef](#)]
29. Diamond, I.R.; Wales, P.W. Advantages of the distal sigmoid colostomy in the management of infants with short bowel syndrome. *J. Pediatr. Surg.* **2008**, *43*, 1464–1467. [[CrossRef](#)]
30. Fusaro, F.; Hermans, D.; Wanty, C.; Veyckemans, F.; Pirenne, J.; Reding, R. Post-serial transverse enteroplasty bowel redilatation treated by longitudinal intestinal lengthening and tailoring procedure. *J. Pediatr. Surg.* **2012**, *47*, e19–e22. [[CrossRef](#)]
31. Lourenço, L.; Campos, M.; Monteiro, J.; Trindade, E.; Dias, J.A.; Guerra, A.; Guerra, P.; Correia-Pinto, J.; Estevão-Costa, J. Serial transverse enteroplasty (STEP): Intermediate outcomes in children with short bowel syndrome. *Eur. J. Pediatr.* **2012**, *171*, 1265–1268. [[CrossRef](#)]
32. Oh, J.T.; Koh, H.; Chang, E.Y.; Chang, H.K.; Han, S.J. Second serial transverse enteroplasty procedure in an infant with extreme short bowel syndrome. *J. Korean Med. Sci.* **2012**, *27*, 701–703. [[CrossRef](#)] [[PubMed](#)]
33. Bhalla, V.K.; Pipkin, W.L.; Hatley, R.M.; Howell, C.G. The use of multiple serial transverse enteroplasty (STEP) procedures for the management of intestinal atresia and short bowel syndrome. *Am. Surg.* **2013**, *79*, 826–828. [[CrossRef](#)] [[PubMed](#)]
34. Garnett, G.M.; Kang, K.H.; Jaksic, T.; Woo, R.K.; Puapong, D.P.; Kim, H.B.; Johnson, S.M. First STEPs: Serial transverse enteroplasty as a primary procedure in neonates with congenital short bowel. *J. Pediatr. Surg.* **2014**, *49*, 104–108. [[CrossRef](#)]

35. Oh, P.S.; Fingeret, A.L.; Shah, M.Y.; Ventura, K.A.; Brodlie, S.; Ovchinsky, N.; Martinez, M.; Lobritto, S.J.; Cowles, R.A. Improved tolerance for enteral nutrition after serial transverse enteroplasty (STEP) in infants and children with short bowel syndrome—A seven-year single-center experience. *J. Pediatr. Surg.* **2014**, *49*, 1589–1592. [[CrossRef](#)]
36. Bueno, J.; Redecillas, S.; García, L.; Lara, A.; Giné, C.; Molino, J.A.; Broto, J.; Segarra, O. Duodenal lengthening in short bowel with dilated duodenum. *J. Pediatr. Surg.* **2015**, *50*, 493–496. [[CrossRef](#)] [[PubMed](#)]
37. Li, B.; Xia, S.L.; Chen, W.B.; Wang, S.Q.; Wang, Y. bo Laparoscope-assisted intestinal lengthening using an anterior flap in jejunal atresia. *Pediatr. Surg. Int.* **2015**, *31*, 1183–1187. [[CrossRef](#)]
38. Lobos, P.A.; Calello, S.E.M.; Busoni, V.B.; Urquizo Lino, M.M.; Prodan, S.G.; Sanchez Claria, R. Neonatal Serial Transverse Enteroplasty (STEP): Case Report. *Transplant. Proc.* **2016**, *48*, 528–531. [[CrossRef](#)]
39. Hong, J.; Yun, S.O.; Lee, S.; Kim, H.-J.; Park, H.J.; Seo, J.-M. Early Experience with Serial Transverse Enteroplasty in a Korean Intestinal Rehabilitation Team. *Surg. Metab. Nutr.* **2018**, *9*, 11–15. [[CrossRef](#)]
40. Amiot, A.; Messing, B.; Corcos, O.; Panis, Y.; Joly, F. Determinants of home parenteral nutrition dependence and survival of 268 patients with non-malignant short bowel syndrome. *Clin. Nutr.* **2013**, *32*, 368–374. [[CrossRef](#)]
41. Pironi, L.; Sasdelli, A.S. Intestinal Failure-Associated Liver Disease. *Clin. Liver Dis.* **2019**, *23*, 279–291. [[CrossRef](#)]
42. Yannam, G.R.; Sudan, D.L.; Grant, W.; Botha, J.; Langnas, A.; Thompson, J.S. Intestinal Lengthening in Adult Patients with Short Bowel Syndrome. *J. Gastrointest. Surg.* **2010**, *14*, 1931–1936. [[CrossRef](#)] [[PubMed](#)]
43. Garritano, S.; Irino, T.; Scandavini, C.M.; Tsekrekos, A.; Lundell, L.; Rouvelas, I. Long-term functional outcomes after replacement of the esophagus in pediatric patients: A systematic literature review. *J. Pediatr. Surg.* **2017**, *52*, 1398–1408. [[CrossRef](#)] [[PubMed](#)]