



ELSEVIER

Contents lists available at [ScienceDirect](https://www.sciencedirect.com)

Trauma Case Reports

journal homepage: www.elsevier.com/locate/tcr

Life-threatening traumatic epistaxis due to massive bleeding into the maxillary sinus

Rika Kotoh^a, Takaaki Maruhashi^{a,*}, Satoshi Tamura^a, Daisuke Yamamoto^b, Hiroyuki Koizumi^b, Yutaro Kurihara^a, Mayuko Osada^a, Marina Oi^a, Yasushi Asari^a

^a Department of Emergency and Critical Care Medicine, Kitasato University School of Medicine, Sagami-hara, Kanagawa, Japan

^b Department of Neurosurgery, Kitasato University School of Medicine, Sagami-hara, Kanagawa, Japan

ARTICLE INFO

Keywords:

Traumatic epistaxis
Hemorrhagic shock
Transcatheter arterial embolization
Maxillary sinus

ABSTRACT

A 77-year-old woman with no medical history fell, and her face was strongly impacted on the ground. On arrival at our hospital, her initial vital signs were stable. She underwent an endoscopy to stop the bleeding. However, identification of the origin of the bleeding failed, and her injury resulted in hemorrhagic shock during the procedure. Head to face contrast computed tomography showed extravasation of contrast media into the maxillary sinus. Transcatheter arterial embolization was performed for the ruptured infraorbital artery branching from the maxillary artery. She recovered from the “shock” state after transcatheter arterial embolization and was admitted to the intensive care unit. There were no complications associated with transcatheter arterial embolization during hospitalization. For this case, early recognition of an active hemorrhage was challenging because the hemorrhage was pooled in the sinuses. Although epistaxis is sometimes fatal, transcatheter arterial embolization can be the first choice for the treatment of life-threatening epistaxis, owing to its safety and effectiveness.

Introduction

Most episodes of epistaxis heal spontaneously. Nevertheless, despite this situation requiring intervention in some cases, hemostasis can be achieved by simple procedures such as compression of the nasal root or cauterization with nasal endoscopy. However, these initial treatments do not stop the bleeding in approximately 10% of cases, and some cases are intractable, requiring more invasive treatments such as endovascular therapy [1].

The same is true for epistaxis complicated with blunt facial trauma. The mortality rate for traumatic epistaxis is low, ranging from 1.2–2.3% [2,3]. The cause of traumatic epistaxis is often upper airway obstruction, and hemorrhagic shock is rare [4,5]. We report on a patient with traumatic epistaxis who was treated using transcatheter arterial embolization (TAE); her injury resulted in shock due to massive sinus bleeding unrecognizable from the body surface.

* Corresponding author at: Department of Emergency and Critical Care Medicine, Kitasato University School of Medicine, 1-15-1 Kitasato, Minami-ku, Sagami-hara, Kanagawa 252-0375, Japan.

E-mail address: tmaruhashi119@gmail.com (T. Maruhashi).

<https://doi.org/10.1016/j.tcr.2021.100434>

Accepted 12 February 2021

Available online 18 February 2021

2352-6440/© 2021 The Author(s). Published by Elsevier Ltd. This is an open access article under the CC BY-NC-ND license

(<http://creativecommons.org/licenses/by-nc-nd/4.0/>).

Case presentation

A 77-year-old woman with no history of illness fell and hit her face hard. She was transported to our hospital 3 h after the injury because of the resulting epistaxis. Consciousness on initial examination corresponded with a Glasgow Coma Scale score of 15 points. Her vital signs were as follows: respiratory rate, 18 breaths/min; blood oxygen saturation of 100%, 10 L/min oxygen; blood pressure, 154/76 mmHg; and heart rate, 118 beats/min. Epistaxis and facial swelling were noted, and epistaxis was hemostatic. Focus assessment with sonography results were negative, and chest and pelvic radiographs revealed no abnormal findings. The blood test data at the time of initial presentation are shown in Table 1. Her hemoglobin was 11.1 g/dL and fibrinogen was 197 mg/dL, which was mildly decreased. Contrast computed tomography revealed a right orbital fundus fracture, a right maxillary fracture, and extravasation in the maxillary sinus (Fig. 1). An otolaryngologist consulted the patient. Endoscopically, in the nasal cavity, only slight blood oozing from the spontaneous orifice was observed with no active bleeding. Gauze packing in the nasal cavity caused bradycardia shock. It was

Table 1
Laboratory data on arrival.

Complete blood count		
WBC	15,700	/ μ L
Neu	83.3	%
Lym	12.5	%
RBC	361	$\times 10^4$ / μ L
Hb	11.1	g/dL
Ht	33.7	%
Plt	17.1	$\times 10^4$ / μ L
Arterial blood gas (10 L/min oxygenation)		
pH	7.422	
pO ₂	198.2	mmHg
pCO ₂	36.6	mmHg
HCO ₃ ⁻	23.3	mmol/L
BE	-0.9	mmol/L
Lac	15.1	mg/dL
Chemistry		
TP	6.1	g/dL
Alb	3.7	g/dL
BUN	13.6	mg/dL
Cr	0.75	mg/dL
Na	136	mmol/L
K	3.5	mmol/L
Cl	102	mmol/L
Ca	9.1	mg/dL
AST	22	U/L
ALT	11	U/L
LDH	226	U/L
ALP	46	U/L
T-Bil	0.4	mg/dL
CPK	122	U/L
CRP	<0.03	mg/dL
Coagulation		
APTT	20.9	Seconds
PT-%	99	%
PT-INR	1	
FIB	197	mg/dL
FDP	214.4	μ g/mL
D-dimer	120.4	μ g/mL

Alb albumin, ALP alkaline phosphatase, ALT alanine aminotransferase, APTT activated partial thromboplastin time, AST aspartate aminotransferase, BE base excess, BUN blood urea nitrogen, Ca calcium, Cl chlorine, CPK creatine phosphokinase, Cr creatinine, CRP C-reactive protein, FDP fibrin degradation product, Fib fibrinogen, Hb hemoglobin, HCO₃ bicarbonate, Ht hematocrit, K potassium, Lac lactate, LDH lactate dehydrogenase, Lym lymphocyte, Na sodium, Neu neutrophil, PCO₂ partial pressure of carbon dioxide, Plt platelets, PO₂ partial pressure of oxygen, PT prothrombin time, RBC red blood cells, T-Bil total bilirubin, TP total protein, WBC white blood cells.

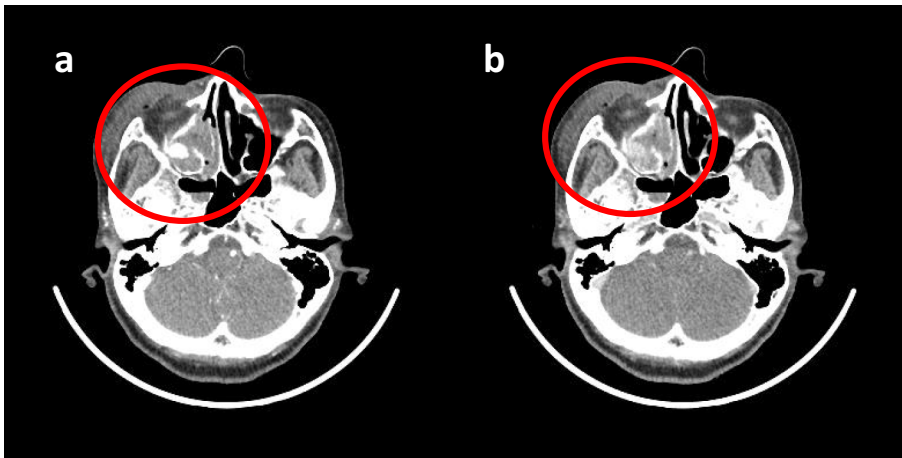


Fig. 1. Contrast computed tomography at initial arrival (a: Arterial phase, b: Delayed phase). A right orbital fundus fracture, a right maxillary fracture, and extravasation detected (circle).

concluded that nasal hemostasis would be difficult to achieve, and endovascular treatment was selected. When she was intubated, she developed epistaxis from the nasal cavity, resulting in hemorrhagic shock. Endovascular treatment was immediately started, and right external carotid artery angiography revealed extravasation on the distal side of the right infraorbital artery. A microcatheter was advanced to the same site and embolized with 30% n-butyl-2-cyanoacrylate (Fig. 2). The endovascular treatment was completed after confirming that the blood flow to the distal side of the embolization site was secured from the collateral channels; she was admitted to the intensive care unit. Re-bleeding did not occur, and no complications associated with TAE were observed. The patient was extubated on the second day and discharged from the intensive care unit on day 12 of hospitalization.

Discussion

Life-threatening traumatic epistaxis is approximately four times more likely to occur in LeFort type II and III and has been reported to be more common in high-energy trauma complicated with head trauma, cervical vertebral fracture, and other trunk trauma [3]. In this case, however, the patient had a low-energy trauma and a low-grade fracture. Owing to the arterial damage associated with the fracture and the presence of a bleeding point in the maxillary sinus, the patient may have had active bleeding that was less likely to manifest as external bleeding, resulting in hemorrhagic shock with a time lag. Hayashi et al. reported a pseudoaneurysm in the suborbital artery due to a fracture similar to the one in the present case, and the fracture of the same area may lead to fatal epistaxis even if the injury occurs via low energy mechanisms [6].

In intractable epistaxis associated with facial trauma, pressure with gauze or balloon catheter insertion into the nasal cavity is the first choice [1]. However, facial trauma is often associated with skull fractures and spinal fluid leakage, and these procedures carry risks in terms of infection. In some cases, hemostasis can be expected with reduction of the fractures; however, in this case, the

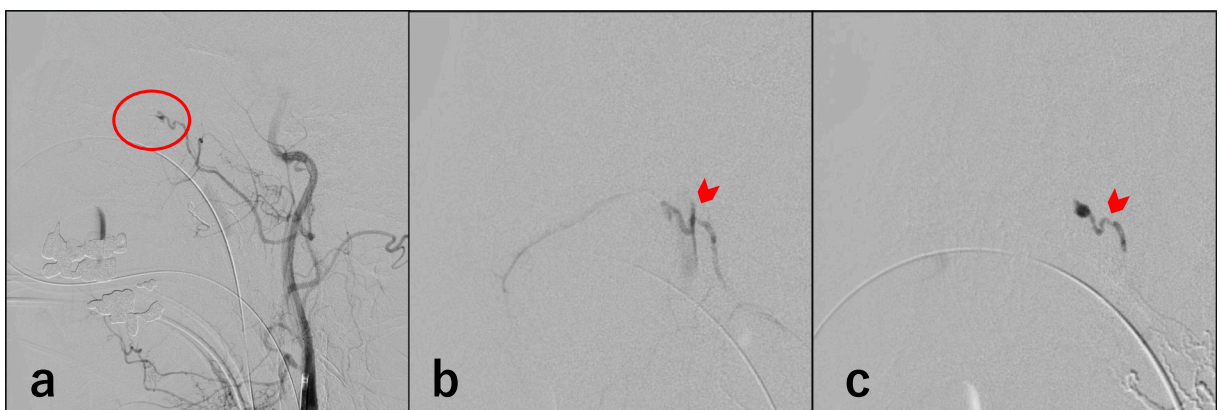


Fig. 2. Transcatheter arterial embolization for life-threatening epistaxis. a: Right external carotid artery angiography reveals extravasation on the distal side of the right infra-orbital artery (circle). b,c: Right maxillary artery angiography and the same contrast media extravasation shown with a microcatheter (arrowhead) and embolized with 30% n-butyl-2-cyanoacrylate (c: arrow).

hemostatic effect of remodeling was small because of few dislocation fractures [7,8]. Moreover, it was difficult to pack because of bradycardia shock occurring during the procedure. The posterior portion of the fracture in the present case is the pterygopalatine ganglion, which may have caused the trigeminal and vagal reflexes [9].

Although the rationale for selecting these treatments depends on the facilities, endovascular treatment is often selected when possible. The reasons for this are (1) endovascular treatment is superior in identifying the bleeding point and selecting the blood vessel; (2) the collateral blood flow path is well developed because the vascular innervation of the face is controlled by two circulatory systems, the external and internal carotid systems; and (3) general anesthesia is not necessarily required, and the procedure can be completed in a short time [7]. Complications of endovascular treatment for epistaxis and facial trauma include facial pain, facial paralysis, skin necrosis, palatal ulcer, diplopia, and cerebral infarction, regardless of the site of bleeding. However, the incidence of irreversible serious complications is low, ranging from <2% to 17% of all complications. Conversely, the success rate of the procedure is high, with observed rates of 87–93% [1,3,4]. TAE is the first choice because of its low complication rate and high procedural success rate.

Conclusions

Even mild facial trauma with low-grade bone fracture and displacement can be fatal if bleeding occurs in the sinuses (not into the nasal side) owing to the arterial injury from the fracture, which delays the recognition of active bleeding. TAE is the first choice because of its invasiveness, high success rate, and low complication rate.

Informed consent

Written informed consent for this case report was obtained from the patient.

Declaration of competing interest

None.

Acknowledgment

The authors would like to thank Editage (<https://www.editage.jp/>) for the English language review.

References

- [1] P. Huyett, B.T. Jankowitz, E.W. Wang, et al., Endovascular embolization in the treatment of epistaxis, *Otolaryngol Head Neck Surg* 160 (2019) 822–828.
- [2] S. Khanna, A.B. Dagum, A critical review of the literature and an evidence-based approach for life-threatening hemorrhage in maxillofacial surgery, *Ann. Plast. Surg.* 69 (2012) 474–478.
- [3] R.P. Bynoe, A.J. Kerwin, H.H. Parker 3rd, et al., Maxillofacial injuries and life-threatening hemorrhage: treatment with transcatheter arterial embolization, *J. Trauma* 55 (2003) 74–79.
- [4] P.W.A. Willems, R.I. Farb, R. Agid, Endovascular treatment of epistaxis, *Am. J. Neuroradiol.* 30 (2009) 1637–1645.
- [5] M.H. Kim, J.H. Yoo, S.S. Kim, W.S. Yang, Massive hemorrhage facial fracture patient treated by embolization, *Arch Craniofac Surg* 17 (2016) 28–30.
- [6] C.M. Pham, S.M. Couch, Oculocardiac reflex elicited by orbital floor fracture and inferior globe displacement, *Am J Ophthalmol Case Rep* 6 (2017) 4–6.
- [7] W.G. Yang, T.R. Tsai, C.C. Hung, T.C. Tung, Life-threatening bleeding in a facial fracture, *Ann. Plast. Surg.* 46 (2001) 159–162.
- [8] K. Ho, J.J. Hutter, J. Eskridge, et al., The management of life-threatening haemorrhage following blunt facial trauma, *J. Plast. Reconstr. Aesthet. Surg.* 59 (2006) 1257–1262.
- [9] H. Kentaro, M. Yoshitaka, H. Yukishige, et al., Traumatic pseudoaneurysm in maxillary sinus presenting intractable epistaxis: a case report of transarterial embolization, *JNET* 11 (2017) 76–80.