





OPEN ACCESS

Case report

Piperacillin–tazobactam induced bicytopenia in low cumulative treatment doses

Chien-Chou Chen ,¹ Hsin-An Lin,² Yi-Jen Hung,³ Jui-Hung Chen ¹

¹Internal Medicine, Tri-Service General Hospital Songshan Branch, Taipei, Taiwan

²Division of Infection Disease, Tri-Service General Hospital Songshan Branch, Taipei, Taiwan

³Department of Internal Medicine, National Defense Medical Center, Taipei, Taiwan

Correspondence to

Dr Chien-Chou Chen;
jffchentw@yahoo.com.tw

Accepted 10 December 2019

SUMMARY

We present the case of infected wet gangrene of right foot in the setting of poorly controlled type 2 diabetes in a 71-year-old woman. This patient presented with improved infection condition after intravenous piperacillin–tazobactam (PTZ) 2.25 gm every 6 hours treatment and below knee amputation surgery on day 3. However, neutropenia and thrombocytopenia developed on day 13. We consulted a haematologist and performed a series of examinations. However, no significant findings were noted thereafter. PTZ was suspected to be the most likely cause of neutropenia and thrombocytopenia and was hence terminated on day 14 (cumulative dose of PTZ: 126 g) following stabilisation of the infection condition. A transfusion was performed with two units of single donor platelets on day 14 and treated with intravenous dexamethasone 5 mg every 8 hours from day 14 to 16. Her white blood cell and platelet counts increased on day 15 and continued to recover thereafter.

BACKGROUND

Piperacillin–tazobactam (PTZ) is one of the most widely used antibiotics for polymicrobial infections, especially in critically ill patients. It is well tolerated. Rare but severe haematological toxicity including neutropenia, haemolytic anaemia and thrombocytopenia have been found in the relevant literature.¹ The mechanisms of PTZ-induced neutropenia and thrombocytopenia are not clearly understood, but theories demonstrated that these could be immune-mediated or a consequence of direct toxicity to myeloid precursors.²

CASE PRESENTATION

A 71-year-old woman presented with infected wet gangrene of the right foot in the setting of poorly controlled type 2 diabetes. Hypertension and hyperlipidemia were significantly present in her medical history. The patient had never received any form of heparin products in recent 6 months, including heparin lock flush over venous catheter.

No history of other adverse drug reaction or haematological problems was found. The patient was started on intravenous PTZ 2.25 gm every 6 hours for infection control after admission. Her other medication regimen had otherwise remained unchanged except in the case of premix insulin, which was changed to a basal bolus regimen. Due to sustained fever and a deteriorated infection range following PTZ therapy, we consulted a plastic

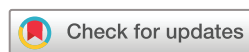surgeon, and amputation below the right knee was performed on day 3. Fever, leukocytosis and high C-reactive protein (CRP) levels improved and no systemic inflammatory response syndrome was observed following the operation. However, petechiae nearby the operation wound was found on day 10.

INVESTIGATIONS

Laboratory findings on admission disclosed the following: white blood cell (WBC): 31 660/μL with neutrophil 29 760/μL, haemoglobin (Hb): 9.6 g/dL, platelet: 408 × 10³/μL, CRP: 25.71 mg/dL, alanine aminotransferase: 26 U/L and creatinine: 1.6 mg/dL with estimated glomerular filtration rate (eGFR) 33.7 mL/min. However, laboratory analysis on day 13 disclosed reduced WBC: 3420/μL with neutrophil 2462/μL, Hb: 10.4 g/dL and platelet: 48 × 10³/μL. Furthermore, the WBC and platelet nadirs of 1330/μL (neutrophil: 190/μL; lymphocyte: 820/μL) and 5 × 10³/μL, respectively, with Hb of 10.0 g/dL were observed on day 14. We had also checked abdomen sonography on day 14 for spleen size evaluation, while peripheral smear exam, infectious, nutritious and autoimmune related workup were also examined meanwhile.

DIFFERENTIAL DIAGNOSIS

The differential diagnosis of the neutropenia and thrombocytopenia included declined marrow function, destruction or consumption, disseminated intravascular coagulation (DIC), autoimmune-induced cytopenias, primary haematological malignancy, heparin-induced thrombocytopenia,



© BMJ Publishing Group Limited 2019. Re-use permitted under CC BY-NC. No commercial re-use. See rights and permissions. Published by BMJ.

To cite: Chen C-C, Lin H-A, Hung Y-J, et al. *BMJ Case Rep* 2019;**12**:e232944. doi:10.1136/bcr-2019-232944

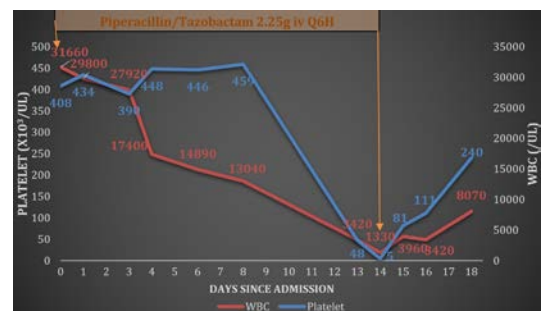


Figure 1 Patient's time course for neutropenia and thrombocytopenia with exposure to piperacillin–tazobactam therapy.

infection, nutrition deficiency, drug related adverse effect or a sequestration effect.

The size of the spleen was deemed to be normal on abdominal sonography. D-dimer, fibrinogen and other coagulation studies did not suggest DIC. Autoimmune factors such as antinuclear antibody and rheumatoid factor showed negative result. No significant abnormality was found through peripheral smear exam. Heparin-induced thrombocytopenia was excluded by absent history of heparin usage. No further systemic inflammatory response syndrome relapsed when bicytopenia developed. Normal serum albumin level also suggested well nutrition status. After reviewing the patient's prescription and other potential causes of bicytopenia, PTZ was regarded as the most likely culprit. Probable drug-induced thrombocytopenia was therefore considered according to the clinical criteria.³

TREATMENT

PTZ was suspected to be the most likely cause of neutropenia and thrombocytopenia and was hence terminated on day 14 (cumulative dose of PTZ: 126 g) following stabilisation of the infection condition. A transfusion was performed with two units of single donor platelets on day 14 and treated with intravenous dexamethasone 5 mg every 8 hours from day 14 to 16. Her WBC and platelet counts increased to 3960/ μ L and 81×10^3 / μ L, respectively, on day 15 and continued to recover thereafter (figure 1). Given the timing and changing of WBC and platelet counts, we considered both neutropenia and thrombocytopenia as side effects of PTZ treatment.

OUTCOME AND FOLLOW-UP

Due to improved bicytopenia and infection condition, the patient was discharged 1 week after termination of PTZ treatment.

DISCUSSION

In our case, neutropenia and thrombocytopenia improved immediately after PTZ termination, and we believed the findings to probably be PTZ-related. However, definite diagnosis requires re-exposure to PTZ following recurrent cytopenia, but this is unfeasible due to medical ethical considerations. To date, the exact incidence of PTZ-induced haematological adverse effects varied between cohort studies due to the difficulty of definite diagnosis in clinical practice. Studies have merely indicated the risk factors for PTZ-induced haematological adverse effects as prolonged courses and increased cumulative doses.^{4,5}

According to the relevant literature, the cumulative dose of PTZ and its induced neutropenia varies between 204 and 612 g, and its minimum treatment course is 18 days.⁴ Systematic review revealed that the discovery of neutropenia associated with PTZ usage prior to 15 days of therapy is rare.⁶ We reported a case of PTZ-induced neutropenia and thrombocytopenia in relatively low cumulative doses (126 g) and shorter treatment duration (day 13). The possibility that PTZ may cause myelosuppression even for shorter treatment durations and lower cumulative doses must be considered.

Patient's perspective

I felt nervous about the petechiae of operation wound developed on day 10. Physicians explained the risk of spontaneous bleeding to me. But they are not really sure about the reason of my decreased platelet count initially. Fortunately my platelet counts and white blood cell counts recovered after discontinuing antibiotics. And no major bleeding was observed during my hospitalisation.

Learning points

- ▶ Neutropenia and thrombocytopenia are rare but severe adverse effects induced by piperacillin-tazobactam (PTZ).
- ▶ Studies have indicated the risk factors for PTZ-induced haematological adverse effects as prolonged courses and increased cumulative doses.
- ▶ PTZ-induced bicytopenia may occur even for treatments of relatively short durations and low cumulative doses. Therefore, monitoring haematological parameters in patients receiving this treatment is crucial.

Contributors Report was written by C-CC, supervised by J-HC. Patient was under the care of J-HC and C-CC and infection specialist H-AL had been consulted for antibiotic treatment. Y-JH had been consulted for the differential diagnosis of bicytopenia and glycaemic control.

Funding The authors have not declared a specific grant for this research from any funding agency in the public, commercial or not-for-profit sectors.

Competing interests None declared.

Patient consent for publication Obtained.

Provenance and peer review Not commissioned; externally peer reviewed.

Open access This is an open access article distributed in accordance with the Creative Commons Attribution Non Commercial (CC BY-NC 4.0) license, which permits others to distribute, remix, adapt, build upon this work non-commercially, and license their derivative works on different terms, provided the original work is properly cited and the use is non-commercial. See: <http://creativecommons.org/licenses/by-nc/4.0/>.

ORCID iDs

Chien-Chou Chen <http://orcid.org/0000-0001-5167-2630>

Jui-Hung Chen <http://orcid.org/0000-0002-4563-3261>

REFERENCES

- 1 Perry CM, Markham A. Piperacillin/tazobactam: an updated review of its use in the treatment of bacterial infections. *Drugs* 1999;57:805–43.
- 2 Neftel KA, Hauser SP, Müller MR. Inhibition of granulopoiesis in vivo and in vitro by beta-lactam antibiotics. *J Infect Dis* 1985;152:90–8.
- 3 George JN, Aster RH. Drug-Induced thrombocytopenia: pathogenesis, evaluation, and management. *Hematology Am Soc Hematol Educ Program* 2009:153–8.
- 4 Peralta FG, Sánchez MB, Roiz MP, et al. Incidence of neutropenia during treatment of bone-related infections with piperacillin-tazobactam. *Clin Infect Dis* 2003;37:1568–72.
- 5 Benli A, Şimşek-Yavuz S, Başaran S, et al. Hematologic adverse effects of prolonged piperacillin-tazobactam use in adults. *Turk J Haematol* 2018;35:290–5.
- 6 Scheetz MH, McKoy JM, Parada JP, et al. Systematic review of piperacillin-induced neutropenia. *Drug Saf* 2007;30:295–306.

Copyright 2019 BMJ Publishing Group. All rights reserved. For permission to reuse any of this content visit <https://www.bmj.com/company/products-services/rights-and-licensing/permissions/>
BMJ Case Report Fellows may re-use this article for personal use and teaching without any further permission.

Become a Fellow of BMJ Case Reports today and you can:

- ▶ Submit as many cases as you like
- ▶ Enjoy fast sympathetic peer review and rapid publication of accepted articles
- ▶ Access all the published articles
- ▶ Re-use any of the published material for personal use and teaching without further permission

Customer Service

If you have any further queries about your subscription, please contact our customer services team on +44 (0) 207111 1105 or via email at support@bmj.com.

Visit casereports.bmj.com for more articles like this and to become a Fellow