

Endoscopic Ultrasound-Guided Angiotherapy for Gastric Varices: A Single Center Experience

Tawfik Khoury,^{1*} Muhammad Massarwa,^{1*} Saleh Daher, Ariel A. Benson, Wadi Hazou, Eran Israeli, Harold Jacob, Julia Epstein, and Rifaat Safadi

There are limited efficacious therapeutic options for management of gastric variceal bleeding. Treatment modalities include transjugular intrahepatic portosystemic shunt, surgical shunts, and endoscopic interventions, including the recent advancement of endoscopic ultrasound (EUS)-guided coiling. We present a case series of 10 patients with portal hypertension (7 with liver cirrhosis and 3 without cirrhosis), complicated by gastric varices (GV) with bleeding. All cases were treated successfully with EUS-guided coiling leading to variceal eradication. There were 10 occurrences of minimal self-limited bleeding at the puncture site during the procedure, and only one occurrence of major bleeding that necessitated cyanoacrylate glue injection for homeostasis. There were no other adverse events within a mean follow-up time of 9.7 months (range, 1-28 months). *Conclusion:* In our series, EUS-guided angiotherapy was effective for GV eradication with a high safety profile. (*Hepatology Communications* 2019;3:207-212).

There is a substantial need for improved treatment of gastric varices (GV), which can develop in up to 15% of patients with cirrhosis with portal hypertension and as many as 20% of patients with noncirrhotic portal hypertension.⁽¹⁾ Furthermore, compared to esophageal variceal bleeding, gastric variceal bleeding is often more severe and there is a significant risk of rebleeding even after intervention.⁽²⁻⁴⁾ Sarin's classification categorizes GV according to location and can be used to help guide treatment. Gastroesophageal varices (GOV) 1 and 2 involve the esophagus and the stomach and arise from the left gastric vein, with GOV-1 arising from the lesser curvature and connecting with esophageal varices. GOV-2 are in the gastric fundus and extend toward the esophagus as esophageal varices. Isolated

GV-1 (IGV-1) are only in the fundus, and IGV-2 are in the gastric body or antrum.

While some treatment options are available for GV, there is no consensus regarding the decision to perform primary prophylactic treatment of high-risk stigmata lesions or secondary treatment after bleeding. Cyanoacrylate (CYA) glue injection is one potential GV treatment option and has a technical success rate of approximately 90%^(5,6) but has been associated with systemic embolization and sepsis.^(7,8) CYA also exposes endoscopic instrumental channels to an occlusion risk. Other endoscopic options for treatment of bleeding GV include endoscopic band ligation and endoscopic-guided ethanol injection, but both have shown lower efficacy and a higher complication rate.⁽⁹⁾ Finally, transjugular intrahepatic

Abbreviations: CYA, cyanoacrylate; EUS, endoscopic ultrasound; GOV, gastroesophageal varices; GV, gastric varices; IGV, isolated gastric varices; INR, international normalized ratio.

Received April 6, 2018; accepted November 3, 2018.

*These authors contributed equally to this work.

© 2018 The Authors. *Hepatology Communications* published by Wiley Periodicals, Inc., on behalf of the American Association for the Study of Liver Diseases. This is an open access article under the terms of the Creative Commons Attribution-NonCommercial-NoDerivs License, which permits use and distribution in any medium, provided the original work is properly cited, the use is non-commercial and no modifications or adaptations are made.

View this article online at wileyonlinelibrary.com.

DOI 10.1002/hep4.1289

Potential conflict of interest: Nothing to report.

portosystemic shunt (TIPS) or surgery are appropriate for a select group of patients.⁽¹⁰⁾ Two published small case series have reported the use of endoscopic ultrasound (EUS)-guided coiling for GV and anastomotic varices with overall favorable results coupled with a lower complication rate. The mechanism of GV obliteration is likely attributed to coil-induced variceal thrombosis.^(11,12)

Herein, we report a case series of 10 patients with portal hypertension and GV who were successfully treated with EUS-guided angiotherapy of GV, with complete to near-complete resolution and with no reported postprocedural major adverse events.

Patients and Methods

Between March 2015 and March 2018, 10 patients with GV were treated with EUS-guided angiotherapy when they experienced recent variceal bleeding or were deemed to have imminent bleeding by screening gastroscopy. Written informed consent was obtained from all participants.

The EUS-guided angiotherapy procedure began with passing a linear-array echoendoscope (ultrasound gastroscope) from the oral orifice to the stomach. The presence of GV was then confirmed by Doppler assessment, which showed color representing blood flow within the varices. Subsequently, under EUS vision and Doppler guidance, the varices were accessed with a 19-gauge needle (Boston-Scientific, Spencer, IN). Once the needle was inside the gastric varix, the stylet was withdrawn and the coil was deployed by advancing the stiffer part of a 0.035-inch guide wire. The coil used was a synthetic, stainless steel fiber, 50-150-mm-long, and 8-15-mm-diameter coil (MWCE; Cook Medical, Limerick, Ireland).

After coil insertion, Doppler examination was performed to assess blood flow. In some patients, we then used 1-2 mL synthetic CYA surgical glue (glubran2; GEM Srl, Viareggio, Italy) injected after coil application. A 7-gauge injection catheter was passed through the gastroscope channel, and the needle was placed into the gastric varix. We then injected 5 mL distilled water into the catheter to eliminate dead space. Immediately after, the CYA glue was injected into the varix with the syringe followed by flushing of the syringe with distilled water to empty the catheter of the glue. The distal tip of the injection catheter was cut before removing it from the endoscope.

Complete eradication was defined by the absence of GV as assessed by subsequent EUS. Near complete eradication was defined as the presence of remnant small GV, as assessed by EUS, that do not require further EUS-guided coiling. Patients underwent repeat EUS-guided angiotherapy sessions at recurring intervals as needed until complete GV obliteration.

All procedures were performed by one physician with more than 10 years expertise in the field of advanced endoscopy. Bleeding complications were divided into minor and major complications, with a minor complication defined as site-puncture bleeding that stopped spontaneously without the need for local treatment. A major complication was defined as bleeding that necessitated endoscopic hemostatic intervention.

Results

CLINICAL PRESENTATIONS AND LABORATORY FINDINGS

Seven of the 10 patients had GV secondary to cirrhosis (four cases secondary to nonalcoholic

ARTICLE INFORMATION:

From the Liver Unit, Institute of Gastroenterology and Liver Diseases, Division of Internal Medicine, Hebrew University-Hadassah Medical Organization, Jerusalem, Israel.

ADDRESS CORRESPONDENCE AND REPRINT REQUESTS TO:

Tawfik Khoury, M.D.
The liver Unit
Institute of Gastroenterology and Liver Diseases
Division of Internal Medicine
Hebrew University-Hadassah Medical Center

P.O.B. 12000
91120 Jerusalem, Israel
E-mail: Tawfik.khoury.83@gmail.com
Tel.: +972 509870611

TABLE 1. BASELINE CHARACTERISTICS

Characteristic	Baseline
Patients (N)	10
Mean age, years (range)	46.8 (13-80)
Male/female	7/3
Cirrhosis	
• Present	7
• Absent	3
Hypertension (n)	2
Type 2 diabetes mellitus (n)	3
Hyperlipidemia (n)	1
GV type	
• GOV-1	2
• GOV-2	5
• IGV-1	3
Thrombocytes (mean)	108,600
INR	1.56

steatohepatitis (NASH), one case secondary to hepatitis C virus, and two secondary to autoimmune hepatitis), while the other 3 patients had noncirrhotic portal

hypertension as the cause of GV. The mean age of male patients (n = 7) and female patients (n = 3) was 46.8 years. The most common GV type was GOV-2, which was present in 5 patients. All patients with NASH cirrhosis had comorbid conditions, including diabetes mellitus type 2, hypertension, and hyperlipidemia, and 1 patient had ischemic heart disease and congestive heart failure. Nine of the 10 patients were treated with beta-blockers to reduce portal hypertension (8 patients were treated with propranolol, 1 patient was treated with carvedilol). The mean platelet count was 108,600 (range, 53,000-200,000), and the mean international normalized ratio (INR) was 1.56 (range, 1.1-3.3) (Table 1).

MANAGEMENT PLAN

All patients underwent EUS-guided coiling (representative procedure of 1 patient is shown in Fig. 1). Eight patients underwent the procedure due to a recent (within 1-2 days) episode of upper gastrointestinal

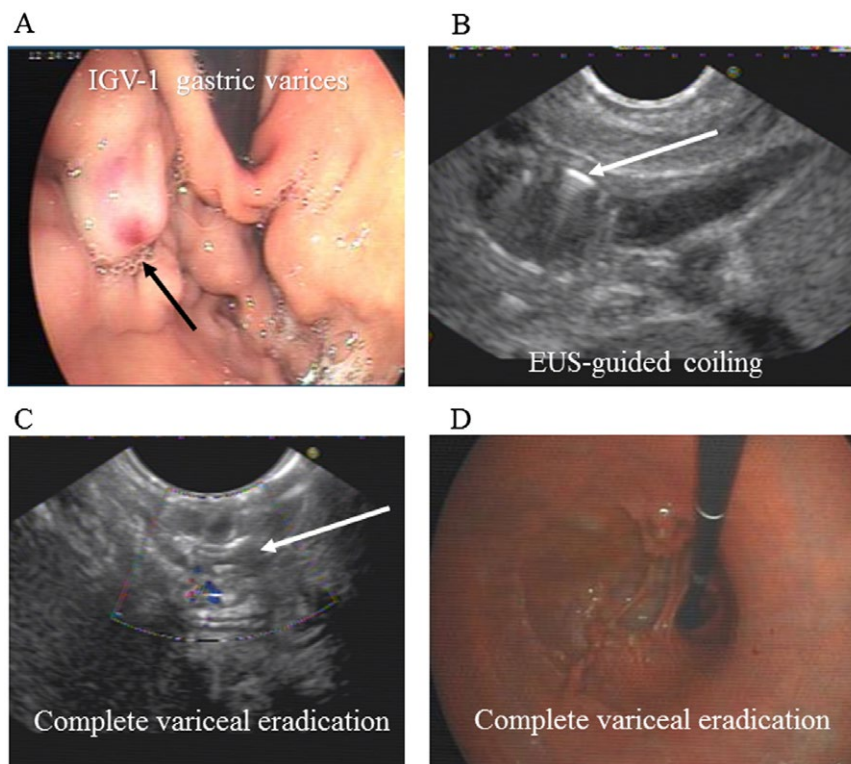


FIG. 1. Representative images of the EUS-guided procedure. (A) Upper gastroscopy showing IGV-1 (black arrow). (B) EUS-guided insertion of coils (white arrow). (C) Doppler EUS showing no blood flow of GV (white arrow). (D) Upper gastroscopy showing a complete eradication of IGV-1. Images are to scale.

bleeding (two coffee ground, five bloody emesis, and one melena). The other two cases underwent the procedure as a preventative measure due to red spots identified on the varix. The sessions were carried out at different time points (range, 4-6 weeks between each session).

Overall, we used CYA glue injection on five occasions (four cases). In case number 2, we injected 1 mL of CYA glue after the first and second coiling sessions due to the presence of an overlying ulcer on the GV. In case number 3, we injected 1 mL of CYA glue in the fourth coiling session due to the presence of a red spot on the GV. In case number 5, we injected 1 mL of CYA glue in the first coiling session due to the presence of an overlying ulcer on the GV. In case number 8, the patient developed postcoiling variceal bleeding after the second session, and we thus injected 2 mL of CYA glue and had complete bleeding cessation (Table 2).

OUTCOMES, SAFETY, AND ADVERSE EVENTS

In two cases we achieved complete eradication of the GV as assessed by complete absence of blood flow on Doppler-EUS. In five cases, near complete eradication was accomplished as we observed very minimal remnants of GV on EUS that were not amenable for

further coiling sessions due to their small size. Three patients underwent one to two coiling sessions, and they are scheduled to receive further treatment to obtain a satisfactory response (case numbers 8-10). No anesthesia-related adverse events occurred. There were 10 instances of minimal self-limited bleeding that occurred at the puncture site during the procedure in 5 patients, and in 1 patient there was persistent bleeding at the puncture site that necessitated CYA glue injection to stop the bleeding (case number 8). There were no EUS-guided angiotherapy-related adverse events within the average follow-up time of 9.7 months (range, 1-28 months). One patient was admitted to hospital 2 months after the procedure due to upper gastrointestinal bleeding that was diagnosed to be secondary to gastric antral vascular ectasia, and 3 months later he died secondary to liver failure (case number 7). Following EUS-guided angiotherapy treatment, no patients required hospitalizations due to variceal-related bleeding. No other procedure-related morbidity or mortality events occurred through the end of follow-up (Table 2).

Discussion

Gastric variceal bleeding is a condition with a high mortality rate, and there is currently no global

TABLE 2. DETAILED TREATMENT PLAN, SAFETY, ADVERSE EVENTS, AND OUTCOMES

Characteristic	Patient Number									
	1	2	3	4	5	6	7	8	9	10
Sex	Male	Male	Female	Male	Male	Male	Male	Female	Male	Female
Age (years)	70	71	13	27	69	41	33	33	80	31
Cirrhosis	Yes	Yes	Yes	No	Yes	No	Yes	No	Yes	Yes
Indication	IGV-1	GOV-2	IGV-1	GOV-2	GOV-2	GOV-2	GOV-2	IGV-1	GOV-1	GOV-1
CPS	B8	B9	A6	-	B7	-	C11	A6	A6	B8
Platelets (10E9/L)	61	84	150	170	71	200	53	85	99	113
INR	1.56	1.49	1.35	1.1	1.27	1.23	3.3	1.27	1.43	1.62
Coiling sessions	2	4	4	4	3	3	3	2	2	1
Total coils inserted	4	6	7	6	3	3	8	2	4	2
Major bleeding	0	0	0	0	0	0	0	1	0	0
Minor bleeding	0	1	1	0	3	3	2	0	0	0
CYA use	No	Yes	Yes	No	Yes	No	No	Yes	No	No
Average time between sessions (days)	56	38	27	45	50	35	68	20	4	-
Outcome	NCE	NCE	CE	NCE	CE	NCE	NCE	FSP	FSP	FSP
Follow-up (months)	23	12	14	28	6	6	5	2	1	1

Abbreviations: CE, complete eradication; CPS, Child-Pugh score; FSP, further sessions planned; NCE, near complete eradication.

current consensus with regards to optimal treatment. According to the American Association of the Study of Liver Diseases, endoscopic therapy is currently considered the first line of treatment for GV.⁽¹³⁾ Moreover, the International Consensus in Portal Hypertension Workshop held in 2015 (Baveno VI) recommended CYA injection as the initial therapeutic choice⁽¹⁴⁾ and TIPS as the second option.⁽¹⁵⁾ Only a few small case series have reported on the topic of coiling therapy in GV. Levy et al.⁽¹¹⁾ were the first to report a successful coiling procedure for bleeding ectopic anastomotic varices. Another series reported the use of coil treatment in 4 patients, resulting in GV obliteration in 3 of these patients.⁽¹²⁾ Romero-Castro et al.⁽¹⁶⁾ compared the impact of CYA injection to that of coiling and showed the mean endoscopic time session and adverse events to be lower in the coiling group compared to the CYA group.

In our study, we used glue injection following coil insertion during five sessions of EUS-guided angiotherapy (four cases). We administered both therapies out of concern for the large size of the varices (>5 cm) in addition to the high-risk potential for bleeding (in patient numbers 2 and 5, an ulcer was seen in the varix; in patient number 3, red signs were seen on the varix). The rationale behind combination therapy of coiling and glue was that the coil would help prevent glue embolization,^(11,12) and an earlier study reported favorable results of combined coiling and CYA injection treatment.⁽¹⁷⁾ Bhat et al.⁽¹⁸⁾ reported the combined use of EUS-guided coils and CYA glue injection and showed a complete obliteration of GV in 93% of the patients. In their series, post-treatment bleeding from obliterated GV occurred in 3 out of 93 patients and adverse events occurred in 5 patients (1 patient had pulmonary embolism and 4 patients had postprocedural abdominal pain). In our study, none of the patients treated with EUS-guided CYA glue injection following coiling had an embolic event. Half of the patients in our cohort had minor complications, with most being minor, self-limited, puncture-site bleeding. This was similar to what was reported in prior case series.^(11,16)

The limitations of our study include that it was a single-center study and that we could not measure the hemodynamics of the portal system by dynamic computed tomography scan. Thus, our study is intended to show the feasibility and safety of EUS-guided coiling of GV rather than

establishing hemodynamic criteria for selection of cases suitable for EUS-guided coiling. Nevertheless, the size of our series is comparable to those already reported, with the largest case series reporting 11 patients with cirrhosis who underwent EUS-guided coiling.⁽¹⁶⁾ Our study also reports on the option for EUS-guided angiotherapy using CYA glue injection as adjunctive therapy for GV with high stigmata for bleeding.

In conclusion, EUS-guided coiling in our cohort of patients was safe and associated with complete to near-complete GV eradication. Large, randomized, controlled trials are warranted for further evaluation of EUS-guided coiling and for comparison with endoscopic glue injection for the treatment of GV.

REFERENCES

- 1) Tripathi D, Ferguson JW, Therapondos G, Plevis JN, Hayes PC. Review article: recent advances in the management of bleeding gastric varices. *Aliment Pharmacol Ther* 2006;24:1-17.
- 2) Sarin SK, Lahoti D, Saxena SP, Murthy NS, Makwana UK. Prevalence, classification and natural history of gastric varices: a long-term follow-up study in 568 portal hypertension patients. *Hepatology* 1992;16:1343-1349.
- 3) Trudeau W, Prindiville T. Endoscopic injection sclerosis in bleeding gastric varices. *Gastrointest Endosc* 1986;32:264-268.
- 4) Sarin SK. Long-term follow-up of gastric variceal sclerotherapy: an eleven-year experience. *Gastrointest Endosc* 1997;46:8-14.
- 5) Tan PC, Hou MC, Lin HC, Liu TT, Lee FY, Chang FY, et al. A randomized trial of endoscopic treatment of acute gastric variceal hemorrhage: N-butyl-2-cyanoacrylate injection versus band ligation. *Hepatology* 2006;43:690-697.
- 6) Huang YH, Yeh HZ, Chen GH, Chang CS, Wu CY, Poon SK, et al. Endoscopic treatment of bleeding gastric varices by N-butyl-2-cyanoacrylate (histoacryl) injection: long-term efficacy and safety. *Gastrointest Endosc* 2000;52:160-167.
- 7) Berry PA, Cross TJ, Orr DW. Clinical challenges and images in GI. Pulmonary embolization of histoacryl "glue" causing hypoxia and cardiovascular instability. *Gastroenterology* 2007;133:1413-1748.
- 8) Saracco G, Giordanino C, Roberto N, Ezio D, Luca T, Caronna S, et al. Fatal multiple systemic embolisms after injection of cyanoacrylate in bleeding gastric varices of a patient who was noncirrhotic but with idiopathic portal hypertension. *Gastrointest Endosc* 2007;65:345-347.
- 9) Sarin SK, Jain AK, Jain M, Gupta R. A randomized controlled trial of cyanoacrylate versus alcohol injection in patients with isolated fundic varices. *Am J Gastroenterol* 2002;97:1010-1015.
- 10) Turon F, Casu S, Hernandez-Gea V, Garcia-Pagan JC. Variceal and other portal hypertension related bleeding. *Best Pract Res Clin Gastroenterol* 2013;27:649-664.
- 11) Levy MJ, Wong Kee Song LM, Kendrick ML, Misra S, Gostout CJ. EUS-guided coil embolization for refractory ectopic variceal bleeding (with videos). *Gastrointest Endosc* 2008;67:572-574.
- 12) Romero-Castro R, Pellicer-Bautista F, Giovannini M, Marcos-Sanchez F, Caparros-Escudero C, Jimenez-Saenz M, et al. Endoscopic ultrasound (EUS)-guided coil embolization therapy in gastric varices. *Endoscopy* 2010;42(Suppl. 2):E35-E36.

- 13) Garcia-Tsao G, Sanyal AJ, Grace ND, Carey W; Practice Guidelines Committee of the American Association for the Study of Liver Diseases; Practice Parameters Committee of the American College of Gastroenterology. Prevention and management of gastroesophageal varices and variceal hemorrhage in cirrhosis. *Hepatology* 2007;46:922-938.
- 14) de Franchis R; Baveno V Faculty. Revising consensus in portal hypertension: report of the Baveno V consensus workshop on methodology of diagnosis and therapy in portal hypertension. *J Hepatol* 2010;53:762-768.
- 15) Azoulay D, Castaing D, Majno P, Saliba F, Ichai P, Smail A, et al. Salvage transjugular intrahepatic portosystemic shunt for uncontrolled variceal bleeding in patients with decompensated cirrhosis. *J Hepatol* 2001;35:590-597.
- 16) Romero-Castro R, Ellrichmann M, Ortiz-Moyano C, Subtil-Inigo JC, Junquera-Florez F, Gornals JB, et al. EUS-guided coil versus cyanoacrylate therapy for the treatment of gastric varices: a multicenter study (with videos). *Gastrointest Endosc* 2013;78:711-721.
- 17) Binmoeller KF, Weilert F, Shah JN, Kim J. EUS-guided transesophageal treatment of gastric fundal varices with combined coiling and cyanoacrylate glue injection (with videos). *Gastrointest Endosc* 2011;74:1019-1025.
- 18) Bhat YM, Weilert F, Fredrick RT, Kane SD, Shah JN, Hamerski CM, et al. EUS-guided treatment of gastric fundal varices with combined injection of coils and cyanoacrylate glue: a large U.S. experience over 6 years (with video). *Gastrointest Endosc* 2016;83:1164-1172.