

Topographic computer analysis for acne scar treatment on face accompanying biopsy study after dermal injection of hydrotoxin mixture

JongSeo Kim MD

Kim-JongSeo Plastic Surgery Clinic, Seoul, Korea

Correspondence

JongSeo Kim, Kim-JongSeo Plastic Surgery Clinic, 2F ApGuJung bd, 842-NonHyun-ro, GangNam-gu, Seoul 06025, Korea.
Email: plastic@surgery.co.kr

Abstract

Background: Acne during youth can leave permanent facial scarring. The depressed acne scars can be treated by injection of stabilized hyaluronic acid (S-HA) into the dermis. Due to the large number of acne scars, manual injection methods are technically difficult and bear high risk of lump formation in the dermis. Therefore, the author designed a specific injection method to solve the two abovementioned problems.

Aims: This research aims to assess the effect of the intradermal injection of S-HA and aboborulinumtoxinA mixture in the treatment of all types of acne scars.

Materials/Methods: A total of 102 patients who suffered from acne scars were treated with a mixture of S-HA (Restylane Vital®) and abobotulinumtoxinA (Dysport®). Using an automatic injector, micro-droplets of the mixture (0.001 cc of S-HA and 0.125 U abobotulinumtoxinA) were delivered into 1000 intradermal sites on whole face except eyelids. This instrument radically reduced injection amounts per site (0.001 cc), lessened manual operator efforts, and ensured consistent injection depth (from 0.8 to 1.2 mm depending on individual dermal thickness) into the facial dermis. The changes in each depression site of acne scars were evaluated by topographic computer analysis (point roughness), based on the 40 magnification microscopic photographs generated. Depth measurements of each small acne scar point were taken one by one at the exact same point before and after the treatments. Global Aesthetic Improvement Scale (GAIS) was measured for improvement of acne scars at 1- and 6-month posttreatment. Additionally, serial histologic examinations of the biopsy specimens evaluated neocollagenesis, neoelastinogenesis, and longevity state of the S-HA.

Results: A total of 78 patients showed improvements of depressed acne scars in physical examinations, medical photographs, and dermoscopic photographs.

Using topographic computer analysis, the average point roughness decreased 27.48% (at 1 month) from 29.042 ± 6.85 (baseline) to $21.05 \pm 6.30 \mu\text{m}$ ($P < .0001$), corresponding with scar improvements observed in physical examinations, and 3.02 ± 0.66 of GAIS at 1-month posttreatment. Using an injector allowed the hydrotoxin mixture

This is an open access article under the terms of the Creative Commons Attribution-NonCommercial-NoDerivs License, which permits use and distribution in any medium, provided the original work is properly cited, the use is non-commercial and no modifications or adaptations are made.

© 2020 The Authors. *Journal of Cosmetic Dermatology* published by Wiley Periodicals LLC

into the deep dermal layer. Biopsy study proved that the injection depth was exactly in the dermis, and showed evidence of neocollagenesis and neolastinogenesis. Also, the S-HA particles remained after 1 year, which proved its longevity of at least 1 year. **Conclusion:** The topographic computer analysis using point roughness showed improvement of all subtype acne scars at 1-month posttreatment. The improvement may have resulted from dermal expansion due to the neocollagenesis and neolastinogenesis. S-HA lasted more than 1 year in human dermis.

KEYWORDS

acne scar, biopsy, dermal injection, hydrotoxin, microbotox, microHA I topographic analysis

1 | INTRODUCTION

As facial skin is a highly visible organ, its good texture is critical for a youthful and beautiful appearance. Acne scar removal has been constantly challenged, at times producing disappointing results.¹ With improvements in technology and esthetic products, acne scars can be treated with fractional lasers and micro-needle rolling to recreate smoother facial skin. Many sessions of fractional laser treatments are usually effective in treating acne scars, but patients experience severe pain and must endure long recovery periods after the treatments. The laser treatments also aggravate active acne with increased risk of postinflammatory hyperpigmentation (PIH).¹ Therefore, laser treatments should be avoided in patients with active acne and seasonally during the summer. To treat acne scar using micro-needling, numerous sessions are necessary.

In contrast, one session of injection using stabilized hyaluronic acid (S-HA) and botulinum toxin mixture showed vast improvement in the depressed acne scars with a relatively short recovery time without risk of PIH or aggravation of active acne.²⁻⁵ Beer (2007) and Alam described that "rolling" type of acne scars was best responded by PLLA injection.⁶ As described by these authors, "broad based, gently undulating scars" responded more to treatment with PLLA injection than "steep-edged smaller ice-pick-type scars."⁶ Sadove (2009) described that macular atrophic scars were easier to conceal and treat than small and deep ice-pick scars.⁷ In postacne scarring, subcision has been used mainly in the treatment of rolling atrophic scars.⁸ The removal of acne scars by manual subdermal injection of S-HA and/or subcision has been documented in previous articles.^{2,3,8-10} However, HA injection and/or subcision procedures have exhibited extreme difficulty in changing skin texture and elevating the ice-pick and boxcar acne scars.⁸⁻¹⁰

The blanching technique¹¹ has been introduced to treat acne scars, but this manual injection into the countless depression sites is difficult, and their depths are often inaccurate and inconsistent. S-HA can be classified into monophasic and biphasic. For blanching technique, monophasic HA filler should be used, but the spreading nature of the monophasic S-HA has caused a lack of lifting effect in the dermis showing less improvement of depressed acne scars. In this study, the biphasic S-HA and specialized automatic injector

were designed to solve these dilemmas.¹²⁻¹⁶ Due to the large number of acne scars, manual injection methods or blanching methods are technically difficult bearing risk of lump formation. The author tried to treat acne scar using real intradermal injection of S-HA into whole face by an automatic injector.

In Shah's studies for patients with oily skin and large pores, dermatoin procedures have decreased their skin pore sizes.¹⁷ Dermatoin has compact consequences of reduced oil secretion and decreased skin pore size. Thus, the author combined dermatoin and intradermal injection of HA. The author's novel injection mixture and technique allow physicians to treat acne scars effectively with less manual effort. This study investigated the impact of using HA with micro-filling effect to treat micro-depression dermal deformities in acne scar on facial dermis, being the prime case study.

2 | MATERIALS AND METHODS

This was a single-center, prospective, up-to-date computer analysis for improvement of acne scar after randomized micro-injections of "hydrotoxin mixture" in dermis. The mixture comprised of 1cc S-HA gel (Restylane Vital[®][RV]; Galderma, Uppsala, Sweden), 1 cc (125 U) of abobotulinumtoxinA (ABO; Dysport[®]; Ipsen, France) and 1 cc of 2%-lidocaine. To lift atrophic depressed acne scars (all subtypes; ice-pick, rolling, boxcar), particle-type S-HA was chosen than monophasic S-HA, and among them, RV has most small particle size that can reduce dermal lumps. BotulinumtoxinA is mixed for booster effect to improve skin texture for acne scar. A total of 500U (1 bottle) of ABO was mixed with 4cc of normal saline (N/S) before the reconstitution, and among them, 1cc was used for constitution of the mixture.

A total of 102 patients (63 female, 39 male with an average 33.1 years of age) who suffered mainly from acne scarring with relatively oily skin were selected and treated between January 2010 and October 2016.

Before the injection, a topical anesthetic cream (9%-lidocaine) was applied on the facial area, followed by occlusive dressing using a common plastic wrap for 40 minutes. An automatic injector (Vital Injector[®], Ensung Global, Korea) placed 0.003 cc of the hydrotoxin mixture (including 0.001cc of S-HA, 0.125 U of ABO in 0.001cc of

N/S, and 0.001 cc of lidocaine) into 1000 discrete sites. While reducing injection time and operation efforts, the automatic injector also ensured constant, consistent controlled, and accurate depth of injection. The injector was set to a 1mm injection depth as a default. During the injection, if there was larger bleeding, injection depth was changed to 0.8 mm setting. If leakage was detected during the procedure, injection depth was changed to 1.2 mm. The injector was equipped with 5 needles (31G) each spaced 5mm apart, thus requiring 200 sets of injections to deliver the total of 1000 injection sites. Systematic distribution of micro-droplet injections placed regularly on the patients' whole faces which had acne scars. After one pass of injection on whole face, remained solution was injected acne scar areas between injection sites. Thus, the injection interval for special areas (acne scar areas) spaced 2.5 mm apart.

Informed consent was obtained from each patient, and the study adhered to tenets of the Declaration of Helsinki. Each patient received only one treatment session with 3 cc of hydrot toxin mixture and followed up at 1 and 6 months for evaluation. The whole face received the injections except eyelids. In order to obtain accurate postprocedure measurements, patients used the same type of facial cleanser (Hydropapaya power wash[®], Reteenage corporation, Seoul, Korea) to remove all makeup and lotion from their faces and then rested for at least 15 minutes in a temperature-controlled room before each measurement.

2.1 | Acne scar evaluation by dermascope

The physical examinations and dermoscopic images before the treatment (baseline, week 0) and 1-month posttreatment evaluated the severities of acne scarring.

A skin dermascope (CCL-215USB, Coscam) measured changes in skin surface morphology, and point roughness was calculated by computer program. The areas were imaged under closed lighting conditions at 10X and 50X magnifications before (as control) and after the treatments by a standardized minimal-contact method using the dermoscopic cap (Figure 1).

2.2 | Topographic computer analysis (point roughness) in each depressed acne scar

Point roughness (speckle contrast) in each acne scar points was observed in comparison with photographs taken before and 1-month posttreatment using the topographic computer analysis program (Gwyddion[®]). From the varying levels of brightness (black and white) in 50X dermoscopic photographs, the points of lighter areas indicated normal skin surfaces while darker (shadowed, depressed) areas indicated acne scars. This measurement method is known as the "Speckle Contrast" method.¹⁸ The

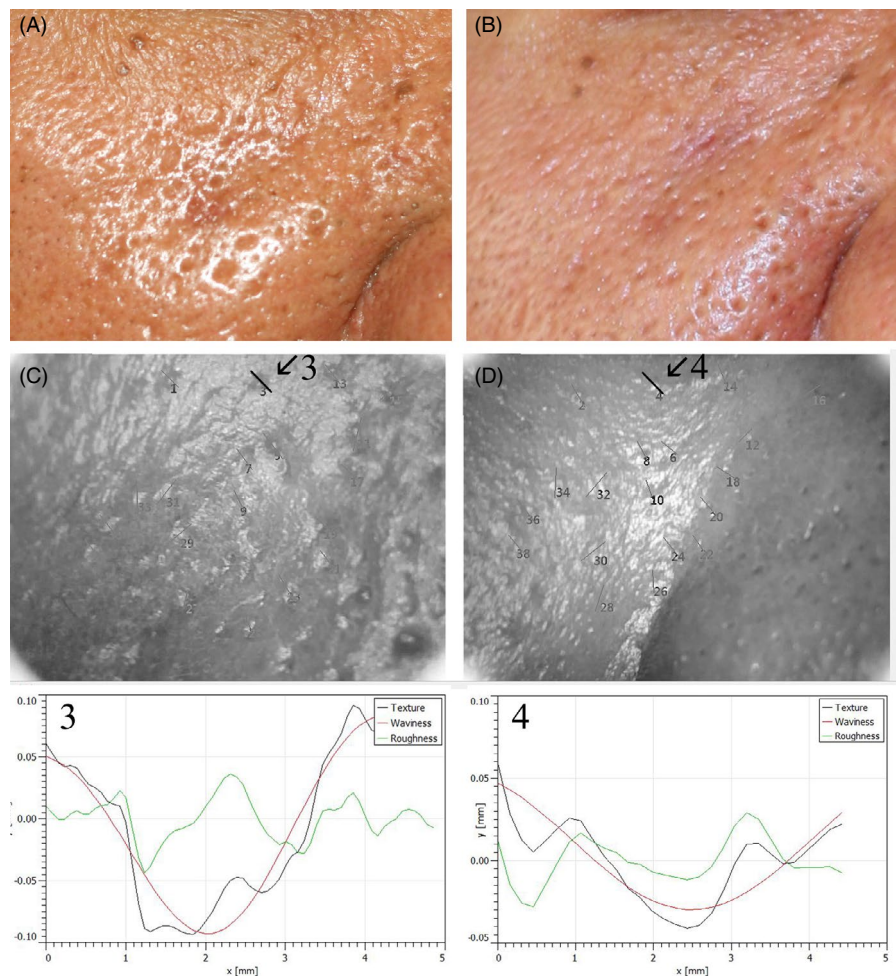


FIGURE 1 Acne scar in a 41-y-old male patient and topographic computer analysis. A,C, Before treatment, the patient displayed oily and thick skin with severe "rolling," "boxcar," and "ice-pick" scars. B,D, One month after treatment with intradermal injection, acne scars were significantly reduced in severity. C, 50 \times magnification dermoscopic photographs before the treatment. D, At 1-mo posttreatment, acne scars appeared significantly less depressed and had smaller diameter than baseline (C) in 50X. (3) Point roughness on point-3 of C. (4) Point roughness on point-4 of D showing reduced roughness

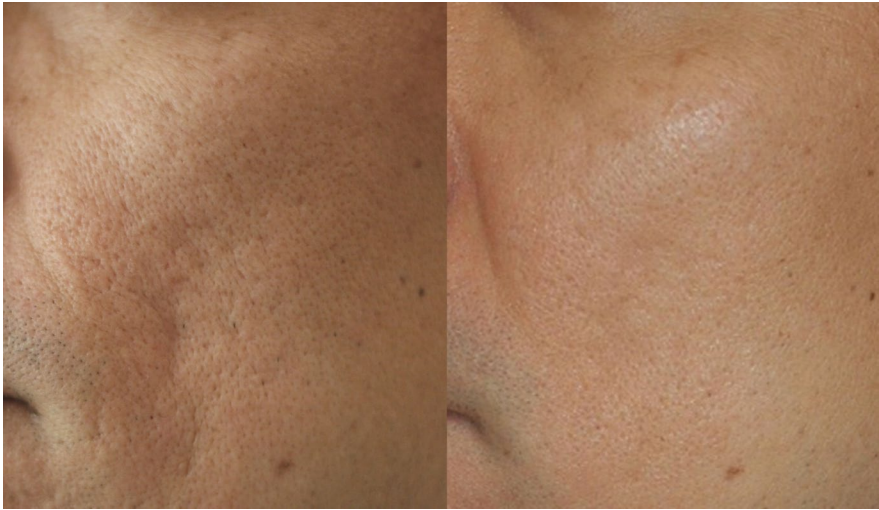

FIGURE 2 Before and after photographs showed improvement of “ice-pick acne scars” in a 53-y-old male patient. (left) Note ice-pick acne scars in cheek area before the treatment. (right) At 1-mo postinjection of the hydrotoxin mixture into dermis, ice-pick type acne scars had improved

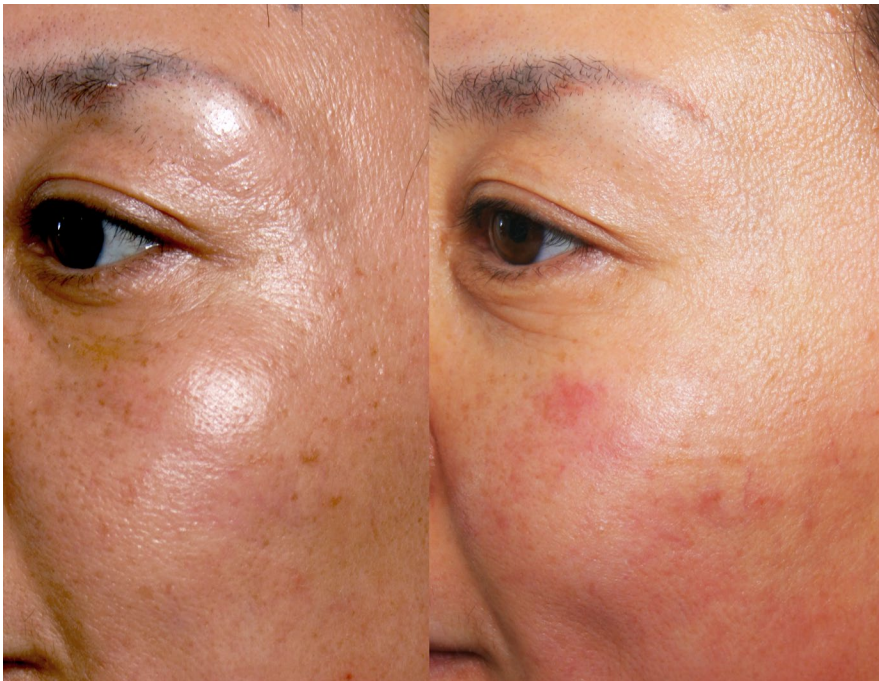

FIGURE 3 Before and after photographs showed improvement of “ice-pick acne scars” on the anterior cheek area in a 63-y-old female. (Left) Note small sized ice-pick acne scars and enlarged skin pores in anterior cheek area before the treatment. (Right) At 1-mo postinjection of the hydrotoxin mixture, ice-pick acne scars and skin pores had improved in her anterior cheek area

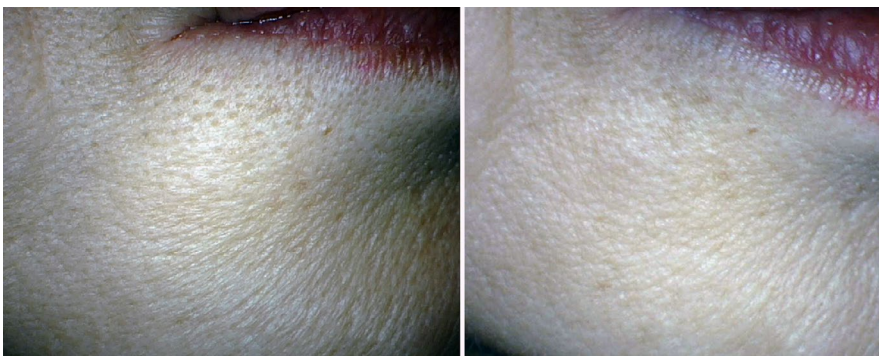


FIGURE 4 Dermoscope imaging (10 \times) of Marionette lines in a 67-y-old Female. (Left) Before treatment. Note mild degree of ice-pick acne scars and wrinkles on lower face. (Right) At 1-mo posttreatment, ice-pick acne scars, skin pores, and skin roughness were reduced, showing improvement of fine wrinkles on her lower face

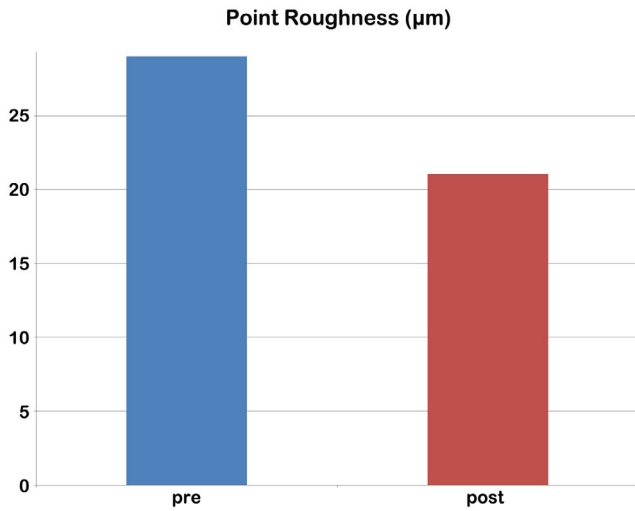


FIGURE 5 Topographic computer analysis (point roughness) for acne scar. The average of point roughness in acne scars decreased 27.48% from $29.04 \pm 6.85 \mu\text{m}$ (before) to $21.05 \pm 6.30 \mu\text{m}$ (at 1-mo posttreatment). ($P < .0001$)

topographic computer analysis program is developing based on the speckle contrast method and can measure the point roughness of each focal point in acne scars. The exact same points (20-point per 50X dermoscopic photographs) were compared in before and after microscopic images by the program. A larger roughness value indicates greater severe, depressed acne scars, where by reduced roughness value after treatment indicates less depressed acne scars (Figure 1E,F).¹⁸

2.3 | Global Aesthetic Improvement Scale

Patient satisfaction was evaluated at 1- and 6-month posttreatment using the Global Aesthetic Improvement Scale (GAIS): 0: worse, 1: no change, 2: improved, 3: much improved, and 4: very much improved.

2.4 | Biopsy study

Six patients volunteered for twice planned facial lift surgeries 1-month and 1-year postinjection to evaluate injection depths, the longevity of injection materials, and tissue reactions of S-HA including neocollagenesis and ne elastinogenesis. Most patients presented acne scars on the temple area. During the facelift surgeries, specimens were taken from the temple area near hairline and then analyzed histologically with hematoxylin-Eosin (H&E), Masson's Trichrome, Alcian-Blue, and Victoria-Blue stainings to confirm that neocollagenesis and ne elastinogenesis in the dermal layer, which influenced the improvements of acne scars. Due to ethical practice policies, biopsies of a control area could not be obtained and intra-individual split study was not implemented. Therefore, observations were made and compared between histologic sections obtained 1-month (baseline in histologic comparison) and 1-year postprocedure from the same subject.

3 | RESULTS

Twenty-four of 102 AS patients failed to follow-up. A total of 78 patients (47 female, 31 male, average 37.8 years of age) followed up for the entire course of this study. All patients showed improvements of depressed acne scars in physical examinations, medical photographs, and dermoscopic photographs (Figures 1-4) sixty-five patients (83.3%) experienced improvement of enlarged pores also. Immediately after the procedure, 49 patients (62.8%) also experienced numerous small (1mm) needle marks (ecchymosis) on each injection sites, especially near the lower-eyelid areas. These needle marks spontaneously resolved within a few days.

Lumps were also found especially for patients who had thin skin near lower eyelids. The lumps were immediately treated by compression with a cotton ball in most cases. But 5 patients (6.4%) experienced long-lasting (more than 1 month) small lumps (0.5 to 1mm

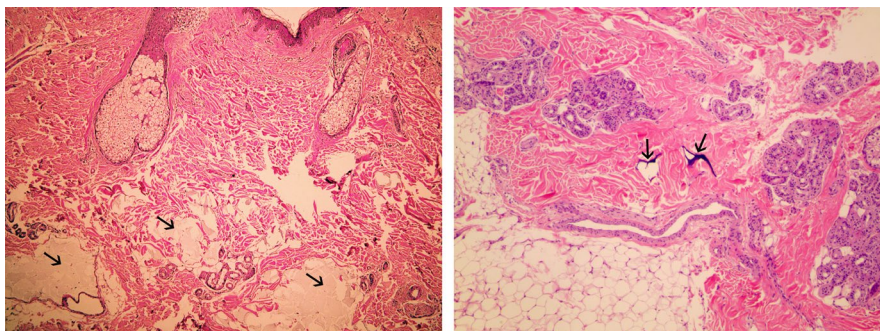


FIGURE 6 Biopsy study from the temple area of the same 41-y-old female after intradermal injection of particle-type S-HA in H&E stain at 1-mo (40 \times) and 1-y posttreatment (100 \times). (left) At 1-mo postinjection, 40 \times H&E stain. 1 μL of S-HA micro-droplets was injected precisely in the dermal layer. S-HA particles (arrow) had been found in deep dermal layer and displaced collagen fibers showing lifting effect. There would be a limit to spread for HA particles through collagen fibers in dermis. Particle size of S-HA on biopsy slide was from 97.79 to 230.51 microns in length (average of 157.29 ± 24.66 microns, Figure 7). (Right) At 13-mo postinjection with 100 \times H&E stain adding Alcian-Blue stain. Collagen fibers became thicker and denser in the dermis than at 1 mo. S-HA particle (arrow) had decreased in size and shrunk, but still existed even though the particle size became smaller. This finding proved that 0.001cc of micro-droplets lasted more than 1 y of longevity. (stabilized hyaluronic acid: S-HA, hematoxylin and eosin: H&E, magnification: \times)

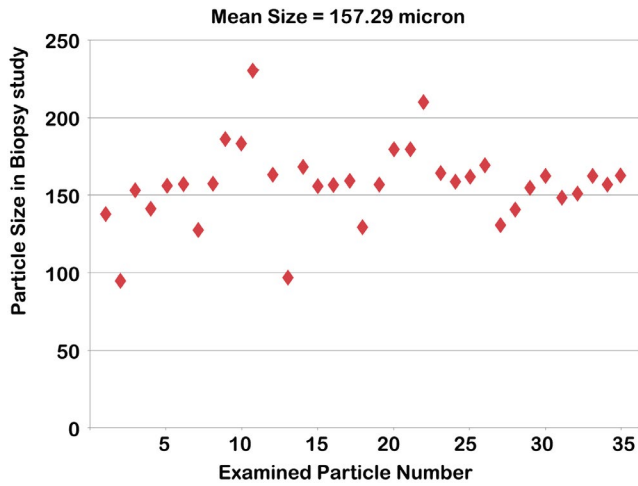


FIGURE 7 Measurement in size of S-HA in biopsy at 1-mo postinjection. S-HA particles measured from 97.79 to 230.51 microns in length on biopsy slides (average: 157.29 ± 24.66) at 1-mo postinjection. (stabilized hyaluronic acid: S-HA)

diameter) on lower eyelids. There was no patient who had experienced itching, allergic reactions.

Improvements in all acne scar subtypes (including ice-pick, rolling, and boxcar) and skin pores were appearing after one or two weeks with significant improvements visible after one or two months in physical examination. Under the skin microscope at high magnification, the changes were more noticeable than in general observations by the naked eye during physical examinations (Figures 1-4).

3.1 | Topographic computer analysis (point roughness) in each depressed acne scar

Using topographic computer analysis, the average point roughness decreased 27.48% from 29.04 ± 6.85 (before) to $21.05 \pm 6.30 \mu\text{m}$ (at 1 month) corresponding to improvements observed in physical

examinations. The point roughness reduction displayed a statistically significant improvement indicating elevation of the depressed areas ($P < .0001$) (Figure 5).

3.2 | Global aesthetic improvement scale

GAIS scoring of acne scars was 3.02 ± 0.66 at 1-month posttreatment, and 1.81 ± 0.31 at 6-month posttreatment.

3.3 | Biopsy study

In the biopsy study with H&E stain after one month's observation, the S-HA filler (RV) revealed particles of HA that had a range of 97.79-230.51 microns in length, with a mean of 157.29 ± 24.66 microns (Figure 6-left, 7). Using the injector allowed exact placement into the deep dermal layer, 0.6 to 0.9 mm from the epidermis in the biopsy results (Figure 6-left). The collagen fibers in the dermis were displaced by S-HA particles showing excellent lifting effect at 1-month and 1-year posttreatment.

In H&E stain with Alcian-Blue, collagen fibers became thicker and denser with decreased HA particle size at 1 year postinjection than at 1 month (Figure 6-right). At 1-year, the S-HA particle also remained even though smaller particle size than at 1 month, which proved that 0.001cc of micro-droplets had more than 1 year of longevity.

Victoria-blue staining showed the changes (amount and pattern) of elastic fibers in the dermis between 1-month and 1-year postinjection. (Figure 8) There were elastic fibers in their typical amount and shape (thin and coiled) that stained dark blue in the dermis showing similar distribution and pattern of elastic fibers at 1-month postinjection. (Figure 8-left) In the biopsy from the same patients at 1-year postinjection, abundant, thicker and stained darker blue elastic fibers than at 1-month, and HA particles were observed with decreased in size. The elastic fibers show an increase in amount and are organized into a denser and thicker pattern, branching in the dermis

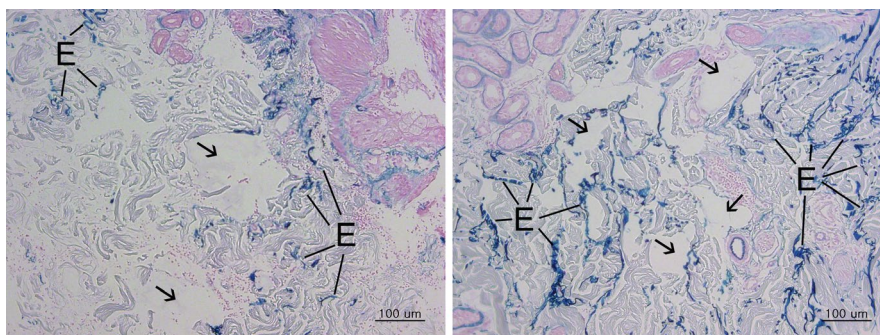


FIGURE 8 The changes of elastic fibers on temple area of 43-y-old female with 200× Victoria-blue staining. (left) S-HA particles (arrow) were identified in the deep dermal layer at 1 mo (baseline) after the injection. Elastic fibers (E) were stained dark blue in the dermis and showed their typical amount and thin coiled shape. (right) At 1-y postinjection, more abundant elastic fibers (stained dark blue: E) were observed around S-HA particles (arrow) than at 1 mo (baseline). The S-HA particles (arrow) have decreased in size. Elastic fibers showed an increase in amount and were organized into a denser and thicker pattern, branching in the dermis

(Figure 8-right) HA particles were identified in the deep dermal layer of the biopsy specimens at 1-month and 1-year postintra-dermal injection. These findings also proved that 0.001cc of micro-droplets had last more than 1 year of longevity in Victoria-blue staining.

4 | DISCUSSION

Ice-pick scars are narrow (<2 mm), deep, sharply marginated epithelial tracts that extend vertically to the deep dermis or subcutaneous tissue. The surface opening is usually wider than the deeper infundibulum as the scar tapers from the surface to its deepest apex.

Rolling scars occur from dermal tethering of otherwise relatively normal-appearing skin and are usually wider than 4-5 mm. Abnormal fibrous anchoring of the dermis to the subcutis leads to superficial shadowing and a rolling or undulating appearance to the overlying skin. Although they tend to be shallow, the subdermal tether precludes treatment from the surface above. Correction of the subdermal component is essential for treatment success. Boxcar scars are round to oval depressions with sharply demarcated vertical edges, similar to varicella scars. Boxcar scars are clinically wider (most often 1.5 to 4.0 mm in diameter at the surface) than ice-pick scars and do not taper to a point at the base. In this study, subjects did not show other less common scars such as sinus tracts, hypertrophic scars, and keloidal scars.^{19,20} As other study, manual injection using injectables showed mainly improvement for rolling type acne scar and it was hard to treat ice-pick scars.^{6,7,10} But in this study, systematic dermal injection using an automatic injector using the novel hydrotoxin mixture (the author's method) showed great improvement of all subtype acne scars. True dermal injection using an automatic injector is effective than subdermal injection by manual injection (false dermal injection). During the treatment of ice-pick acne scar, it is hard to inject into each exact depressed spots and into true dermis with the manual injection method.

According to evaluation techniques for skin surface, especially the speckle contrast techniques, the reduced contrast value shows improvement or elevation of depressed acne scarring.¹⁸ Roughness was evaluated and measured by the Row/Column Statistics Tool using dermoscopic photographs by 50X before and 1 month after treatment.^{18,21} The Row/Column Statistics tool calculates numeric characteristics of each row or column and plots them as a function of its position.

Based on the principles and equations above, in 50X microscopic photographs, point roughness was calculated topographically using the computer program (Gwyddion statistical analysis) for exact same area (1 month and 1 year) of acne scars.²¹ Among countless columns, individual columns are represented in the graph displaying the values. As a sample, the mean value and the standard deviation of the selected quantity are calculated from the set of individual column values (Figure 1E,F).²²

RV contained small particle-sized biphasic-HA among the Restylane[®] filler range, and some articles had introduced intradermal

injection using RV.¹²⁻¹⁶ Before using of RV clinically for patients, the author demonstrated intradermal injection on the author's own hand dorsum, and the injection amount was 0.01 cc per site.⁴ But 0.01 cc of RV had made dermal lumps, despite William's article saying that there was not any lump on dorsal hand after 0.025cc of RV per site after dermal injection (0.5cc for 20 injection points).¹² In William's article, the injection depth was presumed to be subdermal, even though they believed their injection depth was in the dermis.¹²

The author's biopsy study proved that mean particle size of RV was 157.29 ± 24.66 microns (ranged from 97.79 to 230.51 microns). Particle size about 100 micron biphasic-HA filler was named as microphasic-HA in a previous article by the author.²³ Injectables with small particle size S-HA (microphasic-HA) have less opportunities to create lumps by spreading through the dermal layer more easily than the larger particle size S-HA. However, microphasic-HA also poses a higher risk of lump formation than monophasic HA. In biopsy study, microphasic-HA showed relatively larger mass size than dermal collagen bundles. And this difference in size may restrict migration of S-HA from even distribution in dermis (Figure 6).^{4,12,24-26}

When using RV (biphasic S-HA), deep subdermal layer injections may be performed to prevent lumps; however, this deep injection method can hardly improve acne scarring or large skin pores.^{2,3} And monophasic S-HA showed less displacement of dermal collagen than biphasic S-HA in the author's previous study.²⁷ Thus, monophasic S-HA may show less effect in treatment of acne scarring even after dermal injection, because it spreads easily between the collagen fibers and hardly displaces (low lifting power) dermal collagen fibers.^{27,28}

Removing larger-diameter (rolling type and boxcar type) acne scars or deep ice-pick acne scars was more difficult than treating narrow or shallower acne scars. The diameter of an acne scar was an important determinant of the outcomes after the intradermal injection of S-HA. Deeper or wider acne scars required more treatment sessions and showed less improvement than narrow or shallower acne scars.^{29,30}

This combination method of MicroBotox and Microhyaluronicacid has been performed by an automatic injector.²⁷ The method of using a HydroToxin mixture with an automatic injector, known as the "HydroToxin Method" can be a scientific and logical treatment for acne scars, dry skin, and fine wrinkles on the faces. This method simplifies the injection of a hydrotoxin mixture (many kinds of S-HA and botulinumtoxinA) into the true dermal layer dividing a very tiny volume (0.001 cc) into numerous (1000) sites which is impossible in manual injection techniques.¹²⁻¹⁶ The hydrotoxin injection technique facilitates the treatment of acne scars, enlarged skin pores, dry skin, fine wrinkles, and skin roughness with longevity of over 6 months. This is because S-HA persists for more than 1 year while botulinum toxin A lasts for up to 4 or 5 months. In the author's experience, particle-type S-HA also showed a greater effect on acne scar and had higher risk of causing dermal lumps than using monophasic HA (XeoBel method).²⁷ The use of an automatic injector allowed injection into 1000 sites with "Microhyaluronicacid" (1 microliter

of HA) and "MicroBotox" (0.125 U of ABO), and strongly prevents lumps as compared to the manual injector. With manual injection, it is impossible to inject 1-microliter of HA or 0.125U of botulinum toxin per site. The intradermal injection of S-HA is not a simple and easy procedure. Therefore, doctors are advised to exercise caution even when performing intradermal injections with S-HA.

While fractional laser treatment can aggravate active acne with increased risk of PIH,¹ active acne can be treated by the hydrotoxin injection. The mechanism is assumed to be the following: (a) Dermal injection of botulinumtoxinA can improve active acne and reduce sebaceous gland function, (b) 1000 sites of needling and suction cup with strong negative pressure can evacuate pus and inflammation fluid from active acne sites, and (c) hydration effect by HA dermal injection can calm inflammation and reduce oil secretion.

While subcision with S-HA injection can treat rolling acne scar only,⁸⁻¹⁰ the author's method can treat all subtypes of acne scars. The S-HA injection method provokes bruising and pain,⁸⁻¹⁰ but the author's method reduces the bruising, pain, physician's efforts, and procedure time. While subcision with/without S-HA injection needs to exact injection points one by one, the author's method allows systemic distribution regardless of the exact point of acne scars.

To treat skin texture issues (acne scars or enlarged skin pores), superficial injection (into the dermal layer) is should be performed, because subdermal injection produces mainly a volumizing effect with less effect at improving skin texture.⁴ Patients' skin was hydrated, and they felt less dryness after the procedure using hydrotoxin mixture. Patients also experienced reduced oil secretions and skin pore size, likely due to dermatoin effects (MicroBotox) by dermal hydration and dermatoin activity on the sebaceous gland.^{17,30} In comparing study of Elridy (2018), the clinical efficacy of ABO and Onabotulinumtoxin A (ONA, Botox[®]) using a dosing ratio of 2.5U:1.0U in the treatment of crow's feet wrinkles, satisfaction was higher with ABO.³¹ In Rystedt' comparison study (2008) of ABO and ONA, ABO at 200 U/ml was more potent than ONA at 100 U/ml with regard to both anhidrotic and muscular effects, and the equipotent concentration of ABO, compared with ONA 100 U/ml, was found to be in the range 100-150 U/mL.³² A randomized, double-blind, intra-individual Nestor's study (2011) showed ABO with 2.5:1.0 ratio displayed significantly longer duration of action than ONA in the frontalis activity measurement standard.³³ To improve skin texture, ABO was used in this study due to its most powerful potent and efficacy per unit.³¹⁻³³

Most European patients have thinner skin (dermis) than Asians, especially in women. Therefore, injection into dermis is very difficult for European physicians, and some of them did not distinguish the dermal injection from the subdermal injection. Finally, some articles described wrong injection depths.¹²⁻¹⁶ It is easy to inject into dermis for Asian physicians, because Asian patients (especially who have acne scars and enlarged skin pores) generally have thick skin. To treat acne scar, intradermal injection is preferred over subdermal injection into fat layers. The injection into fat layer (subdermal injection) of S-HA in Asian patients did not change the skin texture, acne scars, or enlarged skin pores.² With dermal injection, the hydrotoxin

injection into the dermis can improve various skin conditions such as acne scar, oily skin, dry skin, and fine wrinkles.^{4,27}

The unique developmental nature of the S-HA particle allowed maintenance of its volumizing effect with displacement of collagen fiber expanding the dermal component^{25,26} and may be useful for treatment of various skin conditions. The collagen fiber displacement (mechanical shear stress) may stimulate fibroblasts, resulting in neocollagenesis and neoelastinogenesis, reducing acne scar depression and size of enlarged skin pores. (Figure 7- left) According to Arnold et al, collagen and collagen-degradation peptides function as chemotactic stimuli for fibroblasts in vivo and attract these cells to effectively repair damaged tissue.³⁴ Within the chemotactic factor process, these displaced collagen fibers remain in its location in relation to the lasting S-HA, ultimately creating greater dermal expansion over a lasting period of time. This phenomenon is related with the formation of new elastic fibers (neoelastinogenesis) at 1-year postinjection in biopsy results. (Figure 8) Immediate microwound by needles also may have attracted a very small amount of chemotactic factors. Mainly, the long-term displacement of collagen served as a catalyst for fibroblasts that prompted positive additional neocollagenesis (Figure 6) and neoelastinogenesis (Figure 8). This new collagen and elastic fibers may have filled some space of dermis and reduced acne scars (depressed micro-scar in dermis) and enlarged skin pores.

5 | CONCLUSION

Intradermal injection of S-HA and botulinum toxin dramatically improved acne scars by a mechanism of "dermal expansion" and displacing collagen fibers within the dermal layer, and skin pores by MictoBotox effects. Using an automatic injector for dermal injection of S-HA, all subtype acne scars (ice-pick, boxcar, and rolling type) improved.

The dermal expansion effects may be created by a kind of intradermal volumizing and displacement of dermal collagen by microphasic-HA that was demonstrated by biopsy study. The biopsy study also proved neocollagenesis and neoelastinogenesis in human dermis after dermal injection of S-HA. Biopsies showed that each 0.001cc of 150-micron particle-type S-HA (microphasic-HA) lasted over 1 year in the dermis, and the injector allowed proper intradermal injection.

This method is applicable even on active acne scars and thus can be used to treat active acne and acne scars simultaneously.

The combination of "MicroBotox and MicroHA" showed great effectiveness and improved acne scarring and reduced large pores without significant side effects such as disturbance of facial expression and dermal lumps on the face.

ACKNOWLEDGMENTS

The author expresses thanks to "Dr Kang, Jong-il" for supporting this article.

CONFLICT OF INTEREST

"The authors have no conflicts of interest to declare."

REFERENCES

- Taylor & Francis Group, Tosti A, De Padova M, Fabbrocini G, & Beer K. Superficial peeling, Surgical technique: Subcision, grafting, excision, and punch techniques. In: *Acne Scars: Classification and Treatment*, 2nd ed. London, UK: CRC Press; 2019:1-179.
- Halachmi S, Ben Amitai D, Lapidoth M. Treatment of acne scars with hyaluronic acid: an improved approach. *J Drugs Dermatol*. 2013;12(7):e121-e123.
- Wollina U, Goldman A. Fillers for the improvement in acne scars. *Clin Cosmet Investig Dermatol*. 2015;29(8):493-499.
- Kim JS. Effects of injection depth and volume of stabilized hyaluronic acid in human dermis on skin texture, hydration, and thickness. *Arch Aesthetic Plast Surg*. 2014;20(2):97-103.
- Wu WT. Microbotox of the lower face and neck: evolution of a personal technique and its clinical effects. *Plast Reconstr Surg*. 2015;136(5 suppl):925-1005.
- Beer K. A single-center, open-label study on the use of injectable poly-L-lactic acid for the treatment of moderate to severe scarring from acne or varicella. *Dermatol Surg*. 2007;33(suppl 2):S159-S167.
- Sadove R. Injectable poly-L-lactic acid: a novel sculpting agent for the treatment of dermal fat atrophy after severe acne. *Aesthetic Plast Surg*. 2009;33(1):113-116.
- Kravvas G, Al-Niaimi F. A systematic review of treatments for acne scarring. Part 1: Non-energy-based techniques. *Scars Burn Heal*. 2017;3:1-17.
- Aalami Harandi S, Balighi K, Lajevardi V, Akbari E. Subcision-suction method: a new successful combination therapy in treatment of atrophic acne scars and other depressed scars. *J Eur Acad Dermatol Venereol*. 2011;25:92-99.
- Dierickx C, Larsson MK, Blomster S. Effectiveness and safety of acne scar treatment with nonanimal stabilized hyaluronic acid gel. *Dermatol Surg*. 2018;44:S10-S18.
- Micheels P, Sarazin D, Besse S, Sundaram H. A blanching technique for intradermal injection of the hyaluronic acid Belotero. *Plast Reconstr Surg*. 2013;132:59S-68S.
- Williams S, Tamburic S, Stensvik H, Weber M. Changes in skin physiology and clinical appearance after microdroplet placement of hyaluronic acid in aging hands. *J Cosmet Dermatol*. 2009;8:216-225.
- Distante F, Pagati BA. Stabilized hyaluronic acid of non-animal origin for rejuvenating the skin of the upper arm. *Dermatol Surg*. 2009;35:389-394.
- Reuther T, Bayrhammer J, Kerscher M. Effects of a three-session skin rejuvenation treatment using stabilized hyaluronic acid-based gel of non-animal origin on skin elasticity: a pilot study. *Arch Dermatol Res*. 2010;302:37-45.
- Hartmann V, Bachmann F, Plaschke M, Gottermeier T, Nast A, Rzany B. Hand augmentation with stabilized hyaluronic acid (Macrolane VRF20 and Restylane Vital[®], Restylane Vital Light[®]). *J Dtsch Dermatol Ges*. 2010;8(1):41-44.
- Landau M. Hyaluronic Acid "Skinboosters[®]" and Use of blunt injection microcannulas". *J Drugs Dermatol*. 2012;11(suppl 3):s41-43.
- Shah AR. Use of intradermal botulinum toxin to reduce sebum production and facial pore size. *J Drugs Dermatol*. 2008;7(9):847-850.
- Tchvialeva L, Zenga H, Markhvida I, McLean DI, Lui H, Lee TK. In: Campolo D, ed. *Skin Roughness Assessment, New Developments in Biomedical Engineering*. Rijeka, Croatia: IntechOpen. 2010:341-355.
- Jacob CI, Dover JS, Kamimer MS. Acne scarring: a classification system and review of treatment options. *J Am Acad Dermatol*. 2001;45(1):109-117.
- Alster TS, West TB. Treatment of scars: a review. *Ann Plast Surg*. 1997;39:418-432.
- Klapetek P, Necas D, Anderson C. Gwyddion user guide. Statistical Analysis. Chapter 4. Data Processing and Analysis. (<http://gwyddion.net/documentation/user-guide-en/statisticalanalysis.html>)
- Necas D, Klapetek P. One-dimensional autocorrelation and power spectrum density functions of irregular regions. *Ultramicroscopy*. 2013;124:13-19.
- Kim JS. Detailed sonographic anatomy of dorsal hand augmentation with hyaluronidase and calcium hydroxyapatite fillers. *Aesthet Surg J*. 2019;39(10):1096-1106.
- Micheels P, Besse S, Flynn TC, Sarazin D, Elbaz Y. Superficial dermal injection of hyaluronic acid soft tissue fillers: comparative ultrasound at the American Society for Dermatologic Surgery. *Dermatol Surg*. 2012;38:1162-1169.
- Wang F, Garza L, Kang S, et al. In vivo stimulation of de novo collagen production caused by cross-linked hyaluronic acid dermal filler injections in photodamaged human skin. *Arch Dermatol*. 2007;143(2):155-163.
- Tran C, Carraux P, Micheels P, Kaya G, Salomon D. In vivo bio-integration of three hyaluronic acid fillers in human skin: a histological study. *Dermatology*. 2014;228(1):47-54.
- Kim JS. Clinical Effects on Skin Texture and Hydration of the Face Using Microbotox and Microhyaluronic acid Intradermal injection using Xeobel hydrotoxin mixture for treatment dry skin. *Plast Reconstr Surg Glob Open*. 2018;6(11):e1935.
- Kim JS. Injection Method for Stabilized Hyaluronic Acid into Dermis using an Injector for Skin Revitalization and Radiance Hydration. Invention Patent application number 10-2015-0090707. The Korean Intellectual Property Office.
- Fabbrocini G, Annunziata MC, D'Arco V, et al. Acne scars: pathogenesis, classification and treatment. *Dermatol Res Pract*. 2010;2010:1-13.
- Rose AE, Goldberg DJ. Safety and efficacy of intradermal injection of botulinum toxin for the treatment of oily skin. *Dermatol Surg*. 2013;39(3pt1):443-448.
- Elridy AS, Zaki RGE, Elshinawy RF. Comparison of the Clinical Efficacy of Abobotulinumtoxin A (ABO) and Onabotulinumtoxin A (ONA) in the Treatment of Crow's Feet Wrinkles: A Split-Face Study. *Semin Ophthalmol*. 2018;33(6):739-747.
- Rystedt A, Swartling C, Färnstrand C, Naver H. Equipotent Concentrations of Botox[®] and Dysport[®] in the Treatment of Palmar Hyperhidrosis. *Acta Dermato Venereol*. 2008;88(5):458-461.
- Nestor MS, Ablon GR. Duration of action of abobotulinumtoxin and onabotulinumtoxin: a randomized, double-blind study using a contralateral frontalis model. *J Clin Aesthet Dermatol*. 2011;4(9):43-49.
- Postlethwaite AE, Seyer JM, Kang AH. Chemotactic attraction of human fibroblasts to type I, II, and III collagens and collagen-derived peptides. *Proc Natl Acad Sci U S A*. 1978;75(2):p871-875.

How to cite this article: Kim JS. Topographic computer analysis for acne scar treatment on face accompanying biopsy study after dermal injection of hydrotoxin mixture. *J Cosmet Dermatol*. 2021;20:75-83. <https://doi.org/10.1111/jocd.13462>