



Severe Epistaxis after Tissue Plasminogen Activator administration for Acute Ischemic Stroke in SARS-COV-2 Infection

Priyank Khandelwal^{1,2}, Enrique Martínez-Pías³, Ivo Bach², Tannavi Prakash^{1,2}, Machteld E. Hillen², Mario Martínez-Galdámez⁴, Juan F. Arenillas^{3,5}

Abstract:

Patients with COVID-19 may suffer from hemorrhagic complications. Our article highlights two cases of COVID-19-infected patients, who suffered severe epistaxis after initiation of intravenous recombinant tissue plasminogen activator (IV-rtPA) for acute ischemic stroke, followed by a sudden decline in their clinical status and ultimately leading to death within days. Given the global impact and mortality of COVID-19, it is essential to be aware of its unusual presentation and improve therapeutic strategies. We present two cases of individuals who suffered from a large vessel occlusion of and were candidates for both IV-rtPA and mechanical thrombectomy. They received IV-rtPA but had epistaxis so severe that they were not able to receive MT and died within the next few days. There are many potential mechanisms by which epistaxis can happen in an individual with COVID-19 who received IV-rtPA including invasion of the nasal mucosa and endothelium through angiotensin-converting enzyme 2 receptors by the virus. We also hypothesize that the coagulation abnormality seen in COVID-19 patients can be potentiated by the use of treatments such as IV-rtPA. We review these issues with a diagram illustrating the possible mechanisms.

Keywords:

Acute ischemic stroke, cerebral bleed, COVID-19, Epistaxis, intravenous recombinant tissue plasminogen activator, severe acute respiratory syndrome coronavirus 2

Introduction

Case 1

An 80-year-old male presented to the emergency room (ER) with sudden onset of global aphasia and hemiparesis, consistent with acute ischemic stroke (AIS). He had a known past medical history of essential hypertension (HTN) and dyslipidemia. Upon arrival, his blood pressure (BP) was 125/58 mmHg, heart rate (HR) 51 bpm, SpO₂ 97%, and temperature 36°C. The patient's neurological exam showed global aphasia, forced conjugate gaze deviation to the left, right hemianopia, right facial weakness, right hemiparesis, and

a National Institutes of Health Stroke Scale Score of 20. He had no cough, dyspnea, fever, chest pain, or catarrhal symptoms. He was in isolation at home and had no known close contact with COVID-19-positive individuals. Blood count, biochemical parameters, and coagulation profile were within normal range. Emergent noncontrast computed tomography (CT) of the brain and CT angiogram (CTA) of the head were performed. Brain CT did not show acute hemorrhage and the Alberta Stroke Program Early CT score (ASPECTS) was 10. CTA demonstrated occlusion of the M1 segment of the left middle cerebral artery (MCA) [Figure 1]. Electrocardiogram did

This is an open access journal, and articles are distributed under the terms of the Creative Commons Attribution-NonCommercial-ShareAlike 4.0 License, which allows others to remix, tweak, and build upon the work non-commercially, as long as appropriate credit is given and the new creations are licensed under the identical terms.

For reprints contact: WKHLRPMedknow_reprints@wolterskluwer.com

How to cite this article: Khandelwal P, Martínez-Pías E, Bach I, Prakash T, Hillen ME, Martínez-Galdámez M, *et al.* Severe epistaxis after tissue plasminogen activator administration for acute ischemic stroke in SARS-COV-2 Infection. *Brain Circ* 2021;7:135-8.

Departments of
¹Neurological Surgery and
²Neurology, Rutgers New
 Jersey Medical School,
 NJ, USA, ³Department
 of Neurology, Stroke
 Program, Hospital
 Clínico Universitario,
⁴Department of Radiology,
 Neuroradiology Unit,
 Hospital Clínico
 Universitario, Valladolid,
⁵Neurovascular Research
 Laboratory (i3), Instituto
 de Biología y Genética
 Molecular, Universidad
 de Valladolid, CSIC,
 Valladolid, Spain

Address for correspondence:

Dr. Priyank Khandelwal,
 90 Bergen Street,
 Suite 8100, Newark,
 NJ, 07103, USA.
 E-mail: pk544@njms.
 rutgers.edu

Submission: 16-02-2021
 Revised: 27-04-2021
 Accepted: 07-05-2021
 Published: 29-05-2021

not reveal an arrhythmia and upper chest CT and chest X-ray showed no signs of lung infiltration or pneumonia.

Given that the patient was within the therapeutic window for intravenous recombinant tissue plasminogen activator (IV-rtPA) and had no contraindications for thrombolytic use, decision was made to infuse a total of 70 mg (0.9 mg/kg total dose, 7 mg bolus plus 63 mg slow infusion) IV-rtPA over 1 h. The neurointerventional team was activated in parallel to evaluate the patient for mechanical thrombectomy (MT). The patient was transferred to the neuroradiology angiosuite in preparation for MT. In the angiosuite, approximately, 50 min after IV-rtPA bolus, he suddenly experienced severe epistaxis. Manual compression by the neurology team was unsuccessful. The otolaryngology department was consulted, and they were able to tamponade the bleeding source. However, the patient started to experience shortness of breath and his SpO₂ declined to 80%. Due to massive epistaxis and severe oxygen desaturation, MT was not performed.

A few hours later, reverse transcriptase-polymerase chain reaction (RT-PCR) assay of a nasopharyngeal and oropharyngeal sample taken on admission was positive for severe acute respiratory syndrome coronavirus 2 (SARS-CoV-2), and the patient was transferred to a multidisciplinary COVID-19 unit. During the following days, he had respiratory worsening, with bilateral infiltrates, compatible with COVID-19 pneumonia, on the

chest radiograph. Laboratory tests showed an increase in C-reactive protein (66.3 mg/L), interleukin 6 (23.8 pg/ml), and D-Dimer (2502), characteristic of systemic inflammation associated with COVID-19 disease. The patient's condition progressively worsened, and he died a few days later. Follow-up CT of the head was not performed before death.

Case 2

A 61-year-old female with diabetes mellitus Type 2, HTN (not on angiotensin-converting enzyme [ACE] inhibitor), chronic obstructive pulmonary disease (COPD) (on 2 L home oxygen and continuous positive airway pressure), obstructive sleep apnea, lung adenocarcinoma with resection in 2018, morbid obesity, and anxiety disorder presented to the ER with severe shortness of breath for 2 days. She denied any potential exposure to COVID-19 sick contacts. The patient was speaking in 3-word sentences and was tachypneic in the ER with a temperature of 37°C, HR 111, BP 118/78, respiratory rate of 26, and an oxygen saturation of 89% on room air. She was placed on a nonrebreather mask and her saturation improved to the low 90s. Her initial neurological examination was nonfocal.

The patient was admitted for the treatment of acute on chronic hypoxic respiratory failure with high suspicion of COVID-19. Later in the day, her SARS-CoV2 RT-PCR test was positive. She was started on hydroxychloroquine and zinc for treatment of COVID-19, as well as prednisone and furosemide to treat possible COPD exacerbation. Three days later, the patient had a sudden onset of right-sided weakness, right facial droop, sensory loss, global aphasia, and left-sided gaze preference suspicious for AIS due to MCA occlusion. CTA confirmed a distal left M1 segment occlusion. The chest X-ray showed patch infiltrates consistent with a viral pneumonia and no signs of aspiration. The patient was within window for IV-rtPA and a full-dose alteplase was administered (9 mg bolus and 81 mg infusion). The patient was simultaneously evaluated by the neurointerventional team for possible MT. Shortly after rtPA infusion, she experienced significant epistaxis from the right nare which was controlled with the administration of oxymetazoline and nasal packing by ENT. The maximum BP during the IV-rtPA infusion was 155/91. The patient's laboratory values including coagulation parameters, CBC, and metabolic panel were within normal limits. Her markers of inflammation including D-dimer (7955), ferritin (669), and lactate dehydrogenase (876) were elevated. She had been prescribed nasal ipratropium bromide and nasal saline mist in the 7 months before presentation for complaints of nasal irritation "from O₂ tubing." The patient's clinical status continued to worsen, and she was deemed unsuitable for MT. She died the next day. Follow-up CT of the head was not able to be performed.

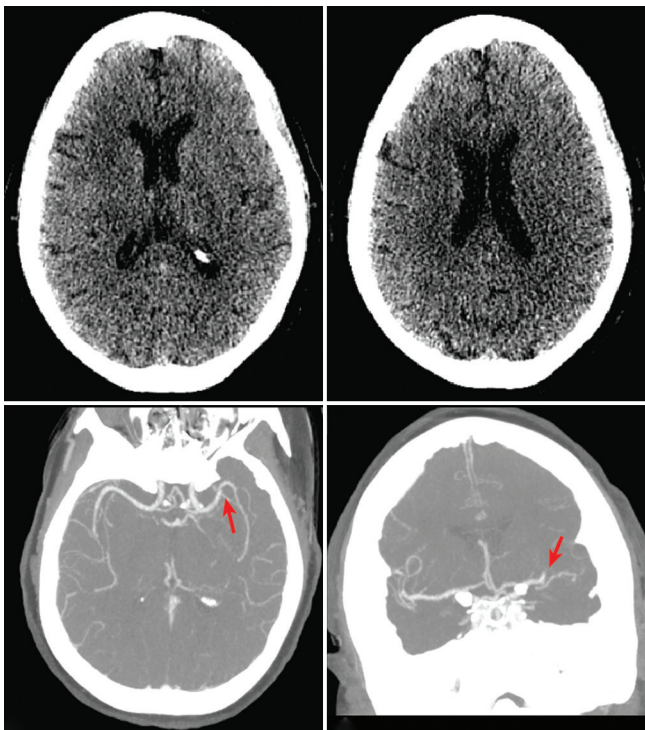


Figure 1: Noncontrast computed tomographic scan of patient one showing no early ischemic changes (panel a and b), consistent with Alberta Stroke Program Early CT

Discussion

Globally, there have been over 6 million cases of COVID-19 disease, an infectious respiratory disease caused by novel coronavirus, SARS-CoV-2. Although it has not been specifically studied, patients with COVID-19 may suffer from hemorrhagic complications.^[1,2] Our Article highlights two cases of COVID-19-infected patients, who suffered severe epistaxis after initiation of IV-rtPA for AIS, followed by a sudden decline in their clinical status and ultimately leading to death within days. Given the global impact and mortality of COVID-19, it is essential to be aware of its unusual presentation and improve therapeutic strategies.

A recent multicenter study showed that the incidence of AIS is 1.3% in COVID admitted patients, the majority due to large vessel occlusion.^[3] Initial report from Wuhan reported the incidence of AIS to be 5% among severely ill patients.^[4] The consensus statement from various societies

has suggested that the management of AIS in COVID-19 patients should be the same as in unaffected patients and should include the use of thrombolytic agents and/or MT with added measures to prevent transmission.^[5] Both our patients met criteria to administer IV-rtPA and received the recommended dose of IV-rtPA. Although thrombolytic agents improve the neurological outcomes in AIS patients, they can also result in serious adverse effects. The most dreaded adverse effects of IV-rtPA are symptomatic intracranial hemorrhage and major systemic bleeding which can occur in 3%–6% and 1.3% of AIS cases, respectively. Other infrequent side effects are anaphylaxis, angioedema, and epistaxis, which are noted in <1% of the cases.^[6,7] After a literature search, we have not found any similar cases of severe epistaxis following IV-rtPA administration in COVID-19-infected patients.

Epistaxis can be attributed to local and systemic etiologies. The most common local etiologies are trauma (be it digital or otherwise), local irritation to the nasal epithelium

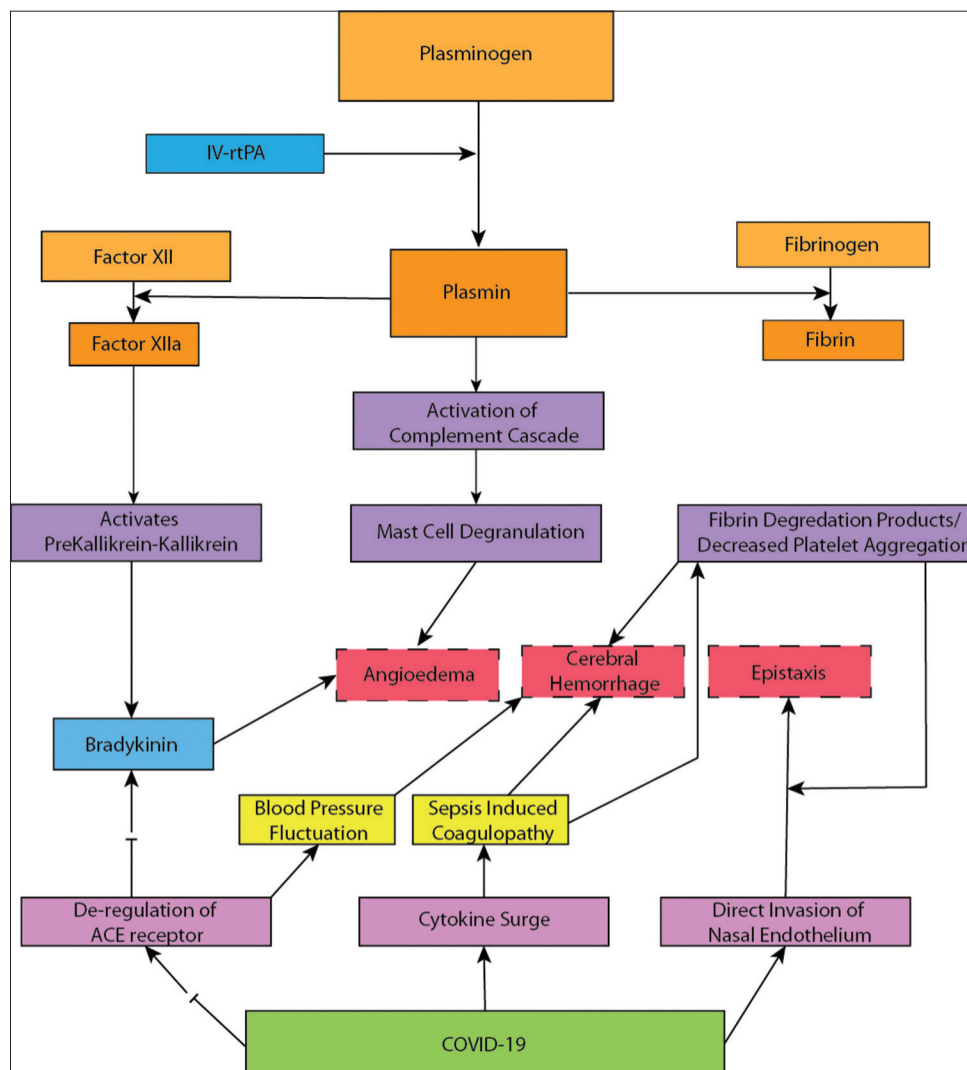


Figure 2: Potential pathways linking between COVID-19 disease and intravenous recombinant tissue plasminogen activator-related adverse effects

through nasal sprays, or dry air through a nasal cannula. Systemic etiologies include hypertension, aberrations in clotting ability, and inherited bleeding diathesis.^[8] One of the mechanisms by which SARS-COV-2 invades human tissue is by binding to the ACE2 receptors of vascular endothelium. Nasal epithelial cells express a large amount of ACE2, making the nasal cavity the main gateway for COVID-19 disease.^[9] Dysregulation of this enzyme could result in BP fluctuations and disruption of normal blood flow due to endothelial damage which promotes cerebral or systemic bleeding. In addition, dysregulation of the ACE-2 enzyme can also result in life-threatening angioedema in COVID-19 patients when receiving IV-rtPA, since angioedema is ACE2 mediated. Patients with COVID-19 can present with coagulation disorders such as thrombocytopenia, prolonged prothrombin, prolonged activated partial thromboplastin time, or disseminated intravascular coagulation with fibrinogen consumption.^[10] The mechanism of action of IV-rtPA is clot disruption through the degradation of plasminogen to plasmin, which in turn degrades fibrinogen to fibrin.^[7] We hypothesize that the coagulation abnormality seen in COVID-19 patients can be potentiated by the use of treatments such as IV-rtPA and may predispose patients to bleeding [Figure 2]. The fact that both of our cases had no significant coagulation abnormalities suggests that they presented early in their COVID-19 disease course. We postulate that the extensive epistaxis in both of our cases was triggered by the administration of IV-rtPA, in the setting of other risk factors such as COVID-19 invading the nasal mucosa, resulting in erosion of the endothelium, trauma to the nasal mucosa from sneezing, or dry air from the nasal cannula irritating the mucosa.^[11]

Conclusions

We describe two cases with severe epistaxis after using IV-rtPA for AIS. We do not know whether the bleeding is related to endothelium erosion by the virus, by local irritation or a combination of both, but the simultaneity in time of our two patients in different centers forces us to be cognizant about this rare complication in patients who are receiving IV-rtPA in the COVID-19 era. Patients with SARS-COV-2 infection could have an increased risk of systemic and intracranial bleeding, but more studies are needed to establish the underlying mechanisms and to establish a causal relationship.

Teaching points

1. It is largely unknown if COVID-19 disease leads to the impairment of bleeding diathesis, resulting in spontaneous bleeding and whether the use of medications such as IV-rtPA can potentiate the bleeding diathesis in these patients
2. Patients with COVID-19 and AIS should undergo standard diagnostic evaluation and treatment; however, clinicians should be aware of unusual complications such as epistaxis in COVID-19 patients receiving IV-rtPA.

Declaration of patient consent

The authors certify that they have obtained all appropriate patient consent forms. In the form, the patients have given their consent for their images and other clinical information to be reported in the journal. The patients understand that their names and initials will not be published and due efforts will be made to conceal their identity, but anonymity cannot be guaranteed.

Acknowledgment

Authors wish to acknowledge Dr. Shadi, Yaghi, MD, from NYU for his valuable input.

Financial support and sponsorship

Nil.

Conflicts of interest

Dr. Juan F. Arenillas is an Editorial Board member of Brain Circulation. The article was subject to the journal's standard procedures, with peer review handled independently of this Editorial Board member and their research groups.

References

1. Joob B, Wiwanitkit V. Hemorrhagic problem among the patients With COVID-19: Clinical summary of 41 Thai infected patients. *Clin Appl Thromb Hemost* 2020;26:1076029620918308.
2. Bargellini I, Cervelli R, Lunardi A, Scandiffio R, Daviddi F, Giorgi L, et al. Spontaneous bleedings in COVID-19 patients: An emerging complication. *Cardiovasc Intervent Radiol* 2020;43:1095-6.
3. Khandelwal P, Al Mufti F, Tiwari A, Ambooj T, Singla A, Dmytriw AA, et al. Incidence, characteristics and outcomes of large vessel stroke in COVID-19 cohort: A multicentric international study. *Neurosurgery* 2021;0:1-7.
4. Mao L, Jin H, Wang M, Hu Y, Chen S, He Q, et al. Neurologic manifestations of hospitalized patients with coronavirus disease 2019 in Wuhan, China. *JAMA Neurol* 2020;77:683-90.
5. Nguyen TN, Abdalkader M, Jovin TG, Nogueira RG, Jadhav AP, Haussen DC, et al. Mechanical thrombectomy in the era of the COVID-19 pandemic: Emergency preparedness for neuroscience teams: A guidance statement from the society of vascular and interventional neurology. *Stroke* 2020;51:1896-901.
6. Yaghi S, Boehme AK, Dibu J, Leon Guerrero CR, Ali S, Martin-Schild S, et al. Treatment and outcome of thrombolysis-related hemorrhage: A multicenter retrospective study. *JAMA Neurol* 2015;72:1451-7.
7. Matosevic B, Knoflach M, Werner P, Pechlaner R, Zangerle A, Ruecker M, et al. Fibrinogen degradation coagulopathy and bleeding complications after stroke thrombolysis. *Neurology* 2013;80:1216-24.
8. Fatakia A, Winters R, Amedee RG. Epistaxis: A common problem. *Ochsner J* 2010;10:176-8.
9. Sungnak W, Huang N, Bécavin C, Berg M, Queen R, Litvinukova M, et al. SARS-CoV-2 entry factors are highly expressed in nasal epithelial cells together with innate immune genes. *Nat Med* 2020;26:681-7.
10. Connors JM, Levy JH. Thromboinflammation and the hypercoagulability of COVID-19. *J Thromb Haemost* 2020;18:1559-61.
11. Dell'Era V, Dosdegani R, Valletti PA, Garzaro M. Epistaxis in hospitalized patients with COVID-19. *J Int Med Res* 2020;48:1-4