

Case Report

---

# Spontaneous Resolution of Macular Edema with Abnormal Vessel Crossing near the Central Macula by Congenital Retinal MacrovesSEL

Rina Okamoto<sup>a</sup> Kentaro Nishida<sup>b</sup> Chikako Hara<sup>b</sup> Taku Wakabayashi<sup>b</sup>  
Hirokazu Sakaguchi<sup>b, c</sup> Kohji Nishida<sup>b, d</sup>

<sup>a</sup>Department of Ophthalmology, Kaizuka City Hospital, Kaizuka, Japan; <sup>b</sup>Department of Ophthalmology, Osaka University Graduate School of Medicine, Suita, Japan; <sup>c</sup>Department of Ophthalmology, Gifu University Graduate School of Medicine, Gifu, Japan; <sup>d</sup>Integrated Frontier Research for Medical Science Division, Institute for Open and Transdisciplinary Research Initiatives (OTRI), Osaka University, Suita, Japan

## Keywords

Congenital retinal macrovesSEL · Fluorescein angiography · Macular edema · Multimodal imaging · Optical coherence tomography · Optical coherence tomography angiography

## Abstract

We present a case of a congenital retinal macrovesSEL (CRM) with spontaneous resolution of cystoid macular edema. A 39-year-old woman with sudden decreased vision in her right eye was referred to our clinic and found to have a CRM with macular edema. Her visual acuity was 20/25. A week later, the macular edema disappeared without any treatment, and her visual acuity was 20/15. We performed optical coherence tomography angiography and fluorescein angiography (FA), which revealed no obstruction of retinal flow but a slight disturbance of retinal flow near the central fovea on FA. We encountered a case of spontaneous resolution of macular edema with abnormal vessel crossing near the central macula by a CRM, and multimodal imaging was useful for investigating the pathology of the disease.

© 2022 The Author(s).  
Published by S. Karger AG, Basel

## Introduction

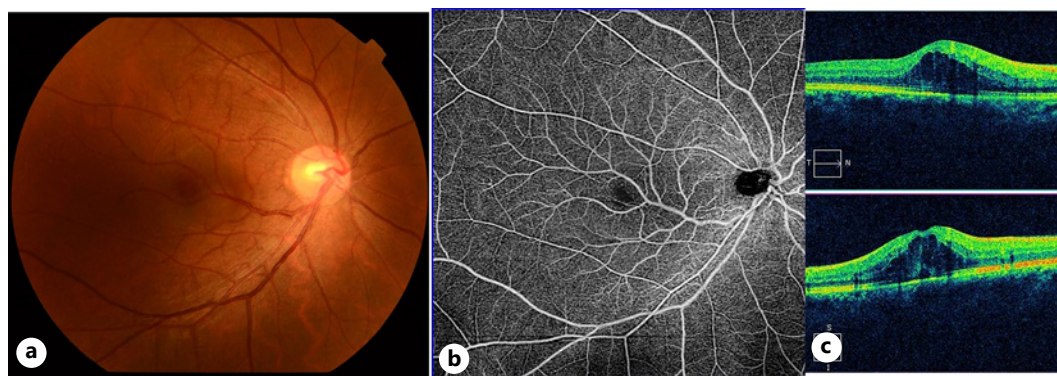
A congenital retinal macrovessel (CRM) is an abnormal vessel, typically a retinal vein, crossing the central macula above and below the horizontal raphe. This was first reported by Mauthner [1] in 1869. Later in 1982, Brown et al. [2] introduced the term “congenital retinal macrovessels” in a report of 7 cases of abnormal retinal vessels. The prevalence of CRMs is estimated at 1 in 200,000 in the USA [3]. However, this number could be an underestimation, since in most cases of CRMs, the patients have no specific symptoms, and in many cases, CRMs have been diagnosed incidentally during retinal examinations. Here, we present a case of spontaneous resolution of macular edema with abnormal vessel crossing near the central macula by a CRM.

## Case Presentation

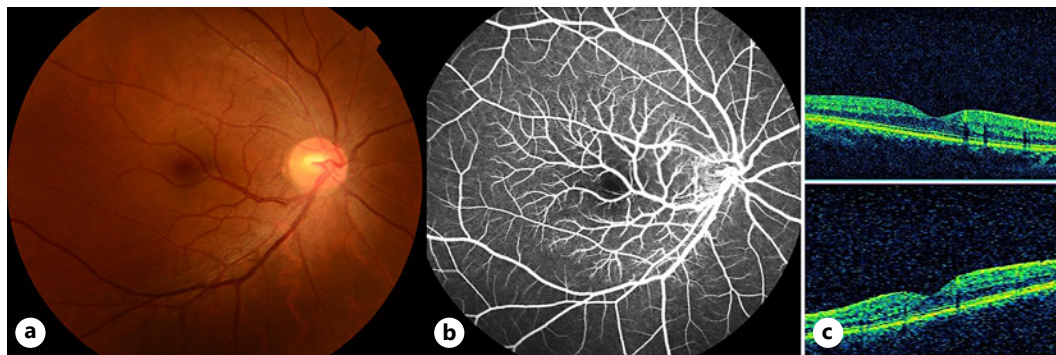
A 39-year-old Asian woman with sudden decreased vision in her right eye, who had experienced migraines for 20 years, presented to our clinic. The patient’s visual acuity was 20/25. The fundus showed abnormal vessel crossing at the central macula (Fig. 1a). Optical coherence tomography (OCT) showed macular edema, but OCT angiography showed no significant changes (Fig. 1b, c). A week later, the visual acuity improved to 20/15, and macular edema was not detected on OCT despite no treatment. Fluorescein angiography (FA) showed a branch from the macrovessel without leakage, blockage, or obstruction of retinal flow (Fig. 2b, c). We performed FA 15 months after her first visit, which showed the same findings as those obtained the first time. The visual acuity remained 20/20 throughout the course, and brain magnetic resonance imaging (MRI) showed no significant changes.

## Discussion

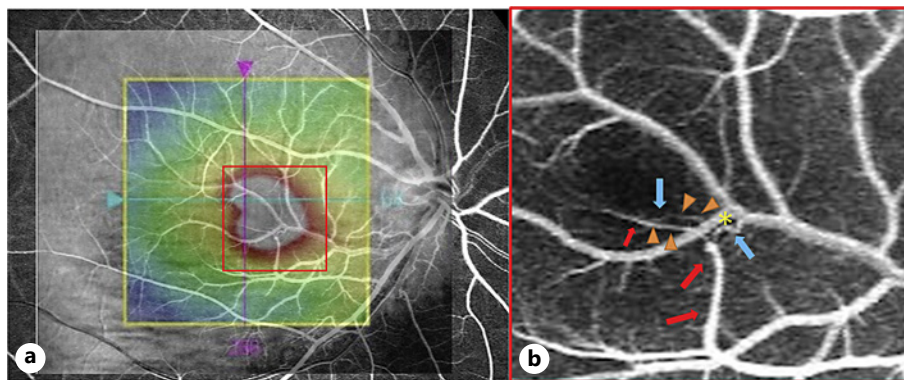
In most cases of CRMs, visual function is not affected, and the condition is incidentally found during routine retinal examinations. However, there are some reports of vision loss caused by macular hemorrhage [4], serous retinal detachment [5], macular edema [6], or branch vein occlusion [7]. In the present case, OCT showed macular edema at the first visit, which disappeared within a week without any treatment. FA showed a macrovessel crossing



**Fig. 1.** Color fundus photography (a) and OCT angiography (b) show a large macrovessel extending within the vascular arcade from an inferior nasal vein, crossing the central macula above the horizontal raphe. c Macula edema is detected on OCT. OCT, optical coherence tomography.



**Fig. 2.** Color fundus photography (a) and FA (b) a week later. FA shows a branch from the macrovessel without leakage, blockage, or obstruction of retinal flow. c OCT a week later shows resolution of cystoid macular edema. FA, fluorescein angiography; OCT, optical coherence tomography.



**Fig. 3.** a FA overlaid on OCT mapping. Macula edema on OCT corresponds to the area where the CRM crosses the fovea. b Macula edema area enlarged on FA. Vein branching from the CRM (blue arrow) and a retinal artery (red arrow) are crossing and compressed by the CRM (\*). Both vessels are narrowing after crossing the CRM (arrowhead). FA, fluorescein angiography; OCT, optical coherence tomography; CRM, congenital retinal macrovessel.

the retinal artery and another small branch originating from the macrovessel (Fig. 3). There seemed to be a slight disturbance of retinal artery flow compressed by a macrovessel based on FA (online suppl. Video 1; for all online suppl. material, see [www.karger.com/doi/10.1159/000524296](http://www.karger.com/doi/10.1159/000524296)).

We established two hypotheses to explain why the macula edema suddenly occurred and resolved spontaneously. One hypothesis involves the deterioration of the blood-retina barrier of the perifoveal capillary. According to previous reports [6–9], macular edema with CRMs may be caused by anomalies of the perifoveal capillary bed around the CRMs, which may have affected the blood-retina barrier of the perifoveal capillary for many years. In our case, there was an abnormal vessel crossing near the central macula, which may have caused deterioration of the blood-retina barrier of the perifoveal capillary and incidentally caused macular edema.

Another hypothesis involves the interruption of retinal vessel flow. Sanfilippo and Sarraf [7] identified an abnormally sheathed macrovessel showing macular edema and interruption of retinal vessel flow near the macula on FA, such as branch retinal vein occlusion, and macula edema resolved spontaneously 2 months later. In the present case, we did not detect interruption of any retinal vessel flow on OCTA when the patient was referred to our clinic because real-time

FA showed a slight disturbance of retinal flow compressed by the macrovessel even after resolution of macular edema. It is possible that an interruption in the perifoveal vessels caused the macula edema, which resolved spontaneously, as described in a previous report [7].

CRMs are strongly associated with venous abnormalities in the brain. They were first reported by Sanfilippo and Sarraf [7] in 2015. In 2018, Pichi et al. [10] reported that approximately 24% of CRM cases involved systemic vascular abnormalities on brain MRI. In the present case, the patient had a history of migraines but had no signs of abnormalities on brain MRI.

## Conclusion

We encountered a case of spontaneous resolution of macular edema with abnormal vessel crossing near the central macula by a CRM, and multimodal imaging was useful for investigating the pathology of the disease.

## Acknowledgment

Medical writing and editing support were provided by Editage.

## Statement of Ethics

Written informed consent was obtained from the patient for publication of this case report and any accompanying images. The study has been granted an exemption from requiring ethics approval by Osaka University Ethics Review Board.

## Conflict of Interest Statement

The authors have no conflicts of interest to declare.

## Funding Sources

This work was supported by JSPS KAKENHI Grant No. 18 K12142. The funders had no role in study design, data collection and analysis, decision to publish, or preparation of the manuscript.

## Author Contributions

Rina Okamoto, Kentaro Nishida, Taku Wakabayashi, and Kohji Nishida participated in drafting the manuscript. Kentaro Nishida, Chikako Hara, and Hirokazu Sakaguchi participated in the diagnosis and treatment of the patient.

## Data Availability Statement

All data generated or analyzed during this study are included in this article and its online supplementary material. Further inquiries can be directed to the corresponding author.

## References

- 1 Mauthner L. *Lehrbuch der Ophthalmoscopie*. Vienna: Tendler and Co.; 1869. p. 249.
- 2 Brown GC, Donoso LA, Magargal LE, Goldberg RE, Sarin LK. Congenital retinal macrovessels. *Arch Ophthalmol*. 1982;100:1430–6.
- 3 Petropoulos IK, Petkou D, Theoulakis PE, Kordelou A, Pournaras CJ, Katsimpris JM. Congenital retinal macrovessels: description of three cases and review of the literature. *Klin Monbl Augenheilkd*. 2008;225:469–72.
- 4 Sebrow DB, Cunha de Souza E, Belucio Neto J, Roizenblatt M, Zett Lobos C, Paulo Bonomo P, et al. Microaneurysms associated with congenital retinal macrovessels. *Retin Cases Brief Rep*. 2020;14:61–5.
- 5 Arai J, Kasuga Y, Koketsu M, Yoshimura N. Development and spontaneous resolution of serous retinal detachment in a patient with a congenital retinal macrovessel. *Retina*. 2000;20:674–6.
- 6 Ipek SC, Kavukcu S, Men S, Saatci AO. Multimodal imaging features of a spontaneously resolved unilateral congenital macrovessel-related macular edema in a 13-year-old boy. *GMS Ophthalmol Cases*. 2020;10:Doc40.
- 7 Sanfilippo CJ, Sarraf D. Congenital macrovessel associated with cystoid macular edema and an ipsilateral intracranial venous malformation. *Retin Cases Brief Rep*. 2015;9(4):357–9.
- 8 de Crecchio G, Alfieri MC, Cennamo G, Forte R. Congenital macular macrovessels. *Graefes Arch Clin Exp Ophthalmol*. 2006;244:1183–7.
- 9 de Crecchio G, Pappalardo G, Pascotto F, Forte R. Aberrant congenital macular vessel crossing the fovea: evaluation with optical coherence tomography. *Eye*. 2006;20:1464–6.
- 10 Pichi F, Freund KB, Ciardella A, Morara M, Abboud EB, Ghazi N, et al. Congenital retinal macrovessel and the association of retinal venous malformations with venous malformations of the brain. *JAMA Ophthalmol*. 2018;136:372–9.