



# Role of suprascapular nerve block in idiopathic frozen shoulder treatment: a clinical trial survey

Mohsen Mardani-Kivi<sup>1</sup>, Bahram Naderi Nabi<sup>2</sup>, Mir-Hashem Mousavi<sup>3</sup>, Ardeshir Shirangi<sup>3</sup>, Ehsan Kazemnejad Leili<sup>4</sup>, Zahra Haghparast Ghadim-Limudahi<sup>3</sup>

<sup>1</sup>Orthopaedic Research Center, Department of Orthopaedic, Poursina Hospital, School of Medicine, Guilan University of Medical Sciences, Rasht, Iran

<sup>2</sup>Anesthesiology Research Center, Department of Anesthesiology, Alzahra Hospital, Guilan University of Medical Sciences, Rasht, Iran

<sup>3</sup>Orthopaedic Research Center, Department of Orthopaedic, Poursina Hospital, School of Medicine, Guilan University of Medical Sciences, Rasht, Iran

<sup>4</sup>Department of Statistics, School of Health, Guilan University of Medical Sciences, Rasht, Iran

**Background:** Several therapeutic methods have been proposed for frozen shoulder syndrome. These include suprascapular nerve block, a simple and cost-effective technique that eliminates the need for nonsteroidal anti-inflammatory drug therapy.

**Methods:** This was a clinical trial that included patients with unilateral shoulder joint stiffness. Patients were divided into three groups: those treated with isolated physiotherapy for 12 weeks (PT group), those treated with a single dose intra-articular injection of corticosteroid together with physiotherapy (IACI group), and those treated with a suprascapular nerve block performed with a single indirect injection of 8-mL lidocaine HCL 1% and 2 mL (80 mg) methylprednisolone acetate together with physiotherapy (SSNB group). The variables assessed were age, sex, side of involvement, dominant limb, presence of diabetes, physical examination findings including erythema, swelling, and muscle wasting; palpation and movement findings; shoulder pain and disability index (SPADI) score; and the visual analog scale (VAS) score pre-intervention and at 2-, 4-, 6-, and 12-week post-intervention.

**Results:** Ninety-seven patients were included in this survey (34 cases in the PT group, 32 cases in the IACI group, and 31 cases in the SSNB group). Mean age was 48.55±11.06 years. Fifty-seven cases were female (58.8%) and 40 were male (41.2%). Sixty-eight patients had a history of diabetes (70.1%). VAS and SPADI scores and range of motion degrees dramatically improved in all cases ( $p<0.001$ ). Results were best in the SSNB group ( $p<0.001$ ), and the IACI group showed better results than the PT group ( $p<0.001$ ).

**Conclusions:** Suprascapular nerve block is an effective therapy with long-term pain relief and increased mobility of the shoulder joint in patients with adhesive capsulitis.

**Keywords:** Shoulder adhesive capsulitis; Frozen shoulder; Nerve block; Surgery; Shoulder

## INTRODUCTION

Adhesive shoulder capsulitis (frozen shoulder) is a disorder that

manifests as limitation of shoulder mobility and debilitating pain [1]. The condition was first diagnosed by Neviasser in 1945 [2], but the symptoms of this syndrome were identified in literature

Received: November 8, 2021    Revised: December 11, 2021    Accepted: December 20, 2021

Correspondence to: Zahra Haghparast Ghadim-Limudahi

Orthopaedic Research Center, Department of Orthopaedic, Poursina Hospital, School of Medicine, Guilan University of Medical Sciences, Parastar Ave., Rasht 4193713191, Iran

Tel: +98-1333311470, Fax: +98-1333339842, E-mail: Dr.zahra.haghparast@gmail.com, ORCID: <https://orcid.org/0000-0002-2073-113X>

**Financial support:** This study was supported by Guilan University of Medical Science.

**Conflict of interest:** None.

Copyright© 2022 Korean Shoulder and Elbow Society.

This is an Open Access article distributed under the terms of the Creative Commons Attribution Non-Commercial License (<http://creativecommons.org/licenses/by-nc/4.0/>) which permits unrestricted non-commercial use, distribution, and reproduction in any medium, provided the original work is properly cited.

long before that. Adhesive shoulder capsulitis is present in 2% to 5% of the general population and in 20% of diabetes mellitus patients [1,3]. This disorder has several causes; idiopathic causes, diabetes mellitus, trauma, and history of shoulder joint manipulation after surgery are highly prevalent causes [4]. The stages of disease development are: the painful stage, the freezing stage, the frozen stage, and the thawing stage. Despite the self-limiting nature of this condition, some patients may benefit from treatment to shorten the recovery period, relieve symptoms and reduce mobility limitations [5]. Various therapeutic methods have been introduced for frozen shoulder syndrome: non-surgical options including physiotherapy, oral anti-inflammatory drugs, intra-articular corticosteroid injections (IACI), hydrodilatation, and local nerve blocking. The proposed surgical treatments include manipulation under anesthesia and release of contractions by an open method or arthroscopy [4-6].

Physiotherapy is the cornerstone of frozen shoulder treatment; and researchers have determined this to be an effective therapeutic method, particularly when combined with IACI [7]. IACI have long been used for treating these patients to relieve intra-articular inflammation and for their antinociceptive effect [8]. The suprascapular nerve block (SSNB) is a new method for reducing shoulder pain, and its advantages and disadvantages have been assessed by various researchers [9-15]. The suprascapular nerve, including superior and posterior roots to the shoulder and acromioclavicular joints, provides 70% of shoulder joint sensory fibers. This nerve is also involved in transmission of motion branches to the supraspinatus and infraspinatus muscles [10].

Advantages of SSNB include its simplicity and cost-effectiveness [11,12]. This method has no complications associated with taking nonsteroidal anti-inflammatory drugs (NSAIDs) [13], but some studies have not yielded satisfactory SSNB results [14,15]. Given the relatively high prevalence of frozen shoulder syndrome, we decided to study the efficacy of physiotherapy in combination with SSNB or IACI and to compare results of these approaches. The intent of the present study was to assist orthopedic specialists in the treatment and control of symptoms of these patients to achieve improved quality of life by eliminating or reducing pain and improving range of shoulder motion.

## METHODS

This study was approved by a research ethics committee (ethical code: IR.GUMS.REC.1397.046) and received approval from the Iranian clinical trial (IRCT) system (IRCT code: IRCT20110809 007274N16). Informed consent was provided by all patients after the benefits and disadvantages of each treatment were explained,

and the consent for publication from the patient in the figure was obtained.

## Study Design

The present study was a non-blinded clinical trial in which the involved patients were referred to an orthopedic surgeon (first author) because of one-sided shoulder dryness and a frozen shoulder diagnosis. The inclusion criteria were persistence of symptoms including pain at rest and limitation of shoulder motion for at least three months (stages 1 and 2 of Kisner and Colby's classification system [6]) and restriction in forward flexion to less than 100° and reduction of external and internal rotation to less than 50% of the normal limit [16,17]. The exclusion criteria were (1) radiologic or magnetic resonance imaging diagnosis of shoulder pathologies such as degenerative joint disease and rotator cuff tear; (2) allergies to celecoxib or other NSAIDs; corticosteroids or lidocaine; (3) history of shoulder joint surgery or trauma; and (4) history of peri-articular, intra-articular or sub-acromial injection of the shoulder joint.

All patients received Celecoxib 200 mg BID (twice a day). The research group consisted of the physiotherapy (PT) group, the IACI group and the SSNB group. The PT group patients underwent 20 sessions of physiotherapy. The IACI group patients initially received a single intra-articular injection that contained 8cc of lidocaine HCL 1% and 2 mL (80 mg) of methylprednisolone acetate. The needle was inserted into the joint under ultrasound guidance 2 to 3 cm inferior and one centimeter medial to the posterolateral angle of acromion (Fig. 1). The patients then underwent 20 sessions of physiotherapy.

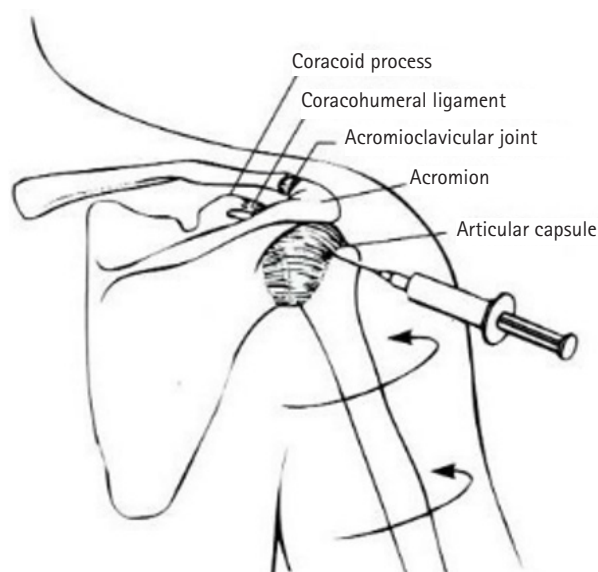


Fig. 1. Intra-articular corticosteroid injection.

The SSNB group patients first received an injection of 8-mL lidocaine HCL 1% and 2 mL (80 mg) of methylprednisolone acetate indirectly in the suprascapular nerve site under ultrasonographic guidance. While patients were in a prone position, a line was drawn along the scapular spine. Another perpendicular line was drawn passing from the inferior scapular angle. The injection site was determined to be 2 cm above and outside of the intersection of the two lines. The linear probe was placed transversely on the acromion and moved inward. The acoustic change was observed as the location of the v- or u-shaped notch after the end of ombre acoustique and bone acoustique of the acromion. Using enclosed hyperacoustic lines corresponding to the scapular transversal ligaments above and the scapular bone ecosystem below, we observed vessel pulses inside. Vessel site was verified by a color Doppler. The probe was maneuvered on the heel to facilitate visualization of the inside of the notch. We inserted the needle from the inside of the probe because the acromion prevented insertion from the outside. We aspirated the syringe before the injection to ensure that the injection was not intravascular. After this process, patients underwent 20 sessions of physiotherapy (Fig. 2).

### Physiotherapy Protocol

The physiotherapy protocol was identical for patients in all three groups, and all patients underwent 20 sessions. This protocol included: (1) treatment with infrared (IR) lights for twenty minutes in which an IR lamp was placed in a position where the patient felt warmth, approximately 50 cm from the shoulder; (2) treatment with a brief transcutaneous electrical neural stimulation (TENS) for 20 minutes in which four TENS electrodes were used on both sides of the shoulder with an applied frequency that varied from 3 to 120 Hz according to the patient's tolerance limit;

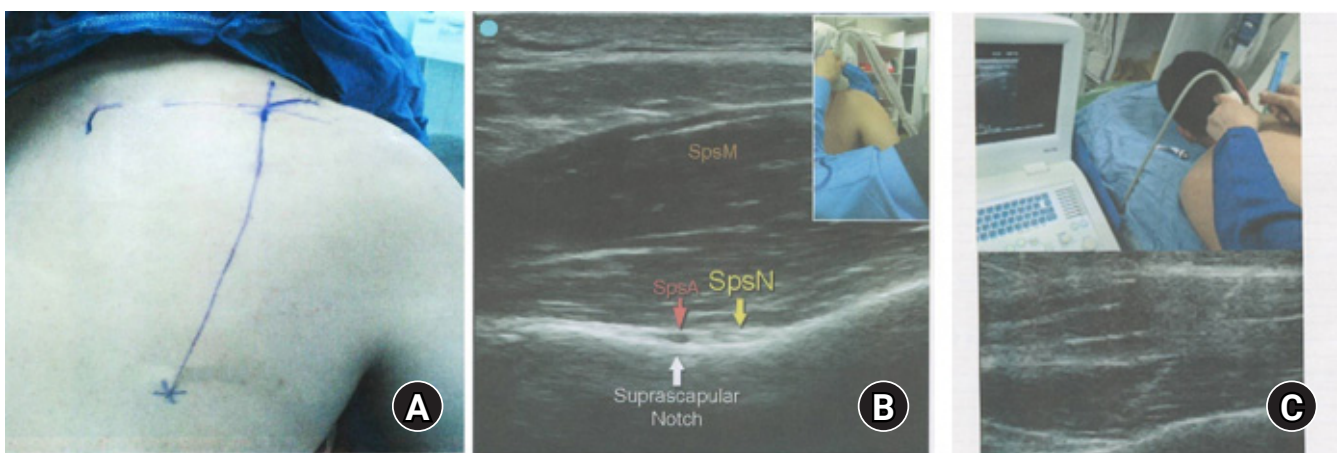
and (3) five types of shoulder muscle strengthening exercises twice daily from sessions 3 to 10.

### Data Collection

Demographic characteristics of the patients were recorded and consisted of age, sex, involved side, dominant limb, and presence of diabetes mellitus (patient was under drug treatment or had hemoglobin A1C rate of equal to or greater than 6.5%). The goniometric range of motion (ROM) was measured in the three groups in four states, abduction, flexion, internal rotation and external rotation, pre-intervention and at 2-, 4-, 6-, and 12-week post-intervention. The shoulder pain and disability index (SPADI) score has two sections for pain and disability. Each section receives a score of 0 to 100, and the mean of the two scores is the total score [18]. The visual analog scale (VAS) from 0 to 10 was utilized to evaluate the patients' pain. These tools were measured pre-treatment and at two, four, six, and 12 weeks post-treatment. Demographic characteristics and other research variables were statistically analyzed using IBM SPSS ver. 21.

### Statistical Analysis

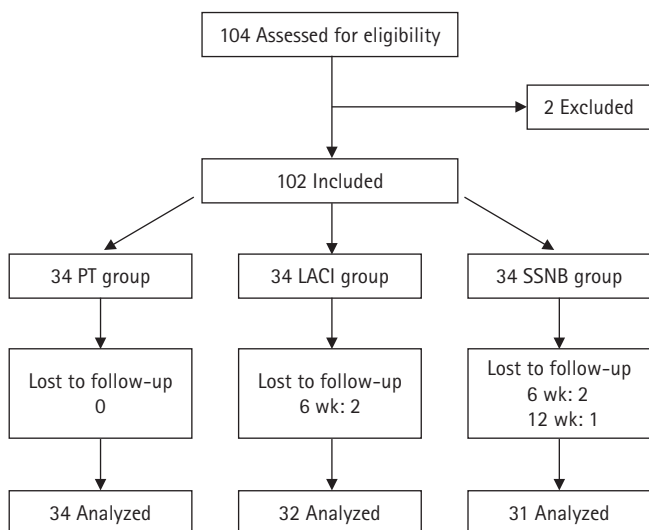
The sample size was 34 cases for comparing pain score at four follow-ups over 12 weeks in three groups based on the results of a study by Abdelshafi et al. [9]. The SPADI score with 95% confidence and 90% test power was used in a two-domain test for comparison of clinical differences with at least 10 pain scores between two treatment methods (34 patients per group). All data was statistically analyzed using a general linear model and repeated measure test. The significance level was  $p < 0.05$  in all tests. IBM SPSS ver. 21 (IBM Corp., Armonk, NY, USA) software was used to analyze the data.



**Fig. 2.** Suprascapular nerve block method. (A) Injection site. (B) Identify the suprascapular nerve with an ultrasound probe. (C) Perform the injection under an ultrasound guide. SpsM: supraspinatus muscle, SpsA: suprascapular artery, SpsN: suprascapular nerve.

## RESULTS

Initially, 104 patients were considered, and 102 met the inclusion criteria. These 102 patients were divided into 3 groups based on the random block method using 29 blocks of 6 sequences. Five patients (two IACI group cases and three SSNB group cases) were excluded from the study due to non-participation in fol-



**Fig. 3.** Flowchart. PT: physiotherapy, IACI: intra-articular corticosteroid injections, SSNB: suprascapular nerve block.

low-up. Therefore, data from 97 patients were analyzed: 34 patients in the PT group, 32 patients in the IACI group and 31 patients in the SSNB group (Fig. 3).

The mean age of patients was  $48.55 \pm 11.06$  years. The youngest patient was 35 years old and the oldest was 71. The highest number of patients (35.1%) was in the age group of 35 to 45 years. Fifty-seven patients were women (58.8%), and 40 were male (41.2%). 75.3% of patients ( $n=73$ ) were right-handed and 68% of cases ( $n=66$ ) had a right limb affected. Sixty-eight patients (70.1%) had a history of diabetes mellitus. Demographic characteristics did not significantly differ among the three study groups, and samples were uniformly distributed in the three groups (Table 1). Table 2 shows the signs and symptoms before interventions. These findings indicate no significant differences among the three groups before intervention. Table 3 and Fig. 4 show the ROM results in patients before and after the intervention according to measurement time.

The mean abduction before intervention in the PT, IACI and SSNB groups were  $75.4^\circ \pm 2.2^\circ$ ,  $76.3^\circ \pm 2.4^\circ$ , and  $74.5^\circ \pm 2.4^\circ$ , respectively. These were in the same clinical range. After the intervention, the abduction ROM dramatically increased in the SSNB group and reached  $110.6^\circ \pm 4.9^\circ$  after 12 weeks. The PT group reached  $87.3^\circ \pm 3^\circ$ , and the IACI group reached  $96.9^\circ \pm 5.6^\circ$ . The results depicted in Table 3 and Fig. 4D show that the increases in

**Table 1.** Demographic features of patients

Variable	PT group	IACI group	SSNB group	p-value
Age group (yr)				0.984
< 35	0	0	0	
35–45	12 (35.3)	12 (37.5)	10 (32.3)	
46–55	10 (29.4)	8 (25)	11 (35.5)	
56–65	7 (20.6)	8 (25)	6 (19.4)	
> 65	5 (14.7)	4 (12.5)	4 (12.9)	
Mean age (yr)	$49.20 \pm 11.77$	$47.75 \pm 10.95$	$48.57 \pm 10.66$	0.859
Sex				0.921
Male	14 (41.2)	14 (43.8)	12 (38.7)	
Female	20 (58.8)	18 (56.3)	19 (61.3)	
Dominant limb				0.860
Right	26 (76.5)	23 (71.9)	24 (77.4)	
Left	8 (23.5)	9 (28.1)	7 (22.6)	
Involved side				0.900
Right	23 (67.6)	21 (65.6)	22 (71)	
Left	11 (32.4)	11 (34.4)	9 (29)	
Diabetes mellitus				0.979
Yes	24 (70.6)	22 (68.8)	22 (71)	
No	10 (29.4)	10 (31.3)	9 (29)	

Values are presented as number (%) or mean±standard deviation.

PT: physiotherapy, IACI: intra-articular corticosteroid injections, SSNB: suprascapular nerve block.

**Table 2.** Physical examinations before intervention

Variable	PT group	IACI group	SSNB group	p-value
Erythema	2 (5.9)	0	1 (3.2)	0.649
Swelling	3 (8.8)	0	3 (9.7)	0.211
Muscle degeneration	10 (29.4)	6 (18.8)	5 (16.1)	0.413
Tenderness	23 (67.6)	24 (75)	20 (64.5)	0.650
Crepitus	11 (32.4)	7 (21.9)	8 (25.8)	0.626
Painful motion	25 (73.5)	24 (75)	20 (64.5)	0.642

Values are presented as number (%).

PT: physiotherapy, IACI: intra-articular corticosteroid injections, SSNB: suprascapular nerve block.

**Table 3.** Range of motion in the three study groups before intervention and at times of follow-up

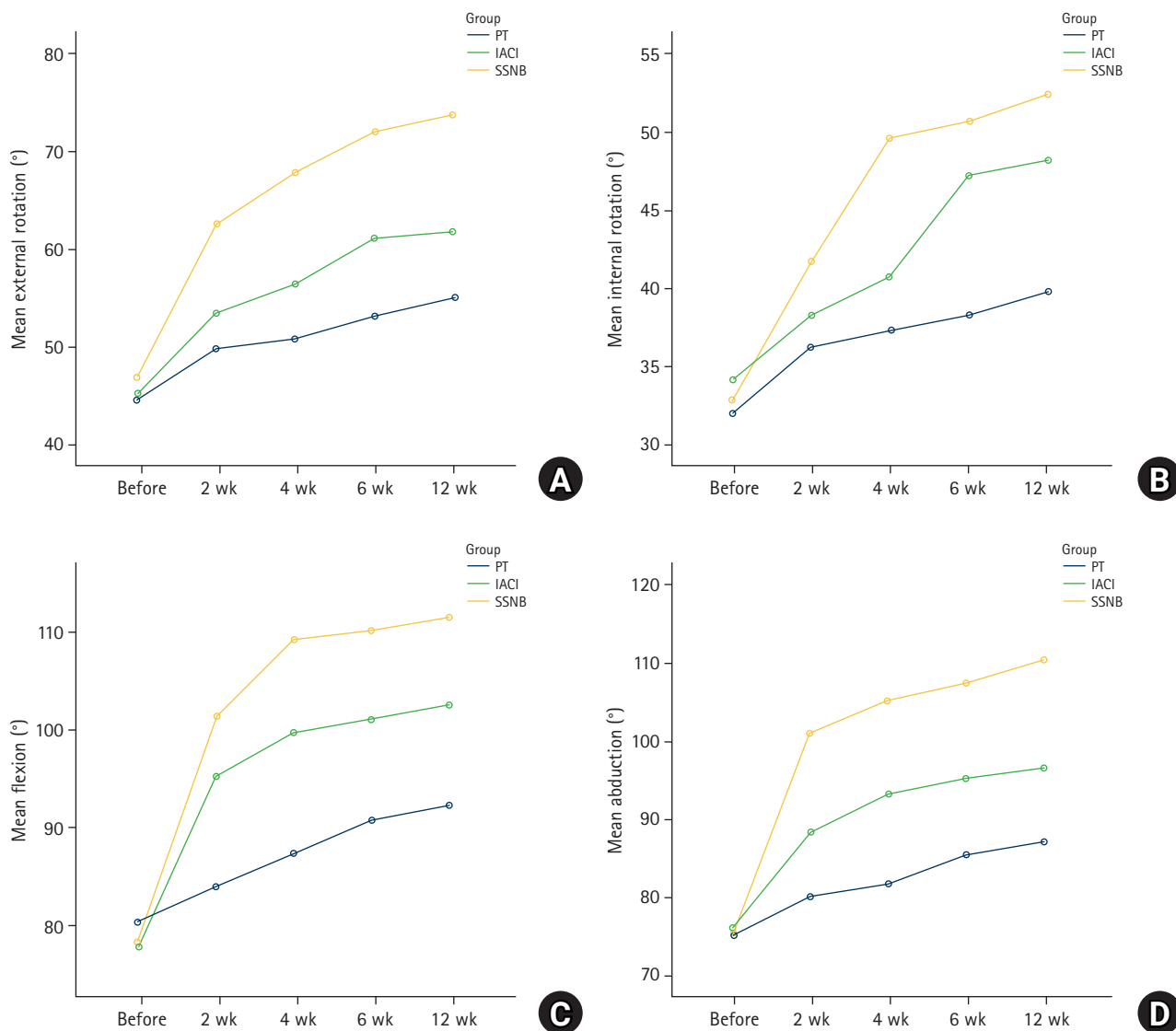
Variable	PT group	IACI group	SSNB group	p-value
<b>Abduction (°)</b>				
Before	75.4 ± 2.2	76.3 ± 2.4	74.5 ± 2.4	0.009
After 2 wk	80.1 ± 3.7	88.5 ± 3.2	101.2 ± 6.5	0.001
After 4 wk	81.8 ± 3.5	93.4 ± 4.5	105.3 ± 6.1	0.001
After 6 wk	85.7 ± 2.9	95.4 ± 5.7	107.6 ± 5.5	0.001
After 12 wk	87.3 ± 3.0	96.9 ± 5.6	110.6 ± 4.9	0.001
p-value	p <sub>time</sub> < 0.001, p <sub>group</sub> < 0.001, p <sub>int.time × group</sub> < 0.001			Power = 0.999, partial ETA score = 0.641
<b>Flexion (°)</b>				
Before	80.5 ± 3.8	77.9 ± 3.8	78.5 ± 4.5	0.026
After 2 wk	83.9 ± 4.5	95.3 ± 4.4	101.4 ± 5.6	0.001
After 4 wk	87.4 ± 3.3	99.7 ± 5.9	109.3 ± 5.7	0.001
After 6 wk	90.7 ± 4.2	101.1 ± 6.3	110.2 ± 4.9	0.001
After 12 wk	92.4 ± 4.7	102.6 ± 6.5	111.5 ± 4.3	0.001
p-value	p <sub>time</sub> < 0.001, p <sub>group</sub> < 0.001, p <sub>int.time × group</sub> < 0.001			Power = 0.999, partial ETA score = 0.543
<b>External rotation (°)</b>				
Before	44.6 ± 3.1	45.2 ± 4.0	46.9 ± 4.2	0.047
After 2 wk	49.8 ± 3.6	53.5 ± 3.6	62.7 ± 3.5	0.001
After 4 wk	51.0 ± 3.2	56.5 ± 3.5	67.9 ± 4.7	0.001
After 6 wk	53.2 ± 4.1	61.1 ± 3.7	72.1 ± 4.6	0.001
After 12 wk	55.1 ± 3.9	61.8 ± 3.4	73.6 ± 4.5	0.001
p-value	p <sub>time</sub> < 0.001, p <sub>group</sub> < 0.001, p <sub>int.time × group</sub> < 0.001			Power = 0.999, partial ETA score = 0.540
<b>Internal rotation (°)</b>				
Before	32.0 ± 4.6	34.2 ± 4.6	32.9 ± 4.9	0.146
After 2 wk	36.2 ± 4.2	38.3 ± 4.6	41.7 ± 5.0	0.001
After 4 wk	37.4 ± 4.6	40.8 ± 4.5	49.5 ± 4.9	0.001
After 6 wk	38.4 ± 4.9	47.3 ± 5.0	50.7 ± 4.4	0.001
After 12 wk	39.8 ± 4.7	48.3 ± 4.5	53.4 ± 4.7	0.001
p-value	p <sub>time</sub> < 0.001, p <sub>group</sub> < 0.001, p <sub>int.time × group</sub> < 0.001			Power = 0.999, partial ETA score = 0.113

Values are presented as mean ± standard deviation.

PT: physiotherapy, IACI: intra-articular corticosteroid injections, SSNB: suprascapular nerve block, int: interaction, ETA: estimated time of arrival.

ROM were statistically significant over time in all three groups (p < 0.001 in all cases). However, the increase seen in the SSNB group was significantly greater than the other two groups (p < 0.001). Furthermore, the slope of increasing abduction ROM in the SSNB group was steeper than the other two groups pre-intervention and 4 weeks after intervention (time and group inter-

action) (p < 0.001) (power = 0.999, partial estimated time of arrival [ETA] score = 0.641). The mean flexion before intervention was 80.5° ± 3.8°, 77.9° ± 3.8°, and 78.5° ± 4.5° in the PT, IACI and SSNB groups, respectively. These were in the same clinical range. After the intervention, the flexion ROM increased dramatically in the SSNB group, eventually reaching 111.5° ± 4.3° after 12



**Fig. 4.** Distribution of different degrees of range of motion (ROM) in patients in the three study groups divided by measurement times. (A) External rotation. (B) Internal rotation. (C) Flexion. (D) Abduction. PT: physiotherapy, IACI: intra-articular corticosteroid injections, SSNB: suprascapular nerve block.

weeks. The IACI group reached  $102.6 \pm 6.5^\circ$ , and the PT group reached  $92.4 \pm 4.7^\circ$ . As shown in Table 3 and Fig. 4C, while these increases were all statistically significant ( $p < 0.001$  in all cases), the SSNB group increase was greatest ( $p < 0.001$ ). Furthermore, the slope of increasing flexion ROM in the SSNB group was steeper than the other two groups before and 4 weeks after intervention (time and group interaction,  $p < 0.001$ ) (power = 0.999, partial ETA score = 0.543).

The mean external rotation was  $44.6 \pm 3.1^\circ$ ,  $45.2 \pm 4.0^\circ$ , and  $46.9 \pm 4.2^\circ$  before the intervention in the PT, IACI and SSNB groups, respectively; these were in the same clinical range. After the intervention, the ROM of external rotation dramatically increased in the SSNB group and reached  $73.6 \pm 4.5^\circ$  after 12 weeks.

This value was  $61.8 \pm 3.4^\circ$  in the IACI group and  $55.1 \pm 3.9^\circ$  in the PT group. According to the results shown in Table 3 and Fig. 4A, all three groups experienced increases ( $p < 0.001$  in all cases), but the SSNB group increase was greatest ( $p < 0.001$ ). Furthermore, the slope of increasing the ROM of external rotation in the SSNB group was steeper than the other two groups before and 4 weeks after the intervention (time and group interaction,  $p < 0.001$ ) (power = 0.999, partial ETA score = 0.540).

The mean internal rotation was  $32.0 \pm 4.6^\circ$ ,  $34.2 \pm 4.6^\circ$ , and  $32.9 \pm 4.9^\circ$  in the PT, IACI and SSNB groups, respectively, before the intervention; these were not significantly different ( $p = 0.164$ ). After the intervention, the ROM of internal rotation dramatically increased in the SSNB group and reached  $53.4 \pm 4.7^\circ$  after

12 weeks. This value was  $48.3^{\circ} \pm 4.4^{\circ}$  in the IACI group and  $39.8^{\circ} \pm 4.7^{\circ}$  in the PT group. As shown in Table 3 and Fig. 4B, all of these values were statistically significant ( $p < 0.001$ ), but the SSNB group increase was greatest ( $p < 0.001$ ). Furthermore, the slope of ROM of internal rotation in the SSNB group was steeper than the other two groups before and 4 weeks after the intervention (time and group interaction) ( $p < 0.001$ ) (power = 0.999, partial ETA score = 0.113).

For comparing SPADI scores, the data in Table 4 and Fig. 5 show that mean scores were approximately equal in the three groups before the intervention ( $p = 0.689$ ). Over time, the mean scores of all three groups significantly decreased ( $p < 0.001$  in all cases) based on the repeated measure analysis. However, the reduction was greater in the SSNB group than the other protocols, especially before and until the second week of intervention. The mean decreased in the SSNB group from  $78.21^{\circ} \pm 2.67^{\circ}$  to  $55.77^{\circ} \pm 3.35^{\circ}$  over a 2-week period. Generally, the mean score of the SSNB protocol was less than other groups (effect of group,  $p < 0.001$ ). Furthermore, the decreasing trend of three groups was significant during the research period (interaction of time and group,  $p < 0.001$ ). Based on mean scores, the reduction changes were different in the three groups until 4 weeks but were the same after 4 weeks ( $p < 0.001$ ) (power = 0.999, partial ETA score = 0.503) (Table 4, Fig. 5).

Table 5 compares VAS scores divided by measurement times for the three protocols. Initial mean and standard deviation of VAS scores were approximately equal:  $9.4 \pm 0.7$  in the PT group,  $9.3 \pm 0.8$  in the IACI group, and  $9.4 \pm 0.6$  in the SSNB group. The differences were statistically insignificant ( $p = 0.967$ ). However, these scores were significantly different in the three groups at 2 weeks ( $p < 0.001$ ), 4 weeks ( $p < 0.001$ ), 6 weeks ( $p < 0.001$ ) and 12 weeks ( $p < 0.001$ ). Mean scores of patients' pain was lower in the SSNB group than the other two groups at all time intervals ( $p < 0.001$  in all cases).

As depicted in Table 5, the reduction of pain scores was also significant among the three groups during the measurement

times (interaction of time) ( $p < 0.001$ ); but the pain score reduction slope in the SSNB group was greater than other two groups. As shown in Fig. 6, the pain score was significant in the SSNB group compared to the reference line (global mean), but the other two methods did not reach the statistically significant level compared to the reference line at 2 weeks.

## DISCUSSION

The present study compared three therapeutic approaches, SSNB, IACI and PT, in patients with adhesive shoulder capsulitis. The age of those with adhesive shoulder capsulitis was 40–60 years; those outside this age range were workers who worked more with their hands [19]. Our study's average age was 49 years; this was consistent with other similar studies [19,20]. According to available sources, adhesive shoulder capsulitis is more prevalent in women with an approximate ratio of 2 to 1 [19]; the same approximate ratio existed in the population of the present study (60% female and 40% male).

According to a meta-analysis in 2016, 30% of patients with ad-

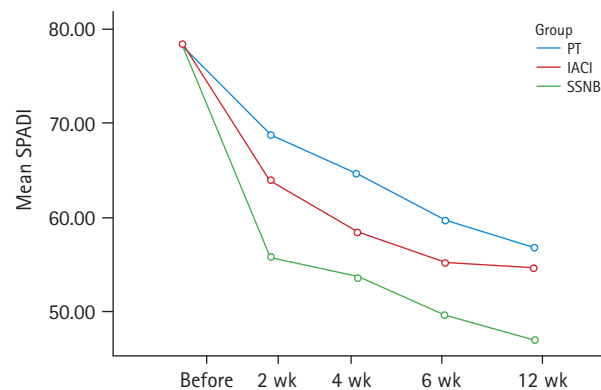


Fig. 5. Distribution of different degrees of shoulder pain and disability index (SPADI) in patients of the three groups divided by the time measurement. PT: physiotherapy, IACI: intra-articular corticosteroid injections, SSNB: suprascapular nerve block.

Table 4. Distribution of different SPADI scores in patients of the three groups divided by the measurement time

SPADI score	PT group	IACI group	SSNB group	p-value
Before	77.93 ± 2.07	78.42 ± 2.56	78.21 ± 2.67	0.689
After 2 wk	68.72 ± 3.0	63.73 ± 4.07	55.77 ± 3.35	0.001
After 4 wk	64.53 ± 3.57	58.30 ± 4.32	53.58 ± 3.62	0.001
After 6 wk	59.65 ± 3.53	55.22 ± 3.95	49.45 ± 4.05	0.001
After 12 wk	56.87 ± 3.09	54.59 ± 3.89	46.81 ± 3.57	0.001
p-value	$P_{\text{time}} < 0.001, P_{\text{group}} < 0.001, P_{\text{int.time} \times \text{group}} < 0.001$			Power = 0.999, partial ETA score = 0.502

Values are presented as mean ± standard deviation.

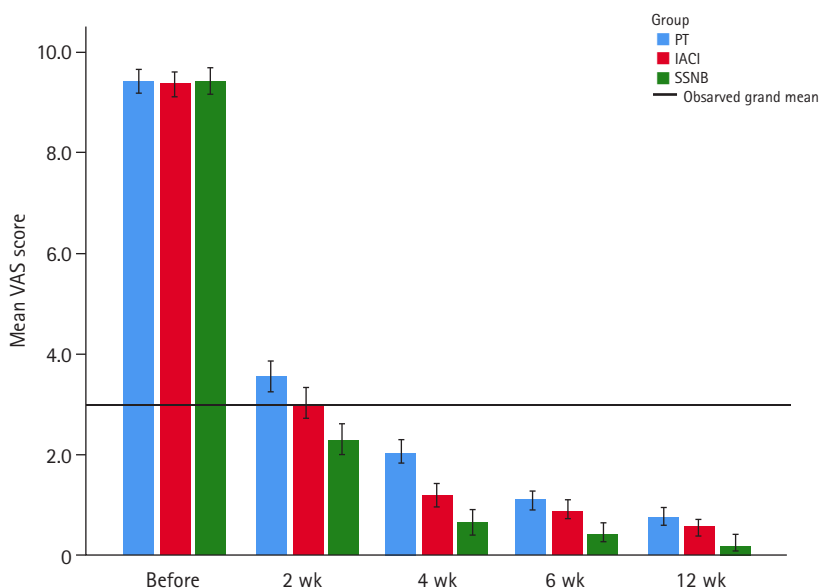
SPADI: shoulder pain and disability index; PT: physiotherapy, IACI: intra-articular corticosteroid injections, SSNB: suprascapular nerve block, int: interaction, ETA: estimated time of arrival.

**Table 5.** Distribution of different scores of VAS in patients of three groups divided by measurement times

VAS score	PT group	IACI group	SSNB group	p-value
Before	9.4 ± 0.7	9.3 ± 0.8	9.4 ± 0.6	0.967
After 2 wk	3.6 ± 0.9	3.0 ± 0.9	2.3 ± 0.9	0.001
After 4 wk	2.1 ± 0.8	1.2 ± 0.6	0.6 ± 0.6	0.001
After 6 wk	1.1 ± 0.5	0.9 ± 0.6	0.5 ± 0.5	0.001
After 12 wk	0.8 ± 0.5	0.5 ± 0.5	0.2 ± 0.4	0.001
p-value	P <sub>time</sub> < 0.001, P <sub>group</sub> < 0.001, P <sub>int.time × group</sub> < 0.001			Power = 0.999; partial ETA score, 0.132

Values are presented as mean ± standard deviation.

VAS: visual analog scale, PT: physiotherapy, IACI: intra-articular corticosteroid injections, SSNB: suprascapular nerve block, int: interaction, ETA: estimated time of arrival.



**Fig. 6.** Distribution of different degrees of visual analog scale (VAS) score in patients of the three groups divided by measurement times. PT: physiotherapy, IACI: intra-articular corticosteroid injections, SSNB: suprascapular nerve block.

hesive shoulder capsulitis had diabetes mellitus. Patients with diabetes mellitus were five times more likely to have frozen shoulder syndrome than others, and treatment was less effective in those with diabetes mellitus. The study provided several hypotheses about tissue changes that occur with diabetes that might be the causes of the greater incidence. For instance, the hypotheses such as inflammatory and fibrous reactions or bond of glucose molecules with collagen and its abnormal deposition in articular cartilage and shoulder tendons were put forth. Diabetes was found in 70.6% of our study patients, a higher percentage than the study cited above. This difference could be due to our inclusion criteria as we omitted post-surgical and post-traumatic cases. Other studies analyzing idiopathic frozen shoulder have data similar to ours [15,19].

There were no significant pre-intervention differences in clinical findings of our patients, and all patients had the same range

of symptoms (stages 1 and 2 of Kisner and Colby’s classification system). After the therapeutic intervention, our findings indicated that the ROM and number of VAS and SPADI tools were clearly beneficial for recovery after intervention, and this recovery was stronger in the SSNB group than the other two groups. IACI was also more effective than physiotherapy alone. Furthermore, scores were dramatically improved in all patients after 2 weeks of treatment. Patients mentioned that their pain was clearly reduced, and the return to daily activities was significant in most of them.

There are several studies that have reported satisfactory results with SSNB. Abdelshafi et al. [9] studied patients with chronic shoulder pain and reported that SSNB along with the physiotherapy was effective in relieving patients’ pain. The value of the SPADI tool and results of ROM tests were much better than in those who underwent IACI with physiotherapy or physiotherapy alone.



This effect remained until 12 weeks after the injection and was not short-term. In another review, Shanahan et al. [21] found a significant improvement in SPADI scores in two-thirds of patients who were treated with the SSNB method. In this study, a single injectable dose of 10 ml of bupivacaine 5% and 40 mg of methylprednisolone was used. Jones and Chattopadhyay [22] also stated that adhesive shoulder capsulitis patients who were treated with the SSNB method had faster and more durable effects than those treated with IACI.

Various studies have introduced different methods for SSNB injection [21,23,24]. In the present study, the SSNB method included a single injection of lidocaine and methylprednisolone acetate that was indirectly under sonographic guide in the suprascapular nerve site. This method is a safe approach and can have minimal complications if performed by an experienced individual with an accurate determination of the injection site using anatomical landmarks [10]. Complications such as pneumothorax are rare in this method (less than 1%) [25]. There were no pneumothorax cases in the present study.

The mechanism of the SSNB effect has not been precisely specified. The suprascapular nerve provides 70% of shoulder joint sensory fibers, and its block definitely affects pain relief. Due to decreased pain, patients have better tolerance for physiotherapy and, therefore, better results. However, we know the direct effect of lidocaine is limited to hours or a few days; hence, this block will certainly affect the underlying disease pathology.

Several mechanisms have been proposed in various papers: (1) Reducing the central sensitivity of the posterior horn of nociceptive neurons (wind down) after the drop-in input impulses of peripheral nociceptive neurons [26]. (2) Longer effect due to the reduction in P substance and nerve growth factor after the block implementation in the synovium and efferent nerve fibers of the glenohumeral joint [27].

Three-direct infiltration of supraspinatus muscle and block of nerve fibers feeding this muscle as well as possible block of infraspinatus muscle (downstream) [21]. The suprascapular nerve is aligned with the omohyoid muscle, passes under the trapezius muscle and is located in the suprascapular notch after passing through the transverse scapular ligament. This notch is on the top of the scapula and on the inner side of the coracoid process. The nerve passes the top of the notch with the artery and suprascapular vein [10]. The best control of pain occurs when the pre-nerve block is applied to these articular branches of the nerve [23]. The most appropriate point is around the suprascapular notch in which the nerve can be easily localized [28]. In the present study, the injection was performed in the same point under the sonographic guide. The intra-tissue injection creates a hy-

poechoic image and its distribution site is visible by ultrasound. Therefore, the drug can be accurately injected in a target site using the ultrasound. Furthermore, intravascular injection is also prevented and the likelihood of systemic toxicity due to anesthetic drugs is decreased. The benefits of ultrasound-mediated peripheral nerve block include better localization of the nerve resulting in less time required for blocking, less volume of drug required, the provision of a visible method and site for topical anesthetics, lower toxicity risk with topical anesthetics, faster start to treatment effects, more complete nerve block, longer period of sensory and motor nerve blocks, fewer complications and greater patient satisfaction [9]. Noteworthy is the fact that the failure of the block is an important complication because the patient tolerates needle entry and movement complications. The patient should undergo general anesthesia and systemic drug administration which are not required in a regional block [27].

IACI under a sonographic guide was another method used in the present study. In a meta-analysis by Koh [29] of several previous clinical trials, IACI injection was found to be an appropriate and effective approach for the treatment of frozen shoulder with both favorable short- and mid-term results. As mentioned earlier, the incidence of frozen shoulder is directly related to diabetes; unfortunately, there are reports indicating that a high dose of intra-articular corticosteroid (> 20 mg) may lead to a rise in blood glucose. This is a disadvantage of IACI [30]. However, there are studies with findings similar to ours indicating that IACI has better results than physiotherapy alone [31,32]. Green et al. [32] reported that IACI was significantly better than physiotherapy alone; IACI was significantly more effective in controlling pain and improving shoulder function. The results of physiotherapy may not be judged in isolation as all patients were treated with Celecoxib 600 BID. However, most of these patients use over the counter drugs like NSAIDs at home. Some researchers have found that NSAIDs can have the same effect as corticosteroids in controlling pain [33].

The use of regional blocks is associated with a reduction in systemic side effects of drugs. This relieves the difficulty of taking multiple medications and analgesics and results in a better quality of life. Unfortunately, the use of regional nerve blocks is sometimes limited such as in cases in which the localized anatomy is disturbed. This may occur post-surgically, as the result of radiotherapy, due to the presence of a mass, as a consequence of obesity and because of muscle hypertrophy. Nerve injury is a potential complication that may occur due to technical errors. Pain may not occur during these improper injections; reliance on clinical symptoms may not be sufficient. SSNB had a noticeably positive effect on patient outcome in our study. We had no complications,

and pain relief was sufficient in our patients.

One of the limitations of our study was that ethical limitations did not allow us to keep our patients blinded to study aims. We had to explain the intervention to the patients of each group. In conclusion, SSNB is an effective method for controlling pain and accelerating recovery of shoulder motion in patients with adhesive shoulder capsulitis.

## ACKNOWLEDGMENTS

The authors express their gratitude to Ms. Zoleikha Azari for critical reading of the manuscript and for her insightful suggestions.

## ORCID

Mohsen Mardani-Kivi <https://orcid.org/0000-0002-9437-5756>  
 Bahram Naderi Nabi <https://orcid.org/0000-0002-1727-2446>  
 Ehsan Kazemnejad Leili <https://orcid.org/0000-0002-4035-2890>  
 Zahra Haghparast Ghadim-Limudahi  
<https://orcid.org/0000-0002-2073-113X>

## REFERENCES

1. Georgiannos D, Markopoulos G, Devetzi E, Bisbinas I. Adhesive capsulitis of the shoulder: is there consensus regarding the treatment?: a comprehensive review. *Open Orthop J* 2017;11:65-76.
2. Neviasser JS. Adhesive capsulitis of the shoulder: a study of the pathological findings in periartthritis of the shoulder. *J Bone Joint Surg* 1945;27:211-22.
3. Salt E, van der Windt DA, Chesterton L, Mainwaring F, Ashwood N, Foster NE. Physiotherapist-led suprascapular nerve blocks for persistent shoulder pain: evaluation of a new service in the UK. *Musculoskeletal Care* 2018;16:214-21.
4. Almashni RA, Calacattawi AW, Almeshal MA, et al. Current management of shoulder adhesive capsulitis: a randomized, triple-blind placebo-controlled trial. *Int J Community Med Public Health* 2018;5:3678-85.
5. Wu WT, Chang KV, Han DS, Chang CH, Yang FS, Lin CP. Effectiveness of glenohumeral joint dilatation for treatment of frozen shoulder: a systematic review and meta-analysis of randomized controlled trials. *Sci Rep* 2017;7:10507.
6. Kisner C, Colby LA. Therapeutic exercise: foundations and techniques. Philadelphia, PA: F.A. Davis; 1994.
7. Kraal T, The B, Boer R, et al. Manipulation under anesthesia versus physiotherapy treatment in stage two of a frozen shoulder: a study protocol for a randomized controlled trial. *BMC Musculoskelet Disord* 2017;18:412.

8. Dahan TH, Fortin L, Pelletier M, Petit M, Vadeboncoeur R, Sussisa S. Double blind randomized clinical trial examining the efficacy of bupivacaine suprascapular nerve blocks in frozen shoulder. *J Rheumatol* 2000;27:1464-9.
9. Abdelshafi ME, Yosry M, Elmulla AF, Al-Shahawy EA, Adou Aly M, Eliewa EA. Relief of chronic shoulder pain: a comparative study of three approaches. *Middle East J Anaesthesiol* 2011;21:83-92.
10. Mitra PK, Bhattacharya D. Comparison of clinical effects of ultrasound guided suprascapular nerve block and oral pregabalin versus suprascapular nerve block alone for pain relief in frozen shoulder. *Indian J Pain* 2016;30:49-54.
11. Ozkan K, Ozcekcic AN, Sarar S, Cift H, Ozkan FU, Unay K. Suprascapular nerve block for the treatment of frozen shoulder. *Saudi J Anaesth* 2012;6:52-5.
12. Sheikh SI, Ahmed A, Javaid S, Basit A, Sheikh IS, Sheikh ZS. Comparison of suprascapular nerve block & intra-articular injection in the treatment of frozen shoulder. *J Islam Int Med Coll* 2012;7:76-81.
13. Salgia A, Agarwal T, Puri SR, Sanghi S, Mohapatra A. Role of suprascapular nerve block in chronic shoulder pain: a comparative study of 60 cases. *Med J DY Patil Univ* 2014;7:44-7.
14. Chang KV, Hung CY, Wu WT, Han DS, Yang RS, Lin CP. Comparison of the effectiveness of suprascapular nerve block with physical therapy, placebo, and intra-articular injection in management of chronic shoulder pain: a meta-analysis of randomized controlled trials. *Arch Phys Med Rehabil* 2016;97:1366-80.
15. Sun Y, Lu S, Zhang P, Wang Z, Chen J. Steroid injection versus physiotherapy for patients with adhesive capsulitis of the shoulder: a PRIMSA systematic review and meta-analysis of randomized controlled trials. *Medicine (Baltimore)* 2016;95:e3469.
16. Bulgen DY, Binder AI, Hazleman BL, Dutton J, Roberts S. Frozen shoulder: prospective clinical study with an evaluation of three treatment regimens. *Ann Rheum Dis* 1984;43:353-60.
17. Rouhani A, Mardani-Kivi M, Bazavar M, et al. Calcitonin effects on shoulder adhesive capsulitis. *Eur J Orthop Surg Traumatol* 2016;26:575-80.
18. Ebrahimzadeh MH, Birjandinejad A, Golhasani F, Moradi A, Vahedi E, Kachooei AR. Cross-cultural adaptation, validation, and reliability testing of the Shoulder Pain and Disability Index in the Persian population with shoulder problems. *Int J Rehabil Res* 2015;38:84-7.
19. Le HV, Lee SJ, Nazarian A, Rodriguez EK. Adhesive capsulitis of the shoulder: review of pathophysiology and current clinical treatments. *Shoulder Elbow* 2017;9:75-84.

20. Fields BK, Skalski MR, Patel DB, et al. Adhesive capsulitis: review of imaging findings, pathophysiology, clinical presentation, and treatment options. *Skeletal Radiol* 2019;48:1171-84.
21. Shanahan EM, Ahern M, Smith M, Wetherall M, Bresnihan B, FitzGerald O. Suprascapular nerve block (using bupivacaine and methylprednisolone acetate) in chronic shoulder pain. *Ann Rheum Dis* 2003;62:400-6.
22. Jones DS, Chattopadhyay C. Suprascapular nerve block for the treatment of frozen shoulder in primary care: a randomized trial. *Br J Gen Pract* 1999;49:39-41.
23. Wassef MR. Suprascapular nerve block: a new approach for the management of frozen shoulder. *Anaesthesia* 1992;47:120-4.
24. Dangoisse MJ, Wilson DJ, Glynn CJ. MRI and clinical study of an easy and safe technique of suprascapular nerve blockade. *Acta Anaesthesiol Belg* 1994;45:49-54.
25. Harmon D, Hearty C. Ultrasound-guided suprascapular nerve block technique. *Pain Physician* 2007;10:743-6.
26. Woolf CJ. Somatic pain: pathogenesis and prevention. *Br J Anaesth* 1995;75:169-76.
27. Lewis RN. The use of combined suprascapular and circumflex (articular branches) nerve blocks in the management of chronic arthritis of the shoulder joint. *Eur J Anaesthesiol* 1999;16:37-41.
28. Kay J, Memon M, Hu T, et al. Suprascapular nerve blockade for postoperative pain control after arthroscopic shoulder surgery: a systematic review and meta-analysis. *Orthop J Sports Med* 2018;6:2325967118815859.
29. Koh KH. Corticosteroid injection for adhesive capsulitis in primary care: a systematic review of randomised clinical trials. *Singapore Med J* 2016;57:646-57.
30. Lee HJ, Lim KB, Kim DY, Lee KT. Randomized controlled trial for efficacy of intra-articular injection for adhesive capsulitis: ultrasonography-guided versus blind technique. *Arch Phys Med Rehabil* 2009;90:1997-2002.
31. Sun Y, Chen J, Li H, Jiang J, Chen S. Steroid injection and non-steroidal anti-inflammatory agents for shoulder pain: a PRISMA systematic review and meta-analysis of randomized controlled trials. *Medicine (Baltimore)* 2015;94:e2216.
32. Green S, Buchbinder R, Hetrick S. Physiotherapy interventions for shoulder pain. *Cochrane Database Syst Rev* 2003;2003:CD004258.
33. Dehghan A, Pishgooei N, Salami MA, et al. Comparison between NSAID and intra-articular corticosteroid injection in frozen shoulder of diabetic patients; a randomized clinical trial. *Exp Clin Endocrinol Diabetes* 2013;121:75-9.