

Contemporary management of obturator hernia

Taylor Anderson ,¹ Kovi E Bessoﬀ,² David Spain,¹ Jeff Choi ¹

► Additional supplemental material is published online only. To view, please visit the journal online (<http://dx.doi.org/10.1136/tsaco-2022-001011>).

¹Surgery, Stanford University, Stanford, California, USA

²Surgery, University of California Davis, Sacramento, California, USA

Correspondence to

Dr Taylor Anderson; tand@stanford.edu

CASE PRESENTATION

A female patient in her 80s presented to the emergency department with 1-day history of severe abdominal pain associated with nausea and vomiting. Her medical history was notable for hypertension, insulin-dependent type II diabetes mellitus, end-stage renal disease secondary to polycystic kidney disease (hemodialysis-dependent) and coronary artery disease with distant history of two drug-eluting stents (on daily clopidogrel). Prior surgical history included appendectomy and bladder suspension.

On arrival, the patient was hemodynamically stable and her abdomen was distended, but soft and non-tender. Laboratory assessment was notable for leukocytosis (19.3 K/ μ L), elevated lactate (3.31 mmol/L), baseline renal impairment (creatinine 3.33 mg/dL), and hyperglycemia (240 mg/dL).

CT angiography of the abdomen and pelvis showed a strangulated, poorly enhancing bowel loop interposed between the right obturator internus and pectineus muscles with severe dilation of proximal bowel loops ([figure 1](#)).

WHAT WOULD YOU DO?

1. Attempt manual reduction with adduction and internal rotation of the thigh.
2. Laparoscopic hernia repair.
3. Open hernia repair via low midline laparotomy.
4. Open hernia repair via right inguinal incision.

WHAT WE DID AND WHY

Our patient's presentation was consistent with an incarcerated obturator hernia causing small bowel obstruction. After nasogastric tube decompression, we proceeded to the operating room for emergency laparoscopic obturator hernia reduction and repair (online supplemental video). On entry, we observed a loop of small bowel protruding through the obturator foramen, which we reduced with gentle traction. This bowel segment had a small ecchymotic area but did not appear ischemic or have serosal tears ([figure 2A,B](#)). We occluded the hernia defect with a prolene mesh plug and the overlying

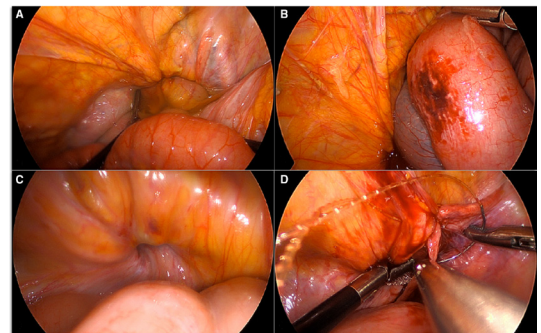


Figure 2 (A) Small bowel herniating through the right obturator foramen. (B) Bowel segment that was incarcerated through the obturator foramen, after reduction. (C) Obturator foramen defect post hernia reduction. (D) Peritoneal closure over obturator foramen plugged with mesh.

peritoneum was closed with a running v-lock suture ([figure 2C,D](#)). We placed a plug mesh to minimize operative time and mitigate potential bleeding associated with extensive dissection. The patient tolerated a diet by postoperative day 2.

Obturator hernia occurs when abdominopelvic contents enter the obturator canal, an osteofibrous passage within the obturator foramen (bordered by the ischiopubic rami at the anteroinferior pelvic margin).¹ Howship-Romberg sign—pain on ipsilateral thigh adduction and internal rotation due to obturator nerve compression—is only present in half of cases.² Most obturator hernias present with bowel obstruction and require emergency operative management; almost half require resection of strangulated bowel.³ Obturator hernias account for only 0.2%–1.6%^{4,5} of mechanical bowel obstructions but are associated with high mortality (12%) due to delayed diagnosis.³ Contralateral obturator hernias (25%) and concomitant groin hernias (inguinal 19%, femoral 11%) are not infrequent.⁶ Abdominal CT is the diagnostic gold standard.³

Open primary repair through a midline laparotomy facilitates rapid exposure and is useful in cases of suspected perforation.^{6,7} However, laparoscopic repair should be considered in hemodynamically stable patients without suspected perforation. A recent meta-analysis (74 studies, 146 patients) found that compared with laparotomy, laparoscopic repair is associated with lower morbidity (OR 0.29, 95% CI 0.09 to 0.78) and mortality (OR 0.84, 95% CI 0.75 to 0.95).³ Another meta-analysis reported no recurrences among 299 laparoscopic obturator hernia repairs with mesh.⁶

Total extraperitoneal (TEP) repair and transabdominal preperitoneal (TAPP) repair facilitate bilateral obturator, femoral, and inguinal hernia repair

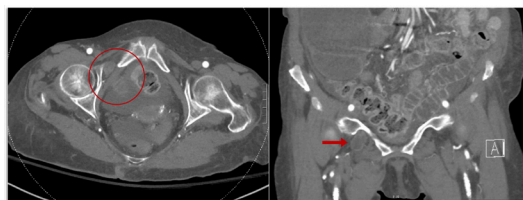

Figure 1 CT angiogram showing a right-sided obturator hernia in axial (red circle, left) and coronal (red arrow, right) views.

© Author(s) (or their employer(s)) 2022. Re-use permitted under CC BY-NC. No commercial re-use. See rights and permissions. Published by BMJ.

To cite: Anderson T, Bessoﬀ KE, Spain D, *et al.* *Trauma Surg Acute Care Open* 2022;**7**:e001011.

with extraperitoneal mesh placement.^{8–12} The abdomen should be explored if there is concern for bowel ischemia after reduction (ie, TEP would be inadequate).

The Kugel approach provides access to the external obturator canal opening and distal hernia sac using a single suprainguinal incision.¹³ Opening the sac prior to hernia reduction facilitates bowel inspection, potential resection, and preperitoneal mesh placement. This technique is useful when an abdominal approach would be challenging.¹⁴

Overall, current evidence suggests that an initial laparoscopic approach is appropriate for obturator hernia repair in patients without suspicion for perforation. Mesh should be considered, either at initial presentation or as a second-stage procedure if the operative field is contaminated.

Contributors TA participated in background research, data acquisition, article writing, and article editing. KEB and DS participated in conceptualization, planning, and article editing. JC participated in conceptualization, planning, design, and article editing. All authors provided final approval of the article and figures prior to submission.

Funding The authors have not declared a specific grant for this research from any funding agency in the public, commercial or not-for-profit sectors.

Competing interests None declared.

Patient consent for publication Not applicable.

Provenance and peer review Not commissioned; internally peer reviewed.

Open access This is an open access article distributed in accordance with the Creative Commons Attribution Non Commercial (CC BY-NC 4.0) license, which permits others to distribute, remix, adapt, build upon this work non-commercially, and license their derivative works on different terms, provided the original work is properly cited, appropriate credit is given, any changes made indicated, and the use is non-commercial. See: <http://creativecommons.org/licenses/by-nc/4.0/>.

ORCID iDs

Taylor Anderson <http://orcid.org/0000-0002-8608-8343>

Jeff Choi <http://orcid.org/0000-0003-1639-8781>

REFERENCES

- Delgado A, Bhuller SB, Phan P, Weaver J. Rare case of obturator hernia: surgical anatomy, planning, and considerations. *SAGE Open Med Case Rep* 2022;10:2050313X2210813.
- Yale SH, Tekiner H, Yale ES. Role of the signs of obturator hernia in clinical practice. *Hernia* 2021;25:235–6.
- Schizas D, Apostolou K, Hasemaki N, Kanavidis P, Tsapralis D, Garmpis N, Damaskos C, Alexandrou A, Filippou D, Kontzoglou K. Obturator hernias: a systematic review of the literature. *Hernia* 2021;25:193–204.
- Lo CY, Lorentz TG, Lau PW. Obturator hernia presenting as small bowel obstruction. *Am J Surg* 1994;167:396–8.
- Ziegler DW, Rhoads JE. Obturator hernia needs a laparotomy, not a diagnosis. *Am J Surg* 1995;170:67–8.
- Holm MA, Fønnes S, Andresen K, Rosenberg J. Laparotomy with suture repair is the most common treatment for obturator hernia: a scoping review. *Langenbecks Arch Surg* 2021;406:1733–8.
- Losanoff JE, Richman BW, Jones JW. Obturator hernia. *J Am Coll Surg* 2002;194:657–63.
- Kwak JS, Lee SE, Park SM, Lee SJ, Kwon SU, Bae IE, Sung NS, Moon JI, Yoon DS, Choi IS, et al. Which patients are a better candidate of laparoscopic repair in obturator hernia patients? *J Minim Invasive Surg* 2020;23:93–8.
- Karashima R, Kimura M, Taura N, Shimokawa Y, Nishimura T, Baba H. Total extraperitoneal approach for incarcerated obturator hernia repair. *Hernia* 2016;20:479–82.
- Yokoyama T, Kobayashi A, Kikuchi T, Hayashi K, Miyagawa S. Transabdominal preperitoneal repair for obturator hernia. *World J Surg* 2011;35:2323–7.
- Hayama S, Ohtaka K, Takahashi Y, Ichimura T, Senmaru N, Hirano S. Laparoscopic reduction and repair for incarcerated obturator hernia: comparison with open surgery. *Hernia* 2015;19:809–14.
- Wu J-M, Lin H-F, Chen K-H, Tseng L-M, Huang S-H. Laparoscopic preperitoneal mesh repair of incarcerated obturator hernia and contralateral direct inguinal hernia. *J Laparoendosc Adv Surg Tech A* 2006;16:616–9.
- Kugel RD. Minimally invasive, nonlaparoscopic, preperitoneal, and sutureless, inguinal herniorrhaphy. *Am J Surg* 1999;178:298–302.
- Hosoi Y, Asano H, Fukano H, Shinozuka N. Treatment outcomes of Kugel repair for obturator hernias: a retrospective study. *BMC Surg* 2020;20:131.