

Tomographic Analysis of Positioning of Reverse Baseplates Positioning

Journal of Shoulder and Elbow
Arthroplasty
Volume 5: 1–9
© The Author(s) 2021
Article reuse guidelines:
sagepub.com/journals-permissions
DOI: 10.1177/2471549220987714
journals.sagepub.com/home/sea



Alexandre Almeida, MBBS¹ , Daniel C Agostini, MBBS²,
Pietro FT Nesello, BM³, Nayvaldo C de Almeida, MBBS⁴,
Rafael Mioso, MBBS², and Ana Paula Agostini, MD⁵

Abstract

Objective: To verify whether reverse baseplate positioning without the support of intraoperative three-dimensional technology is within the acceptable parameters in the literature and whether glenoid bone deformity (GBD) compromises this positioning.

Methods: Sixty-nine reverse shoulder arthroplasties were evaluated with volumetric computed tomography (CT). Two radiologists performed blinded CT scan analysis and evaluated baseplate position within 2mm of the inferior glenoid; the inclination and version of the baseplate in relation to the Friedman line; and upper and lower screw and baseplate metallic peg end point positionings. The patients were divided according to the presence of GBD for statistical analyses.

Results: The two radiologists concurred reasonably in their interpretations of the following analyzed parameters: baseplate position within 2mm of the inferior glenoid rim (97.1% and 95.7%), baseplate inclination (82.6% and 81.2%), baseplate version (69.6% and 56.5%), the upper screw reaching the base of the coracoid process (71% and 79.7%), the inferior screw remaining inside the scapula (88.4% and 84.1%), and the metallic peg of the baseplate considered intraosseous (88.4% and 72.5%).

Conclusion: Reverse baseplate positioning without intraoperative three-dimensional technology is within the acceptable parameters of the literature, except for baseplate version and upper screw position. GBD did not interfere with baseplate positioning in reverse shoulder arthroplasty.

Keywords

Shoulder/surgery, arthroplasty, tomography

Date received: 28 August 2020; revised: 15 October 2020; accepted: 22 December 2020

Introduction

Reverse Shoulder Arthroplasty (RSA) provides excellent short-term results in the treatment of different shoulder joint pathologies.^{1–3} The verified RSA durability in the literature is cited to be 90%–94% in 10 years of follow-up, including posttraumatic lesions and revisions.^{3–5}

Factors involved in the early loosening of the RSA components are being explored by medical professionals and implant-development companies to improve the durability of surgical treatment and reduce the risk of complications.^{6–9} The durability of the RSA is related to patient factors, as the quality of bone and factors that are surgeon's responsibility.⁹ Some well determined factors include preoperative planning,^{7,10–14} surgical technique employed,^{8,14–16} the remaining functional tendons,^{1,17} glenoid bone deformity (GBD),^{6,9,10} implant characteristics,^{13,18–20} and postoperative management.

The positioning and the fixation of the reverse baseplate has received particular attention. The correct positioning of the baseplate is challenging for the surgeon, especially in the presence of glenoid bone defects.¹⁰ The surgical planning of an RSA should include a thorough presurgical investigation of these defects.^{6,9,10,12} Precision is not achieved using simple radiographic

¹Orthopaedic Surgeon, Pompeia Hospital, Caxias do Sul, Brazil

²Radiologist Physician, General Hospital, Caxias do Sul, Brazil

³Second Year Fellowship Resident at Pompeia Hospital, Caxias do Sul, Brazil

⁴Orthopedic Surgeon, Saude Hospital, Caxias do Sul, Brazil

⁵Master's Degree in Pediatrics from PUC-POA, Porto Alegre, Brazil

Corresponding Author:

Alexandre Almeida, Rua Vitória Buzelatto, 222/601 Caxias do Sul, RS, Brazil.

Email: alealmeida19613@gmail.com



studies.²¹ Van Haver et al.¹² reported that the beta-angle may help analyze the angular glenoid tilt in conventional radiographs, but 10° errors may occur. Even simple computed tomography (CT) (2D) without the use of the entire scapula body as a referenceless accurate than volumetric CT (3D).⁶

The vast majority of surgeons perform shoulder arthroplasty surgery only with the visualization of the glenoid, without the support of 3D technology. The literature is controversial regarding the need to use 3D planning and instrumentation (navigated surgery) to achieve the ideal positioning and fixation of the baseplate. Some studies suggest the superiority of preoperative and intraoperative 3D technology in improving angular positioning and decreasing the chance of perforation of the medial cortical of the scapula by the implant.^{7,11} The intraoperative 3D instrumentation also improved the endpoint of the fixation screws, especially the lower screw.⁸ Although these new technologies hold promise in improving baseplate positioning, they are associated with increase surgery costs.

The main objective of this research is to verify whether the reverse baseplates positioning without the support of intraoperative 3D technology is within the acceptable parameters of the literature. Also, assessing whether GBD compromises the positioning of the baseplate.

Methods

We performed a cross-sectional study. Seventy patients underwent RSA between September 2009 and April 2019 and were evaluated with postoperative volumetric CT (3D). One patient had revision surgery, intentionally performed with a non-anatomical positioning of the baseplate, and hence was excluded from the cohort.²² The RSA surgical indication pathologies are listed in Table 1.

We performed the surgeries in the “beach-chair” position. The deltopectoral approach was used in 94.2% of the cases (65 patients), and the anteroposterior approach was used in the rest. All the arthroplasties used the

Equinoxe Shoulder System® (Exactech) with a neck shaft angle of 132.5° and the baseplate fixed with compression-blocked screws. The Exactech brand baseplate features 6-hole options for placing 4.5 mm fixation screws that initially compress and then lock in place. The length of the screws varies from 18 to 46 mm. In the upper 1/3 of the baseplate, there is an eccentric peg, 16 mm long (standard) discreetly conical, fenestrated, and with a space for the autograft placement from the anatomical head. The baseplate is made with a 5° inferior tilt.

Four fixation screws were used in 95.6% of the cases (66 patients) and 5 screws in the rest. The central peg of the baseplate was standard (16 mm) in 68 cases. An extended central peg (26 mm) was used in one case.

The surgeon chose the technique used for the positioning of the arthroplasty components without any PSI instrumentation or intraoperative navigation. Although all patients had a CT scan performed preoperatively, no specific software was used to plan the surgery.

The average time of the surgical procedure was 103 minutes (IQR: 90–120 minutes). Eighteen patients (26%) needed a blood transfusion.

All patients were immobilized for 30 days with a cushioned sling, maintaining upper limb neutral rotation. If the subscapularis tendon was repaired, active exercises for anterior forward flexion, lateral rotation, and internal rotation were started at 30 days, postoperatively. In patients where the subscapularis was not repaired, these exercises were started on the 15th day. Deltoid isometric exercises and isotonic reinforcement of the scapula stabilizers muscles were started at 30 days postoperatively in all patients.

During the postoperative follow-up, 4 problems and 13 complications (18.8%) in total were identified.

Tomographic evaluation of the shoulder was performed for follow-up, the median period being 39 months (IQR: 34–62 months). Volumetric acquisition in the axial plane of the shoulder girdle with posterior multiplanar and 3D reconstructions was performed during the tomographic examination. The patients

Table 1. Pathologies, Number of Cases, Frequency, and Confidence Interval.

Pathology	n	% [95% CI]
Cuff tear arthropathy	35	50.72 [38.40, 62.98]
Four-part fracture	11	15.94 [8.24, 26.74]
Arthrosis without a cuff	9	13.04 [6.14, 23.32]
Fracture sequelae	6	8.70 [3.26, 17.97]
Chronic luxation	4	5.80 [1.6, 14.18]
Arthrosis in patient with rheumatoid arthritis	1	1.44 [0.00, 7.81]
Severe instability	1	1.44 [0.00, 7.81]
Hemiarthroplasty revision	1	1.44 [0.00, 7.81]
Periprosthetic fracture	1	1.44 [0.00, 7.81]

CI: confidence interval.

were subjected to a unilateral shoulder CT scan of the Achillion Prime model with multiple detector rows (multi-slice - 160 channels), with software for dose modulation (sure exposure) and reduction of metal artifacts (single-energy metal artifact reduction - SEMAR). The images were acquired with the patient in supine and with the upper limb positioned at the side of the body. The cuts' size was 1.0×0.75 mm (cut's thickness 0.75 mm, increase of 0.4 mm, 512-pixel image matrix), scanning from 1 cm above the acromion to the end of the scapula and the prosthesis at the medulla of the humerus, using a standard bone filter cartridge (FC) 35. The dosimetry parameters used were 135 Kv/200 mA and the total effective dose with a mean between 1.5 and 2.0 mSv. After the acquisition, 3D reconstructions were performed (Recon AIDR 3D process) to evaluate the images in the OsiriX DICOM Viewer visualization platform.

Two non-related radiologists performed blinded CT scans analysis. The following parameters were evaluated: baseplate position within 2mm of the inferior glenoid, inclination of the baseplate within the arc from zero to 10° inferior tilt in relation to the Friedman Line, baseplate version within the angular arc of 2° of anteversion, and 9° of retroversion regarding the Friedman Line, end point positioning of the upper screw, end point positioning of the lower screw and positioning of the metallic peg of the baseplate.

Patients were divided into 2 groups for statistical analysis: Group 1 entailed patients without bony defects in the glenoid (n=45); Group 2 patients with GBD (n=24). The bone deformity was determined in the pre-operative diagnostic exams (radiography, volumetric CT, and magnetic resonance imaging) using the classifications of Hamada,²³ Favard,²⁴ and Walch.²⁵ Patients were classified as type 4A, 4B, and 5 according to the Hamada classification; type E1, E2, E3, and E4 according to the Favard classification; and type A2, B2, B3, C, and D, according to the Walch classification, were considered as having GBD and were included in Group 2.

The descriptive and statistical analysis was performed with R-software (The R Foundation for Statistical Computing, <https://www.r-project.org/>, version 4.0.0, 2020-04-24). For the description of the sample, the mean and standard deviation were used for variables with symmetrical distribution, the median and interquartile range (IQR) for variables with asymmetric distribution, and percentage with 95% confidence intervals (CI95%) for categorical variables. In the comparison between two asymmetric numerical variables, the Wilcoxon signed-rank test was used, and in the consensus between the radiologists, the Cohen's kappa coefficient (k) was used (Table 2). Chi-square or Fisher's exact test was used for categorical variables. For all statistical analyses, value $P < 0.05$ was considered significant.

Table 2. Kappa Value, Interpretation.

Kappa Value	Interpretation
< 0.00	No agreement
0.00–0.20	Slight agreement
0.21–0.40	Fair agreement
0.41–0.60	Moderate agreement
0.61–0.80	Substantial agreement
0.81–1.00	Almost perfect agreement

Results

The average age of the 69 patients included in the study was 72.3 years (SD ± 7.2). Fifty-six or 81.2% (95% CI: 71.9–90.4) patients were women. In 44 patients or 63,8% (IC95%: 52.4–76.5), the operated shoulder was the right one. The upper limb was dominant in 65.2% (95% CI: 54–76.5) of the cases.

The median of baseplate inferior inclination was measured by Radiologist 1 at 4.20°, while the median of the version was 2.40° of retroversion ($P = 0.006$). Radiologist 2 evaluated the median of the inferior baseplate inclination at 5.20°, while the median of the version was 3.50° of retroversion ($P = 0.182$) (Table 3).

Radiologists 1 and 2 verified the baseplate position within 2mm of the inferior glenoid rim in 97.1% (67 patients) and 95.7% (66 patients) of the cases, respectively. There was no statistical difference between patients with and without GBD ($P = 0.540$ and $P > 0.999$) according to Radiologist 1 and 2, respectively. There was a 92.8% agreement between the analyses of both radiologists [Kappa = 0.57 (95% CI: 0.31–0.81); $P < 0.001$].

Radiologists 1 and 2 verified that the baseplate inclination was within the angulation from 0° to 10° inferior tilt regarding the Friedman Line in 82.6% (57 patients) and 81.2% (55 patients) of the cases. There was no statistical difference between patients with and without GBD, $P = 0.740$ verified by Radiologist 1, and ($p = 0.352$) by Radiologist 2. There was a 78.2% agreement between the analyses of both radiologists [Kappa = 0.27 (95% CI: 0.011–0.55); $P = 0.026$].

Radiologist 1 verified that the baseplate version was within the angular arc of 2° anteversion and 9° retroversion in relation to the Friedman Line in 69.6% of the cases (48 patients) and there was no statistical difference between patients with and without GBD ($p = 0.513$). Radiologist 2 results of the same baseplate position were 56.5% of the cases (39 patients), with no statistical difference between patients with and without GBD ($p = 0.773$). There was a 72.3% agreement between the analyses of both radiologists [Kappa = 0.42 (95% CI: 0.21–0.63); $P < 0.001$].

Table 3. Variables, Frequency, and Confidence Interval in Grades, p-Value.

Variable	Radiologist 1 Median in Grade [CI _{95%}]	Radiologist 2 Median in Grade [CI _{95%}]	P ^a
Baseplate Inclination	4.20 [2.00, 6.90]	5.20 [2.50, 7.40]	0.1828
Baseplate Version	-2.40 [-3.50, 2.60]	-3.50 [-7.00, 2.20]	0.0063

^aWilcoxon signed rank test.

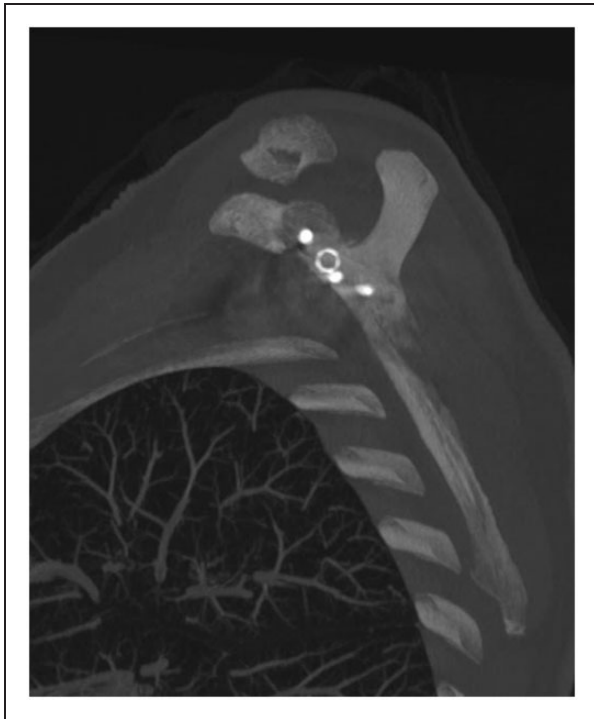

Figure 1. A Tomographic Image of the Shoulder With The Upper Screw Reaching the Base of the Coracoid Process.

Radiologists 1 and 2 verified that the upper screw reached the base of the coracoid process in 71% of the cases (49 patients) and 79.7% of the cases (55 patients), respectively. There was no statistical difference between patients with and without GBD ($P=0.090$) and ($P=0.537$) reported by Radiologist 1 and 2, respectively. There was an 85.5% agreement between the analyses of both radiologists [Kappa = 0.61 (95% CI: 0.40-0.83); $P < 0.001$], Figures 1 and 2. Radiologist 1 considered that there was a tendency, although not significant, of greater error probability in the positioning of the superior screw in patients with GBD.

Radiologists 1 and 2 verified that the inferior screw remained inside the scapula in 88.4% of the cases (61 patients) and 84.1% of the cases (58 patients), respectively. There was no statistical difference between patients with and without GBD ($P > 0.999$) and ($P = 0.496$) reported by Radiologists 1 and 2, respectively. There was a 92.8% agreement between the analyses

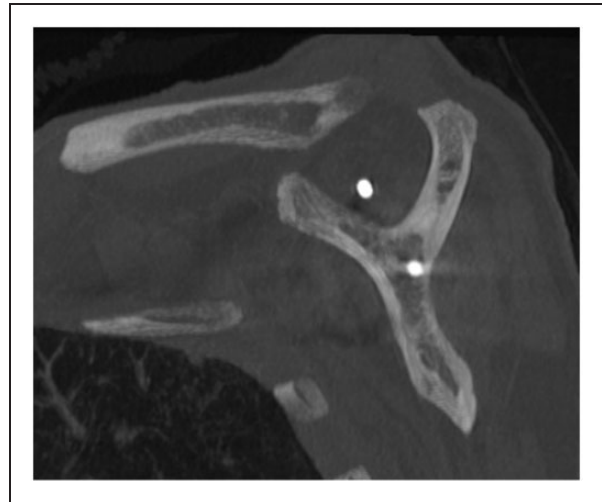


Figure 2. A Tomographic Image of the Shoulder With the Upper Screw Off the Base of the Coracoid Process.

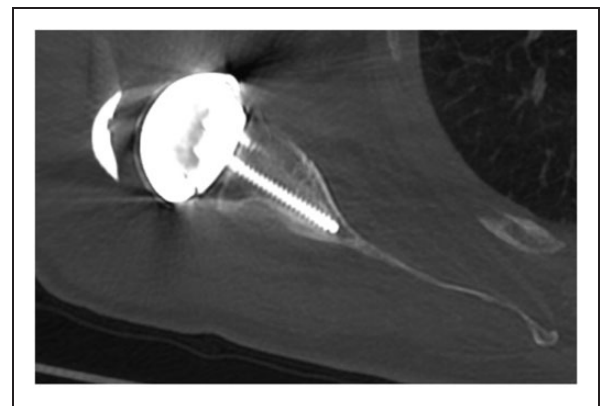


Figure 3. A Tomographic Image of the Shoulder With the Lower Screw Inside the Body of the Scapula.

of both radiologists (Kappa = 0.70 (95% CI: 0.45–0.94); $P < 0.001$) (Figures 3 and 4).

Radiologists 1 and 2 observed the positioning of the metallic peg of the baseplate and considered it intraosseous without perforating the medial cortex of the scapula in 88.4% of the cases (61 patients) and 72.5% of the cases (50 patients), respectively. There was no statistical difference between patients with and without GBD ($P > 0.999$) and ($P = 0.730$), reported by Radiologists 1

and 2, respectively. There was an 84.1% agreement between the analyses of both radiologists [Kappa = 0.51, (95% CI: 0.28–0.74); $P < 0.001$].

In summary, both radiologists concurred in their interpretation reasonably. The comparison between their analyses is shown in Table 4.

Discussion

The clinical outcome and durability of RSA are related to several factors, among which the baseplate correct positioning and fixation are particularly important.^{2–5}

Regarding the clinical result, the correct positioning of the baseplate influences the stability,^{10,18} and the range of movement recovered by the patient.¹⁸ Gulotta

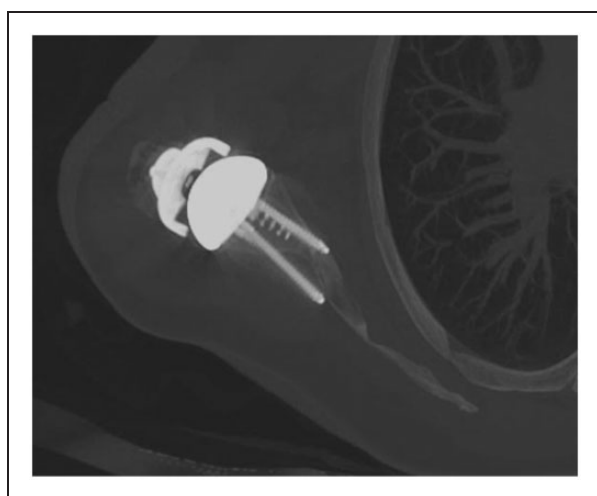


Figure 4. A Tomographic Image of the Shoulder With the Lower Screw Outside of the Body of the Scapula.

et al.,¹⁴ in their cadaver study, found that baseplate placement at 0° to 20° of retroversion allowed the medial rotation of the superior limb necessary for daily living activities. Increased retroversion of the baseplate leads to a decrease in lateral rotation and extension of the upper limb; however, it improves medial rotation.¹⁰ The ideal arc of motion was most frequently reached when the baseplates were positioned between the neutral position and the 5° of retroversion.¹⁰ In our study, we did not assess the patients' range of motion or clinical results.

Regarding the durability of the RSA, there is a high rate of complications related to early loosening of the baseplate screws.^{6–8} Objectifying an adequate initial fixation of the baseplate is probably the main factor influencing the procedure's durability.^{22,26} In the literature review, the main factors responsible for reducing the RSA durability are considered to be the use of unlocked screws and the need to use a bone graft in the glenoid.^{26,27} The GBD have received special importance in their role in influencing the durability of arthroplasties.^{6–8,10,11,13}

The acquired bone defects present a challenge to the surgeon^{7,10,11,28,29} and may be present in up to 40% of patients.^{22,30} According to Klein et al., the first challenge is their preoperative recognition and evaluation.^{28,31} Therefore, classifications identifying the different types and characteristics of bone defects have been developed,^{22,29,31,32} and the correct preoperative evaluation of the patients submitted to RSA^{28,31} is discussed. Preoperative assessment with simple radiography is considered insufficient²¹ and may lead to positioning errors of up to 10° of angulation.¹² The superiority of the tomographic evaluation over the radiography is

Table 4. Columns: Rated Parameter, Number of Cases, and Frequency Measured by Radiologist 1, Number of Cases and Frequency Measured by Radiologist 2, Agreement Percentage, Kappa Frequency and Confidence Interval, Kappa p. Lines: Rated Parameter, the Respective Number of P-Comparing Cases With and Without Glenoid Bone Deformity (GBD).

Rated Parameter	Radiologist 1 n (%)	Radiologist 2 n (%)	% Agreement	Kappa Value [95% CI]	P Kappa
Baseplate-glenoid inferior symmetry	67 (97.1)	66 (95.7)	92.8	0.57 [0.31, 0.81]	<0.001
With or without GBD	$P = 0.5396^a$	$P > 0.9999^a$			
Baseplate inclination	57 (82.6)	55 (81.2)	78.2	0.27 [–0.011, 0.55]	0.026
With or without GBD	$P = 0.7402^a$	$P = 0.3523^a$			
Baseplate version	48 (69.6)	39 (56.5)	72.3	0.42 [0.21, 0.63]	<0.001
With or without GBD	$P = 0.5134$	$P = 0.7732$			
Superior screw position	49 (71.0)	55 (79.7)	85.5	0.61 [0.40, 0.83]	<0.001
With or without GBD	$P = 0.0900$	$P = 0.5371^a$			
Inferior screw position	61 (88.4)	58 (84.1)	92.8	0.70 [0.45, 0.94]	<0.001
With or without GBD	$P > 0.9999$	$P = 0.4964$			
Intraosseous location of baseplate peg	61 (88.4)	50 (72.5)	84.1	0.51 [0.28, 0.74]	<0.001
With or without GBD	$P > 0.9999^a$	$P = 0.7305$			

^aFisher exact test.

CI: confidence interval; GBD: glenoid bone deformity.

described in the literature, with volumetric CT being superior to the non-volumetric CT.⁶ The most accurate way to evaluate the glenoid bone in the preoperative period of patients submitted to RSA seems to be volumetric CT,²⁸ because of the possibility of revealing the relationship between the joint and the entire scapula body, and including this data in specific surgical planning software. Iannotti et al.³³ developed and validated a volumetric CT method to evaluate the positioned components of total shoulder arthroplasties, which we used in our study while searching the correlation of various factors involved in the durability of the fixation of the baseplate implant with the presence of GBD.

The quality, the characteristics of the design, and the coating of the chosen implant are important in the initial fixation of the baseplate. In this regard, there is an investment involved, and the influence of the developer's company of each implant is significant.^{18,34,35} In our study, we used a single implant brand to avoid selection bias.

The positioning of the baseplate in line with the lower border of the glenoid bone is implicated in reducing notching, decreasing bone resorption, and consequently improving the implant durability.³⁶⁻³⁸ The Exactech brand baseplate used in our study is recommended to be positioned on the lower edge of the glenoid. We found that the surgeons' ability to correctly position the baseplate in relation to the inferior glenoid, even without intraoperative 3D technology, is excellent (Radiologist 1 and 2 measurements reported 97.1% and 95.7% respectively, and were not influenced by the GBD). One possible reason, explaining this fact is that this step does not depend on the surgeon's spatial knowledge of the scapula assessment.

As previously mentioned, baseplate inclination implies stability and movement,^{10,14,18,39} but is also cited as a durability factor in the RSA procedure.^{30,40,41} The literature considers as normal a glenoid inclination between 4° and 12° inferior tilt.^{40,42} Biomechanical studies suggest that the superior slope of the reverse baseplates increases the tensile force on the implant during the contraction of the deltoid muscle and may lead to early aseptic loosening.^{30,41} In our study, we considered the baseplates fixed within an angular arc 0°–10° of inferior tilt as positioned within acceptable parameters, according to the literature.²⁴ Radiologist 1 found 82.6% and Radiologist 2 found 81.2% of the baseplates well-positioned, although there was no agreement between them. No positional worsening was found in the baseplates placed on GBD.

Also mentioned above, the baseplate version relates to the arch of movement,^{10,14,18} but is also cited as a durability factor in the RSA procedure.⁴³ There are several studies in the literature that have tried to identify the version considered normal for human glenoid

bone.^{23,29,44-46} In general, the angular arc considered normal comprises the angulation between 5° of anteversion and 15° of retroversion of the glenoid.⁴⁵ The angulation above 15° retroversion is considered a risk factor for early aseptic loosening.⁴³ In our study, we considered the baseplates fixed within the angular arc at 2° of anteversion and 9° of retroversion as being positioned within the acceptable parameters according to the literature. Radiologist 1 found only 69.6% and Radiologist 2 found 56.5% of the baseplates well-positioned, suggesting a difficulty in reaching the ideal version of baseplate positioning while working without intraoperative 3D technology. Reports in the literature refer to greater difficulty in identifying and correcting bone deformities in the trans-operative period and a tendency among surgeons to hypercorrect the retroversion.^{11,45} Our research did not identify any statistically-correlated less advantageous position of the baseplates placed in GBD, even though about 1/2 to 1/3 of the baseplates were positioned outside the ideal parameters established in the literature.

The end point of the upper screw reaching the bony mass of the base of the coracoid process is critical for the initial fixation of the baseplate. It may improve the durability of the implant since most of the RSA are performed in patients with advanced age and poor bone quality.^{26,47} Studies suggest that the surgeon should target the identified best bone-quality points of the scapula.^{41,47} Stephens et al.¹³ reported that a baseplate previously rotated 11° made it easier for the screws to reach the base of the coracoid and the body of the scapula. In our study, the baseplate was positioned on the glenoid axis, without any adaptive rotation. Radiologist 1 and 2 verified that 71% and 79.7% of the upper screws, respectively, reached the goal of the base of the coracoid. These findings also suggested a technical difficulty in reaching the basis of the coracoid while working without 3D technology. No statistical correlation was found between superior screws placed on GBD, even though about 1/3 of the upper screws did not reach the base of the coracoid process.

The end point of the inferior screw within the narrow body of the scapula is also considered critical for the initial fixation of the reverse baseplate.⁴¹ However, the use of locked screws reduces the need for this screw to be completely intraosseous.⁴¹ It was verified by Radiologist 1 and 2 that 88.4% and 84.1% of the lower screws, respectively, reached the goal of remaining inside the scapula. No worsening in the positioning of the inferior screw was found in the GBD.

The maintenance of the polyethylene anatomical glenoid pegs within the scapula (vault) bone is controversial in relation to the clinical outcome and the shoulder arthroplasties durability.⁴⁸⁻⁵⁰ In anatomical total shoulder arthroplasties, retroversion correction with excessive

reaming leads to a medialization of the articular surface and an increased risk of perforation of the scapula medial cortex by the implant.⁵⁰ In the case of RSA, the stress forces on the baseplate are even stronger and deleterious to the initial fixation and longevity of the component.³⁵ Frankle et al. suggested that when the glenoid depth is < 25 mm in the preoperative planning, implantation of an RSA should be avoided due to the high risk of early loosening of the baseplate.²² In our study, Radiologists 1 and 2 verified 88.4%, and 72.5% of the metallic baseplate pegs, respectively, achieved the objective of not violating the scapula medial cortex. The violation of the scapula medial cortex was not found to be more frequent in RSA with GBD.

In the literature, the spatial intraoperative scapula assessment is considered ideal in improving the positioning of the shoulder arthroplasties' implants.^{7,8,11} Venne et al.,⁸ in a cadaveric study, simulated RSA surgeries with and without computerized planning and verified better accuracy in the components' angular positions as well as in the endpoints of the screws, especially the lower screw when 3D technology was used. The surgeon did not need navigation to properly make the entry point of the baseplate and the entry point of the screws. Likewise, in our study, there was no difficulty in the correct positioning of the baseplate near the lower surface of the glenoid. We determined through our research that there was a loss of accuracy in the positioning of the implants if spatial knowledge of the scapula was necessary. Similar findings were verified by Berhouet et al.,¹¹ simulating surgeries in 3D reconstruction models. We believe that with the evolution of surgical techniques, the implant positioning would improve, providing extended durability and better clinical outcomes for patients, although certain cost increase is inevitable. Our study demonstrated that visualization of the glenoid without spatial knowledge of the scapula (3D) was insufficient to achieve excellence in the baseplate implant positioning. We consider the small number of cases as a limitation of our study.

Conclusion

Our study verified that the reverse baseplates positioning without the support of intraoperative 3D technology is within the acceptable parameters of the reviewed literature in terms of its placement close to the lower glenoid rim, inclination of the baseplate, positioning of the inferior screw, and the capacity to maintain the metallic peg of the baseplate intraosseous.

About 1/3 of the baseplates were positioned outside the recommended version in the literature, and 1/3 of the upper screws did not reach the base of the coracoid.

Glenoid bone deficiency did not interfere with baseplate positioning in the Reverse Shoulder Arthroplasty.

Declaration of Conflicting Interests

The author(s) declared no potential conflicts of interest with respect to the research, authorship, and/or publication of this article.


Funding

The author(s) received no financial support for the research, authorship, and/or publication of this article.

Research Ethics and Patient Consent

The Ethics Committee of the institution issued a favorable opinion to carry out the research (approval number 3,210,714). Patients included in the study were verbally informed about the radiation they would be subjected to upon entering the CT scanner. All patients provided written informed consent to undergo the tomographic examination.

ORCID iD

Alexandre Almeida  <https://orcid.org/0000-0002-6215-0923>

References

1. Sirveaux F, Favard L, Oudet D, Huquet D, Walch G, Molé D. Grammont inverted total shoulder arthroplasty in the treatment of glenohumeral osteoarthritis with massive rupture of the cuff. Results of a multicenter study of 80 shoulders. *J Bone Joint Surg Br.* 2004;86(3):388–395.
2. Frankle M, Levy JC, Pupello D, et al. The reverse shoulder prosthesis for glenohumeral arthritis associated with severe rotator cuff deficiency. A minimum two-year follow-up study of sixty patient's surgical technique. *J Bone Joint Surg Am.* 2006;88(Suppl 1 Pt 2):178–190.
3. Guery J, Favard L, Sirveaux F, Oudet D, Mole D, Walch G. Reverse total shoulder arthroplasty. Survivorship analysis of eighty replacements followed for five to ten years. *J Bone Joint Surg Am.* 2006;88(8):1742–1747.
4. Bacle G, Nové-Josserand L, Garaud P, Walch G. Long-term outcomes of reverse total shoulder arthroplasty: a follow-up of a previous study. *J Bone Joint Surg Am.* 2017;99(6):454–461.
5. Favard L, Levigne C, Nerot C, Gerber C, De Wilde L, Mole D. Reverse prostheses in arthropathies with cuff tear: are survivorship and function maintained over time? *Clin Orthop Relat Res.* 2011;469(9):2469–2475.
6. Venne G, Pickell M, Ellis RE, Bicknell RT. Reliability of a novel 3-dimensional computed tomography method for reverse shoulder arthroplasty postoperative evaluation. *JSES Open Access.* 2019 Jun 27;3(3):168–173.
7. Dallalana RJ, McMahon RA, East B, Geraghty L. Accuracy of patient-specific instrumentation in anatomic and reverse total shoulder arthroplasty. *Int J Shoulder Surg.* 2016;10(2):59–66.
8. Venne G, Rasquinha BJ, Pichora D, Ellis RE, Bicknell R. Comparing conventional and computer-assisted surgery baseplate and screw placement in reverse shoulder arthroplasty. *J Shoulder Elbow Surg.* 2015;24(7):1112–1119.
9. Simon P, Streit JJ, Abboud JA, Mighell MA, Williams GR Jr, Frankle MA. Quantitative videographic analysis of

- intraoperative total shoulder arthroplasty is predictive of radiographic implant loosening. *JSES Open Access*. 2018;2(1):18–22.
10. Keener JD, Patterson BM, Orvets N, Aleem AW, Chamberlain AM. Optimizing reverse shoulder arthroplasty component position in the setting of advanced arthritis with posterior glenoid erosion: a computer-enhanced range of motion analysis. *J Shoulder Elbow Surg*. 2018;27(2):339–349.
 11. Berhouet J, Gulotta LV, Dines DM, et al. Preoperative planning for accurate glenoid component positioning in reverse shoulder arthroplasty. *Orthop Traumatol Surg Res*. 2017;103(3):407–413.
 12. Van Haver A, Heylen S, Vuylsteke K, Declercq G, Verborgt O. Reliability analysis of glenoid component inclination measurements on postoperative radiographs and computed tomography-based 3D models in total and reversed shoulder arthroplasty patients. *J Shoulder Elbow Surg*. 2016;25:632–640.
 13. Stephens BF, Hebert CT, Azar FM, Mihalko WM, Throckmorton TW. Optimal baseplate rotational alignment for locking-screw fixation in reverse total shoulder arthroplasty: a three-dimensional computer-aided design study. *J Shoulder Elbow Surg*. 2015;24(9):1367–1371.
 14. Gulotta LV, Choi D, Marinello P, et al. Humeral component retroversion in reverse total shoulder arthroplasty: a biomechanical study. *J Shoulder Elbow Surg*. 2012;21(9):1121–1127.
 15. Levy JC, Everding NG, Frankle MA, Keppler LJ. Accuracy of patient-specific guided glenoid baseplate positioning for reverse shoulder arthroplasty. *J Shoulder Elbow Surg*. 2014;23(10):1563–1567.
 16. Hendel MD, Werner BC, Camp CL, et al. Management of the biconcave (B2) glenoid in shoulder arthroplasty: technical considerations. *Am J Orthop (Belle Mead NJ)*. 2016;45(4):220–227.
 17. Walker DR, Struk AM, Matsuki K, Wright TW, Banks SA. How do deltoid muscle moment arms change after reverse total shoulder arthroplasty? *J Shoulder Elbow Surg*. 2016;25(4):581–588.
 18. Werner BS, Chaoui J, Walch G. The influence of humeral neck shaft angle and glenoid lateralization on range of motion in reverse shoulder arthroplasty. *J Shoulder Elbow Surg*. 2017;26(10):1726–1731.
 19. Carpenter S, Pinkas D, Newton MD, Kurdziel MD, Baker KC, Wiater JM. Wear rates of retentive versus non retentive reverse total shoulder arthroplasty liners in an in vitro wear simulation. *J Shoulder Elbow Surg*. 2015;24(9):1372–1379.
 20. Lädermann A, Walch G, Lubbeke A, et al. Influence of arm lengthening in reverse shoulder arthroplasty. *J Shoulder Elbow Surg*. 2012;21(3):336–341.
 21. Nyffeler RW, Jost B, Pfirmann CWA, Gerber C. Measurement of glenoid version: conventional radiographs versus computed tomography scans. *J Shoulder Elbow Surg*. 2003;12(5):493–496.
 22. Frankle MA, Teramoto A, Luo ZP, Levy JC, Pupello D. Glenoid morphology in reverse shoulder arthroplasty: classification and surgical implications. *J Shoulder Elbow Surg*. 2009;18(6):874–885.
 23. Hamada K, Fukuda H, Mikasa M, Kobayashi Y. Roentgenographic findings in massive rotator cuff tears. A long-term observation. *Clin Orthop Relat Res*. 1990;(254):92–96.
 24. Favard L, Berhouet J, Walch G, Chaoui J, Lévine C. Superior glenoid inclination and glenoid bone loss: definition, assessment, biomechanical consequences, and surgical options. *Orthopade*. 2017;46(12):1015–1021.
 25. Bercik MJ, Kruse K 2nd, Yalozis M, Gauci MO, Chaoui J, Walch G. A modification to the Walch classification of the glenoid in primary glenohumeral osteoarthritis using three-dimensional imaging. *J Shoulder Elb Surg*. 2016;25(10):1601–1606.
 26. Harman M, Frankle M, Vasey M, Banks S. Initial glenoid component fixation in “reverse” total shoulder arthroplasty: a biomechanical evaluation. *J Shoulder Elbow Surg*. 2005;14(1 Suppl S):162S–167S.
 27. Bitzer A, Rojas J, Patten IS, Joseph J, McFarland EG. Incidence and risk factors for aseptic baseplate loosening of reverse total shoulder arthroplasty. *J Shoulder Elbow Surg*. 2018;27(12):2145–2152.
 28. Scalise JJ, Codsí MJ, Bryan J, Brems JJ, Iannotti JP. The influence of three-dimensional computed tomography images of the shoulder in preoperative planning for total shoulder arthroplasty. *J Bone Joint Surg Am*. 2008;90(11):2438–2445.
 29. Rouleau DM, Kidder JF, Pons-Villanueva J, Dynamidis S, Defranco M, Walch G. Glenoid version: how to measure it? Validity of different methods in two-dimensional computed tomography scans. *J Shoulder Elbow Surg*. 2010;19(8):1230–1237.
 30. Boileau P, Morin-Salvo N, Gauci MO, et al. Angled BIO-RSA (bony-increased offset-reverse shoulder arthroplasty): a solution for the management of glenoid bone loss and erosion. *J Shoulder Elbow Surg*. 2017;26(12):2133–2142.
 31. Klein SM, Dunning P, Mulieri P, Pupello D, Downes K, Frankle MA. Effects of acquired glenoid bone defects on surgical technique and clinical outcomes in reverse shoulder arthroplasty. *J Bone Joint Surg Am*. 2010;92(5):1144–1154.
 32. Lévine C, Boileau P, Favard L, et al. Scapular notching in reverse shoulder arthroplasty. *J Shoulder Elbow Surg*. 2008;17(6):925–935.
 33. Iannotti JP, Ricchetti ET, Rodriguez EJ, Bryan JA. Development and validation of a new method of 3-dimensional assessment of glenoid and humeral component position after total shoulder arthroplasty. *J Shoulder Elbow Surg*. 2013;22(10):1413–1422.
 34. Werner BS, Chaoui J, Walch G. Glenosphere design affects range of movement and risk of friction-type scapular impingement in reverse shoulder arthroplasty. *Bone Joint J*. 2018;100-B(9):1182–1186.
 35. Liou W, Yang Y, Petersen-Fitts GR, Lombardo DJ, Stine S, Sabesan VJ. Effect of lateralized design on muscle and joint reaction forces for reverse shoulder arthroplasty. *J Shoulder Elbow Surg*. 2017;26(4):564–572.

36. Zhang M, Junaid S, Gregory T, Hansen U, Cheng CK. Effect of baseplate positioning on fixation of reverse total shoulder arthroplasty. *Clin Biomech (Bristol, Avon)*. 2019;62:15–22.
37. Friedman RJ, Barcel DA, Eichinger JK. Scapular notching in reverse total shoulder arthroplasty. *J Am Acad Orthop Surg*. 2019;27(6):200–209.
38. Kolmodin J, Davidson IU, Jun BJ, et al. Scapular notching after reverse total shoulder arthroplasty: prediction using patient-specific osseous anatomy, implant location, and shoulder motion. *J Bone Joint Surg Am*. 2018;100(13):1095–1103.
39. Tashjian RZ, Martin BI, Ricketts CA, Henninger HB, Granger EK, Chalmers PN. Superior baseplate inclination is associated with instability after reverse total shoulder arthroplasty. *Clin Orthop Relat Res*. 2018;476(8):1622–1629.
40. Barrett I, Remakrishnan A, Cheung E. Safety and efficacy of intraoperative computer-navigated versus non-navigated shoulder arthroplasty at a tertiary referral. *Orthop Clin North Am*. 2019;50(1):95–101.
41. Chebli C, Huber P, Watling J, Bertelsen A, Bicknell RT, Matsen F 3rd. Factors affecting fixation of the glenoid component of a reverse total shoulder prosthesis. *J Shoulder Elbow Surg*. 2008;17(2):323–327.
42. Churchill RS, Brems JJ, Kotschi H. Glenoid size, inclination, and version: an anatomic study. *J Shoulder Elbow Surg*. 2001;10:327–332.
43. Ho JC, Sabesan VJ, Iannotti JP. Glenoid component retroversion is associated with osteolysis. *J Bone Joint Surg Am*. 2013;95:e82.
44. Knowles NK, Ferreira LM, Athwal GS. Premorbid retroversion is significantly greater in type B2 glenoids. *J Shoulder Elbow Surg*. 2016;25(7):1064–1068.
45. Gregory TM, Sankey A, Augereau B, et al. Accuracy of glenoid component placement in total shoulder arthroplasty and its effect on clinical and radiological outcome in a retrospective, longitudinal, monocentric open study. *PLoS One*. 2013;8:2–8.
46. De Wilde LF, Berghs BM, VandeVyver F, Schepens A, Verdonk RC. Glenohumeral relationship in the transverse plane of the body. *J Shoulder Elbow Surg*. 2003;12(3):260–267.
47. Nyffeler RW, Werner CM, Gerber C. Biomechanical relevance of glenoid component positioning in the reverse Delta III total shoulder prosthesis. *J Shoulder Elbow Surg*. 2005;14:524–528.
48. Hsu JE, Namdari S, Baron M, et al. Glenoid perforation with pegged components during total shoulder arthroplasty. *Orthopedics*. 2014;37(6):e587–e591.
49. Ting FS, Poon PC. Perforation tolerance of glenoid implants to abnormal glenoid retroversion, anteversion, and medialization. *J Shoulder Elbow Surg*. 2013;22(2):188–196.
50. Aleem AW, Orvets ND, Patterson BC, Chamberlain AM, Keener JD. Risk of perforation is high during corrective reaming of retroverted glenoids: a computer simulation study. *Clin Orthop Relat Res*. 2018;476(8):1612–1619.