

Available online at www.sciencedirect.com

ScienceDirect

journal homepage: www.elsevier.com/locate/radcr

Case Report

Subdural hygroma after spontaneous rupture of an arachnoid cyst in a pediatric patient: A case report ^{☆,☆☆}

Gagandeep Singh, MD*, Amanda Zuback, BS, Rishabh Gattu, MD, German Kilimnik, MD, Anatoliy Vaysberg, MD

Neuroradiology Division, Department of Radiology, Newark Beth Israel Medical Center, 201 Lyons Avenue, Newark, NJ, USA

ARTICLE INFO

Article history:

Received 13 November 2020

Accepted 19 November 2020

Keywords:

Arachnoid cyst

Subdural hygroma

Spontaneous rupture

Papilledema

ABSTRACT

Arachnoid cysts are benign masses that represent a relatively small percentage of intracranial lesions. Spontaneous rupture of an arachnoid cyst resulting in a subdural hygroma is a very rare event. We report a case of a pediatric patient with a history of an arachnoid cyst and chronic headaches presenting with bilateral papilledema, worsening headaches, and no history of head trauma. Magnetic resonance imaging of the brain revealed an extra-axial cystic lesion in the right middle cranial fossa, similar to an arachnoid cyst seen on previous imaging. A new right subdural collection similar to the cerebral spinal fluid signal causing mass effect on brain parenchyma was determined to represent a subdural hygroma. Craniotomy was performed to evacuate the subdural hygroma as well as cyst fenestration. We report this case to emphasize the importance of considering spontaneous rupture of an arachnoid cyst as a differential diagnosis despite absence of head trauma.

© 2020 The Authors. Published by Elsevier Inc. on behalf of University of Washington.

This is an open access article under the CC BY-NC-ND license

(<http://creativecommons.org/licenses/by-nc-nd/4.0/>)

Introduction

An arachnoid cyst is a benign lesion composed of cerebral spinal fluid (CSF) that develops within the arachnoid membrane. Approximately 1% of all intracranial space-occupying masses are arachnoid cysts. They are often left-sided in the middle cranial fossa and affect males more frequently than

females [1,2]. Development of a subdural hematoma, intracystic hemorrhage, or subdural hygroma is a rare complication that can sometimes occur following head trauma [1,3,4]. Even rarer, a subdural hygroma can occur spontaneously with no history of trauma to the head [5]. We report a case of a female pediatric patient developing a spontaneous rupture of an arachnoid cyst in the right middle cranial fossa resulting in a subdural hygroma.

[☆] Competing Interest: The authors declare that they have no competing interests.

^{☆☆} Acknowledgments: This research received no external funding.

* Corresponding author.

E-mail address: gagan32092@gmail.com (G. Singh).

<https://doi.org/10.1016/j.radcr.2020.11.036>

1930-0433/© 2020 The Authors. Published by Elsevier Inc. on behalf of University of Washington. This is an open access article under the CC BY-NC-ND license (<http://creativecommons.org/licenses/by-nc-nd/4.0/>)

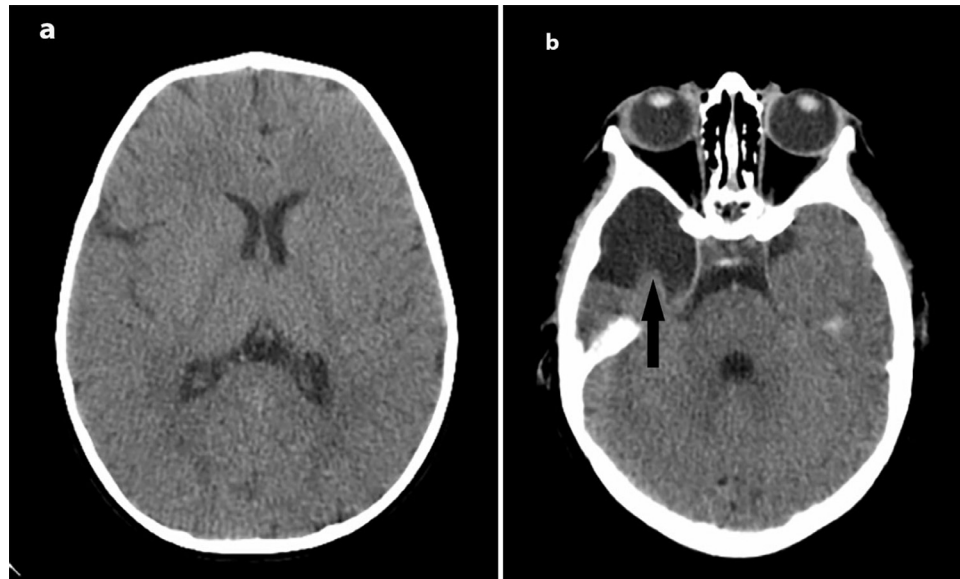


Fig. 1 – (a, b): Axial CT images at 8 months of age. An arachnoid cyst is seen along the right anterior temporal lobe (black arrow). The sulci, fissures, and cisterna are unremarkable. The ventricular system demonstrates no dilatation, distortion, or displacement. There is no displacement of the midline structures. No subdural collections are present in this study.

Case

An 11-year-old girl, with a history of an arachnoid cyst and chronic headaches, presented to the Emergency Department (ED) after being evaluated by her ophthalmologist due to concerns for increased intracranial pressure. The patient began developing chronic headaches between the ages of 5-7. The headaches had been progressively worsening for 2 months prior to her ED visit, localizing to the right frontal and parietal area with radiation down into the neck and arm. Additionally, she had been having photophobia as well as sensitivity to noises and smells. There was no history of recent traumas or inciting factors. Of note, at 8 months old, the patient had a computed tomography (CT) scan for macrocephaly, revealing a right anterior temporal arachnoid cyst with no evidence of rupture or displacement of midline structures (Fig. 1). The patient had multiple hospitalizations related to her headaches leading up to her ED visit. However, she was told it was due to migraines, treated conservatively, and sent home. The patient was found to have bilateral papilledema and vision loss in her lower eye fields during an ophthalmology visit, resulting in her being sent to the ED. An magnetic resonance (MR) imaging of the brain revealed an extra-axial cystic lesion in the right middle cranial fossa following the CSF signal on all sequences, measuring approximately $4.6 \times 3.6 \times 3.3$ cm (AP, TV, CC), grossly similar to the right middle cranial fossa arachnoid cyst seen on prior CT of the head. The presence of a new right subdural collection follows CSF signal on all sequences measures approximately 10 mm in maximal thickness, representing a subdural hygroma, causing mass effect on the underlying brain parenchyma with 7-mm leftward midline shift (Fig. 2). In the setting of no given history of trauma, it was determined these findings were likely to be due to spontaneous

arachnoid cyst rupture resulting in right convexity subdural hygroma with resultant elevated intracranial pressure as evidenced by ophthalmologic exam. The patient underwent a craniotomy performed to evacuate the subdural hygroma and fenestration of the arachnoid cyst. The patient tolerated the procedure well.

Discussion

Arachnoid cysts are composed of an accumulation of CSF in between the layers of the arachnoid membrane [3,4]. Due to the increase in usage of cross-sectional diagnostic imaging in recent years, most arachnoid cysts are found incidentally [1,3,6]. Patients are often asymptomatic with the cyst remaining stable [2,7]. In some instances, the mass may resolve without any treatment [4]. Arachnoid cysts can become symptomatic in cases where they enlarge in size or rupture resulting in a subdural hygroma, subdural hematoma, or intracystic hemorrhage [7]. The most common presenting symptom associated with arachnoid cysts is headache [1].

Trauma to the head can cause an arachnoid cyst to rupture. However, the spontaneous rupture of an arachnoid cyst is a rare occurrence [7]. A literature review by Balestrino et al [7] revealed 57 cases of spontaneous rupture of an arachnoid cyst found in the literature with an additional 17 pediatric cases of spontaneously ruptured arachnoid cysts treated surgically was reported by the authors in their case series. Of the 57 cases in the literature review, a minority of the reported cases resulted in specifically a subdural hygroma. However, the mean age of the 57 cases was also higher than that of the 17 pediatric cases reported. Interestingly, of the 17 cases in the case series, most ruptured arachnoid cysts resulted in a subdural

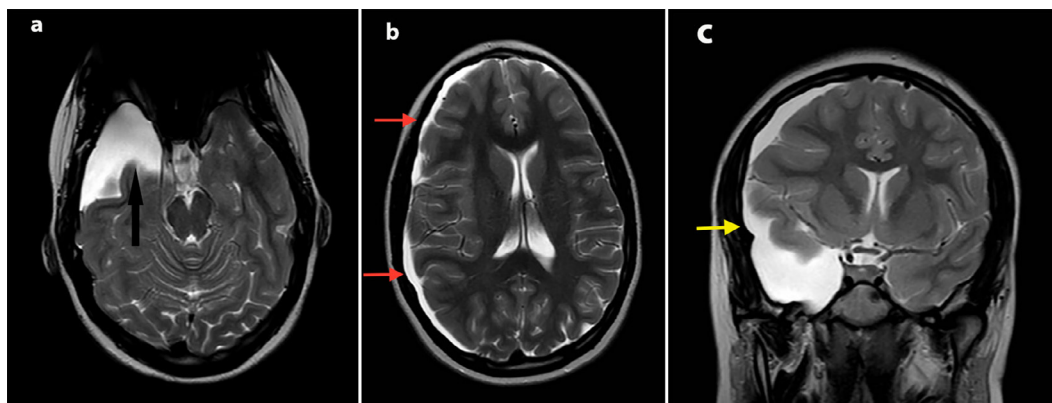


Fig. 2 – (a-c): Axial (a) T2 MR image of an extra-axial cystic lesion in 11-year-old, in the right middle cranial fossa following CSF signal (black arrow). Axial (b) T2 MR image of the subdural hygroma measuring 10 mm in maximal thickness seen along the entire right cerebral convexity (red arrows) causing mass on the underlying brain parenchyma and causing approximately 7-mm leftward midline shift. Coronal (c) T2 MR image showing communication between the right arachnoid cyst and the right cerebral convexity subdural hygroma (yellow arrow). (Color version of figure is available online.)

hygroma. This literature review and case series highlight the rarity of this pathology.

Subdural hygromas resulting from an arachnoid cyst rupture are thought to result from a tear of the cyst membrane through trauma, manipulation, or spontaneously. It is possible that unreported head trauma could also be the cause of this event. Others believe cyst rupture leading to a hygroma can be explained by a focal increase in intracranial pressure from Valsalva maneuvers [8].

The most common sign of arachnoid cyst rupture on imaging is a collection in the subdural space [7]. In our case, an extra-axial cystic lesion was identified and followed the CSF signal on all MR sequences, similar to the arachnoid cyst seen on previous CT imaging. The new subdural collection also followed the CSF signal on all MR sequences. Given the absence of a history of head trauma and imaging results, it was deduced that these findings likely represented a spontaneous rupture of an arachnoid cyst resulting in a subdural hygroma.

Due to the infrequency of this phenomenon, the timing as well as the type of appropriate treatment to manage this pathology remains controversial. Some treatments that have been suggested include craniotomy or burr holes to drain subdural fluid, fenestration of the cyst, and shunting of cerebral spinal fluid [4,7]. Conservative management with steroids or acetazolamide has also been reported [7,9]. In our case, the subdural hygroma was causing midline shift of structures as well as symptoms of increased intracranial pressure necessitating a craniotomy and cyst fenestration.

Conclusion

This case illustrates the importance of recognizing the possibility of a spontaneous rupture of an arachnoid cyst. Previously diagnosed arachnoid cyst in conjunction with

clinical presentation, despite the absence of head trauma, should prompt consideration of this phenomenon as a differential diagnosis. Although a rare occurrence, the inclusion of this differential can prevent misdiagnosis and facilitate efficient evaluation.

REFERENCES

- [1] Gosalakal JA. Intracranial arachnoid cysts in children: a review of pathogenesis, clinical features, and management. *Pediatr Neurol* 2002;26:93–8.
- [2] Poirrier AL, Ngosso-Tetanye I, Mouchamps M, Misson JP. Spontaneous arachnoid cyst rupture in a previously asymptomatic child: a case report. *Eur J Paediatr Neurol* 2004;8:247–51.
- [3] Adin ME, Yıldız MS, Deniz MA, Behzadi AH, Mata-Mbemba D. Arachnoid cysts with spontaneous intracystic hemorrhage and associated subdural hematoma: report of management and follow-up of 2 cases. *Radiol Case Rep* 2018;13:516–21.
- [4] Khilji MF, Jeswani NL, Hamid RS, Al Azri F. Spontaneous arachnoid cyst rupture with subdural hygroma in a child. *Case Rep Emerg Med* 2016;2016:6964713.
- [5] Bora A, Yokuş A, Batur A, Bulut MD, Yavuz A, Gülşen I, et al. Spontaneous rupture of the middle fossa arachnoid cyst into the subdural space: case report. *Pol J Radiol* 2015;80:324–7.
- [6] Chen Y, Fang HJ, Li ZF, Yu SY, Li CZ, Wu ZB, et al. Treatment of middle cranial fossa arachnoid cysts: a systematic review and meta-analysis. *World Neurosurg* 2016;92:480–90 e482.
- [7] Balestrino A, Piatelli G, Consales A, Cama A, Rossi A, Pacetti M, et al. Spontaneous rupture of middle fossa arachnoid cysts: surgical series from a single center pediatric hospital and literature review. *Childs Nerv Syst* 2020;36:2789–99.
- [8] Maher CO, Garton HJ, Al-Holou WN, Trobe JD, Muraszko KM, Jackson EM. Management of subdural hygromas associated with arachnoid cysts. *J Neurosurg Pediatr* 2013;12:434–43.
- [9] Choong CT, Lee SH. Subdural hygroma in association with middle fossa arachnoid cyst: acetazolamide therapy. *Brain Dev* 1998;20:319–22.