

# Alpha Fetoprotein-Secreting Gastric Cancer in the Setting of Chronic Hepatitis B: The Role of Endoscopy

Stephen Ip, MD<sup>1</sup>, David F. Schaeffer, MD, FRCPC<sup>2</sup>, Eric M. Yoshida, MD, FRCPC<sup>1</sup>, and WC Peter Kwan, MD, FRCPC<sup>1</sup>

<sup>1</sup>Division of Gastroenterology, University of British Columbia, Vancouver, British Columbia, Canada

<sup>2</sup>Department of Pathology and Laboratory Medicine, University of British Columbia, Vancouver, British Columbia, Canada

## Abstract

Alpha-fetoprotein (AFP) is a common tumor marker for hepatocellular carcinoma (HCC). We report a unique case of an AFP-producing gastric cancer in an elderly man with known chronic hepatitis B (HBV) and a markedly elevated AFP. Thorough diagnostic imaging failed to reveal a HCC, but a gastric adenocarcinoma was found on endoscopy. After successful resection, the serum AFP normalized. On histopathologic examination, the cancer demonstrated focal positive staining for AFP, in keeping with a hepatoid gastric adenocarcinoma. Endoscopy should be considered in clinical situations where increased serum AFP is detected but no HCC is found.

## Introduction

Alpha-fetoprotein (AFP) is a common tumor marker for hepatocellular carcinoma (HCC). Rising serum AFP in a patient with cirrhosis or hepatitis B (HBV) should raise suspicion of a developing HCC. However, AFP may be elevated in other malignancies, of which gastric cancer is the most common after HCC and tumors of gonadal origin.<sup>1</sup> AFP-producing gastric cancer (AFPGC) has been reported sporadically since 1970,<sup>2-6</sup> including several recent case series from Asia.<sup>7-9</sup> Our report adds to the growing literature of this rare entity and illustrates the importance of considering endoscopy in a patient with elevated AFP when investigative efforts for HCC are fruitless.

## Case Report

An 81-year-old Asian man was followed by his gastroenterologist for chronic HBV and was treated with tenofovir, resulting in undetectable HBV viral load. He did not have cirrhosis or other comorbidities. The patient complained of early satiety, anorexia, weight loss (>4.5 kg), and right-sided chest pain over several months on a follow-up visit. His physical examination showed normal cardiovascular and respiratory function and no appreciable lymphadenopathy. His abdominal exam was benign, with no detectable ascites, no hepatosplenomegaly, and no masses. Laboratory investigations demonstrated a normocytic anemia (hemoglobin 98 g/L, previously 140 g/L) and an elevated AFP of 45 mcg/L (normal: <4.4 mcg/L), while his remaining bloodwork was within normal limits. Given his underlying HBV, exhaustive efforts were directed at identifying a hepatic neoplasm, but computed tomography (CT) and magnetic resonance imaging (MRI) failed to reveal a liver lesion. However, his AFP gradually increased to 540 mcg/L over the ensuing 2 months.

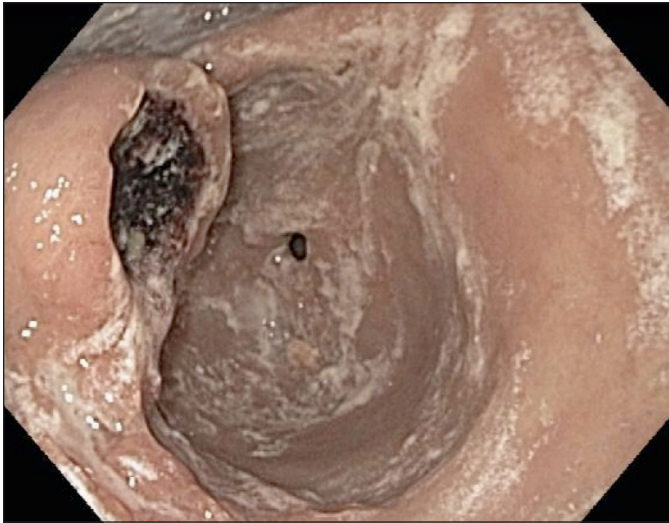
The patient then presented with an acute upper gastrointestinal bleed. He described a 1-week history of melena with no hematemesis or hematochezia. Laboratory tests revealed a hemoglobin of 80 g/L, and normal elec-

ACG Case Rep J 2015;2(3):152-154. doi:10.14309/crj.2015.38. Published online: April 10, 2015.

**Correspondence:** Dr. Stephen Ip, GI Fellow, and Dr. Eric M. Yoshida, Head, Division of Gastroenterology, Vancouver General Hospital, University of British Columbia, 5th Floor, 2775 Laurel Street, Vancouver, BC, Canada V5Z 1M9 (stevetgp@hotmail.com; eric.yoshida@vch.ca).



**Copyright:** © 2015 Ip et al. This work is licensed under a Creative Commons Attribution-NonCommercial-NoDerivatives 4.0 International License. To view a copy of this license, visit <http://creativecommons.org/licenses/by-nc-nd/4.0>.



**Figure 1.** Upper endoscopy revealed a 3-cm ulcerated mass in the lesser curvature of the stomach.

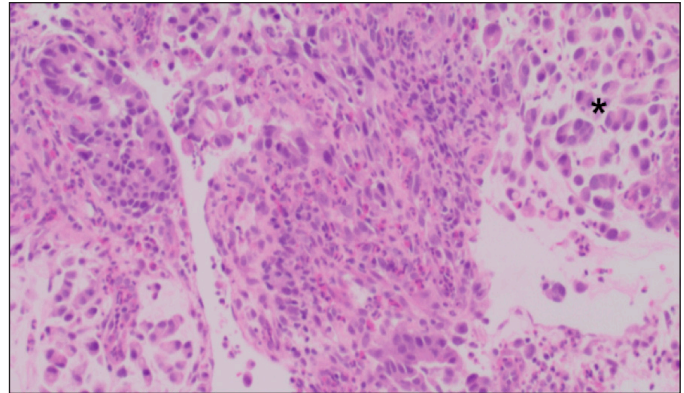
trolytes and renal function except for elevated urea of 9.1 mmol/L. Upper endoscopy revealed a large, 3-cm ulcerated mass with friable, irregular edges along the lesser curvature confined to the antrum with no extension into the pylorus (Figure 1). Biopsies showed an invasive, moderately differentiated gastric adenocarcinoma with intestinal differentiation. Larger cells were also present, in keeping with a focal hepatoid differentiation (Figure 2). Immunohistochemical staining was negative for Her2/neu and focally positive for AFP.

Staging CT showed no metastatic spread of the disease. The patient received neoadjuvant chemotherapy and subsequent partial gastrectomy. Postoperatively, the patient's AFP levels normalized, and have remained normal nearly 2 years later.

## Discussion

AFPGCs are rare, accounting for only 1-6% of gastric cancers.<sup>9</sup> They are often associated with liver and lymph node metastases and a poorer prognosis, and outside Japan and parts of Asia, they are underrecognized.<sup>6-9</sup> Our patient had chronic HBV, while in previous case series of AFPGCs, patients with chronic viral hepatitis, HCC, and/or fatty liver were excluded<sup>7-8</sup> or their hepatitis statuses were not clearly documented.<sup>9</sup>

Pathologic examination of our patient's biopsy demonstrated focal hepatoid differentiation consistent with hepatoid adenocarcinoma of the stomach (HAS). This term was originally proposed by Ishikura et al to describe primary gastric cancers with hepatocytic differentiation and large produc-



**Figure 2.** Histology showing a poorly differentiated gastric adenocarcinoma. By morphology, the tumor cells were not cohesive but showed a hepatoid differentiation (marked by \*), further highlighted by positivity for AFP by immunohistochemistry.

tion of AFP.<sup>10</sup> HAS is classified similarly to other AFPGCs, but this variant only accounts for 0.38-0.78% of all gastric cancers.<sup>7-11</sup> HAS predominantly affects males (3.2:1), and average age of 63.3 years.<sup>12</sup> Given its clinical and pathological similarities to HCC, prompt diagnosis of hepatoid adenocarcinoma can be difficult, especially in endemic areas with a high incidence of HCC.<sup>12</sup>

As in our case report, previous reports have found that with appropriate treatment of AFPGCs such as surgery and/or chemotherapy,<sup>3-6</sup> AFP levels will decrease. Conversely, with recurrent disease, AFP levels will increase again, suggesting that AFP can serve as a surrogate marker for disease burden. The presence of liver metastases are an important prognostic factor when compared to those with non-AFPGCs,<sup>13</sup> suggesting that decreasing AFP levels in AFPGCs may be associated with better quality of life and presumably improved survival.

Because of the obvious risk factor of HBV for potentially causing HCC in our case, initial investigative efforts were directed at detecting a HCC. A recently reported case described a patient who also had an unexplained elevated AFP level in the setting of chronic HBV cirrhosis, where variceal screening revealed an AFPGC.<sup>6</sup> In contrast, because our patient had no known cirrhosis, he would not have undergone similar screening.

Although AFPGCs have been recognized in Japan and parts of Asia for more than 40 years, there are few publications about AFPGCs outside of Asia. We highlight that clinicians should consider this entity in geographic locations with growing Asian immigrant populations. Given the aggressive nature of AFPGCs, this malignancy should be included in the differential diagnosis of an elevated AFP. Endoscopy is an appropriate next test if initial imaging is negative.

## Disclosures

Author contributions: S. Ip drafted the manuscript. DF Schaeffer provided the pathologic data and photographs. EM Yoshida and WCP Kwan critically revised and approved the manuscript. EM Yoshida is the article guarantor.

Financial disclosure: None to report.

Informed consent was obtained for this case report.

Received: October 28, 2014; Accepted: February 17, 2015

## References

1. Wu JT. Serum alpha-fetoprotein and its lectin reactivity in liver diseases: A review. *Ann Clin Lab Sci*. 1990;20(2):98–105.
2. Bourreille J, Metayer P, Sauger F, et al. Existence d'alphafoetoproteine au cours d'un cancer secondaire du foie d'origine gastrique. [Article in French.] *Presse Med*. 1970;78(28):1277–78.
3. Chang YC, Nagasue N, Abe S, et al. Alpha fetoprotein producing early gastric cancer with liver metastasis: Report of three cases. *Gut*. 1991;32(5):542–45.
4. Tsurumachi T, Yamamoto H, Watanae K, et al. Resection of liver metastasis from alpha-fetoprotein-producing early gastric cancer: Report a case. *Surg Today*. 1997;27(6):563–66.
5. Shibata Y, Sato K, Kodama M, et al. Alpha-fetoprotein-producing early gastric cancer of the remnant stomach: Report of a case. *Surg Today*. 2007;37(11):995–99.
6. Gallo P, Gentilucci UV, Taffon C, et al. A challenging alfa-fetoprotein in a cirrhotic patient. *Acta Gastroenterol Belg*. 2014;77(1):66–7.
7. Lin HJ, Hsieh YH, Fang W, et al. Clinical manifestations in patients with alpha-fetoprotein-producing gastric cancer. *Curr Oncol*. 2014;21(3):e394–9.
8. Liu X, Cheng Y, Sheng W, et al. Clinicopathologic features and prognostic factors in alpha-fetoprotein-producing gastric cancers: Analysis of 104 cases. *J Surg Oncol*. 2010;102(3):249–55.
9. Inoue M, Sano T, Kuchiba A, et al. Long-term results of gastrectomy for alpha-fetoprotein-producing gastric cancer. *Br J Surg*. 2010;97(7):1056–61.
10. Ishikura H, Fukasawa Y, Ogasawara K et al. An AFP producing gastric carcinoma with features of hepatic differentiation. A case report. *Cancer*. 1985;56(4):840–8.
11. Gao YB, Zhang DF, Jin XL, et al. Preliminary study on the clinical and pathological relevance of gastric hepatoid adenocarcinoma. *J Dig Dis*. 2007;8(1):23–8.
12. Su JS, Chen YT, Wang RC, et al. Clinicopathological characteristics in the differential diagnosis of hepatoid adenocarcinoma: A literature review. *World J Gastroenterol*. 2013;19(3):321–7.
13. Li X-D, Wu C-P, Ji M, et al. Characteristic analysis of  $\alpha$ -fetoprotein-producing gastric carcinoma in China. *World J Surg Oncol*. 2013;11:246–52.

## Publish your work in ACG Case Reports Journal

ACG Case Reports Journal is a peer-reviewed, open-access publication that provides GI fellows, private practice clinicians, and other members of the health care team an opportunity to share interesting case reports with their peers and with leaders in the field. Visit <http://acgcasereports.gi.org> for submission guidelines. Submit your manuscript online at <http://mc.manuscriptcentral.com/acgcr>.