

A Case Series of Patients with Isolated IgG4-related Hypophysitis Treated with Rituximab

Hessa Boharoon,^{1,*} James Tomlinson,^{2,*} Clara Limback-Stanic,³ Anastasia Gontsorova,⁴ Niamh Martin,^{1,5} Emma Hatfield,¹ Karim Meeran,^{1,5} Ramesh Nair,⁶ Nigel Mendoza,⁶ Jeremy Levy,^{2,5} Steve McAdoo,² Charles Pusey,² and Florian Wernig¹

¹Department of Endocrinology, Hammersmith Hospital, Imperial College Healthcare NHS Trust, London, UK; ²Renal Unit, Hammersmith Hospital, Imperial College Healthcare NHS Trust, London, UK; ³Department of Cellular Pathology, Imperial College Healthcare NHS Trust, London, UK; ⁴Department of Neuroradiology, Imperial College Healthcare NHS Trust, London, UK; ⁵Division of Diabetes, Endocrinology and Metabolism, Imperial College London, London, UK; and ⁶Department of Neurosurgery, Imperial College Healthcare NHS Trust, London, UK

*Joint first authors.

ORCID numbers: 0000-0001-5914-9318 (F. Wernig).

Context: The acute presentation of immunoglobulin G4 (IgG4)-related hypophysitis can be indistinguishable from other forms of acute hypophysitis, and histology remains the diagnostic gold standard. The high recurrence rate necessitates long-term immunosuppressive therapy. Rituximab (RTX) has been shown to be effective in systemic IgG4-related disease (IgG4-RD), but experience with isolated pituitary involvement remains limited.

Case Description: We report 3 female patients with MRI findings suggestive of hypophysitis. All patients underwent transsphenoidal biopsy and fulfilled diagnostic criteria for IgG4-related hypophysitis. Treatment with glucocorticoids (GCs) resulted in good therapeutic response in Patients 1 and 2, but the disease recurred on tapering doses of GCs. GC treatment led to emotional lability in Patient 3, necessitating a dose reduction. All 3 patients received RTX and Patients 2 and 3 received further courses of treatment when symptoms returned and B-cells repopulated. Patient 3 did not receive RTX until 12 months from the onset of symptoms. Patient 1 was not able to have further RTX treatments due to an allergic reaction when receiving the second dose. Rituximab treatment resulted in sustained remission and full recovery of anterior pituitary function in Patients 1 and 2, with complete resolution of pituitary enlargement. By contrast, Patient 3 only showed a symptomatic response following RTX treatment, but pituitary enlargement and hypofunction persisted.

Conclusion: Rituximab treatment for IgG4-related hypophysitis resulted in sustained remission in 2 patients treated early in the disease process but only achieved partial response in a patient with chronic disease, suggesting that early therapeutic intervention may be crucial in order to avoid irreversible changes.

© Endocrine Society 2020.

This is an Open Access article distributed under the terms of the Creative Commons Attribution-NonCommercial-NoDerivs licence (<http://creativecommons.org/licenses/by-nc-nd/4.0/>), which permits non-commercial reproduction and distribution of the work, in any medium, provided the original work is not altered or transformed in any way, and that the work is properly cited. For commercial re-use, please contact journals.permissions@oup.com

Key Words: IgG-4 related hypophysitis, Rituximab, IgG4-related disease, pituitary

Abbreviations: ACTH, adrenocorticotrophic hormone; FSH, follicle-stimulating hormone; LH, luteinizing hormone; GH, growth hormone; IGF-1, insulin-like growth factor-1.

Received 30 March 2020

Accepted 17 April 2020

First Published Online 21 April 2020

Corrected and Typeset 8 June 2020

June 2020 | Vol. 4, Iss. 6

doi: 10.1210/endo/bvaa048 | Journal of the Endocrine Society | 1–9

Context

The term IgG4-related disease (IgG4-RD) has been used to describe a group of immune-mediated fibroinflammatory disorders, which share distinctive clinical and histopathological features and commonly involve multiple organs [1, 2]. Pituitary involvement appears to be rare and, if present, can either occur in the context of multiorgan disease or present as primary hypophysitis [3–5]. Isolated IgG4-related hypophysitis seems to be more prevalent than previously thought [6]. A recent retrospective study re-examining the histology of all cases of primary hypophysitis concluded that more than 40% of cases fulfilled the histological criteria of IgG4-related pituitary disease proposed by Leporati: “Mononuclear infiltration of the pituitary gland, rich in lymphocytes and plasma cells, with more than 10 IgG4-positive cells per high-power field” [7, 8]. Although IgG4-RD tends to respond well to high-dose glucocorticoids (GC) therapy initially, disease recurrence invariably occurs on tapering GC doses [9]. Morbidity of long-term GC exposure can be significant. Efficacy in achieving remission by adding conventional steroid-sparing agents does not appear to be superior to GC monotherapy [10]. Recently, B-cell depletion therapy with the monoclonal anti-CD20 antibody Rituximab (RTX) has shown to be highly effective in achieving sustained remission of IgG4-RD [11]. To date, there is only 1 published case report of isolated IgG4-related hypophysitis treated with RTX in a teenage girl presenting with hypophysitis, who initially underwent surgical resection of the pituitary mass [12]. Here we present a case series of 3 young female patients with histologically confirmed IgG4-related hypophysitis on pituitary biopsy and no other obvious organ involvement apart from the pituitary, all of whom received treatment with RTX following remission induction with GCs.

Case descriptions

Patient 1. A 22-year-old nulliparous woman of mixed ethnic origin was admitted via the Accident and Emergency department with a 12-month history of worsening headaches, polyuria, and polydipsia (Table 1). Her past medical history included migraines and asthma. She did not take any regular medications. Pituitary MRI showed an enlarged and diffusely enhancing pituitary gland extending into the suprasellar cistern, with adjacent dural enhancement. Visual fields were normal. Initial biochemical evaluation revealed normal prolactin of 393 mIU/L [71–566]. Thyroid function was normal. Early morning cortisol was 172 nmol/L and ACTH 18.6 ng/L. She had a progestogen-only contraceptive implant in situ and estradiol was undetectable, with FSH 5.6 IU/L and LH 2.8 IU/L (Table 2). Full blood count was normal and erythrocyte sedimentation rate (ESR) was 34 mm/hour [1–5]. Cerebrospinal fluid (CSF) analysis was unremarkable. Both serum and CSF angiotensin converting enzyme (ACE) levels were normal. Serum IgG4 levels at presentation were not elevated (0.85 g/L, NR < 1.3). GC and desmopressin replacement were commenced and she underwent transsphenoidal pituitary biopsy. Histology revealed a lymphoplasmacytic infiltrate with focal granulomatous inflammation (Fig. 1). The infiltrate contained numerous IgG4-positive plasma cells (> 10 per high-power field). A tapering course of prednisolone starting at 30 mg per day resulted in the improvement of her headaches, polyuria, and polydipsia. Full resolution of diabetes insipidus was confirmed by a water deprivation test. However, her headache returned following the reduction of prednisolone, and the dose had to be increased. As a result, she gained a significant amount of weight and therefore received RTX (two 1000 mg doses, 2 weeks apart) 4 months after her initial presentation, with full resolution of her symptoms. Twelve months later, her symptoms returned and she received a further dose of RTX but developed an allergic reaction, and the infusion had to be discontinued early. Despite her not having received the full dose, her headaches resolved and the pituitary enlargement almost fully normalized (Fig. 2). Her B cells remained deplete for 8 months. Ten months later, her symptoms recurred once again. She was therefore challenged with a different anti-CD20 monoclonal antibody, Ofatumumab. Unfortunately, once again she developed an allergic reaction 20 minutes into the infusion, which had to

Table 1. Patient characteristics, presenting symptoms, histology and endocrine dysfunction at presentation

Patient	Age at Presentation	Sex	Ethnicity	Presenting Symptoms	Time of Onset of Symptoms to Presentation	Visual Fields	Histology	IgG4	Endocrine Dysfunction at Presentation
Patient 1	22	F	Mixed	Headaches, polyuria, and polydipsia.	12 months	Normal	Lymphoplasmacytic infiltrate with focal granulomatous inflammation.	>10/ HPF	ACTH deficiency, diabetes insipidus.
Patient 2	35	F	Asian Pakistani	Headaches, polyuria, and polydipsia.	4 months	Bitemporal hemianopia.	Lymphocytic hypophysitis.	>10/ HPF	ACTH deficiency, diabetes insipidus, secondary hypothyroidism.
Patient 3	34	F	Asian or Asian British—Indian	Headaches, secondary amenorrhea, polyuria, and polydipsia.	24 months	Partial bitemporal hemianopia.	Lymphocytic hypophysitis.	10 - 30 / HPF	ACTH deficiency, secondary hypothyroidism, hypogonadotropic hypogonadism, diabetes insipidus.

Table 2. Serum IgG4 levels and biochemical profiles at presentation

Results	Patient 1	Patient 2	Patient 3
IgG4 (g/L)	0.85 [<1.3]	1.53 [<1.3]	0.55 [<1.3]
ESR (mm/hr)	34 [0–17]	17 [0–17]	54 [0–17]
Prolactin (mIU/L)	393 [100–500]	1,076 [100–500]	909 [100–500]
TSH (mIU/L)	1.02 [0.3–4.2]	1.27 [0.3–4.2]	2.35 [0.3–4.2]
Free T4 (pmol/L)	9.6 [9–23]	4.6 [9–23]	12.8 [9–23]
ACTH (ng/L)	18.6	9.9	N/A
Cortisol (am) (nmol/L)	172	51	296
FSH (IU/L)	FSH 5.6	2.6	6.4
LH (IU/L)	LH 2.8	1.0	2.1
Estradiol (pmol/L)	Undetectable (hormonal contraceptive implant)	Undetectable	98
IGF-1 (nmol/L)	19.5 [11–46]	35.8 [10–38]	22.9 [10–38]

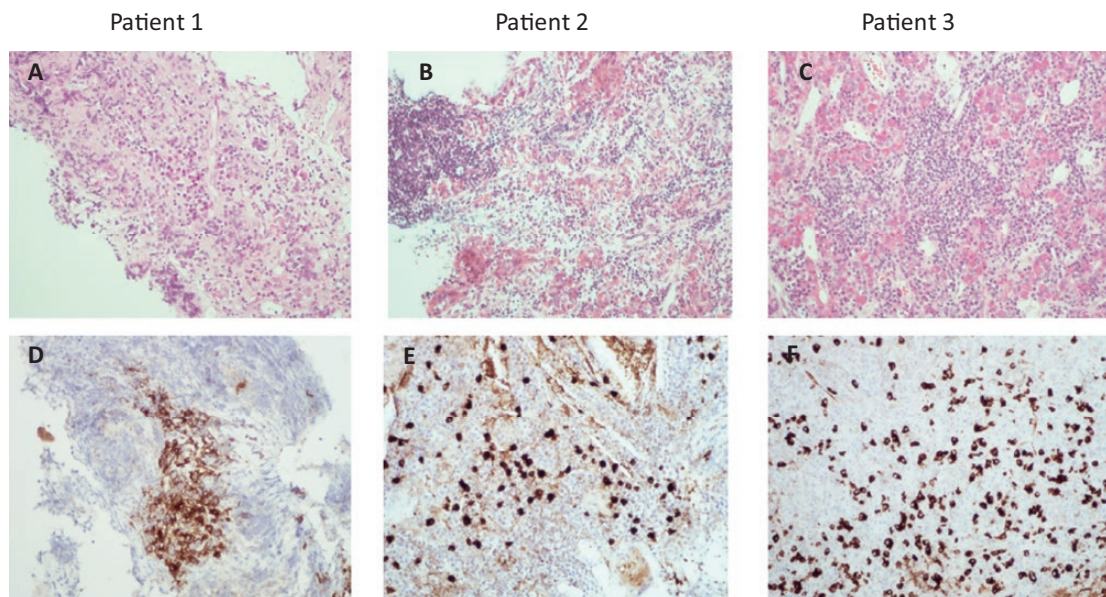


Figure 1. Histopathological features of the pituitary biopsies from Patients 1–3. Hematoxylin and eosin staining (upper panel) and anti-IgG4 immunohistochemical staining (lower panel). **A:** Patient 1, adenohypophysis with lymphoplasmacytic inflammatory infiltrates and focal granulomatous formation. The inflammatory infiltrate (**D**) contains numerous IgG4-positive plasma cells (> 10/HPF). **B:** Patient 2, extensive lymphoplasmacytic inflammatory infiltration of the anterior pituitary. Many IgG4-positive plasma cells (> 10/HPF) are present (**E**). **C:** Patient 3, adenohypophysis with lymphocytoplasmacytic inflammatory infiltrates and xanthogranulomatous changes. The inflammatory infiltrate contains abundant (10–30/HPF) IgG4-positive plasma cells (**F**).

be discontinued. Despite the short infusion of Ofatumumab, complete B-cell depletion was achieved, lasting for 4 months. Her symptoms significantly improved and she remains in full remission. There has been continuous improvement of the pituitary MRI findings without any significant pituitary enlargement (Fig. 2).

Patient 2. A 38-year-old woman (gravida 2, para 2) of Pakistani-Asian origin presented with a 4-month history of headaches, blurred vision, polydipsia, and polyuria (Table 1). Her second pregnancy was delivered via an elective caesarian section. She had no other past medical history. She had been taking a progesterone-only contraceptive pill for several years. She was found

to have elevated prolactin of 1076 mIU/L [102–496], and a subsequent pituitary MRI revealed a pituitary mass elevating and compressing the optic chiasm, with adjacent dural enhancement. Visual field testing confirmed bitemporal hemianopia. Initial laboratory investigations showed low free thyroxine of 4.6 pmol/L [12–22] and low thyroid stimulating hormone (TSH) of 1.27 mIU/L [0.27–4.2]. She was taking a progesterone-only pill and estradiol was undetectable, with FSH of 2.6 IU/L and LH of 1.0 IU/L (Table 2), and late morning cortisol was 51 nmol/L. Full blood count was normal and ESR was 17 mm/hour. GC replacement and levothyroxine were commenced. Desmopressin was started following the confirmation of cranial diabetes insipidus by a water deprivation test. Serum ACE was normal. She underwent trans-sphenoidal pituitary biopsy and histology showed extensive infiltration of anterior pituitary tissue with lymphocytes and IgG4-positive plasma cells, fulfilling the diagnostic criteria proposed by Leporati for IgG4-related hypophysitis [7] (Fig. 1). A modest elevation of serum IgG4 levels at 1.53 g/L (NR < 1.3) further supported the diagnosis of IgG4-related hypophysitis. A CT of the chest, abdomen, and pelvis did not reveal any features of systemic IgG4-related disease. A tapering course of prednisolone starting at 60 mg per day was initiated, resulting in rapid symptomatic relief, improvement of visual fields, and normalization of the serum IgG4 concentration (0.53 g/L). Reduction of prednisolone, however, led to the recurrence of her symptoms, necessitating an escalation of her GC dose. Therefore, RTX was started as second-line treatment. Rituximab resulted in full resolution of her symptoms and a significant reduction in the size of the pituitary mass on MRI (Fig. 3). She remained fully asymptomatic for almost 1 year before her headaches returned. She received further RTX with excellent response to

Patient 1

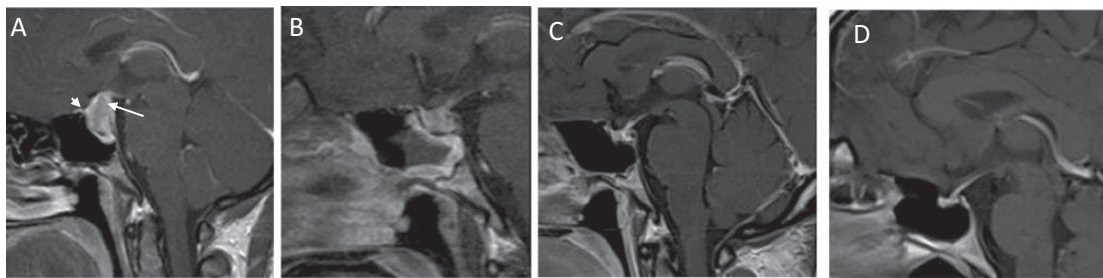


Figure 2. Sagittal postcontrast T1W MR images of the pituitary. **A:** Pretreatment scan showing an enlarged and diffusely enhancing pituitary gland extending into the suprasellar cistern (long white arrow) with adjacent dural enhancement (short white arrow). **B:** Image following GC and RTX treatment showing the initial response to treatment with significant reduction in the size of the pituitary mass. **C:** Image following further RTX treatment showing substantial reduction in the size of the pituitary mass. **D:** Image following treatment with Ofatumumab, demonstrating full normalization of the pituitary gland.

Patient 2

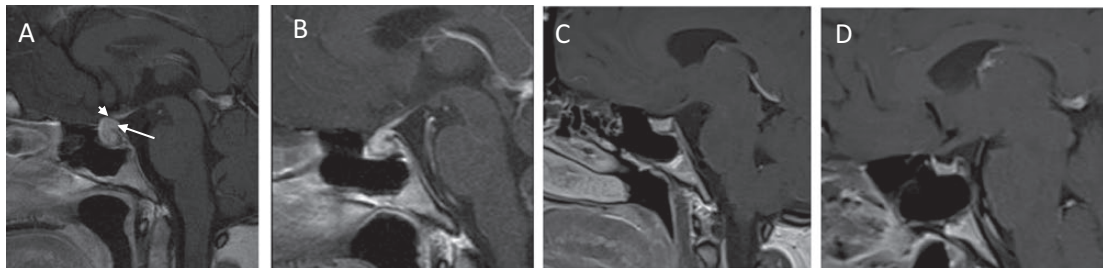


Figure 3. Sagittal postcontrast T1W MR images of the pituitary. **A:** Pretreatment scan showing a pituitary mass (long white arrow) elevating and compressing the optic chiasm (short white arrow). **B:** Image following remission induction with GC treatment, demonstrating mild reduction in the size of the pituitary mass. **C:** Image following the first cycle of RTX treatment showing significant reduction in the size of the pituitary mass. **D:** Image 6 months after RTX showing substantial reduction in the volume of the pituitary gland.

treatment. She was able to wean her GCs completely and her anterior pituitary function fully recovered. Further imaging confirmed full radiological resolution of the pituitary mass (Fig. 3). About 9 months later, a further clinical and radiological recurrence associated with an increase in total B-lymphocytes was treated with further RTX. Currently, she receives RTX every 6 to 9 months for remission maintenance (depending on symptoms and B-cell counts), aiming for B-cell depletion for 2 years (Fig. 4).

Patient 3. A 36-year-old nulliparous woman of Indian–Asian descent presented with a 2-year history of headaches, amenorrhea, polyuria, and polydipsia (Table 1). She had no past medical history and did not take any regular medications. At presentation, prolactin was 909 mIU/L [100–500], free T4 12.8 pmol/L [12–22], TSH 2.35 mIU/L [0.27–4.2], estradiol 98 pmol/L, FSH 6.4 IU/L, LH 2.1 IU/L, and morning cortisol 296 nmol/L (Table 2). Visual field testing revealed incomplete bitemporal hemianopia. Pituitary MRI showed an enhancing sellar and suprasellar mass lesion involving the pituitary stalk and compressing the optic chiasm and left optic nerve. Cerebrospinal fluid analysis was normal. Both serum and CSF ACE levels were normal. Serum IgG4 was not elevated (0.55 g/L). Full blood count was normal and ESR was 54 mm/hr. Cranial diabetes insipidus was confirmed by a water deprivation test. One month later, she also developed secondary hypothyroidism (free T4 6.4 IU/L, TSH 2.85 mIU/L). She commenced GC replacement (hydrocortisone 10 mg, once daily), levothyroxine (50 mcg daily), and desmopressin (100 mcg at night). A CT of the chest, abdomen, and pelvis were normal. She underwent transsphenoidal pituitary biopsy, and histological analysis confirmed a diagnosis of lymphocytic hypophysitis with IgG4-positive plasma cells ranging between 10 and 30 per high-power field in different biopsy areas (Fig. 1). She commenced a tapering course of prednisolone starting at 60 mg per day. She became very irritable and emotionally labile on high-dose prednisolone, but her headaches worsened when the GC dose was reduced. She therefore received RTX, although notably the first dose was more than 2 years after her initial presentation. Her headaches and visual fields improved but recurring symptoms led to 2 further courses of RTX between 9 and

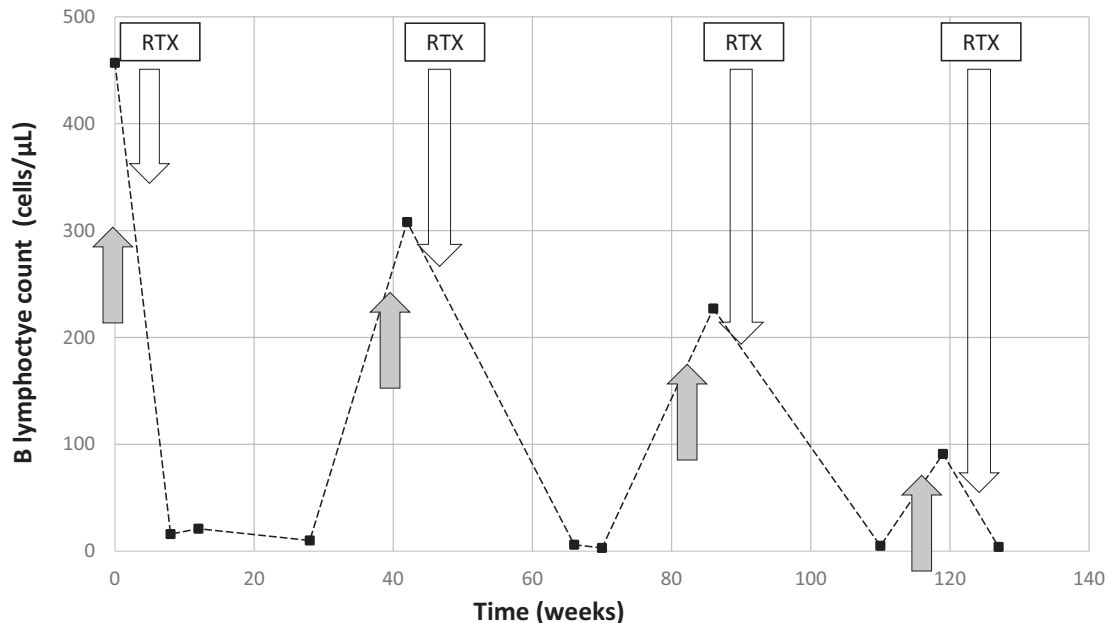


Figure 4. Patient 2. Correlation of symptoms, total B lymphocyte count (y-axis, cells/ul) and RTX treatments. Total B lymphocyte count, normal reference range 100 to 500 cells/ul. Rituximab treatment consisted of 1 gram of RTX given twice, 2 weeks apart. Grey arrows denote the onset of headaches and other systemic symptoms.

Patient 3

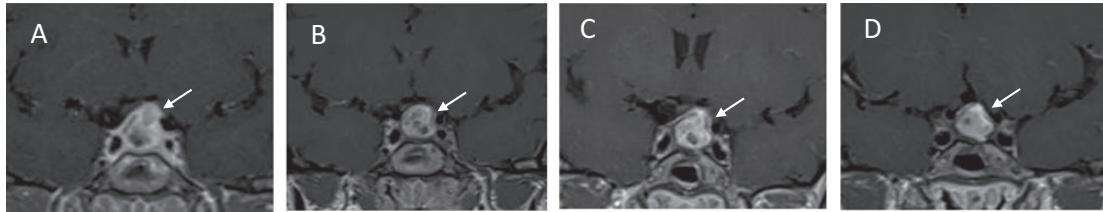


Figure 5. Coronal postcontrast T1W MR images of the pituitary. **A:** Image at presentation showing a sellar and suprasellar mass lesion involving the pituitary stalk and compressing the optic chiasm and involving the left optic nerve. **B:** Image following a short period of GC treatment and the first cycle of RTX. **C:** Image following the second cycle of RTX. **D:** Image following the third cycle of rituximab. Serial images demonstrate gradual reduction of the left-sided suprasellar component and some decompression of the left optic nerve (white arrows). There is been no significant overall reduction in the size of the pituitary mass lesion.

12 months apart. Despite symptomatic improvement, the pituitary appearances on imaging did not change significantly (Fig. 5).

Discussion

We present 3 cases, all young females with histologically confirmed IgG4-related hypophysitis without any evidence of other organ involvement. All 3 patients met the histological criteria for IgG4-related hypophysitis proposed by Leporati [7]. Bernreuther et al demonstrated that a significant proportion of previously labeled primary hypophysitis may be IgG4-related [8]. The final diagnosis of IgG4-RD is made histologically. Histological criteria vary according to the organ(s) involved and classic histological features, such as IgG4-positive plasma cell infiltration, storiform fibrosis, and obliterative phlebitis, are not always present [9, 13, 14]. Pituitary IgG4-RD constitutes a relatively recent addition to the disease spectrum [7] and pituitary biopsy is not always routinely considered in the clinical context of primary hypophysitis. Our cases highlight the importance of obtaining a histological diagnosis if IgG4-related hypophysitis is suspected, as the clinical course and treatment options differ from other forms of primary hypophysitis.

All 3 patients received high-dose GC treatment for remission induction followed by RTX treatment for remission maintenance. Two patients remain in full remission and no longer require GC maintenance therapy. Patient 1 managed to discontinue pituitary hormone replacement altogether and continues to have normal pituitary function. Patient 2 fully recovered anterior pituitary function, but she remains on desmopressin. In both cases, there was almost complete radiological resolution of the pituitary swelling. By contrast, Patient 3 experienced symptoms for almost 2 years before presenting to our services. Her hormonal and radiological response remains incomplete, more than 2 years after her first of 3 courses of RTX treatment. Although there were no obvious fibrotic changes on her histopathological specimen, it is plausible that the chronicity of her disease contributed to the lack of therapeutic response. Encouragingly, case reports show that RTX may be effective in nonpituitary chronic IgG4-RD, such as Riedel's thyroiditis refractory to GC treatment [15, 16] or retroperitoneal fibrosis [17], but our report underlines the importance of early intervention to avoid irreversible changes. Deleterious health consequences from long-term GC treatment are often underestimated, and GC treatment alone rarely achieves long-term remission in IgG4-RD. All of our patients gained significant weight while on high-dose GC therapy and Patient 3 became very emotionally labile during GC remission induction, necessitating rapid GC withdrawal. Rituximab treatment was generally well tolerated, although Patient 1 suffered an allergic reaction, which settled promptly with antihistamines and a single dose of hydrocortisone. The main reported adverse events associated with RTX treatment are

infusion reactions and an increased infection risk. None of our patients, however, experienced significant infections during follow-up. Long-term data from patients with rheumatoid arthritis receiving RTX showed that the infection risk does not increase with repeated and prolonged treatment and, importantly, no increased risk of malignancy was observed [18].

Rituximab appears to be highly effective in achieving remission maintenance in IgG4-RD, although the optimal intervals between doses and total duration of treatment required to achieve long-term remission are unclear. Repeated RTX is often only administered when there is a disease flare, but each flare could potentially lead to irreversible fibrotic changes, thus diminishing the chances of long-term remission. It may therefore be preferable to maintain B-cell depletion for a longer period of time to avoid disease flares and irreversible consequences. The total length of RTX treatment required for sustained remission needs to be determined in clinical trials. Our current approach is to aim for a 2-year period of B-cell depletion. There is no good marker (clinical, radiological, or biochemical) to determine whether IgG4-RD will remain in remission following cessation of RTX treatment. Serum IgG4 levels are usually not elevated in isolated pituitary disease and are therefore not useful for monitoring of disease activity. Primary hypophysitis often affects young females in childbearing age. Most GC-sparing treatments should be avoided in pregnancy, and it would therefore be important to determine a treatment regimen that achieves long-term disease control without the need of ongoing maintenance drug therapy in this patient group.

In selected cases, there might be a role for pituitary surgery if sustained remission cannot be achieved otherwise, but recurrence rates following surgery remain unknown. In addition, women planning pregnancy or women whose disease presents during pregnancy might also benefit from surgery, as there is an increased risk of chiasmal compromise in pregnancy and other (nonsurgical) treatment options, such as RTX, would be contraindicated.

Conclusion

This is the first report of a series of 3 patients with biopsy-proven isolated IgG4-related hypophysitis receiving more than 1 course of RTX for remission maintenance. This case series highlights the importance of a confirmatory histological diagnosis at the outset, as it will have significant impact on long-term management. Rituximab appears to be a promising treatment option in IgG4-related hypophysitis to achieve remission maintenance without the need for long-term GCs. It remains uncertain whether subsequent RTX administration is best guided by symptoms, imaging, or B-cell counts to achieve sustained remission. Reliable clinical data collection as well as tissue banking will be useful to establish effective treatment protocols for this rare condition.

Acknowledgments

We would like to thank Dr. Tom Cairns and Professor Frederick Tam for their advice and support. This work was supported by the National Institute for Health Research (NIHR) Biomedical Research Centre (BRC) based at the Imperial College Healthcare NHS Trust.

Additional Information

Correspondence: Florian Wernig, MD, FRCP, Department of Endocrinology, Hammersmith Hospital, Imperial College Healthcare NHS Trust, London W12 0HS, UK. E-mail: f.wernig@imperial.ac.uk.

Disclosure Summary: The authors have nothing to disclose.

Data Availability: All data generated or analyzed during this study are included in this published article or in the data repositories listed in References.

References and Notes

1. Stone JH, Zen Y, Deshpande V. IgG4-related disease. *N Engl J Med*. 2012;**366**(6):539–551.
2. Kamisawa T, Zen Y, Pillai S, Stone JH. IgG4-related disease. *Lancet*. 2015;**385**(9976):1460–1471.

3. Poo SX, Tham CSW, Smith C, et al. IgG4-related disease in a multi-ethnic community: clinical characteristics and association with malignancy. *Qjm*. 2019;**112**(10):763–769.
4. Carruthers MN, Stone JH, Khosroshahi A. The latest on IgG4-RD: a rapidly emerging disease. *Curr Opin Rheumatol*. 2012;**24**(1):60–69.
5. Smith C, Hameed S, Rose GE, Wernig F. A 61 year old man with pancreatitis, pituitary dysfunction, and painful exophthalmos. *Bmj*. 2019;**364**:193.
6. Bando H, Iguchi G, Fukuoka H, et al. The prevalence of IgG4-related hypophysitis in 170 consecutive patients with hypopituitarism and/or central diabetes insipidus and review of the literature. *Eur J Endocrinol*. 2014;**170**(2):161–172.
7. Leporati P, Landek-Salgado MA, Lupi I, Chiovato L, Caturegli P. IgG4-related hypophysitis: a new addition to the hypophysitis spectrum. *J Clin Endocrinol Metab*. 2011;**96**(7):1971–1980.
8. Bernreuther C, Illies C, Flitsch J, et al. IgG4-related hypophysitis is highly prevalent among cases of histologically confirmed hypophysitis. *Brain Pathol*. 2017;**27**(6):839–845.
9. Deshpande V, Zen Y, Chan JK, et al. Consensus statement on the pathology of IgG4-related disease. *Mod Pathol*. 2012;**25**(9):1181–1192.
10. Hart PA, Topazian MD, Witzig TE, et al. Treatment of relapsing autoimmune pancreatitis with immunomodulators and rituximab: the Mayo Clinic experience. *Gut*. 2013;**62**(11):1607–1615.
11. Carruthers MN, Topazian MD, Khosroshahi A, et al. Rituximab for IgG4-related disease: a prospective, open-label trial. *Ann Rheum Dis*. 2015;**74**(6):1171–1177.
12. Bullock DR, Miller BS, Clark HB, Hobday PM. Rituximab treatment for isolated IgG4-related hypophysitis in a teenage female. *Endocrinol Diabetes Metab Case Rep*. 2018;**2018**(1):1–6.
13. Arora K, Rivera M, Ting DT, Deshpande V. The histological diagnosis of IgG4-related disease on small biopsies: challenges and pitfalls. *Histopathology*. 2019;**74**(5):688–698.
14. Uccella S, Amaglio C, Brouland JP, et al. Disease heterogeneity in IgG4-related hypophysitis: report of two histopathologically proven cases and review of the literature. *Virchows Arch*. 2019;**475**(3):373–381.
15. Soh SB, Pham A, O’Hehir RE, Cherk M, Topliss DJ. Novel use of rituximab in a case of Riedel’s thyroiditis refractory to glucocorticoids and tamoxifen. *J Clin Endocrinol Metab*. 2013;**98**(9):3543–3549.
16. Dahlgren M, Khosroshahi A, Nielsen GP, Deshpande V, Stone JH. Riedel’s thyroiditis and multifocal fibrosclerosis are part of the IgG4-related systemic disease spectrum. *Arthritis Care Res (Hoboken)*. 2010;**62**(9):1312–1318.
17. Wallwork R, Wallace Z, Perugino C, Sharma A, Stone JH. Rituximab for idiopathic and IgG4-related retroperitoneal fibrosis. *Medicine (Baltimore)*. 2018;**97**(42):e12631.
18. van Vollenhoven RF, Fleischmann RM, Furst DE, Lacey S, Lehane PB. Longterm safety of rituximab: final report of the rheumatoid arthritis global clinical trial program over 11 years. *J Rheumatol*. 2015;**42**(10):1761–1766.