



Uterine lipoma: A case report

Noni Chan ^{*}, Mathumathi Vythianathan

Department of Anatomical Pathology, NSW Health Pathology, Orange Base Hospital, Orange, NSW, Australia

ARTICLE INFO

Article history:

Received 30 June 2020

Received in revised form 20 July 2020

Accepted 10 August 2020

Available online xxx

Keywords:

Lipomatous tumour
Lipoma
Uterine neoplasms
Pathology
Case report

ABSTRACT

Uterine lipomas are a rare benign gynaecological tumour of uncertain histogenesis. Clinically, a uterine lipoma may be mistaken for leiomyoma or a malignant tumour. Radiological findings may be suggestive but can also often be inconclusive. However, it has a distinctive appearance on histopathological examination. We present a case of uterine lipoma in a 70-year-old woman, to increase awareness of this unusual entity.

© 2020 The Authors. Published by Elsevier B.V. This is an open access article under the CC BY-NC-ND license (<http://creativecommons.org/licenses/by-nc-nd/4.0/>).

1. Introduction

Lipomatous tumours of the uterus are rare. Pure uterine lipomas are exceptionally so, with only a handful cases reported in the literature. The histogenesis of these lipomatous neoplasms is unclear, with multiple theories proposed. We report a case of uterine lipoma in a 70-year-old woman which was diagnosed postoperatively on histopathological examination.

2. Case Presentation

A 70-year-old woman presented to her general practitioner with recurrent urinary tract infections and was incidentally found to have a large painless abdominal mass upon examination. She had no systemic symptoms. Her obstetric and gynaecological history consisted of 2 uncomplicated vaginal births and prolapse. There was no history of hormone replacement therapy. Her other medical history included hypertension and hypercholesterolemia. Computed tomography (CT) showed a 160 × 123 × 144 mm fatty mass, with a favoured differential diagnosis of uterine lipoleiomyoma. A pelvic ultrasound was done as the mass was difficult to differentiate on CT from the right ovary. This showed a 124 × 123 × 111 mm mass, favouring dermoid arising from the right ovary. Due to the conflicting radiological findings, she underwent elective hysterectomy and bilateral salpingo-oophorectomy and the specimen was submitted for histopathological examination.

The uterus weighed 1666 g. The cut surface showed a round yellow mass of likely adipose tissue in the posterior wall, measuring 150 × 140 × 125 mm (Fig. 1). No areas of hemorrhage or necrosis were identified macroscopically within this lesion. Apart from a small paratubal cyst, the fallopian tubes and ovaries were unremarkable.

Microscopic examination revealed the lesion to be composed of benign mature adipocytes (Fig. 2). There were septa containing thick-walled blood vessels with occasional perivascular smooth muscle (Fig. 3). There was no evidence of malignancy or atypia in the adipocytes (Fig. 4). The endometrium showed atrophic changes. The cervix demonstrated benign Nabothian cysts. Ovarian cortical inclusion cysts and paratubal cysts were noted. Immunohistochemistry showed focal desmin and SMA positivity around the vessels (Fig. 5). MDM2, HMB-45 and Melan-A were negative with a very low Ki-67 proliferation index. This was diagnosed as a benign intramural uterine lipoma with focal smooth muscle around vessels.

The patient recovered well from her operations with no complications and remained well in the 3 years since her surgery.

3. Discussion

Lipomatous tumours of the uterus include pure lipomas, lipoleiomyomas, angiomyolipomas, fibromyolipomas, lipofibromas and liposarcomas [1]. The differential diagnosis of pelvic fat-containing tumours also includes ovarian teratomas, myelolipomas and pelvic lipomatosis.

The incidence of lipomatous tumours is reported as 0.03–0.25%; of these, only a handful of pure uterine lipomas have been reported in the literature [2]. These benign tumours occur more commonly in post-menopausal women and are typically located in the fundus [3].

^{*} Corresponding author.

E-mail address: Noni.Chan@health.nsw.gov.au (N. Chan).



Fig. 1. Macroscopic appearance of uterine lipoma.

The exact histogenesis of these tumours is unclear, particularly as adipose tissue is not a normal constituent of the uterus [1]. Multiple hypotheses have been proposed, including lipoblastic differentiation of misplaced embryonic mesoderm, metaplasia of smooth muscle or connective tissue into adipose cells, fatty infiltration or degeneration of connective tissue, perivascular fat cells proliferation and migration of adipose cells through uterine vessels [2].

There is no defined set of criteria distinguishing lipoma from a mixed lipomatous tumour [3]. However, the literature suggests that lipomas are diagnosed when lesions are predominantly composed of encapsulated mature adipose tissue [4]. Lesions containing thin fibrovascular septa are widely accepted [2]. Smooth muscle is generally present only at the periphery of the tumour though some patients, similar to ours, also have very focal smooth muscle around vessels in these fibrous septa [5]. Thorough sampling of the specimen is required to exclude the

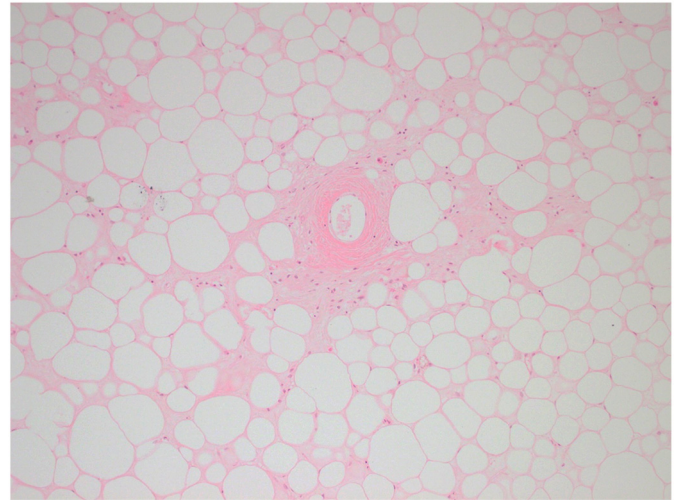


Fig. 3. H&E stain 100× magnification showing focal smooth muscle around blood vessel in a background of mature adipocytes.

presence of atypical adipocytes, significant smooth muscle or connective tissue intermingled with adipocytes which are present in other lipomatous tumours [2,5].

Immunohistochemistry may be helpful in differentiating lipomas from other entities containing adipose tissue. SMA and desmin can be used to highlight the presence of smooth muscle and whether this extends beyond vessel walls, which would lead to an alternative diagnosis of lipoleiomyoma. HMB-45 and Melan-A are positive in angiomyolipomas whilst MDM2 is positive in liposarcomas. Ki-67 is a marker of cell proliferation and, in our case, a low Ki-67 index is further evidence of the lesion's benign nature.

Patients with uterine lipomas are often asymptomatic. However, if they do have symptoms, these are non-specific and include vaginal bleeding, urinary frequency and abdominal distension [4]. As a result, these lesions are commonly clinically thought to be leiomyomas or, given the older cohort, a malignant tumour [6]. Radiological findings may be non-specific and diagnosis is often made only with histopathological examination. However, some case reports have described radiological findings that may aid in pre-operative diagnosis and thus obviate the need for surgery [7]. Indeed, the CT imaging for our patient favoured a lipomatous

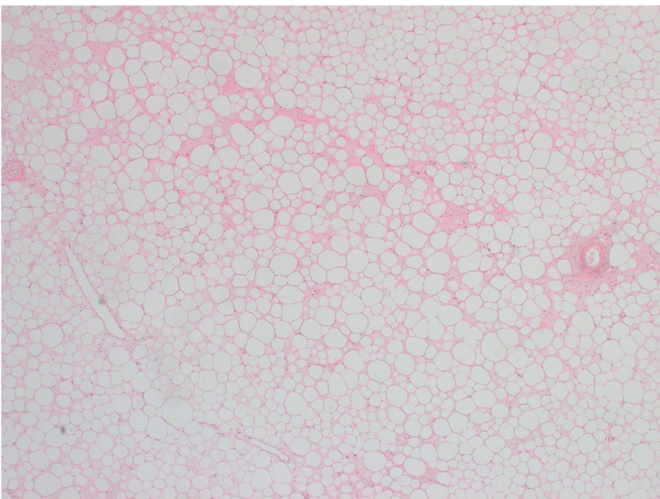


Fig. 2. H&E stain 20× magnification showing mature adipocytes with occasional fibrous septa containing blood vessels.

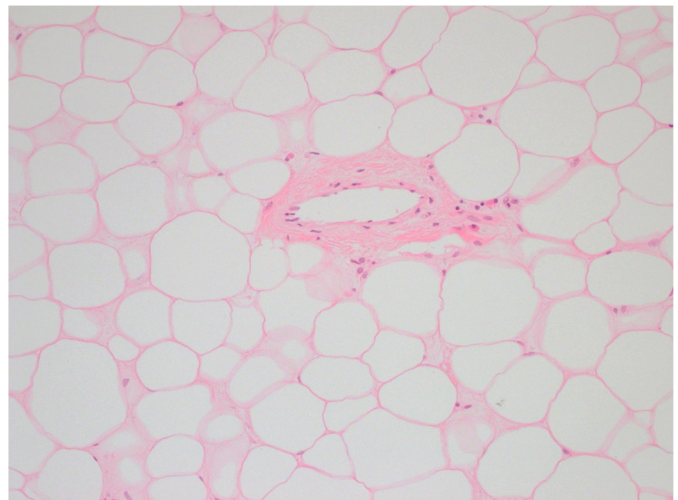


Fig. 4. H&E stain 200× magnification showing adipocytes with no cytologic atypia.

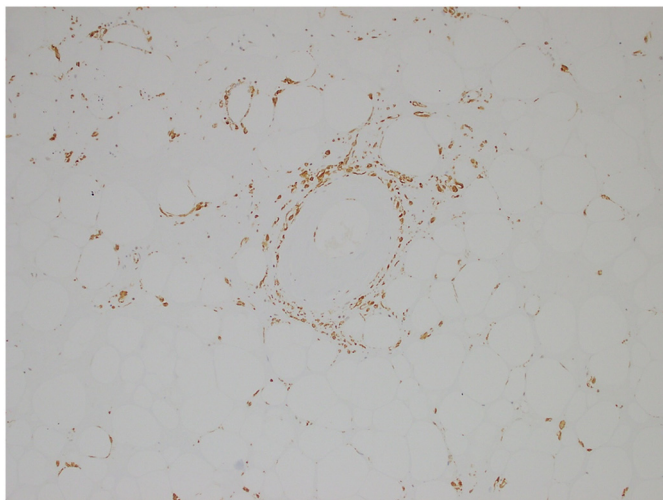


Fig. 5. SMA stain of same area in Fig. 3 at 100× magnification showing focal positivity around blood vessel.

tumour, although ultrasonography did not. Wijesuriya [7] reports the following imaging findings to be suggestive of lipomatous tumour: avascularity and hyperechoic imaging on ultrasound; fat attenuation and non-enhancement on CT; and hyperintensity on T1 and T2 with signal dropout on fat suppression sequences on MRI. However, both Chandawale and Garg reported in their cases that CT findings favoured leiomyomas with degenerative change [2,4].

On the other hand, Lau [8] and Fujimoto [9] each report a case of uterine lipoma diagnosed pre-operatively on MRI and confirmed on histopathological examination. Lau [8] advocates that MRI is the superior imaging modality for these lesions due to its multiplanar capability, tissue-specific characteristics and ability to distinguish between adnexal tissues, uterus and pelvic fat. However, the consensus from the literature supports confirmatory histopathological diagnosis to exclude other uterine neoplasms, particularly malignancies [2,10].

4. Conclusion

Uterine lipomas are a rare benign tumour, more common in post-menopausal women. There may be a role for radiology in pre-operative diagnosis. However, most cases are diagnosed on histopathological examination. These lesions must be thoroughly sampled to exclude other lipomatous tumours of the uterus.

Contributors

Noni Chan drafted the article and contributed to editing and revision.

Mathumathi Vythianathan contributed to editing and revision of the article.

Both authors approved submission of the manuscript.

Conflict of interest

The authors declare that they have no conflict of interest regarding the publication of this case report.

Funding

No funding from an external source supported the publication of this case report.

Patient Consent

Obtained.

Provenance and Peer Review

This case report was peer reviewed.

References

- [1] D.J. Pounder, Fatty tumours of the uterus, *J. Clin. Pathol.* 35 (12) (1982) 1380–1383, <https://doi.org/10.1136/jcp.35.12.1380>.
- [2] A. Garg, S. Sudhamani, V.M. Kiri, A.A. Pandit, Pure lipoma of uterus: a case report with review of literature, *J. Sci. Soc.* 40 (2) (2013) 114.
- [3] A. Bandopadhyay, S. Ray, P. Bera, M. Gangopadhyay, I. Chakrabarti, B. Dey, Calcified pure uterine lipoma mimicking myoma, *J. Turk. Ger. Gynecol. Assoc.* 11 (2) (2010) 113–114, <https://doi.org/10.5152/jtgga.2010.013>.
- [4] S.S. Chandawale, K.M. Karia, N.S. Agrawal, A.A. Patil, A.B. Shetty, M. Kaur, Uterine lipoleiomyoma and lipoma: a rare unique case report with review of literature, *Int. J. Appl. Basic Med. Res.* 8 (3) (2018) 193, https://doi.org/10.4103/ijabmr.IJABMR_119_17.
- [5] R. Vilallonga, A. García, J. Castellví, J.M. Fort, M. Armengol, Ramón y Cajal S. Lipoma of the uterine corpus: exceptional eventuality combined with an ovarian thecoma, *Case Rep. Med.* 2009 (2009), 340603, <https://doi.org/10.1155/2009/340603>.
- [6] M.M. KV, D. Radhika, C.N. Mohan, S. Rajkumari, J.N. Raju, Pure uterine lipoma, *J. Case Rep.* 5 (1) (2015) 16–18, <https://doi.org/10.17659/01.2015.0005>.
- [7] S.M. Wijesuriya, S. Gandhi, A pure uterine lipoma: a rare, benign entity, *BMJ Case Rep.* 2011 (2011) <https://doi.org/10.1136/bcr.07.2011.4425>.
- [8] L.U. Lau, R.F. Thoeni, Uterine lipoma: advantage of MRI over ultrasound, *Br. J. Radiol.* 78 (925) (2005) 72–74, <https://doi.org/10.1259/bjr/61054799>.
- [9] Y. Fujimoto, K. Kasai, M. Furuya, et al., Pure uterine lipoma, *J. Obstet. Gynaecol. Res.* 32 (5) (2006) 520–523, <https://doi.org/10.1111/j.1447-0756.2006.00439.x>.
- [10] G. Calongos, Y. Ito, Y. Kubota, M. Handa, A. Ida, Y. Tsuji, A large pure uterine lipoma: its diagnosis by pelvic MRI and histopathology, *Case Rep. Obstet. Gynecol.* 2019 (2019) <https://doi.org/10.1155/2019/3929647>.