

# Investigation of the Lower Punctum Parameters: A Spectral Domain Anterior Segment Optical Coherence Tomography Study

Aliakbar Sabermoghaddam<sup>1</sup>, Shahin Golestani<sup>1</sup>, Kiiana Hassanpour<sup>2</sup>, Elham Bakhtiari<sup>3</sup>

<sup>1</sup>Khatam-Al-Anbia Hospital, Khatam Al Anbia Hospital, Mashhad University of Medical Sciences, Mashhad, Iran, <sup>2</sup>Imam Hossein Hospital, Shahid Beheshti University of Medical Sciences, Tehran, Iran, <sup>3</sup>Department of Pharmacology, Mashhad University of Medical Sciences, Mashhad, Iran

## Abstract

**Purpose:** To evaluate the dimensions of lower punctum in a sample of Iranian normal population using spectral domain anterior segment optical coherence tomography (OCT).

**Methods:** In this cross-sectional study, 102 eyes of 102 healthy volunteers were enrolled. All participants underwent a detailed history and complete ophthalmic examination. Lower punctum metrics were measured using OCT (Spectralis, Heidelberg) with the anterior segment module. External punctal diameter was defined as the largest diameter at the surface of the punctum. Internal punctal diameter was measured at two different depths of 100  $\mu\text{m}$  and 500  $\mu\text{m}$  from the external surface. Measurements were repeated for 30% of data by another grader. The agreement was measured using intraclass correlation coefficient (ICC).

**Results:** The mean age of the participants was  $61.5 \pm 7.9$  years. The mean external punctal diameter was  $425.6 \pm 124.3 \mu\text{m}$ . The mean internal punctal diameter at 100  $\mu\text{m}$  and 500  $\mu\text{m}$  was  $183 \pm 97.5 \mu\text{m}$  and  $77.7 \pm 51.4 \mu\text{m}$ , respectively. The agreement between the graders was high in assessing all punctal characteristics (ICC >0.9 for all measurements).

**Conclusion:** The spectral domain OCT can be used for measuring lower punctum diameter with acceptable reproducibility.

**Keywords:** Optical coherence tomography, Punctum, Epiphora

**Address for correspondence:** Shahin Golestani, Eye Research Center, Khatam-Al-Anbia Hospital, Mashhad University of Medical Sciences, Mashhad, Iran.

E-mail: shahingolestani@yahoo.com

**Submitted:** 07-Apr-2020; **Revised:** 31-Jan-2021; **Accepted:** 19-Apr-2021; **Published:** 05-Jul-2021

## INTRODUCTION

The punctum is the only visible part of the tear drainage system. The upper and lower eyelid punctum are located at the apex of the lacrimal papillae on the upper and lower eyelid margins.<sup>1</sup> Understanding the normal anatomy of the punctum is essential to treat a variety of diseases such as stenosis or improper dilatation of the punctum, which could lead to disruption of the tear flow.<sup>2</sup> Furthermore, understanding the normal punctum anatomy could be helpful for more accurate design of punctal plugs.

Most of our knowledge about the normal anatomy of lacrimal drainage system has come from cadaver studies. However, numerous methods such as ultrasonography have been used for accurate measuring of the anatomical dimensions in *in vivo* condition.<sup>3,4</sup> Recently, optical coherence tomography (OCT) has been introduced to assess the punctum and proximal part of canaliculus. Wawrzynski *et al.*<sup>5</sup> showed that OCT could provide high-resolution images of the punctum and vertical canaliculus. However, normal values of these OCT measures have yet to be determined in different populations. The aim

This is an open access journal, and articles are distributed under the terms of the Creative Commons Attribution-NonCommercial-ShareAlike 4.0 License, which allows others to remix, tweak, and build upon the work non-commercially, as long as appropriate credit is given and the new creations are licensed under the identical terms.

**For reprints contact:** WKHLRPMedknow\_reprints@wolterskluwer.com

**How to cite this article:** Sabermoghaddam A, Golestani S, Hassanpour K, Bakhtiari E. Investigation of the lower punctum parameters: A spectral domain anterior segment optical coherence tomography study. *J Curr Ophthalmol* 2021;33:124-7.

### Access this article online

Quick Response Code:



**Website:**  
www.jcurrophthalmol.org

**DOI:**  
10.4103/JOCO.JOCO\_131\_20

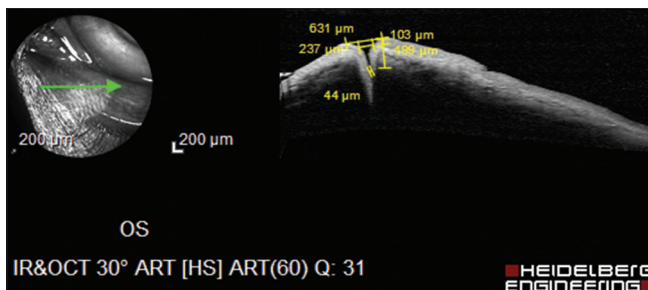
of this study was to evaluate the lower punctum features in Iranian normal population using OCT.

## METHODS

In this cross-sectional study, healthy volunteers aged between 20 and 70 years were recruited. Most of them were companies of the outpatients referred to Khatam-Al-Anbia Eye Hospital, Mashhad, Iran. The study protocol was approved by the Ethics Committee of Mashhad University of Medical Sciences (Ethics code of IR.MUMS.fm.REC.1396.764). Written informed consent was obtained from all participants. The study protocol adhered to the Declaration of Helsinki.

All participants underwent a detailed history and complete ophthalmic examination. Lid margins were thoroughly examined. Slit-lamp biomicroscopy and evaluation of the ocular surface were performed as well. The subjects with epiphora, long-term use of ocular drops except for artificial tears, previous history of chemotherapy, lower eyelid anomalies, lesions or history of the lid and lacrimal drainage disease, or surgery were excluded. Patients with tear meniscus height >2 mm or tear break-up time test <5 s were also excluded. In each patient, only one eye was enrolled in the study.

All OCT images were obtained by one experienced operator on a separate day without any further manipulation for ophthalmic examination. Lower punctum metrics measurements were performed using OCT (Spectralis, Heidelberg Engineering, Heidelberg, Germany) set on the anterior segment module [Figure 1]. This system acquires 40,000 A-scans/second with a 7- $\mu$ m axial resolution in tissue. All images were acquired using the scleral setting, a mode in which enhanced depth imaging can be performed. While the eyes were open and the lower eyelid margin was everted using a cotton swap without any pressure, the lower punctum was positioned to a plane perpendicular to the light source. The brightness was set to be 25%, and the angle of each cross-sectional scan was 15°. Images were obtained at a working distance of about 12 mm with 8 mm coverage of the lower eyelids. Automated real-time setting with an average between 2 and 20 frames was chosen. Three OCT images were obtained for each subject, and the highest quality scan was chosen subjectively.



**Figure 1:** Representative image of anterior segment optical coherence tomography of the inferior punctum

Measurements of lacrimal punctal anatomy, as visualized on OCT, were taken using Heidelberg Eye Explorer software (version 1.6.8) (Heidelberg Engineering, Heidelberg, Germany). The best and clearest one was chosen for measuring the lower punctum diameters. A skilled grader (A.S.) measured the dimensions. External punctal diameter was defined as the largest diameter at the surface of the punctum. Internal punctal diameter was measured at two different canalicular depths of 100 and 500  $\mu$ m from the external punctum [Figure 1]. To evaluate the reproducibility, 30% of measurements were repeated by another experienced researcher (S.G.).

Statistical analysis was performed using SPSS windows program version 16 (SPSS Institute, Inc., Chicago, IL, USA). All experimental values are presented as mean  $\pm$  standard deviation and median and interquartile range (IQR). Normal distribution was evaluated using Kolmogorov–Smirnov test.  $P < 0.05$  was considered statistically significant. The comparison between men and women was done by independent  $t$ -test. Pearson's correlation coefficient was used to evaluate the linear relationship between variables. The agreement between observers was measured using intraclass correlation coefficient (ICC) with single measures, absolute agreement method.

## RESULTS

One hundred and two eyes of 102 healthy volunteers were enrolled in the present study. The mean age of the participants was  $61.5 \pm 7.9$  years (29–69 years), and 53 (52%) of them were male.

The mean external punctal diameter was  $425.6 \pm 124.3$   $\mu$ m (median, IQR: 403, 336.2–503.2  $\mu$ m). Mean internal punctal diameter at 100  $\mu$ m and 500  $\mu$ m was  $191.6 \pm 101.7$   $\mu$ m (median, IQR: 155, 107.2–262) and  $79.6 \pm 61.4$   $\mu$ m (median, IQR: 61, 44–98.5), respectively. All values showed normal distributions in the study participants. There was a significant correlation between external punctal diameter and internal punctal diameter at 100  $\mu$ m ( $r = 0.821$ ;  $P < 0.0001$ ) and 500  $\mu$ m ( $r = 0.770$ ;  $P = 0.006$ ). There was no significant difference between men and women in all punctal measurements [Table 1]. There was no significant correlation between age and punctal measurements ( $P > 0.05$ ).

There was a good agreement between graders in measuring punctal diameters. ICC was 0.928 for external punctal diameter, 0.950 for internal punctal diameter at 100  $\mu$ m, and 0.901 for internal punctal diameter at 500  $\mu$ m.

## DISCUSSION

In the present study, we used OCT to measure lower punctum dimensions in Iranian healthy subjects. The punctum could be recognized and measured on the OCT images in all subjects. There was a good agreement between observers in assessing the punctal dimensions.

**Table 1: Punctal characteristics in the study population**

Variables	Total (n=102)	Male (n=53)	Female (n=49)	P*
External punctal diameter				
Mean±SD	425.6±124.3	434.5±134.5	416±112.9	0.455
Median	403	408	399	
IQR	336.2-503.2	340-563	319-492	
Internal punctal diameter at 100 µm				
Mean±SD	183±97.5	191.6±101.7	173.8±92.8	0.360
Median	155	162	140	
IQR	107.2-262	119-275	99-234	
Internal punctal diameter at 500 µm				
Mean±SD	77.7±51.4	79.6±61.4	75.7±38.4	0.709
Median	61	52	69	
IQR	44-98.5	43-104	44-96	

\*Based on student's *t*-test. SD: Standard deviation, IQR: Interquartile range

Understanding the anatomy of the punctum and the vertical portion of the lacrimal canal plays an important role in the success of lacrimal system surgeries and can also help determine the etiology of epiphora, especially in patients with punctal stenosis and obstruction.<sup>6</sup> Furthermore, the design, fitting, and insertion of the punctal plug are dependent on knowing the exact anatomy of this part.<sup>7,8</sup> The use of lacrimal system imaging techniques can be helpful in the diagnosis of lacrimal canal disease. Because of the surface and prominent status of the lacrimal canal, imaging techniques commonly used for the evaluation of the lacrimal drainage system such as dacryocystography,<sup>9</sup> ultrasound biomicroscopy,<sup>3,4</sup> and magnetic resonance imaging may not accurately represent the size of the punctum.<sup>10</sup>

Anterior segment OCT is a noncontact imaging modality that uses infrared light at a wavelength of 840 nm to image the anterior segment structures of the eye.<sup>11</sup> Wawrzynski *et al.*<sup>5</sup> were the first to demonstrate its applicability for evaluation of the lower punctum diameter and vertical canaliculus. They evaluated 36 eyes and provide the OCT measurements of the width of the punctum, and the width, depth, and cross-sectional area of the visualized canaliculi using Topcon 3D OCT. Afterward, some other studies applied OCT in assessing the punctal features and provided the values for the variables, including inner punctal diameter at different depth, punctal depth, and intrapunctal tear meniscus depth.<sup>12-14</sup>

In our study, the mean outer punctal diameter was 425.6 µm which is in the range of the reported values (215–645 µm) in previous studies. The inner punctal diameter in our study was 183 µm at 100 µm and 77.7 µm at 500 µm from the surface. The reported inner punctal diameter values (50–234 µm) showed even more variability in different investigations. However, this is mainly due to different definition of this dimension. Similar to Timlin *et al.*,<sup>12</sup> we measured the inner punctal diameter at a fixed distance from surface which could facilitate to provide better comparison between studies.

OCT-based evaluation of lacrimal drainage system, however, has some limitations. First, the assessment of the upper punctum is challenging. The upper punctum is slightly rotated

posteriorly, and it is difficult to rotate the opening.<sup>12</sup> This could be remedied by designing newer devices that would direct the infrared at the right angle to the upper punctum. Second, the exact effect of everting the lower eyelid margin on punctum size is not clear. Third, the dimensions are currently measured manually, since no automatic software is available for punctal diameters. On the other hand, the ability to capture images quickly without the need for eye contact and the ability to three-dimensional reconstruct and visualize the surface of a puncture are undeniable benefits of OCT.

In conclusion, OCT is a useful technique for imaging the inferior punctum. Values measured by OCT have acceptable reproducibility and can be evaluated for this purpose.

#### **Financial support and sponsorship**

Nil.

#### **Conflicts of interest**

There are no conflicts of interest.

## **RÉFÉRENCES**

- Cowen D. Stenotic puncta: Microsurgical punctoplasty. *Ophthalmic Plast Reconstr Surg* 1993;9:201-5.
- Soiberman U, Kakizaki H, Selva D, Leibovitch I. Punctal stenosis: Definition, diagnosis, and treatment. *Clin Ophthalmol* 2012;6:1011-8.
- Hurwitz JJ, Pavlin CJ, Hassan A. Proximal canalicular imaging utilizing ultrasound biomicroscopy A: Normal canaliculi. *Orbit* 1998;17:27-30.
- Al-Faky YH. Anatomical utility of ultrasound biomicroscopy in the lacrimal drainage system. *Br J Ophthalmol* 2011;95:1446-50.
- Wawrzynski JR, Smith J, Sharma A, Saleh GM. Optical coherence tomography imaging of the proximal lacrimal system. *Orbit* 2014;33:428-32.
- Kashkouli MB, Beigi B, Murthy R, Astbury N. Acquired external punctal stenosis: Etiology and associated findings. *Am J Ophthalmol* 2003;136:1079-84.
- DeMartelaere SL, Blyndon SM, Tovilla-Canales JL, Shore JW. A permanent and reversible procedure to block tear drainage for the treatment of dry eye. *Ophthalmic Plast Reconstr Surg* 2006;22:352-5.
- Tost FH, Darman J, Clemens S. 20-MHz ultrasound and its value in imaging of lacrimal plugs. *Ophthalmologica* 2004;218:14-9.
- Waite DW, Whittet HB, Shun-Shin GA. Technical note: Computed tomographic dacryocystography. *Br J Radiol* 1993;66:711-3.
- Dutton JJ, White JJ. Imaging and Clinical Evaluation of the Lacrimal.

- Drainage System. The Lacrimal System. New York: Springer; 2006
11. Ramos JL, Li Y, Huang D. Clinical and research applications of anterior segment optical coherence tomography. A review. *Clin Exp Ophthalmol* 2009;37:81-9.
  12. Timlin HM, Keane PA, Rose GE, Ezra DG. The application of infrared imaging and optical coherence tomography of the lacrimal punctum in patients undergoing punctoplasty for epiphora. *Ophthalmology* 2017;124:910-7.
  13. Kamal S, Ali MJ, Ali MH, Naik MN. Fourier domain optical coherence tomography with 3D and en face imaging of the punctum and vertical canaliculus: A step toward establishing a normative database. *Ophthalmic Plast Reconstr Surg* 2016;32:170-3.
  14. Singh S, Ghosh A, Rath S. Imaging of proximal lacrimal system with time domain anterior segment optical coherence tomography in Asian Indian population. *Orbit* 2017;36:251-5