

Use of N-acetylcysteine plus simethicone to improve mucosal visibility in upper digestive endoscopy via systematic alphanumeric-coded endoscopy: a randomized, double-blind controlled trial

Sergio Sobrino-Cossío^a, Fabian Emura^b, Oscar Teramoto-Matsubara^c, Raúl Araya^d, Adolfo Parra-Blanco^e, Jonathan Richard White^e, Vitor Arantes^f, Josué Aliaga Ramos^g, Elymir Soraya Galvis-García^h, Francisco de-la-Vega-Gonzálezⁱ, Gonzalo Rodríguez-Vanegas^j, Carlos Alberto Donneys^k, Arturo Reding-Bernal^l, Estrella Martínez-López^m, Juan Carlos López-Alvarengaⁿ, Noriya Uedo^o

Hospital Angeles del Pedregal, Gástrica, Centro Avanzado en Endoscopia y Estudios Funcionales, Mexico city, México; La Sabana University, Emura Foundation for the Promotion of Cancer Research, Bogota, D. C., Colombia; Gástrica, Centro Avanzado en Endoscopia y Estudios Funcionales, Mexico City, ABC Medical Center, Gastroenterology, Mexico City, México; Hospital Militar, Gastroenterology, Santiago de Chile, Chile; NIHR Nottingham Biomedical Research Centre, Nottingham University Hospitals NHS Trust and University of Nottingham, Nottingham, UK; Alfa Institute of Gastroenterology, School of Medicine, Federal University of Minas Gerais, Hospital Mater Dei Contorno, Belo Horizonte, Brazil; Hospital “José Agurto Tello-Chosica”, Digestive endoscopy unit “San Pablo” clinic, Service of Gastroenterology “Madre Zoraida” Clinic, Lima, Perú; Hospital General de México “Dr. Eduardo Liceaga”, Mexico City, Mexico; Gástrica, Centro Avanzado en Endoscopia y Estudios Funcionales, Mexico City, ABC Medical Center, Gastroenterology, Mexico City, México; Gástrica, Centro Avanzado en Endoscopia y Estudios Funcionales, Mexico City, ABC Medical Center, Gastroenterology, Mexico City, México; Electronic Engineer, Universidad Distrital de Bogotá, Bogotá, Colombia; Hospital General de México “Dr. Eduardo Liceaga”, Mexico City; Doctorado en Ciencias Medicas y de la Salud, UNAM, Mexico City, Mexico; School of Medicine, University of Texas Rio Grande Valley, USA; Universidad Mexico Americana del Norte, Reynosa, Tamaulipas, Mexico; Osaka International Cancer Institute, Osaka, Japan

Abstract

Background The use of antifoaming and mucolytic agents prior to upper gastrointestinal (GI) endoscopy and a thorough systematic review are essential to optimize lesion detection. This study evaluated the effect of simethicone and N-acetylcysteine on the adequate mucosal visibility (AMV) of the upper GI tract by an innovative systematic method.

Methods This randomized, double-blind controlled trial included consecutive patients who underwent diagnostic upper GI endoscopy for screening for early neoplasms between August 2019 and December 2019. The upper GI tract was systematically assessed by systematic alphanumeric-coded endoscopy. Patients were divided into 4 groups: 1) water; 2) only simethicone; 3) N-acetylcysteine + simethicone; and 4) only N-acetylcysteine. The following parameters were assessed in each group: age, sex, body mass index, level of adequate mucosal visibility, and side-effects.

Results A total of 4564 images from upper GI areas were obtained for evaluation. The mean AMV in the 4 groups was $93.98 \pm 7.36\%$. The N-acetylcysteine + simethicone group had a higher cleaning percentage compared with the other groups ($P=0.001$). There was no significant difference among the remaining groups, but several areas had better cleaning when a mucolytic or antifoam alone was used. No side-effects were found in any group.

Conclusion The combination of N-acetylcysteine plus simethicone optimizes the visibility of the mucosa of the upper GI tract, which could potentially increase diagnostic yield.

Keywords Adequate mucosal visibility, high quality endoscopy, N-acetylcysteine, systematic alphanumeric-coded endoscopy, upper digestive endoscopy

Ann Gastroenterol 2024; 37 (4): 410-417

Introduction

Gastroscopy is a safe and well-tolerated gold standard method for the detection of upper gastrointestinal (GI) pathology. In daily endoscopic practice, the identification of early GI cancer represents a great challenge, even in the hands of expert endoscopists [1-4]. High quality in upper GI endoscopy is a critical step in optimizing the diagnostic yield in the detection of pre-malignant and early malignant lesions. Traditional fasting periods of 6-8 h prior to the procedure are not always sufficient to guarantee clean and adequately visible mucosa. Clustered mucus, foam and bubbles in the

upper GI tract interfere with adequate visibility for complete endoscopic evaluation [5-13]. The adequate mucosal visibility (AMV) scale is a good tool to evaluate the pharmacological effect of defoamers and mucolytics on cleaning the upper GI mucosa. This has the potential to improve the early gastric cancer detection rate, although this has not been formally evaluated [14-24]. Improving mucosal visualization and subsequent cancer detection is vital, as up to 11.3% of gastric cancers were not detected during endoscopy 3 years before diagnosis [25-27]. Upper GI cancers detected at an early stage have a 5-year survival greater than 90% after endoscopic resection [28,29].

Systematic alphanumeric-coded endoscopy (SACE) has been successfully applied in Colombia since 2006 to help facilitate complete upper GI examination with high gastric cancer detection rates. It was subsequently adopted by other Latin American countries and China, after detecting approximately 1 positive case in 325 endoscopies in healthy volunteers with an average cancer risk. Consequently, the application of a thorough endoscopic evaluation system, such as SACE, and adequate cleaning prior to upper GI endoscopy comprise the optimal strategy to improve the detection of early lesions; however, data are lacking to support its routine use [17,18]. The aim of our study was to evaluate the effect of the ingestion of an antifoaming substance (simethicone) and/or mucolytic agent (N-acetylcysteine), prior to upper GI endoscopy, on the adequate visibility of the mucosa over 28 predetermined areas using SACE.

Patients and methods

Patients

This was a randomized, double-blind controlled clinical trial. Data were extracted from a prospectively maintained database, which included consecutive patients recruited during the period August 2019 to December 2019 who underwent screening gastroscopy for detection of early neoplasms. Written informed consent was obtained. Inclusion criteria were as follows: adult patients aged 18 and over scheduled for diagnostic gastroscopy. Exclusion criteria were as follows: history of upper GI surgery; upper GI cancers; active upper GI bleeding; esophageal or gastroduodenal stenosis; ingestion of caustics or non-steroidal anti-inflammatory drugs during the past 30 days; chronic cardiopulmonary, renal or decompensated liver disease; allergies to N-acetylcysteine or simethicone; and pregnancy or lactation.

Patients were divided into 4 treatment groups: Group 1 (G1), Control (water); Group 2 (G2), simethicone; Group 3 (G3), N-acetylcysteine + simethicone; and Group 4 (G4), N-acetylcysteine. The following parameters were assessed in each group: age, sex, body mass index (BMI), level of adequate mucosal visibility, rate of serious adverse events (laryngospasm, bronchoaspiration, variations in blood pressure, heart frequency and oxygen saturation), and rate of side-effects.

^aHospital Angeles del Pedregal, Gástrica, Centro Avanzado en Endoscopia y Estudios Funcionales, Mexico city, México (Sergio Sobrino-Cossío); ^bAdvanced Gastrointestinal Endoscopy, Emura Center LatinoAmerica, Division of Gastroenterology, La Sabana University, Emura Foundation for the Promotion of Cancer Research, Bogota, D. C., Colombia (Fabian Emura); ^cGástrica, Centro Avanzado en Endoscopia y Estudios Funcionales, Mexico City, ABC Medical Center, Gastroenterology, Mexico city, México (Oscar Teramoto-Matsubara); ^dHospital Militar, Gastroenterology, Santiago de Chile, Chile (Raúl Araya); ^eNIHR Nottingham Biomedical Research Centre, Department of Gastroenterology, Nottingham University Hospitals NHS Trust and University of Nottingham, Nottingham, UK (Adolfo Parra-Blanco); ^fEndoscopy Unit, Alfa Institute of Gastroenterology, School of Medicine, Federal University of Minas Gerais, Hospital Mater Dei Contorno, Belo Horizonte, Brazil (Vitor Arantes); ^gDepartment of Gastroenterology, Hospital "José Agurto Tello-Chosica", Digestive endoscopy unit "San Pablo" clinic, Service of Gastroenterology "Madre Zoraida" Clinic, Lima, Perú (Josué Aliaga Ramos); ^hGástrica, Centro Avanzado en Endoscopia y Estudios Funcionales, Mexico City, Hospital General de México "Dr. Eduardo Liceaga", Mexico City, Mexico (Elymir Soraya Galvis-García); ⁱGástrica, Centro Avanzado en Endoscopia y Estudios Funcionales, Mexico City, ABC Medical Center, Gastroenterology, Mexico City, México (Francisco de-la-Vega-González); ^jGástrica, Centro Avanzado en Endoscopia y Estudios Funcionales, Mexico City, ABC Medical Center, Gastroenterology, Mexico City, México (Gonzalo Rodríguez-Vanegas); ^kElectronic Engineer, Universidad Distrital de Bogotá, Bogotá, Colombia (Carlos Alberto Donneys); ^lHospital General de México "Dr. Eduardo Liceaga", Mexico City, Mexico (Arturo Reding-Bernal); ^mDoctorado en Ciencias Médicas y de la Salud, UNAM, Mexico City, Mexico (Estrella Martínez-López); ⁿDepartment of Population Health and Biostatistics, School of Medicine, University of Texas, Rio Grande Valley, USA. Universidad Mexico Americana del Norte, Reynosa, Tamaulipas, Mexico (Juan Carlos López-Alvarenga); ^oOsaka International Cancer Institute, Department of Gastrointestinal Oncology, Osaka, Japan (Noriya Uedo)

Conflict of Interest: None

Correspondence to: Juan Carlos López-Alvarenga, MD, DSc, Department of Population Health and Biostatistics, School of Medicine, University of Texas Rio Grande Valley, USA, e-mail: juan.lopezalvarenga@utrgv.edu

Received 21 December 2023; accepted 10 April 2024; published online 14 June 2024

DOI: <https://doi.org/10.20524/aog.2024.0895>

This is an open access journal, and articles are distributed under the terms of the Creative Commons Attribution-NonCommercial-ShareAlike 4.0 License, which allows others to remix, tweak, and build upon the work non-commercially, as long as appropriate credit is given and the new creations are licensed under the identical terms

Interventions

A random number list, generated by computer, was used to assign patients to one of the 4 intervention groups: G1) Water 100 mL; G2) simethicone 200 mg + 100 mL of water; G3) Simethicone 200 mg + N-acetylcysteine 600 mg + 100 mL of water; and G4) N-acetylcysteine 600 mg + 100 mL of water. Fig. 1 shows a flow chart of the distribution of all enrolled patients.

All patients received standard recommendation instructions, which included an 8-h fast, and ingestion of the study solution under supervision 20 min before the procedure. Both patients and endoscopists were blinded to the prepared solution.

Upper GI tract visibility assessment

All procedures were completed using gastroscopes (Magniview EG-2990Zi HD, Pentax Hoya, Tokyo, Japan) with an iPK7010 processor (OE-Iscon-Mode system). For the systematic evaluation of the upper GI tract, the SACE system was used, consisting of 28 areas [1]. Expert endoscopists (SS, OTM, EG and GR) trained on the SACE system, performed all the procedures. Prior to participating in the study an interobserver agreement evaluation was carried out with 80 archive photographs, to verify that there was sufficient interobserver agreement ($Kappa > 0.4$) before rating the photographs in the study.

The 28 SACE areas were divided into 7 regions of the upper GI tract (Table 1). Each region was given a score from 1-4 points using the AMV score. The total sum of the AMV score of the 7 regions ranged from 7 (best) to 28 points (worst). This modification has previously been validated [5,7,12]. The AMV scale was evaluated by 4 endoscopists, for each of the 28 different regions of the SACE system. A 4-point Likert scale

was used (AMV scale): 1) no adherent mucus in the mucosa; 2) small amount of mucus that does not hinder endoscopic vision; 3) large amount of mucus that can be removed by irrigating with 50 mL of water; and 4) large amount of mucus on the mucosa that cannot be removed by irrigation with 50 mL of water.

The endoscopists were blinded to the preparation used, and 28 endoscopic photographs were taken, 1 of each SACE area, which were subsequently evaluated according to the AMV scale. Kappa (k) statistics were used to determine interobserver agreement.

Statistical analysis

SPSS version V.27.0 and Stata version V.17 were used for the statistical analysis. The data were presented as means, standard deviations, frequencies and percentages. Differences between groups were assessed using with the chi-square, 1-way ANOVA and *post hoc* testing, with robust Games-Howell analysis accordingly to variable dimensions. A Scheffe contrast method was used to build homogeneous groups, with Fisher notation. As the residuals showed significant skewness to the right side, a robust analysis was performed, as an alternative to ordinary least squares. Violin plots were performed to show the dispersion and variance of cleanness by group. A factor analysis with varimax rotation of vectors was conducted to assess uncorrelated (orthogonal) values for evaluating gastrointestinal (GI) mucosa cleaning clusters, in addition to the seven anatomical regions outlined in Table 1. The adequacy of these factors was analyzed with the Kaiser Meyer Olkin (KMO) test and Bartlett's sphericity test. The scores obtained by the factors were analyzed with robust ANOVA and *post hoc* with Games-Howell. Heatmaps of the factors obtained with factor analysis were also obtained. The difference and 95% confidence intervals (adjusted for sex,

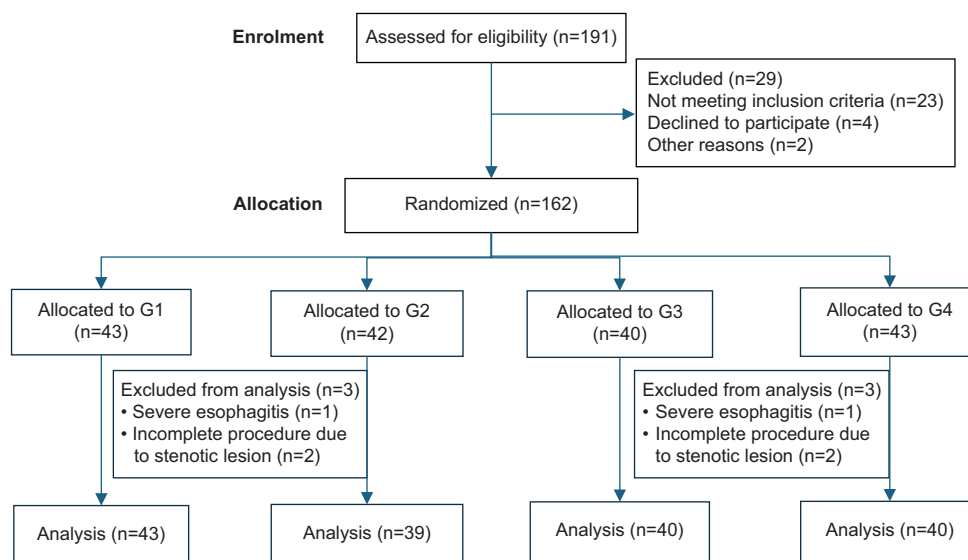


Figure 1 Flow chart showing the distribution of the enrolled patients

Table 1 Comparison among groups

Part	G1	G2	G3	G4	Total	P-value
Esophagus	1.29 (0.31)	1.16 (0.21)	1.06 (0.1)	1.14 (0.3)	1.16 (0.26)	0.001
Antrum	1.23 (0.31)	1.14 (0.27)	1.07 (0.12)	1.26 (0.39)	1.17 (0.3)	0.011
Lower third of the stomach	1.37 (0.41)	1.24 (0.32)	1.07 (0.2)	1.19 (0.4)	1.22 (0.36)	0.001
Middle third of the stomach	1.4 (0.38)	1.31 (0.35)	1.16 (0.27)	1.23 (0.39)	1.28 (0.36)	0.021
Upper third of the stomach	1.24 (0.34)	1.17 (0.27)	1.13 (0.25)	1.19 (0.36)	1.18 (0.31)	0.419
Lesser curvature of the stomach	1.2 (0.29)	1.11 (0.22)	1.04 (0.11)	1.16 (0.43)	1.13 (0.29)	0.066
Duodenum	1.15 (0.3)	1.04 (0.13)	1 (0)	1.09 (0.27)	1.07 (0.22)	0.011

G1: Water 100 mL, G2: Only simethicone 200 mg + 100 mL of water, G3: Simethicone 200 mg+N-acetylcysteine 600 mg + 100 mL of water, G4: Only N-acetylcysteine 600 mg + 100 mL of water

diabetes mellitus and hypertension) between each group compared to the great mean were calculated (zero centered). Sample size calculation was determined using previous studies, considering a difference between 2 proportions ($\delta=30\%$) with different interventions in the AMV, 70% the combination of N-acetylcysteine 600 mg + simethicone + 100 mL of water vs. 40% of simethicone 200 mg alone and without intervention, and with an error α of 0.05 and a power of 0.8. Based on these calculations a sample size of 40 patients for each group was required, a total of 160 patients. Accounting for patient exclusions or loss of 20%, the recommended sample size was 191 patients.

Ethical statements

The study was conducted in accordance with the Declaration of Helsinki. This study was approved by the Ethics and Research Committees of the General Hospital of Mexico with registry number DI/20/310T/03/65.

Results

A total of 191 patients were enrolled. Twenty-nine patients were excluded (23 did not meet the inclusion criteria, 4 declined to participate, and 2 for other reasons). Thus, 162 patients were included in the final analysis, of whom 74 were female (45.6%) and 88 were male (54.3%). The mean age was 50.4 ± 17.1 years. The mean BMI was 25.3 ± 4.4 kg/m². Sex differences were observed for groups G2 and G3, but the regression analysis did not demonstrate significant effects. A total of 4564 images from the examined areas in the upper GI tract were obtained for evaluation. No statistically significant differences were found in relation to age ($P=0.48$), BMI ($P=0.82$), diabetes mellitus, or hypertension. Two patients were taking medication that delayed gastric emptying. Table 1 shows the average value of the degree of cleanliness in the 7 different regions studied.

The factor analysis considered the 28 areas; this analysis was suitable (KMO=0.79, sphericity test $P<0.001$) (Table 1). The anti-image matrices were greater than 0.5, except that of the E3 region (0.457). These 3 techniques (KMO, Bartlett's sphericity

test, and anti-imaging matrix) determined the appropriateness of the factor analysis. The maximum variance explained by 8 factors was 66%, the highest value was 7.7 and the lowest 1.17. The reproduced correlations were greater than 0.5, except for the A9 region (0.46), which was considered acceptable. Fig. 2 shows the graphic variation of the degree of cleaning in the different 28 SACE areas in each study group.

The total sum of the score was significantly greater in the control group, as can be derived from the higher distances at the ends of the distributions. The mean of the N-acetylcysteine + simethicone group was lower in comparison to the rest of the interventions, which reflects less dispersion in the scores. An ANOVA test was applied to determine the statistical significance between the treatment groups in the sum of the scores, finding a value of 0.0001 between the control group and the combination group. Fig. 3 shows the comparison of the degree of cleaning among groups.

The contrast between groups using the distance grand mean and robust standard error calculation showed G3 (N-Acet + Simet) presented greater efficiency compared to G1 (control) ($P=0.001$). The other groups did not show significant differences. It was also evident that certain areas showed improved mucosal visibility from the use of a mucolytic, while others were improved by use of an antifoam. The average AMV in the 4 groups was 93.98% and the standard deviation was 7.36. No severe adverse events or side-effects occurred in either group in this study. Fig. 4 and 5 show representative images of adequate and inadequate cleansing of the upper GI tract, respectively.

Discussion

This study adds further scientific evidence for the optimal efficacy and safety profile of the use of defoamers and mucolytics in the improvement of upper GI mucosal visibility in a Latin American population. The main strength of this study is the reporting of the largest cohort in Latin America, demonstrating the benefits of adequate cleansing in the upper GI tract. The clinical outcomes were similar to those reported in Japanese centers with vast experience.

Multiple studies based in Asia have shown that premedication with defoamers and mucolytics prior to upper GI endoscopy

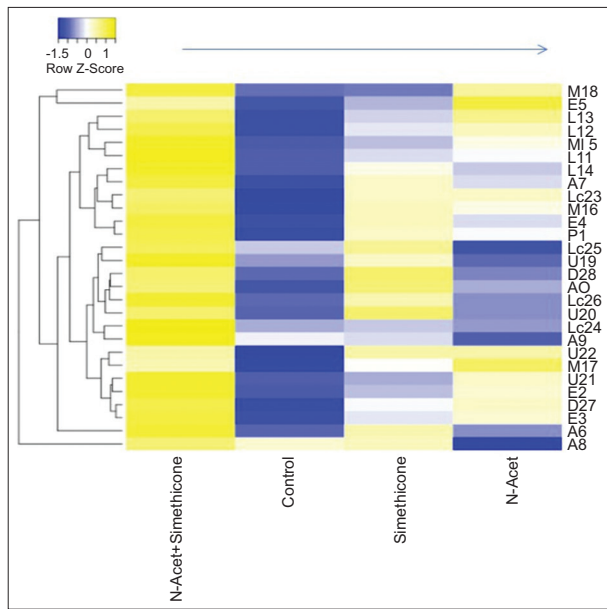


Figure 2 Heatmap showing a comparison of the degree of cleaning in the 28 regions by treatment group
 Yellow: regions with a higher degree of cleanliness; Blue: regions with a lower degree of cleanliness; Columns: study groups, Rows: systematic alphanumeric-coded endoscopy areas

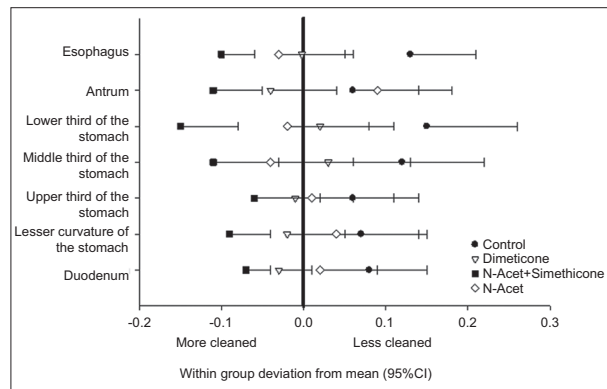


Figure 3 Differences with respect to grand mean by group of treatment
 The symbols represent mean differences and 95% confidence intervals. The thick line on zero represents the null value. The standard errors were calculated with robust analysis

can be effective [5,6]. However, the standard mucolytic used by most Asian centers, pronase (Beijing Tide-Pharmaceutical Co., Ltd., Beijing, China), is available exclusively in eastern countries. This has led several western studies to develop alternatives in order to obtain similar results. One of the most widely used at present is N-acetylcysteine, given its optimal efficacy and safety profile demonstrated in the most representative studies [7-12]. Several randomized controlled trials have shown the superiority of the combination of N-acetylcysteine plus simethicone for improving AMV. They also found areas in the GI tract with differences in cleaning qualities [8-12].

Manfredi *et al* [13] prospectively enrolled 197 patients divided into 2 groups: treated (97 patients) and control

(100 patients). The treated group were administered premedication with N-acetylcysteine (600 mg) + simethicone (2 mL) for 20 min before their gastroscopy, while the control group received no premedication. There was a significantly higher mean stomach cleaning cream score in the treated group (7.6±1.5) compared to the control group (6±0.7) (P<0.001). The investigators also observed a score ≤5 in 11% and 33% of the treated and control groups, respectively (P<0.001). This study provides further evidence of the benefits of these agents, but with a more systematic evaluation.

The greatest potential clinical impact of premedication with mucolytics and antifoams is the reduction in missed lesions due to better visibility of the GI mucosa. International clinical guidelines also advocate the use of these agents to optimize the detection of preneoplastic and early neoplastic lesions [14,15]. Monrroy *et al* [16] conducted a double-blinded, placebo-controlled randomized controlled trial in 230 patients undergoing diagnostic gastroscopies. There were 5 groups studied: 2 control groups, no intervention and water 100 mL (W); and 3 intervention groups: simethicone 200 mg (S), S + N-acetylcysteine (NAC) 500 mg (S + NAC500) and S + NAC 1000 mg (S + NAC1000). There was a higher lesion detection rate in the intervention groups compared to the non-intervention groups: 32% (37/115) versus 14% (6/42) (P=0.027). Adoption of the SACE system in previous studies showed an improvement in lesion detection and characterization [17,18]. Pérez-Mendoza *et al* [19] demonstrated diagnostic accuracies of 96% and 52% for coded alphanumeric systematic endoscopy and conventional endoscopy, respectively. The specificity was 95% for systematic alphanumeric coded endoscopy and 45% for conventional endoscopy. The combined use of mucolytics, anti-foaming agents and the SACE system optimizes lesion detection. Further studies in different populations are required to fully assess these parameters in lesion detection to improve clinical outcomes.

The administration 20 min before the procedure does not represent any significant risk of aspiration to patients [20-22]. The alternative to a pre-endoscopy drink is the application of water with simethicone during the procedure; however, the volume that needs to be instilled is usually significantly greater than 100 mL, and this is likely to lead to a greater risk of aspiration. This pre-endoscopy premedication has also been given in other Asian countries for decades, and there have been no safety concerns or reports of complications. The variability of an AMV can be explained by several factors affecting mucolytic activity: gastric acidity, duodenogastric reflux, and delayed gastric emptying (gastroparesis and functional dyspepsia) [23,24]. In our study we did not encounter any adverse events or side-effects.

The use of standardized endoscopic systems, high-definition white light endoscopy, and meticulous inspection techniques of the mucosa are of paramount importance to improve the detection of lesions [25-29]. The superimposed photographic record of the mucosa is a robust indicator of the integrity of the evaluation [17]. Overlapping images are critical for a registration of consecutive images that provide examiners with a complete sequence of the procedure. The systematic stomach screening protocol proposes a minimum of 22 endoscopic

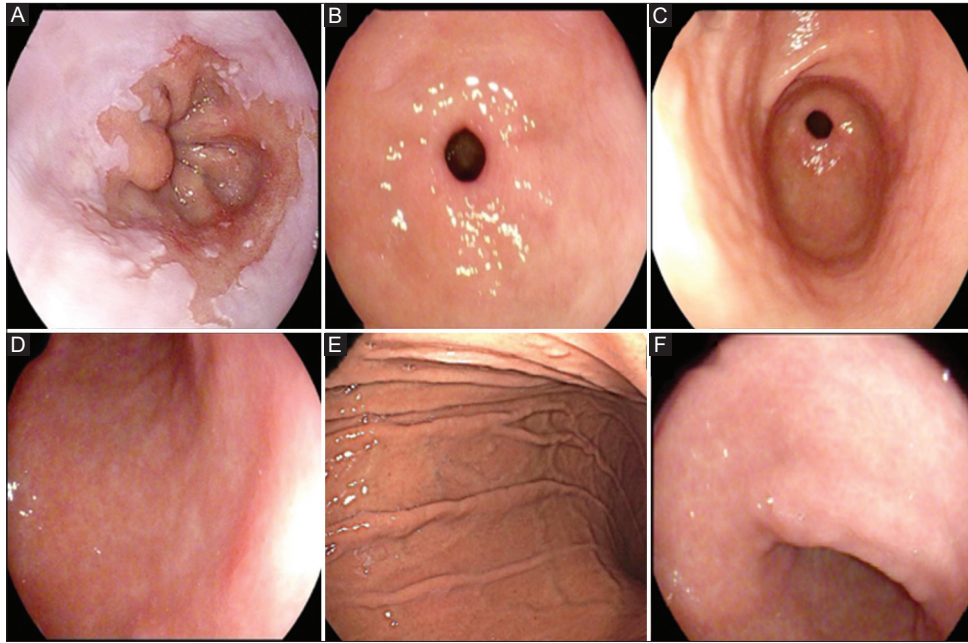


Figure 4 Adequate mucosal visibility of stomach. (A) Esophagogastric junction, (B) pyloric channel, (C) greater curvature of antrum, (D) posterior wall of lower third of the gastric body, (E) greater curvature of middle third of the gastric body, (F) lesser curvature of lower third of the gastric body

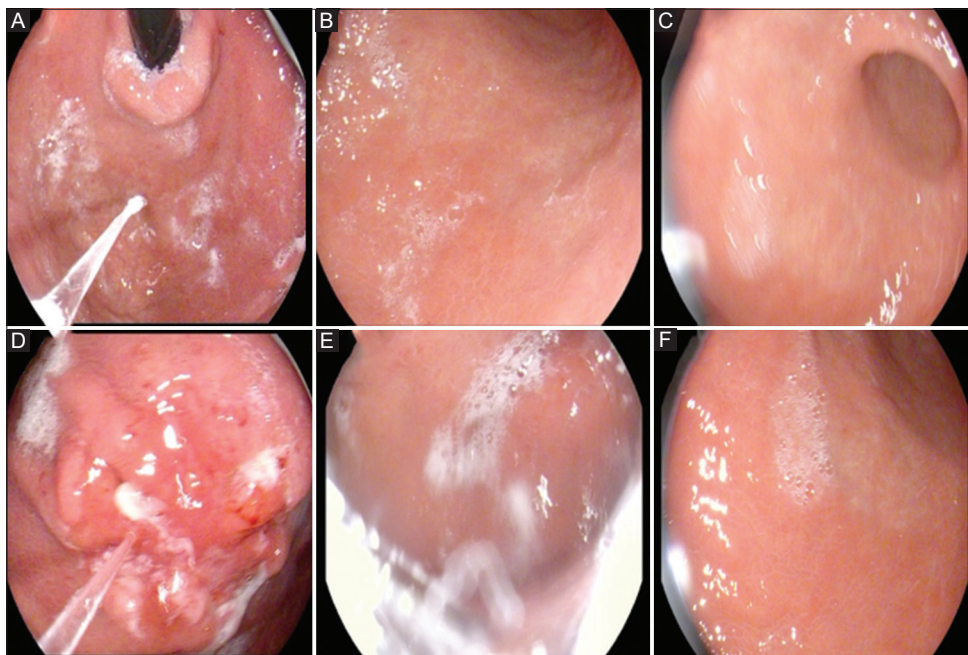


Figure 5 Inadequate mucosal visibility of stomach. (A) Fornix, (B) greater curvature (lower third of the gastric body), (C) anterior wall (lower third of the gastric body), (D) malignant lesion in lesser curvature (middle third of the gastric body), (E) antero-posterior wall (upper third of the gastric body), (F) anterior wall (middle third of the gastric body)

images. However, it does not take into account other digestive areas (hypopharynx, esophagus, esophagus-gastric junction, and duodenum) [18]. In contrast, SACE allows complete standardized evaluation of 28 specific areas of mucosa, from the hypopharynx to the second portion of duodenum, through the superposition of images (photodocumentation), which reduces blind spots [17,19]. This technique provides to the

examiner a sequence of images and can reduce medico-legal concerns over missed lesions [2,4,18]. This is the first study in the world to evaluate all areas (28 areas) of upper GI endoscopy using an imaging sequence protocol (SACE).

One limitation of this study is the lack of a standardized scale to classify mucosal visualization, as previous studies have used different measures. Another limitation of our study was

the lack of registration of the lesions found during endoscopy, procedure duration and the volume of water required to clean the mucosa. In the study, we did not perform tests to evaluate the degree of delayed gastric emptying. Randomized studies are still needed to evaluate the full effectiveness of SACE in detecting malignant and non-malignant lesions. Studies with a larger cohort of patients are required to evaluate the full pharmacological effect.

In conclusion, the combination of a mucolytic (N-acetylcysteine 600 mg) with an antifoam (simethicone 200 mg) was more effective than water or other substances alone in improving the AMV scale. Such premedication might improve the diagnostic yield of this procedure, and should be considered in routine clinical practice.

Acknowledgment

We would like to express our gratitude to Dr. Noriya Uedo, from Osaka International Cancer Institute, Department of Gastrointestinal Oncology, Osaka Japan, for kindly reviewing the manuscript.

Summary Box

What is already known:

- Premedication agents for improving mucosal visibility during upper gastrointestinal (GI) endoscopy are important in routine clinical practice
- Pronase is the mucolytic agent of choice to optimize the visibility of the gastroduodenal mucosa during upper GI endoscopy; however, it is only available in Eastern countries
- Systematic review during upper GI endoscopy is an essential element to optimize the early detection of neoplastic lesions

What the new findings are:

- N-acetylcysteine is an excellent alternative as a mucolytic agent for premedication in upper GI endoscopy in countries where pronase is not available
- The combination of N-acetylcysteine and simethicone in premedication for upper GI endoscopy is an optimal strategy to improve mucosal visibility
- The systematic alphanumeric-coded endoscopy system is an innovative method of systematic review and allows for a thorough evaluation of the entire upper GI tract

References

1. Emura F, Sharma P, Arantes V, et al. Principles and practice to facilitate complete photodocumentation of the upper gastrointestinal tract: World Endoscopy Organization position statement. *Dig Endosc* 2020;**32**:168-179.
2. Emura F, Rodriguez-Reyes C, Giraldo-Cadavid L. Early gastric cancer: current limitations and what can be done to address them. *Am J Gastroenterol* 2019;**114**:841-845.
3. Yang L. Incidence and mortality of gastric cancer in China. *World J Gastroenterol* 2006;**12**:17-20.
4. Suzuki H, Gotoda T, Sasako M, Saito D. Detection of early gastric cancer: misunderstanding the role of mass screening. *Gastric Cancer* 2006;**9**:315-319.
5. Kuo CH, Sheu BS, Kao AW, Wu CH, Chuang CH. A defoaming agent should be used with pronase premedication to improve visibility in upper gastrointestinal endoscopy. *Endoscopy* 2002;**34**:531-534.
6. Zhang LY, Li WY, Ji M, et al. Efficacy and safety of using premedication with simethicone/Pronase during upper gastrointestinal endoscopy examination with sedation: A single center, prospective, single blinded, randomized controlled trial. *Dig Endosc* 2018;**30**:57-64.
7. Asl SM, Sivandzadeh GR. Efficacy of premedication with activated dimethicone or N-acetylcysteine in improving visibility during upper endoscopy. *World J Gastroenterol* 2011;**17**:4213-4217.
8. Elvas L, Areia M, Brito D, Alves S, Saraiva S, Cadime AT. Premedication with simethicone and N-acetylcysteine in improving visibility during upper endoscopy: a double-blind randomized trial. *Endoscopy* 2017;**49**:139-145.
9. Basford PJ, Brown J, Gadeke L, et al. A randomized controlled trial of pre-procedure simethicone and N-acetylcysteine to improve mucosal visibility during gastroscopy - NICEVIS. *Endosc Int Open* 2016;**4**:E1197-E1202.
10. Mahawongkajit P, Kanlerd A. A prospective randomized controlled trial comparing simethicone, N-acetylcysteine, sodium bicarbonate and peppermint for visualization in upper gastrointestinal endoscopy. *Surg Endosc* 2021;**35**:303-308.
11. Chen X, Dai N, Deng Y, et al. Premedication with reformulated simethicone and sodium bicarbonate improves mucosal visibility during upper gastrointestinal endoscopy: a double-blind, multicenter, randomized controlled trial. *BMC Gastroenterol* 2021;**21**:124.
12. Chang WK, Yeh MK, Hsu HC, Chen HW, Hu MK. Efficacy of simethicone and N-acetylcysteine as premedication in improving visibility during upper endoscopy. *J Gastroenterol Hepatol* 2014;**29**:769-774.
13. Manfredi G, Bertè R, Iiritano E, et al. Premedication with simethicone and N-acetylcysteine for improving mucosal visibility during upper gastrointestinal endoscopy in a Western population. *Endosc Int Open* 2021;**9**:E190-E194.
14. De Francesco V, Alicante S, Amato A, et al. Quality performance measures in upper gastrointestinal endoscopy for lesion detection: Italian AIGO-SIED-SIGE joint position statement. *Dig Liver Dis* 2022;**54**:1479-1485.
15. Beg S, Ragnunath K, Wyman A, et al. Quality standards in upper gastrointestinal endoscopy: a position statement of the British Society of Gastroenterology (BSG) and Association of Upper Gastrointestinal Surgeons of Great Britain and Ireland (AUGIS). *Gut* 2017;**66**:1886-1899.
16. Monrroy H, Vargas JI, Glasinovic E, et al. Use of N-acetylcysteine plus simethicone to improve mucosal visibility during upper GI endoscopy: a double-blind, randomized controlled trial. *Gastrointest Endosc* 2018;**87**:986-993.
17. Emura F, Gralnek I, Baron TH. Improving early detection of

- gastric cancer: a novel systematic alphanumeric-coded endoscopic approach. *Rev Gastroenterol Peru* 2013;**33**:52-58.
18. Emura F, Mejía J, Mejía M, et al. Effectiveness of systematic chromoendoscopy for diagnosis of early cancer and gastric premalignant lesions. Results of two consecutive screening campaigns in Colombia (2006-2007). *Rev Col Gastroenterol* 2010;**25**:18-28.
 19. Pérez-Mendoza A, Zárate-Guzmán ÁM, Galvis García ES, Sobrino Cossío S, Djamus Birch J. Systematic alphanumeric-coded endoscopy versus chromoendoscopy for the detection of precancerous gastric lesions and early gastric cancer in subjects at average risk for gastric cancer. *Rev Gastroenterol Mex (Engl Ed)* 2018;**83**:117-124.
 20. Bertoni G, Gumina C, Conigliaro R, et al. Randomized placebo-controlled trial of oral liquid simethicone prior to upper gastrointestinal endoscopy. *Endoscopy* 1992;**24**:268-270.
 21. Keeratichananont S, Sobhonslidsuk A, Kitiyakara T, Achalanan N, Soonthornpun S. The role of liquid simethicone in enhancing endoscopic visibility prior to esophagogastroduodenoscopy (EGD): A prospective, randomized, double-blinded, placebo-controlled trial. *J Med Assoc Thai* 2010;**93**:892-897.
 22. Ahsan M, Babaei L, Gholamrezaei A, Emami MH. Simethicone for the preparation before esophagogastroduodenoscopy. *Diagn Ther Endosc* 2011;**2011**:484532.
 23. Vijayvargiya P, Jameie-Oskooei S, Camilleri M, Chedid V, Erwin PJ, Murad MH. Association between delayed gastric emptying and upper gastrointestinal symptoms: a systematic review and meta-analysis. *Gut* 2019;**68**:804-813.
 24. Parkman HP. Idiopathic gastroparesis. *Gastroenterol Clin North Am* 2015;**44**:59-68.
 25. Yao K. The endoscopic diagnosis of early gastric cancer. *Ann Gastroenterol* 2013;**26**:11-22.
 26. Gotoda T, Uedo N, Yoshinaga S, et al. Basic principles and practice of gastric cancer screening using high-definition white-light gastroscopy: eyes can only see what the brain knows. *Dig Endosc* 2016;**28** (Suppl 1):2-15.
 27. Menon S, Trudgill N. How commonly is upper gastrointestinal cancer missed at endoscopy? A meta-analysis. *Endosc Int Open* 2014;**2**:E46-E50.
 28. Nishizawa T, Suzuki H. Long-term outcomes of endoscopic submucosal dissection for superficial esophageal squamous cell carcinoma. *Cancers (Basel)* 2020;**12**:2849.
 29. Waddingham W, Nieuwenburg SAV, Carlson S, et al. Recent advances in the detection and management of early gastric cancer and its precursors. *Frontline Gastroenterol* 2021;**12**:322-331.