

Concise Clinical Review

Current Concepts in the Management of Periodontitis

TaeHyun Kwon^{a*}, Ira B. Lamster^b, Liran Levin^c^a Private Practice, Keene, NH, USA^b Stony Brook University School of Dental Medicine, Stony Brook, NY, USA^c Faculty of Medicine and Dentistry, University of Alberta, Edmonton, AB, Canada

ARTICLE INFO

Article history:

Available online 19 February 2021

Key words:

Biofilm

dental plaque

oral hygiene

periodontal disease

non-surgical periodontal therapy

ABSTRACT

Periodontitis is a common disorder affecting >40% of adults in the United States. Globally, the severe form of the disease has a prevalence of 11%. In advanced cases, periodontitis leads to tooth loss and reduced quality of life. The aetiology of periodontitis is multifactorial. Subgingival dental biofilm elicits a host inflammatory and immune response, ultimately leading to irreversible destruction of the periodontium (i.e. alveolar bone and periodontal ligament) in a susceptible host. In order to successfully manage periodontitis, dental professionals must understand the pathogenesis, primary aetiology, risk factors, contributing factors and treatment protocols. Careful diagnosis, elimination of the causes and reduction of modifiable risk factors are paramount for successful prevention and treatment of periodontitis. Initial non-surgical periodontal therapy primarily consists of home care review and scaling and root planing. For residual sites with active periodontitis at periodontal re-evaluation, a contemporary regenerative or traditional resective surgical therapy can be utilised. Thereafter, periodontal maintenance therapy at a regular interval and long-term follow-ups are also crucial to the success of the treatment and long-term retention of teeth. The aim of this review is to provide current concepts of diagnosis, prevention and treatment of periodontitis. Both clinical and biological rationales will be discussed.

© 2021 Published by Elsevier Inc. on behalf of FDI World Dental Federation. This is an open access article under the CC BY-NC-ND license (<http://creativecommons.org/licenses/by-nc-nd/4.0/>)

Periodontitis

Periodontitis is a chronic multifactorial inflammatory disease associated with the accumulation of dental plaque (which will be referred to as dental biofilm/biofilm), and characterised by progressive destruction of the teeth-supporting apparatus, including the periodontal ligament and alveolar bone.^{1,2} The disease involves complex dynamic interactions among specific bacterial pathogens, destructive host immune responses, and environmental factors such as smoking (Figure 1).^{1,3} The common features of periodontitis include gingival inflammation, clinical attachment loss, radiographic evidence of alveolar bone loss, sites with deep probing depths, mobility, bleeding upon probing and pathologic migration.^{2,4,5}

Prevalence and significance

According to data from the National Health and Nutrition Examination Survey 2009–2014, 42% of adults in the United

States had periodontitis, with 7.8% having severe periodontitis.⁶ This survey confirmed a high prevalence of periodontitis in the United States affecting almost 50% of the adult population (30 years old or older).⁶ Globally, approximately 11% of the world population may have severe periodontitis, affecting 743 million individuals (Figure 2).^{7–13} Furthermore, a robust literature has identified potential associations between periodontitis and certain non-communicable chronic diseases.¹⁴ In addition, the loss of periodontal support was associated with a significant reduction in masticatory performance.¹⁵ Thus, periodontitis and its clinical ramifications, including tooth loss, may have a substantially negative effect on oral health related quality of life (OHRQoL), while successful management may improve patients' OHRQoL.^{15,16}

Aetiology

Dental biofilm

For a susceptible host, microbial infection in subgingival dental biofilm by periodontal pathogens, in particular a group of specific gram-negative anaerobic species referred to as the red complex, results in chronic inflammation.^{17,18} These red-

* Correspondence author. Dr TaeHyun Kwon, Monadnock Perio & Implant Center, 819 Court street, Unit A, Keene, NH 03431, USA.

E-mail address: tkwon3@gmail.com (T. Kwon).

<https://doi.org/10.1111/idj.12630>

0020-6539/© 2021 Published by Elsevier Inc. on behalf of FDI World Dental Federation. This is an open access article under the CC BY-NC-ND license (<http://creativecommons.org/licenses/by-nc-nd/4.0/>)

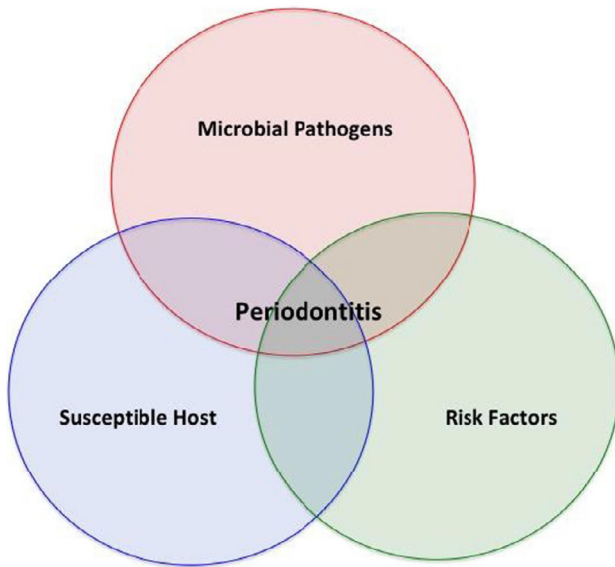


Fig. 1 – Periodontitis is multifactorial in nature and results from the presence of pathogenic bacteria, the host inflammatory and immune responses and other identified environmental and systemic risk factors.

complex bacteria include *Porphyromonas gingivalis*, *Tannerella forsythia*, and *Treponema denticola*, which are predominantly found in deep periodontal pockets of patients with periodontitis (Table 1).^{17–24} Lipopolysaccharide along with other virulence factors from these periodontal pathogens stimulate the host macrophages, and other inflammatory and constituent cells, leading to the production of a range of pro-inflammatory cytokines such as tumour necrosis factor (TNF)- α , interleukin (IL)-1 β and prostaglandin E₂ (PGE₂). The presence of these pro-inflammatory cytokines and virulence factors stimulates the

production of matrix metalloproteinases (MMPs) by macrophages, fibroblasts, junctional epithelial cells, and neutrophils.^{3,25} The resulting MMPs then mediate the destruction of collagen fibres in periodontal tissues, especially periodontal ligaments.³ In addition, the pro-inflammatory cytokines induce the expression of receptor activator of nuclear factor κ B ligand (RANK-L) on the osteoblasts and T helper cells. The resulting RANK-L on the osteoblasts and the T helper cells then interacts with receptor activator of nuclear factor κ B (RANK) on osteoclast precursors, which results in the genesis of osteoclasts and their maturation. The mature osteoclasts mediate alveolar bone destruction.^{26,27}

Natural history/progression

Periodontitis was previously believed to progress at a constant rate until treatment or tooth loss.²⁸ For instance, individuals with so-called rapidly progressing periodontitis exhibited an annual rate of interproximal attachment loss of between 0.1 and 1.0 mm, while individuals with moderately progressing periodontitis exhibited a loss of between 0.05 and 0.5 mm.²⁹ Individuals with minimal to no progression exhibited an annual loss rate of between 0.05 and 0.09 mm.²⁹ Currently, based on longitudinal observations from human and animal studies, periodontitis is now believed to progress by recurrent acute episodes instead.^{28,30} During their lifetime, patients with periodontitis exhibit a cycle of bursts of destruction at individual sites over short periods of time, followed by longer periods of remission.^{28,31}

Diagnosis

A patient's medical history should be obtained prior to periodontal assessment. This will provide identification of any

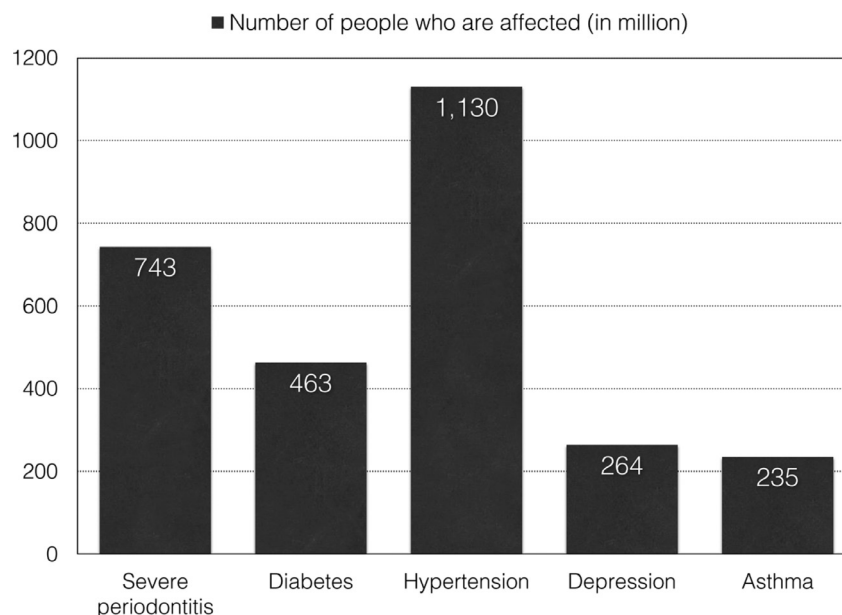


Fig. 2 – Global prevalence of severe periodontitis^{7–9} in comparison to diabetes¹⁰, hypertension¹¹, depression¹² and asthma.¹³

Table 1 – Red-complex bacteria and their characteristics

Pathogens	Characteristics ¹⁹	Virulence factors	Major functions
<i>Porphyromonas gingivalis</i>	Gram negative Non-motile Anaerobic Pleomorphic rod (coccal to short)	Capsule Fimbriae Outer membrane proteins Gingipains	Antiphagocytic ²⁰ Cellular adhesion ²⁰ Contain LPS, eliciting the host pro-inflammatory response and the production of pro-inflammatory cytokines ²¹ Possibly linked to Alzheimer's disease ²² <ul style="list-style-type: none"> • Degrade host proteins, providing essential amino acids, peptides and heme for the growth of <i>Tannerella forsythia</i>²³ • Degrade periodontal tissues²³ • Activate host degradative enzymes²³ • Modify host cell proteins to expose cryptotopes for bacterial colonisation²³ • Cleave components in host innate (cytokines, complement factors) and adaptive immune system (immunoglobulins), thus paralysing host immunity²³ • Active components involved in clotting and fibrinolysis²³
<i>Tannerella forsythia</i>	Gram negative Non-motile Anaerobic Pleomorphic rod (spindle shaped)	Various proteinases	Induces host cellular apoptosis ²³ <ul style="list-style-type: none"> • Enable the bacterium to rapidly colonise new sites, penetrate deep periodontal pockets, and penetrate epithelial layers²⁴ • Impair neutrophil chemotaxis and phagocytosis • Interact synergistically with other periodontal pathogens including <i>Porphyromonas gingivalis</i> and <i>Tannerella forsythia</i> at several levels²⁴ • Bind to and coat their surface with soluble host proteins, thus avoiding and delaying host recognition²⁴
<i>Treponema denticola</i>	Gram negative Motile Anaerobic Cork-screw shaped or spiralled	Surface lipoproteins Motility and chemotaxis Outer sheath proteins (dentilisin, major sheath proteins, lipoproteins) Metabolic end products Toxin-antitoxin system, and transposases	Cytotoxic to various host cells ²⁴ <ul style="list-style-type: none"> • Contribute to biofilm formation and persistence²⁴ • Resist to various environmental assaults such as antibiotics²⁴ • Allows transfer of virulence genes through horizontal gene transfer within biofilm²⁴

systemic or environmental risk factors for periodontitis, such as diabetes and smoking. A comprehensive periodontal evaluation includes several clinical parameters: biofilm index, periodontal probing depth, presence of bleeding on probing, gingival recession, mucogingival deformity, furcation involvement, tooth mobility, and occlusal trauma. A comprehensive radiographic evaluation is a part of the initial periodontal evaluation to determine the extent of horizontal and vertical alveolar bone loss. According to the 2017 World Workshop on the Classification of Periodontal and Peri-Implant Diseases and Conditions², a new periodontitis classification categorises the disease based on a multi-dimensional staging and grading system. Staging is determined by the severity of the disease at initial presentation and the complexity of disease management (Table 2).² Furthermore, grading is used as an indicator of the rate of periodontitis progression, which is determined by the history as well as the presence of risk factors for periodontitis (Table 3).²

Risk factors

Smoking

Smoking is the most important environmental risk factor for periodontitis. Compared to non-smokers or past smokers, smokers exhibited a significantly higher prevalence of red-complex periodontal pathogens in their subgingival biofilm.^{32–34} Furthermore, a potential negative effect of smoking

on host immune cells, especially neutrophils, was reported, making their host more susceptible to periodontitis.^{35–37} Consistent with these findings, light and heavy smokers are at a greater risk for developing alveolar bone loss with an odds ratio of 3.25 and 7.28, respectively, compared to non-smokers. Similarly, light and heavy smokers are at a greater risk for developing periodontal attachment loss with an odds ratio 2.05 and 4.07, respectively, compared to non-smokers.³⁸ Furthermore, smoking has a negative impact on the outcome of active periodontal therapy as well as long-term maintenance periodontal therapy.^{39,40} Thus, patients should be continuously reminded of the importance of smoking cessation for successful management of periodontitis.⁴¹

Diabetes

Patients with uncontrolled diabetes are at a greater risk for developing periodontitis as compared to systemically healthy patients or patients with well-controlled diabetes.^{42,43} Plausible biological mechanisms underlying this association have been scientifically validated.⁴³ The association is partly due to alterations in the immune system of patients with uncontrolled diabetes, which result in impaired neutrophil function or hyper-responsive macrophages producing pro-inflammatory cytokines.⁴³ Furthermore, patients with uncontrolled diabetes exhibit alterations in connective tissue metabolism, which modulates the resorptive and formative process in the periodontium.⁴³ The alterations in connective tissue metabolism are due to higher levels of advanced glycation end

Table 2 – The stages of periodontitis

Periodontal stage	Stage I	Stage II	Stage III	Stage IV
Severity	1 to 2 mm Interdental CAL at site of greatest loss Radiographic bone loss Tooth loss	3 to 4 mm Coronal third (15% to 33%)	≥5 mm Extending to middle or apical third of the root Tooth loss due to periodontitis of <4 teeth	≥5 mm Extending to middle or apical third of the root Tooth loss due to periodontitis of ≥5 teeth
Complexity	Maximum probing depth ≤4 mm. Mostly horizontal bone loss	Maximum probing depth ≤5 mm. Mostly horizontal bone loss	In addition to stage II complexity: • Probing depth ≥6 mm • Vertical bone loss ≥3 mm • Furcation involvement Class II or III	In addition to stage III complexity: Need for complete rehabilitation due to: • Masticatory dysfunction • Secondary occlusal trauma (tooth mobility degree ≥2) • Severe ridge defect • Bite collapse, drifting, flaring • Less than 20 remaining teeth (10 opposing pairs)
Extent and distribution	Local	For each stage, describe extent as localised (<30% of teeth involved), generalised, or molar/incisor pattern		

The stage of periodontitis is initially determined based on clinical attachment loss (CAL). If CAL is not available, then radiographic bone loss can be used. A history of tooth loss due to periodontitis may modify the stage. In the presence of any complexity factor, the stage may shift to a higher tier. For example, the presence of class II or III furcation involvement would shift to either stage III or IV regardless of CAL, radiographic bone loss, or tooth loss due to periodontitis. The extent and distribution is primarily determined by the percentage of teeth involved.² The table was modified from Papanou et al. (2018).²

products (AGEs) and interaction with their receptors, receptors for AGE (RAGEs), in patients with uncontrolled diabetes compared to systemically healthy patients or patients with well-controlled diabetes.^{43–47} The interaction between AGEs and RAGEs results in the marked elevation of gingival crevicular fluid levels of IL-1 β , TNF- α and PGE₂ in patients with uncontrolled diabetes.^{43,45,47} These pro-inflammatory cytokines then contribute to the inflammatory response that characterises periodontitis.^{43,45,47} Lastly, macrovascular (i.e. atherosclerosis) and microvascular changes (i.e. thickening of the basement membrane) in patients with uncontrolled diabetes may result in the abnormal growth of vessels, impaired regeneration of vessels, and abnormal homeostatic transport across the basement membrane in the periodontium.⁴³

Clinically, patients with type 2 diabetes exhibited an increased risk of periodontitis with an odds ratio of 2.81 for clinical attachment loss and an odds ratio of 3.43 for alveolar bone loss.³³ Patients with diabetes exhibit a greater percentage of teeth having at least one site with a probing depth of 5 mm or more, a greater percentage of sites with bleeding on probing, and a greater number of missing teeth compared to non-diabetic patients.⁴⁸ Moreover, patients with uncontrolled diabetes may not respond as favourably to periodontal therapy as do patients with periodontitis but milder diabetes.⁴³ Thus, patients' glycaemic status should be continuously monitored, and haemoglobin A1c (HbA1c) levels should be documented. Ideally, the HbA1c level should be <7.0%.² For patients with poorly managed diabetes, inter-professional practice is essential.

Contributing factors

Overhanging/over-contoured restorations

Overhanging or over-contoured restorations may promote dental biofilm retention, initiating a local periodontal lesion.^{49,50} Thus, a restoration with overhang or excessive contour should be eliminated during the course of periodontal therapy to create an environment that allows biofilm removal (Figure 3).

Open interproximal contacts

Open interproximal contacts may promote biofilm retention due to chronic food impaction.⁵¹ Thus, during the course of treatment, open interproximal contacts should be corrected.

Occlusal trauma

Though occlusal trauma is not considered a risk factor for alveolar bone loss or development of periodontal disease, when occlusal trauma is present, periodontitis may exhibit a greater rate of progression.^{52,53} Thus, resolution of occlusal trauma should be considered during periodontal therapy (Figure 4). For example, fremitus on centric occlusion or excursive movement should be eliminated in periodontally compromised teeth. Teeth presenting with excessive or increasing mobility as a result of occlusal trauma may be splinted.⁵⁴

Table 3 – The grades of periodontitis

Periodontitis grade			Grade A: Slow rate of progression	Grade B: Moderate rate of progression	Grade C: Rapid rate of progression
Primary criteria	Direct evidence of progression ≥ 2 mm over 5 years	Longitudinal date	(radiographic bone loss or CAL)	Evidence of no loss over 5 years	<2 mm over 5 years
Case	Indirect evidence of progression	% bone loss/age phenotype	<0.25 Heavy biofilm deposits with low levels of destruction	0.25 to 1.0 Destruction commensurate with biofilm deposits	≥ 1.0 Destruction exceeds expectation given biofilm deposits; specific clinical patterns suggestive of periods of rapid progression and/or early onset disease (e.g. molar/incisor pattern; lack of expected response to standard bacterial control therapies)
Grade modifiers	Smoker ≥ 10 cigarettes/day	Risk factors	Smoking	Non-smoker	Smoker <10 cigarettes/day
Diabetes			Normoglycaemic/ no diagnosis of diabetes	HbA1c <7.0% in patients with diabetes	HbA1c $\geq 7.0\%$ in patients with diabetes

Grade is primarily determined by the direct evidence of progression. If not available, then the indirect evidence of progression can be used. In the presence of risk factors for periodontitis, the grade can shift to a higher tier.² The table was modified from Papapanou et al. (2018).² CAL, clinical attachment loss; HbA1c, haemoglobin A1c.

Mucogingival deformity

The presence of 2 mm or more of attached gingiva is considered necessary to maintain gingival health.⁵⁵ A significantly higher gingival index was noted for teeth with <2 mm of attached gingiva compared to those with at least 2 mm of attached gingiva.⁵⁵ Thus, all mucogingival deformities should be recorded during a comprehensive periodontal evaluation and, if indicated, treated during the phase of surgical periodontal therapy.

Anatomical factors

The presence of certain anatomical factors such as a cemental tear⁵⁶, narrow furcation entrance,⁵⁷ enamel pearl,^{58,59} root concavity,⁵⁷ cervical enamel projection,⁶⁰ and positioning of the tooth^{61,62} may increase the risk of local periodontal attachment loss (Figure 5). Thus, these factors should be considered during diagnosis and treatment.

Treatment

Initial cause-related therapy

Home care review

Achieving adequate home care is an essential component of prevention of periodontal disease, successful periodontal therapy and long-term retention of the dentition.^{63–65} Clinicians should educate patients about the importance of effectively removing dental biofilm at home, especially prior to proceeding with active periodontal therapy (Figure 6).⁶⁶ The importance of adequate home care should be reinforced frequently during the initial and subsequent phases of periodontal treatment.

Scaling and root planing

After adequate home care or biofilm control is achieved, scaling and root planing should be performed at the sites with periodontal probing depths of 5 mm or greater. This phase of treatment should be delivered in conjunction with correction of local contributing factors, extraction of hopeless teeth and treatment of active carious lesions. During scaling and root planing, adequate local anaesthesia should be administered prior to initiating the procedure to ensure patient comfort. Automated instruments, such as piezoelectric or ultrasonic scalers, may be used in combination with manual instruments.⁶⁷ For areas where access is difficult, automated instruments may be superior to curettes for removal of subgingival biofilm and calculus.⁶⁸ Occlusal adjustment should be considered to relieve fremitus, severe mobility, or excessive central and lateral excursive contact.⁵⁴ Clinically, a periodontal explorer such as Old Dominion University explorer 11/12 should be used to check for removal of subgingival calculus. Furthermore, post-operative intraoral radiographs may be helpful to assess removal of subgingival calculus visible on pre-operative intraoral radiographs. For patients with severe periodontitis, adjunctive use of systemic antibiotics may be considered.^{69,70} Recent randomised clinical trials^{71,72} as well as systematic reviews and meta-analysis^{73–75} reported a significant improvement in the outcome of scaling and root planing when antibiotics were used systemically as an adjunctive therapy. For example, in a recent systematic review of a total of 28 double-blinded randomised controlled trials investigating the benefit of systemic antibiotics as an adjunctive therapy to scaling and root planing in the treatment of moderate to severe periodontitis,⁷⁶ meta-analysis reported a statistically significant additional full-mouth probing depth mean reduction of 0.448 mm and a clinical attachment gain of 0.389 mm at 6-month follow-up in the antibiotic versus the placebo control groups, which appeared to persist

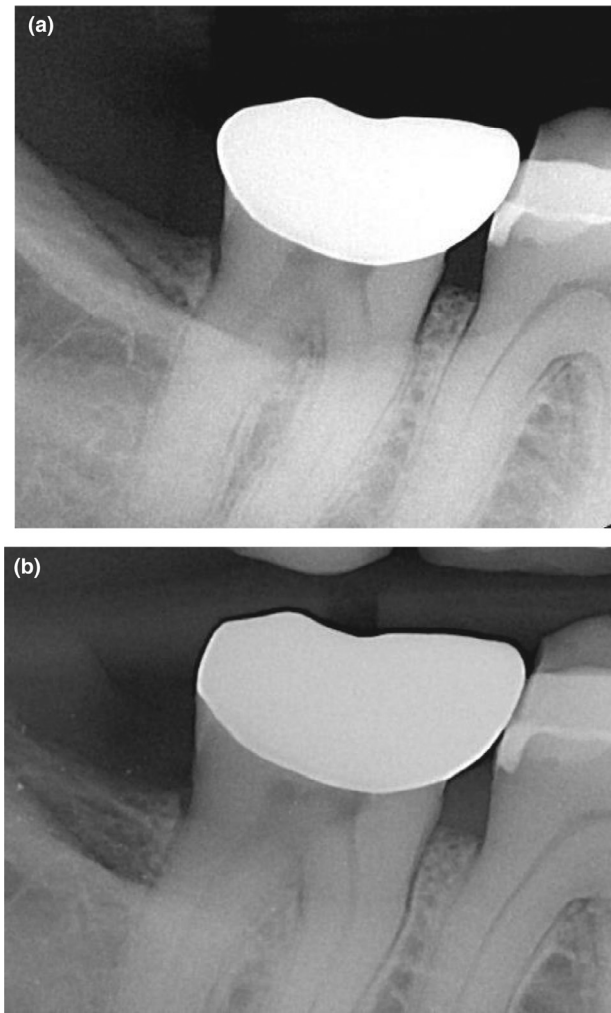


Fig. 3 – Management of a restoration with excessive contour. (a) Pre-operative radiograph; over-contoured restoration was present on the distal aspect of the mandibular right second molar, causing biofilm and food accumulation in the area. As a result, the distal aspect of the mandibular right second molar exhibited 6–7 mm probing depths. (b) Post-operative radiograph; the restoration was modified in order to improve the distal contour of the mandibular right second molar.

at 12-month follow-up (i.e. pocket probing reduction of 0.485 mm and clinical attachment level gain of 0.285 mm).⁷⁶ These improvements were further supported by reductions in bleeding on probing and in frequency of residual periodontal pockets, and increases in periodontal pocket closure.⁷⁶ The most significant benefit was observed with amoxicillin and metronidazole.⁷⁶ Considering the limited evidence to support the superiority of any specific dosage regimen, clinicians should consider using the highest dosage for the shortest duration of time to reduce the risk of antibiotic resistance.⁷³ For a localised site with a deep periodontal probing depth, administration of a locally delivered antibiotic (i.e. minocycline microspheres^{77–80}) or an antimicrobial (i.e. chlorhexidine chip^{81,82}) may be considered. Benefit of host

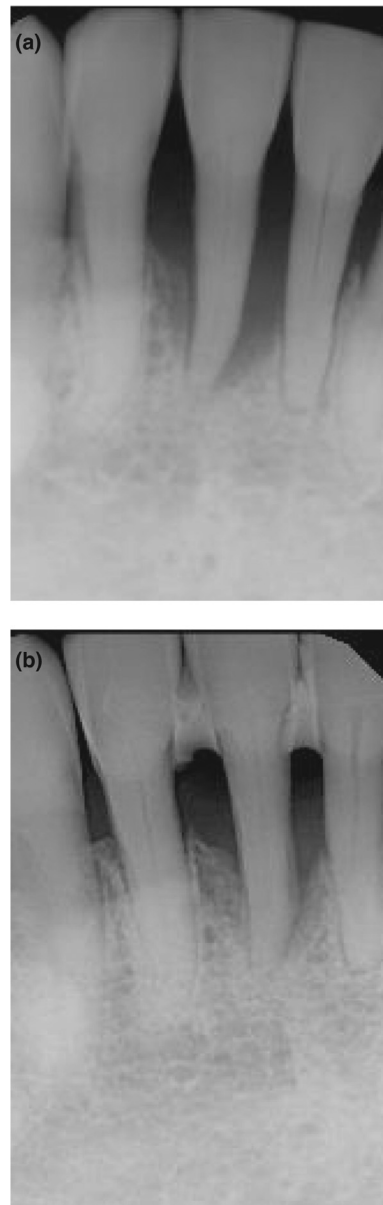


Fig. 4 – A mandibular right central incisor with severe alveolar bone loss and secondary occlusal trauma. (a) Pre-operative radiograph; the mandibular right central incisor exhibited a severe vertical bone loss. Clinically, the tooth exhibited excessive mobility as a result of occlusal trauma. (b) One year post-operative radiograph; after initial periodontal therapy with occlusal adjustment and splinting, radiographic evidence of increased height of alveolar bone was noted for the mandibular incisors. No surgical treatment was performed.

modulation therapy was also reported in several studies.^{83,84} When administered at sub-antimicrobial dosages, doxycycline inhibits MMPs in the gingival tissues without a microbial effect.^{83,84} The significant adjunctive effect of sub-antimicrobial dosage doxycycline in addition to scaling and root planing was found in treating patients with periodontitis.⁸³ Furthermore, the adjunctive use of omega-3 fatty acids and

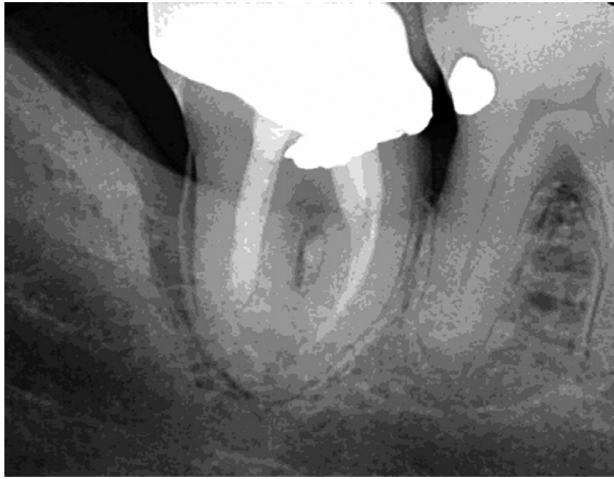

Fig. 5 – A mandibular right second molar with a distal cemental tear. Right mandibular second molar exhibited cemental tear on its distal surface. This was associated with an infrabony defect as well as a deep periodontal pocket (9 mm).

81 mg acetylsalicylic acid with scaling and root planing in patients with periodontitis resulted in a significant reduction of probing depths and a significant clinical attachment gain compared to scaling and root planing alone.^{85,86} This significant adjunctive benefit is possibly due to the combined effect of producing host endogenous protective mediators such as resolvins, in addition to the anti-inflammatory effect, on resolving inflammation.^{85,86} Available adjunctive therapeutic modalities are summarised in Table 4.^{69–75,77–102} It must be emphasised that limited literature and evidence are available for most adjunctive therapeutic modalities except systemic antibiotics and that clinicians should carefully plan using these modalities based on the most current evidence.¹⁰³

Table 4 – Available adjunctive therapies to scaling and root planing

Adjunctive therapies	Specifics
Systemic antibiotics	Amoxicillin and metronidazole ^{69–71,73–75} Azithromycin ^{71,87–91} Doxycycline ^{92–94}
Locally delivered antibiotics/antimicrobials*	Minocycline microspheres ^{77–80} Chlorhexidine chip ^{81,82}
Host modulation therapy*	Subclinical dose doxycycline ^{83,84} Omega-3 and 81 mg ASA ^{79,80}
Other adjunctive therapies*	Antimicrobial photodynamic therapy ⁹⁵ Laser therapy ^{96,97} Probiotics ^{98,99} Propolis ^{100,101} Chlorhexidine ¹⁰²

ASA, acetylsalicylic acid.

* Limited literature is available and clinicians should carefully plan using these modalities based on the most current evidence.

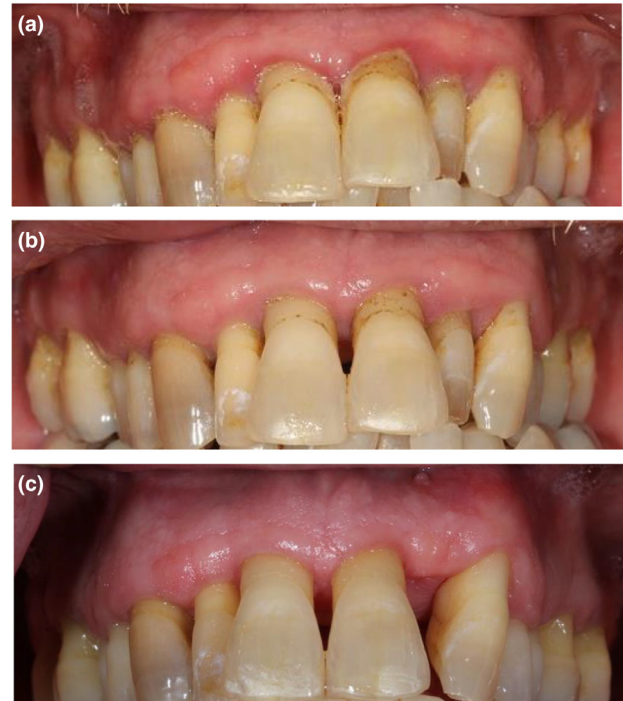


Fig. 6 – Effect of home care on reducing periodontal inflammation. Improved home care/biofilm removal should be demonstrated prior to beginning active periodontal therapy. Patient presented with generalised gingival marginal erythema as well as oedema in the maxillary arch. Moderate deposits of dental biofilm were noted at the gingival margin. As a result of home care, after 9 weeks, significant resolution of gingival erythema and oedema were noted. Minimally visible dental biofilm was present, indicating effective home care. Scaling and root planing was then initiated, specifically aimed at the removal of supragingival and subgingival calculus. After completing initial cause-related therapy and achieving a stable periodontium, the maxillary left lateral incisor was extracted due to its linguoversion and endodontic pathology. (a) Initial. (b) After 9 weeks of home care. (c) Periodontal re-evaluation: 6 weeks after completing initial cause-related therapy (i.e. home care, scaling and root planing; no periodontal surgery was performed).

Periodontal re-evaluation

Four to six weeks after completing scaling and root planing, a re-evaluation should be conducted (Figure 6). A comprehensive periodontal charting should be updated and the findings compared to the initial charting to determine the degree of improvement. Furthermore, patient compliance, as determined by adherence to the suggested home care regimen, should be carefully evaluated. Generally, for areas with relatively shallow probing depths (i.e. 1–5 mm), non-surgical management, including repeated root planing if indicated, frequent periodontal maintenance therapy and continuous reinforcement of home care could be considered as a treatment approach. The efficiency of subgingival calculus removal decreases as the probing depth increases.^{104,105} Thus, for areas with persistently deep periodontal probing

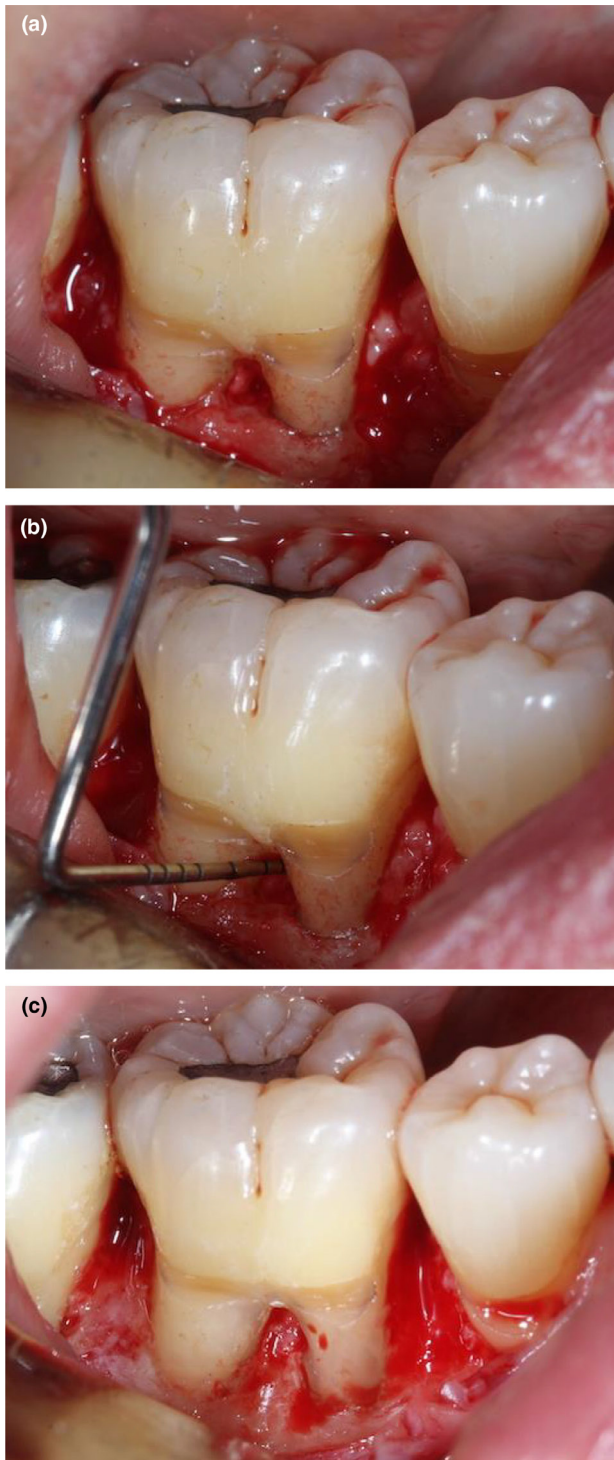


Fig. 7 – Resective periodontal surgery in the area of a mandibular right first molar. (a) Mandibular right first molar with a persistent probing depth of 7 mm on mid-buccal aspect, with grade II furcation. An infrabony defect was associated with the presence of cervical enamel projection. (b) Advanced furcation involvement was confirmed. Osseous recontouring in combination with removal of the cervical enamel projection was planned. The buccal convexity of the roots was reduced in order to decrease the horizontal furcation depth. (c) Completion of recontouring prior to closure of the surgical wound. Resolution of infrabony defect,

depths (i.e. 6 mm or deeper), surgical periodontal therapy may be indicated. It must be emphasised that excellent compliance with suggested home care is an indispensable prerequisite for proceeding with surgical therapy in order to achieve the optimal surgical outcome.⁶⁴ Thus, if necessary, surgical therapy should be delayed until adequate biofilm removal is demonstrated by the patient.⁶⁴

Periodontal surgical therapy

Resective periodontal surgery

Areas with persistently deep probing depths generally exhibit underlying infrabony or vertical defects. Such teeth with infrabony or vertical defects exhibit significantly reduced survival compared to teeth without those defects.^{106,107} Thus, for these teeth, osseous resective surgery may be considered. During this surgery, infrabony or vertical osseous defects should be reduced or eliminated by osteotomy and osteoplasty.¹⁰⁸ Thereafter, the gingival tissue may be positioned apically at the new height of alveolar crest. This would result in resolution or reduction of the deep probing depths (Figure 7).¹⁰⁸ For areas with persistently deep probing depths without an apparent underlying alveolar defect, soft tissue resection may be considered.^{109–114} Post-surgically, resective periodontal surgery may result in attachment loss in immediately neighbouring but less involved sites,¹¹⁵ dentinal hypersensitivity from the exposed root surfaces,^{116,117} transient increase in tooth mobility,¹¹⁸ and loss of interproximal papilla.¹¹⁹ The loss of interproximal papilla may result in chronic food impaction, aesthetic concerns and phonetic change.¹¹⁹

Regenerative periodontal surgery

Regenerative periodontal surgery is intended to re-establish periodontal tissues lost as a result of the disease process. Specifically, the goal of this type of surgery is to increase attachment of the teeth to the periodontium and induce bone gain and increased support for the dentition.^{120,121} For infrabony or vertical defects, periodontal regenerative therapy should also be considered. Guided tissue regeneration utilises a barrier membrane with various particulate bone graft material.^{122–125} A number of different approaches have been introduced. Recently, in order to further enhance the outcome of periodontal regeneration, biologic modifiers have been utilised in combination with bone replacement grafts and barrier membranes.¹²⁶ Purified recombinant human platelet derived growth factor BB (rhPDGF-BB) is a potent wound healing growth factor and stimulator of the proliferation and recruitment of cells of the periodontal ligament as well as bone cells.¹²⁷ A meta-analysis and human histologic studies reported a greater clinical attachment gain and a greater bone fill with rhPDGF-BB in the treatment of infrabony defects and advanced furcation lesions as compared to the carrier or bone replacement graft alone.^{127–129}

complete removal of cervical enamel projection and reduction in horizontal furcation depth were achieved.

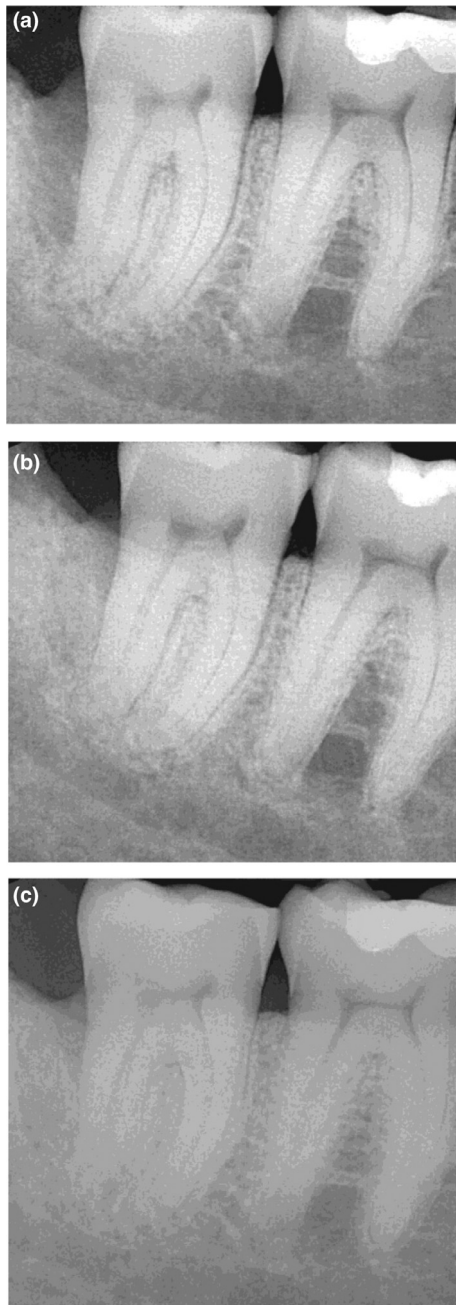


Fig. 8 – Regenerative periodontal therapy on a mandibular right second molar. (a) Pre-operative radiograph; the mandibular right second molar exhibited a vertical bone loss on its distal surface. (b) Post-operative radiograph; after 5 months of healing following laser-assisted periodontal regenerative therapy, an increase in the height of alveolar bone was noted on the distal surface of the mandibular right second molar. (c) Post-operative radiograph; after 10 months of healing following laser-assisted periodontal regenerative therapy. Further increase in the height of alveolar bone as well as an increase in alveolar bone density were noted on the distal surface of the mandibular right second molar.

Similarly, enamel matrix derivatives (EMD) have been used in periodontal regenerative therapy with the intent of inducing cell proliferation of both osteoblasts and periodontal

ligament cells.^{130,131} A meta-analysis reported that infrabony defect sites that were treated with EMD revealed a significantly greater clinical attachment gain compared to sites that were treated with open-flap debridement, ethylenediaminetetraacetic acid, or a placebo.¹³²

Therapy using an Nd:YAG laser was reported to achieve periodontal regeneration (Figure 8).^{133,134} During this therapy, the laser is used to selectively remove the diseased inner sulcular epithelium, potentially exposing more of the diseased root surface. Following thorough root planing of the involved root surface, the laser is used again to create a stable blood clot.^{133,134} However, considering the limited published data, the use of Nd:YAG laser therapy for periodontal regeneration requires further evaluation.¹³⁵

When planning regenerative periodontal therapy, the morphology of the periodontal alveolar defect such as the number of remaining alveolar walls (i.e. 1,2,3-walled defect) and the angulation of the defect, should be carefully considered (Figure 9).^{106,123} Significantly better regenerative outcomes were found with more remaining alveolar walls and a defect angulation of <45 degrees.^{106,123}

Mucogingival surgery

After completing initial periodontal therapy, and when there is a specific indication, mucogingival deformity should be carefully evaluated and treated if necessary. During this evaluation, among the clinical parameters considered are the severity of gingival recession, progression of recession, width of remaining keratinised gingiva, frenal involvement, vestibular depth, presence of marginal gingival inflammation, dental hypersensitivity and aesthetic concerns.¹¹⁷

Periodontal maintenance therapy

For patients with a history of periodontal disease, periodontal maintenance should be provided on a regular and recurrent basis, generally at intervals of 2–6 months;^{136,137} however, the appropriate interval should be determined following completion of active periodontal therapy, and modified by continuously assessing an individual's risk for periodontitis.¹³⁷ Among the factors to be considered are medical history (i.e. diagnosis of diabetes), smoking habit, presence of residual sites with deep probing depths, presence of other aforementioned contributing factors, and the level of home care.¹³⁷ A regular recall interval allows timely detection and intervention upon the recurrence or re-activation of disease in patients who have been previously treated for periodontitis.¹³⁶ For example, compared to erratic and non-compliant patients, compliant patients who regularly attended periodontal maintenance therapy exhibited a significantly reduced tooth loss due to periodontitis.¹³⁸ During maintenance therapy, periodontal charting should be updated and radiographs obtained as needed. Furthermore, home care should be thoroughly reviewed. For areas with persistently deep or progressing periodontal probing depths, re-initiating active periodontal therapy (i.e. scaling and root planing, and surgical periodontal therapy) should be considered.¹³⁶

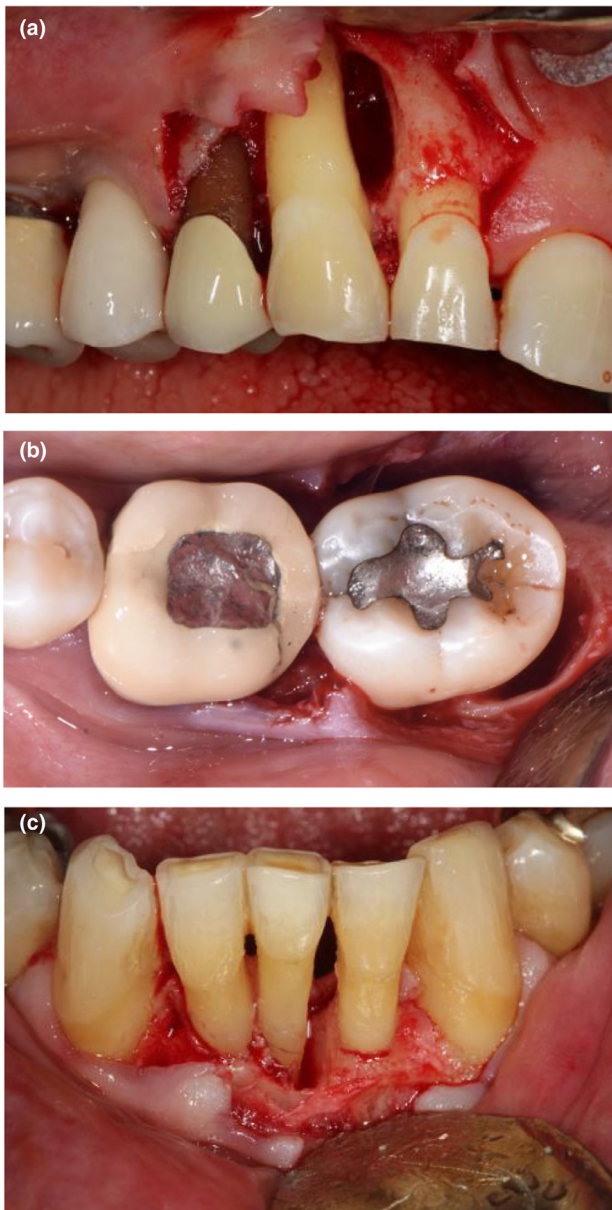


Fig. 9 – Different types of periodontal alveolar defects. (a) Two-walled alveolar defect (mesial and palatal walls). (b) Three-walled alveolar defect (distal, lingual and buccal walls; photograph courtesy of Dr Howard Yen, periodontist). (c) Combined alveolar defect (coronally 1-walled defect and apically 3-walled defect).

Decision tree and current trends

A decision tree representing the management of a patient with periodontitis can be helpful (Figure 10), recognising that the goals of periodontal therapy include not only the

arrest of periodontitis but when feasible the regeneration of periodontium lost as a result of disease.¹³⁹ Traditional resective periodontal surgery offers reliable methods to access root surfaces, reduce periodontal probing depths and attain improved periodontal architecture.¹³⁹ However, these procedures offer only limited potential towards recovering tissues destroyed during earlier active disease.¹³⁹ The introduction of new biological modifiers and new approaches to successful periodontal regeneration indicates a trend favouring conservative surgical therapy.¹³⁹ This represents a fundamental shift in the intent of periodontal surgery, away from tissue removal to an approach that maintains existing periodontium and seeks to re-establish support that was lost.

With the introduction of dental implants, a natural tooth with a compromised periodontal prognosis may be extracted and replaced with a dental implant instead of receiving periodontal therapy. However, while implant retention is high (at least 90% after 5 years), a meta-analysis of a total of 6,283 implants estimated the frequency of peri-implant mucositis and peri-implantitis as 30.7% and 9.6%, respectively, indicating that implant therapy is not without complications.¹⁴⁰ Furthermore, peri-implantitis and periodontitis appeared to share common risk factors such as poor oral hygiene, smoking and diabetes.^{141,142} The previous history of periodontitis as well as having a residual site with a periodontal depth of 6 mm or more were also associated with greater odds for developing peri-implantitis.^{141,143–145} Thus, the premature and strategic removal of a tooth with periodontitis for the sake of delivering implant therapy should be avoided.¹⁴⁶ In addition, when considering extraction of a tooth due to periodontitis and subsequent replacement with a dental implant, clinicians should inform patients regarding the potential risk of developing peri-implantitis, which may ultimately result in implant failure.¹⁴⁷

Lastly, there is now a robust literature indicating an association between periodontitis and certain systemic conditions.^{14,148,149} Although a detailed discussion of this topic is beyond the scope of this review, this research has resulted in a shift in how periodontitis and treatment of periodontal disease are considered in the larger context of general health.^{150–152}

Conclusions

Careful diagnosis, elimination of the causes and reduction of modifiable risk factors are paramount for successful prevention and treatment of periodontitis. Following the completion of initial non-surgical periodontal therapy predominantly consisting of home care review and scaling and root planing, contemporary regenerative or traditional resective surgical therapies can be utilized to eradicate any residual site with active periodontitis. Thereafter,

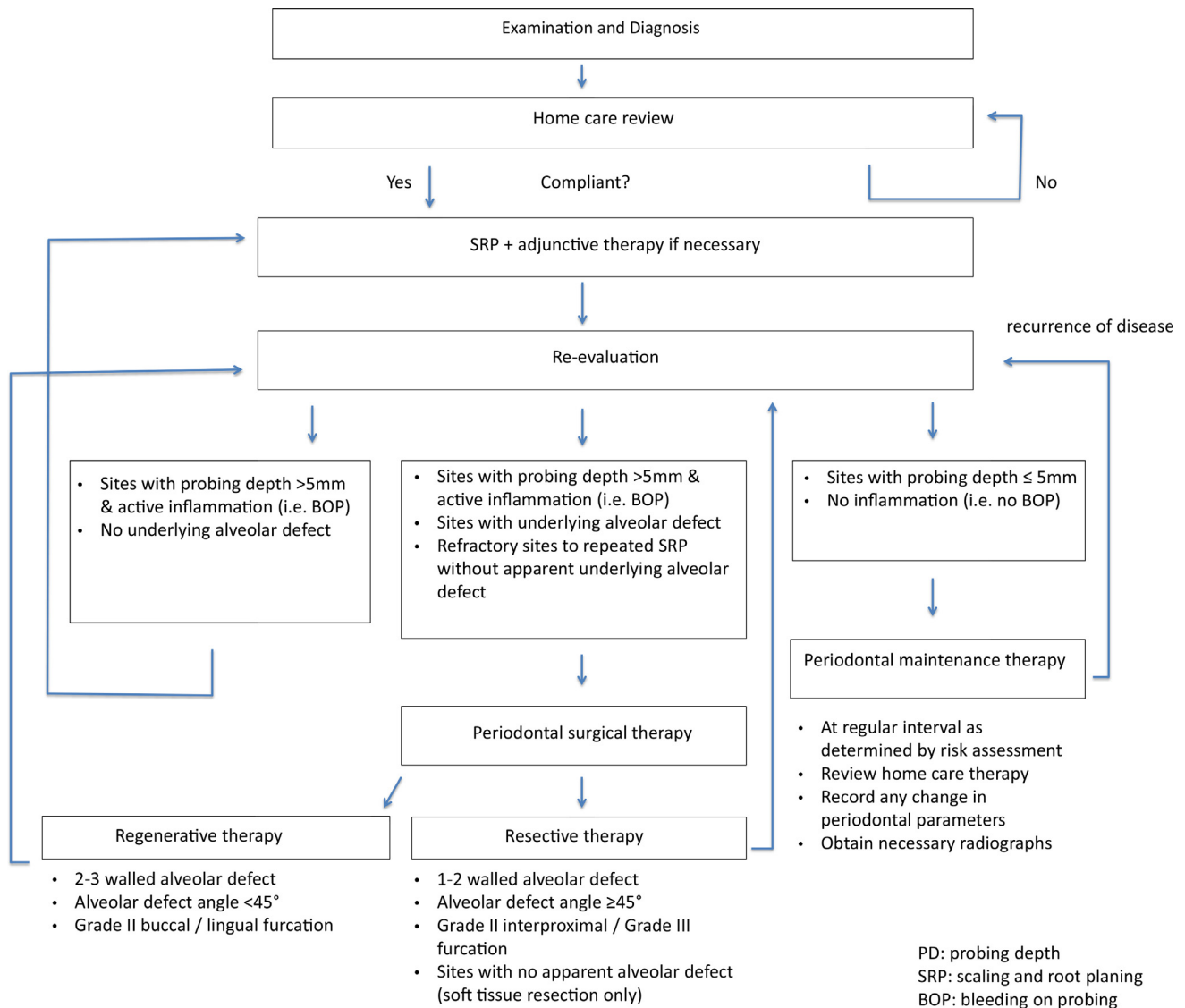


Fig. 10 – A decision tree for treating a patient with periodontitis.

periodontal maintenance therapy and long-term follow-up are also crucial to the success of the treatment and long-term retention of teeth.

REFERENCES

1. Slots J. Periodontitis: facts, fallacies and the future. *Periodontol* 2000 2017;75:7–23.
2. Papapanou PN, Sanz M, Buduneli N, et al. Periodontitis: consensus report of workgroup 2 of the 2017 World Workshop on the Classification of Periodontal and Peri-Implant Diseases and Conditions. *J Periodontol* 2018;89(Suppl 1):S173–82.
3. Page RC, Offenbacher S, Schroeder HE, et al. Advances in the pathogenesis of periodontitis: summary of developments, clinical implications and future directions. *Periodontol* 2000 1997;14:216–48.
4. Page RC, Eke PI. Case definitions for use in population-based surveillance of periodontitis. *J Periodontol* 2007;78(7 Suppl):1387–99.
5. Brunsvold MA. Pathologic tooth migration. *J Periodontol* 2005;76:859–66.
6. Eke PI, Thornton-Evans GO, Wei L, et al. Periodontitis in US Adults: National Health and Nutrition Examination Survey 2009–2014. *J Am Dent Assoc* 2018;149 576–588.e6.
7. Richards D. Review finds that severe periodontitis affects 11% of the world population. *Evid Based Dent* 2014;15:70–1.
8. Kassebaum NJ, Bernabe E, Dahiya M, et al. Global burden of severe periodontitis in 1990–2010: a systematic review and meta-regression. *J Dent Res* 2014;93:1045–53.
9. Frencken JE, Sharma P, Stenhouse L, et al. Global epidemiology of dental caries and severe periodontitis - a comprehensive review. *J Clin Periodontol* 2017;44(Suppl 18):S94–S105.
10. International Diabetes Federation. Global diabetes data report 2010–2045. Available from: <https://diabetesatlas.org/data/>. Accessed May 9, 2020.

11. World Health Organization. WHO fact sheet on hypertension. Available from: <https://www.who.int/news-room/factsheets/detail/hypertension>. Accessed May 9, 2020.
12. World Health Organization. WHO fact sheet on depression. Available from: <https://www.who.int/news-room/factsheets/detail/depression>. Accessed May 9, 2020.
13. World Health Organization. WHO factsheet on asthma. Available from: <https://www.who.int/news-room/factsheets/detail/asthma>. Accessed May 9, 2020.
14. Beck JD, Papapanou PN, Phillips KH, et al. Periodontal medicine: 100 years of progress. *J Dent Res* 2019;98:1053–62.
15. Borges T de F, Regalo SC, Taba Jr M, et al. Changes in masticatory performance and quality of life in individuals with chronic periodontitis. *J Periodontol* 2013;84:325–31.
16. Graziani F, Music L, Bozic D, et al. Is periodontitis and its treatment capable of changing the quality of life of a patient? *Br Dent J* 2019;227:621–5.
17. Socransky SS, Haffajee AD, Cugini MA, et al. Microbial complexes in subgingival plaque. *J Clin Periodontol* 1998;25:134–44.
18. Socransky SS, Haffajee AD. Periodontal microbial ecology. *Periodontol* 2000 2005;38:135–87.
19. Haffajee AD, Socransky SS. Microbial etiological agents of destructive periodontal diseases. *Periodontol* 2000 1994;5:78–111.
20. Mohanty R, Asopa SJ, Joseph MD, et al. Red complex: polymicrobial conglomerate in oral flora: a review. *J Family Med Prim Care* 2019;8:3480–6.
21. Mysak J, Podzimek S, Sommerova P, et al. *Porphyromonas gingivalis*: major periodontopathic pathogen overview. *J Immunol Res* 2014;2014:476068.
22. Singhrao SK, Harding A, Poole S, et al. *Porphyromonas gingivalis* periodontal infection and its putative links with Alzheimer's disease. *Mediators Inflamm* 2015;2015:137357.
23. Sharma A. Virulence mechanisms of *Tannerella forsythia*. *Periodontol* 2000 2010;54:106–16.
24. Dashper SG, Seers CA, Tan KH, et al. Virulence factors of the oral spirochete *Treponema denticola*. *J Dent Res* 2011;90:691–703.
25. Birkedal-Hansen H. Role of matrix metalloproteinases in human periodontal diseases. *J Periodontol* 1993;64(Suppl 5S):474–84.
26. Taubman MA, Kawai T. Involvement of T-lymphocytes in periodontal disease and in direct and indirect induction of bone resorption. *Crit Rev Oral Biol Med* 2001;12:125–35.
27. Taubman MA, Valverde P, Han X, et al. Immune response: the key to bone resorption in periodontal disease. *J Periodontol* 2005;76(11 Suppl):2033–41.
28. Socransky SS, Haffajee AD, Goodson JM, et al. New concepts of destructive periodontal disease. *J Clin Periodontol* 1984;11:21–32.
29. Løe H, Anerud A, Boysen H, et al. Natural history of periodontal disease in man. Rapid, moderate and no loss of attachment in Sri Lankan laborers 14 to 46 years of age. *J Clin Periodontol* 1986;13:431–45.
30. Haffajee AD, Socransky SS. Attachment level changes in destructive periodontal diseases. *J Clin Periodontol* 1986;13:461–75.
31. Goodson JM, Tanner AC, Haffajee AD, et al. Patterns of progression and regression of advanced destructive periodontal disease. *J Clin Periodontol* 1982;9:472–81.
32. Camelo-Castillo AJ, Mira A, Pico A, et al. Subgingival microbiota in health compared to periodontitis and the influence of smoking. *Front Microbiol* 2015;6:119.
33. Haffajee AD, Socransky SS. Relationship of cigarette smoking to the subgingival microbiota. *J Clin Periodontol* 2001;28:377–88.
34. Chigasaki O, Takeuchi Y, Aoki A, et al. A cross-sectional study on the periodontal status and prevalence of red complex periodontal pathogens in a Japanese population. *J Oral Sci* 2018;60:293–303.
35. Persson L, Bergström J, Ito H, et al. Tobacco smoking and neutrophil activity in patients with periodontal disease. *J Periodontol* 2001;72:90–5.
36. Shivanaikar SS, Faizuddin M, Bhat K. Effect of smoking on neutrophil apoptosis in chronic periodontitis: an immunohistochemical study. *Indian J Dent Res* 2013;24:147.
37. White PC, Hirschfeld J, Milward MR, et al. Cigarette smoke modifies neutrophil chemotaxis, neutrophil extracellular trap formation and inflammatory response-related gene expression. *J Periodontol Res* 2018;53:525–35.
38. Grossi SG, Zambon JJ, Ho AW, et al. Assessment of risk for periodontal disease. I. Risk indicators for attachment loss. *J Periodontol* 1994;65:260–7.
39. Nociti FH, Casati MZ, Duarte PM. Current perspective of the impact of smoking on the progression and treatment of periodontitis. *Periodontol* 2000 2015;67:187–210.
40. Müller Campanile V, Megally A, Campanile G, et al. Risk factors for recurrence of periodontal disease in patients in maintenance care in a private practice. *J Clin Periodontol* 2019;46:918–26.
41. Ryder MI, Couch ET, Chaffee BW. Personalized periodontal treatment for the tobacco- and alcohol-using patient. *Periodontol* 2000 2018;78:30–46.
42. Emrich LJ, Shlossman M, Genco RJ. Periodontal disease in non-insulin-dependent diabetes mellitus. *J Periodontol* 1991;62:123–31.
43. Mealey BL, Oates TW. Diabetes mellitus and periodontal diseases. *J Periodontol* 2006;77:1289–303.
44. Schmidt AM, Weidman E, Lalla E, et al. Advanced glycation endproducts (AGEs) induce oxidant stress in the gingiva: a potential mechanism underlying accelerated periodontal disease associated with diabetes. *J Periodontol Res* 1996;31:508–15.
45. Lalla E, Lamster IB, Schmidt AM. Enhanced interaction of advanced glycation end products with their cellular receptor RAGE: implications for the pathogenesis of accelerated periodontal disease in diabetes. *Ann Periodontol* 1998;3:13–9.
46. Lalla E, Lamster IB, Drury S, et al. Hyperglycemia, glycoxidation and receptor for advanced glycation endproducts: potential mechanisms underlying diabetic complications, including diabetes-associated periodontitis. *Periodontol* 2000 2000;23:50–62.
47. Lalla E, Lamster IB, Stern DM, et al. Receptor for advanced glycation end products, inflammation, and accelerated periodontal disease in diabetes: mechanisms and insights into therapeutic modalities. *Ann Periodontol* 2001;6:113–8.
48. Lamster IB, Cheng B, Burkett S, et al. Periodontal findings in individuals with newly identified pre-diabetes or diabetes mellitus. *J Clin Periodontol* 2014;41:1055–60.
49. Jeffcoat MK, Howell TH. Alveolar bone destruction due to overhanging amalgam in periodontal disease. *J Periodontol* 1980;51:599–602.
50. Jansson L, Ehnevid H, Lindskog S, et al. Proximal restorations and periodontal status. *J Clin Periodontol* 1994;21:577–82.
51. Koral SM, Howell TH, Jeffcoat MK. Alveolar bone loss due to open interproximal contacts in periodontal disease. *J Periodontol* 1981;52:447–50.
52. Glickman I, Smulow JB. Effect of excessive occlusal forces upon the pathway of gingival inflammation in humans. *J Periodontol* 1965;36:141–7.
53. Ericsson I, Lindhe J. Effect of longstanding jiggling on experimental marginal periodontitis in the beagle dog. *J Clin Periodontol* 1982;9:497–503.

54. Andereggs CR, Metzler DG. Tooth mobility revisited. *J Periodontol* 2001;72:963–7.
55. Lang NP, Löe H. The relationship between the width of keratinized gingiva and gingival health. *J Periodontol* 1972;43:623–7.
56. Leknes KN, Lie T, Selvig KA. Cemental tear: a risk factor in periodontal attachment loss. *J Periodontol* 1996;67:583–8.
57. Bower RC. Furcation morphology relative to periodontal treatment: furcation root surface anatomy. *J Periodontol* 1979;50:366–74.
58. Moskow BS, Canut PM. Studies on root enamel (2). Enamel pearls. A review of their morphology, localization, nomenclature, occurrence, classification, histogenesis and incidence. *J Clin Periodontol* 1990;17:275–81.
59. Romeo U, Palaia G, Botti R, et al. Enamel pearls as a predisposing factor to localized periodontitis. *Quintessence Int* 2011;42:69–71.
60. DeSanctis M, Murphy KG. The role of resective periodontal surgery in the treatment of furcation defects. *Periodontol* 2000;22:154–68.
61. Richman C. Is gingival recession a consequence of an orthodontic tooth size and/or tooth position discrepancy? “A paradigm shift. *Compend Contin Educ Dent* 2011;32:e73–9.
62. Kassab MM, Cohen RE. The etiology and prevalence of gingival recession. *J Am Dent Assoc* 2003;134:220–5.
63. Kwon T, Levin L. Cause-related therapy: a review and suggested guidelines. *Quintessence Int* 2014;45:585–91.
64. Kwon T, Salem DM, Levin L. Nonsurgical periodontal therapy based on the principles of cause-related therapy: rationale and case series. *Quintessence Int* 2019;50:370–6.
65. Kwon T, Kim DM, Levin L. Successful nonsurgical management of post-orthodontic gingival enlargement with intensive cause-related periodontal therapy. *N Y State Dent J* 2015;81:21–3.
66. Kwon T, Wang JCW, Levin L. Home care is therapeutic. Should we use the term “Home-care Therapy” Instead of “Instructions”? *Oral Health Prev Dent* 2020;18:397–8.
67. Oosterwaal PJ, Matee MI, Mikx FH, et al. The effect of subgingival debridement with hand and ultrasonic instruments on the subgingival microflora. *J Clin Periodontol* 1987;14:528–33.
68. Matia JI, Bissada NF, Maybury JE, et al. Efficiency of scaling of the molar furcation area with and without surgical access. *Int J Periodontics Restorative Dent* 1986;6:24–35.
69. Winkel EG, Van Winkelhoff AJ, Timmerman MF, et al. Amoxicillin plus metronidazole in the treatment of adult periodontitis patients. A double-blind placebo-controlled study. *J Clin Periodontol* 2001;28:296–305.
70. Haffajee AD, Socransky SS, Gunsolley JC. Systemic anti-infective periodontal therapy. A systematic review. *Ann Periodontol* 2003;8:115–81.
71. Liaw A, Miller C, Nimmo A. Comparing the periodontal tissue response to non-surgical scaling and root planing alone, adjunctive azithromycin, or adjunctive amoxicillin plus metronidazole in generalized chronic moderate-to-severe periodontitis: a preliminary randomized controlled trial. *Aust Dent J* 2019;64:145–52.
72. Borges I, Favari M, Figueiredo LC, et al. Different antibiotic protocols in the treatment of severe chronic periodontitis: a 1-year randomized trial. *J Clin Periodontol* 2017;44:822–32.
73. McGowan K, McGowan T, Ivanovski S. Optimal dose and duration of amoxicillin-plus-metronidazole as an adjunct to non-surgical periodontal therapy: a systematic review and meta-analysis of randomized, placebo-controlled trials. *J Clin Periodontol* 2018;45:56–67.
74. Zandbergen D, Slot DE, Niederman R, et al. The concomitant administration of systemic amoxicillin and metronidazole compared to scaling and root planing alone in treating periodontitis: =a systematic review=. *BMC Oral Health* 2016;16:27.
75. Nibali L, Koidou VP, Hamborg T, et al. Empirical or microbiologically guided systemic antimicrobials as adjuncts to non-surgical periodontal therapy? A systematic review. *J Clin Periodontol* 2019;46:999–1012.
76. Teughels W, Feres M, Oud V, et al. Adjunctive effect of systemic antimicrobials in periodontitis therapy: a systematic review and meta-analysis. *J Clin Periodontol* 2020;47(Suppl 22):257–81.
77. Bland PS, Goodson JM, Gunsolley JC, et al. Association of antimicrobial and clinical efficacy: periodontitis therapy with minocycline microspheres. *J Int Acad Periodontol* 2010;12:11–9.
78. Williams RC, Paquette DW, Offenbacher S, et al. Treatment of periodontitis by local administration of minocycline microspheres: a controlled trial. *J Periodontol* 2001;72:1535–44.
79. Grossi SG, Goodson JM, Gunsolley JC, et al. Mechanical therapy with adjunctive minocycline microspheres reduces red-complex bacteria in smokers. *J Periodontol* 2007;78:1741–50.
80. Matesanz-Pérez P, García-Gargallo M, Figuero E, et al. A systematic review on the effects of local antimicrobials as adjuncts to subgingival debridement, compared with subgingival debridement alone, in the treatment of chronic periodontitis. *J Clin Periodontol* 2013;40:227–41.
81. Machtei EE, Hirsh I, Falah M, et al. Multiple applications of flurbiprofen and chlorhexidine chips in patients with chronic periodontitis: a randomized, double blind, parallel, 2-arms clinical trial. *J Clin Periodontol* 2011;38:1037–43.
82. Lecic J, Cacic S, Janjic Pavlovic O, et al. Different methods for subgingival application of chlorhexidine in the treatment of patients with chronic periodontitis. *Acta Odontol Scand* 2016;74:502–7.
83. Caton JG, Ciancio SG, Blieden TM, et al. Treatment with subantimicrobial dose doxycycline improves the efficacy of scaling and root planing in patients with adult periodontitis. *J Periodontol* 2000;71:521–32.
84. Caton JG, Ciancio SG, Blieden TM, et al. Subantimicrobial dose doxycycline as an adjunct to scaling and root planing: post-treatment effects. *J Clin Periodontol* 2001;28:782–9.
85. El-Sharkawy H, Aboelsaad N, Eliwa M, et al. Adjunctive treatment of chronic periodontitis with daily dietary supplementation with omega-3 Fatty acids and low-dose aspirin. *J Periodontol* 2010;81:1635–43.
86. Castro Dos Santos NC, Andere NM, Araujo CF, et al. Omega-3 PUFA and aspirin as adjuncts to periodontal debridement in patients with periodontitis and type 2 diabetes mellitus: randomized clinical trial [published online ahead of print Feb 26, 2020]. *J Periodontol* 2020. doi: 10.1002/JPER.19-0613.
87. Botero JE, Yepes FL, Ochoa SP, et al. Effects of periodontal non-surgical therapy plus azithromycin on glycemic control in patients with diabetes: a randomized clinical trial. *J Periodontol Res* 2013;48:706–12.
88. Haas AN, Seleme F, Segatto P, et al. Azithromycin as an adjunctive treatment of aggressive periodontitis: radiographic findings of a 12-month randomized clinical trial. *Am J Dent* 2012;25:215–9.
89. Mascarenhas P, Gapski R, Al-Shammari K, et al. Clinical response of azithromycin as an adjunct to non-surgical periodontal therapy in smokers. *J Periodontol* 2005;76:426–36.
90. O'Rourke VJ. Azithromycin as an adjunct to non-surgical periodontal therapy: a systematic review. *Aust Dent J* 2017;62:14–22.
91. Oliveira AMSD, Costa FO, Nogueira LMR, et al. Azithromycin and full-mouth scaling for the treatment of generalized stage III and IV periodontitis: a 6-month randomized comparative clinical trial. *Braz Dent J* 2019;30:429–36.

92. Baltacıoğlu E, Aslan M, Saraç Ö, et al. Analysis of clinical results of systemic antimicrobials combined with nonsurgical periodontal treatment for generalized aggressive periodontitis: a pilot study. *J Can Dent Assoc* 2011;77:b97.
93. Machtei EE, Younis MN. The use of 2 antibiotic regimens in aggressive periodontitis: comparison of changes in clinical parameters and gingival crevicular fluid biomarkers. *Quintessence Int* 2008;39:811–9.
94. Akincibay H, Orsal SO, Sengün D, et al. Systemic administration of doxycycline versus metronidazole plus amoxicillin in the treatment of localized aggressive periodontitis: a clinical and microbiologic study. *Quintessence Int* 2008;39:e33–9.
95. Salvi GE, Stahli A, Schmidt JC, et al. Adjunctive laser or antimicrobial photodynamic therapy to non-surgical mechanical instrumentation in patients with untreated periodontitis: a systematic review and meta-analysis. *J Clin Periodontol* 2020;47:176–98.
96. Roncati M, Gariffo A. Systematic review of the adjunctive use of diode and Nd:YAG lasers for nonsurgical periodontal instrumentation. *Photomed Laser Surg* 2014;32:186–97.
97. Sgolastra F, Severino M, Gatto R, et al. Effectiveness of diode laser as adjunctive therapy to scaling root planning in the treatment of chronic periodontitis: a meta-analysis. *Lasers Med Sci* 2013;28:1393–402.
98. Invernici MM, Salvador SL, Silva PHF, et al. Effects of Bifidobacterium probiotic on the treatment of chronic periodontitis: a randomized clinical trial. *J Clin Periodontol* 2018;45:1198–210.
99. Ikram S, Hassan N, Raffat MA, et al. Systematic review and meta-analysis of double-blind, placebo-controlled, randomized clinical trials using probiotics in chronic periodontitis. *J Investig Clin Dent* 2018;9:e12338.
100. de Andrade DP, Carvalho ICS, Gadoi BH, et al. Subgingival irrigation with a solution of 20% propolis extract as an adjunct to non-surgical periodontal treatment: a preliminary study. *J Int Acad Periodontol* 2017;19:145–51.
101. El-Sharkawy HM, Anees MM, Van Dyke TE. Propolis improves periodontal status and glycemic control in patients with type 2 diabetes mellitus and chronic periodontitis: a randomized clinical trial. *J Periodontol* 2016;87:1418–26.
102. Zhao H, Hu J, Zhao L. Adjunctive subgingival application of Chlorhexidine gel in nonsurgical periodontal treatment for chronic periodontitis: a systematic review and meta-analysis. *BMC Oral Health* 2020;20:34.
103. Sanz M, Herrera D, Kerschull M, et al. Treatment of stage I-III periodontitis-The EFP S3 level clinical practice guideline. *J Clin Periodontol* 2020;47(Suppl 22):4–60.
104. Rabbani GM, Ash MM, Caffesse RG. The effectiveness of subgingival scaling and root planing in calculus removal. *J Periodontol* 1981;52:119–23.
105. Stambaugh RV, Dragoo M, Smith DM, et al. The limits of subgingival scaling. *Int J Periodontics Restorative Dent* 1981;1:30–41.
106. Steffensen B, Webert HP. Relationship between the radiographic periodontal defect angle and healing after treatment. *J Periodontol* 1989;60:248–54.
107. Papananou PN, Wennström JL. The angular bony defect as indicator of further alveolar bone loss. *J Clin Periodontol* 1991;18:317–22.
108. Schluger S. Osseous resection; a basic principle in periodontal surgery. *Oral Surg Oral Med Oral Pathol* 1949;2:316–25.
109. Froum SJ, Coran M, Thaller B, et al. Periodontal healing following open debridement flap procedures. I. Clinical assessment of soft tissue and osseous repair. *J Periodontol* 1982;53:8–14.
110. Stahl SS, Froum SJ, Kushner L. Periodontal healing following open debridement flap procedures. II. Histologic observations. *J Periodontol* 1982;53:15–21.
111. Stahl SS, Froum SJ, Kushner L. Healing responses of human intraosseous lesions following the use of debridement, grafting and citric acid root treatment. II. Clinical and histologic observations: one year postsurgery. *J Periodontol* 1983;54:325–38.
112. Yukna RA, Bowers GM, Lawrence JJ, et al. A clinical study of healing in humans following the excisional new attachment procedure. *J Periodontol* 1976;47:696–700.
113. Ramfjord SP, Nissle RR. The modified widman flap. *J Periodontol* 1974;45:601–7.
114. Ramfjord SP, Knowles JW, Nissle RR, et al. Results following three modalities of periodontal therapy. *J Periodontol* 1975;46:522–6.
115. Carnevale G, Kaldahl WB. Osseous resective surgery. *Periodontol* 2000 2000;22:59–87.
116. Canakçi CF, Canakçi V. Pain experienced by patients undergoing different periodontal therapies. *J Am Dent Assoc* 2007;138:1563–73.
117. Clark D, Levin L. Non-surgical management of tooth hypersensitivity. *Int Dent J* 2016;66:249–56.
118. Feller L, Lemmer J. Tooth mobility after periodontal surgery. *SADJ* 2004;59:409–11.
119. Checchi L, Montevecchi M, Checchi V, et al. A modified papilla preservation technique, 22 years later. *Quintessence Int* 2009;40:303–11.
120. Villar CC, Cochran DL. Regeneration of periodontal tissues: guided tissue regeneration. *Dent Clin North Am* 2010;54:73–92.
121. Chavda S, Levin L. Human studies of vertical and horizontal alveolar ridge augmentation comparing different types of bone graft materials: a systematic review. *J Oral Implantol* 2018;44:74–84.
122. Cortellini P, Pini Prato G, Tonetti MS. Periodontal regeneration of human infrabony defects. I. Clinical measures. *J Periodontol* 1993;64:254–60.
123. Cortellini P, Pini Prato G, Tonetti MS. Periodontal regeneration of human infrabony defects. II. Re-entry procedures and bone measures. *J Periodontol* 1993;64:261–8.
124. Tonetti MS, Pini Prato G, Williams RC, et al. Periodontal regeneration of human infrabony defects. III. Diagnostic strategies to detect bone gain. *J Periodontol* 1993;64:269–77.
125. Tonetti MS, Pini-Prato G, Cortellini P. Periodontal regeneration of human intrabony defects. IV. Determinants of healing response. *J Periodontol* 1993;64:934–40.
126. Reynolds MA, Kao RT, Camargo PM, et al. Periodontal regeneration - intrabony defects: a consensus report from the AAP Regeneration Workshop. *J Periodontol* 2015;86(2 Suppl):S105–7.
127. Nevins M, Camelo M, Nevins ML, et al. Periodontal regeneration in humans using recombinant human platelet-derived growth factor-BB (rhPDGF-BB) and allogenic bone. *J Periodontol* 2003;74:1282–92.
128. Camelo M, Nevins ML, Schenk RK, et al. Periodontal regeneration in human Class II furcations using purified recombinant human platelet-derived growth factor-BB (rhPDGF-BB) with bone allograft. *Int J Periodontics Restorative Dent* 2003;23:213–25.
129. Khoshkam V, Chan H-L, Lin G-H, et al. Outcomes of regenerative treatment with rhPDGF-BB and rhFGF-2 for periodontal intra-bony defects: a systematic review and meta-analysis. *J Clin Periodontol* 2015;42:272–80.
130. Miron RJ, Chandad F, Buser D, et al. Effect of enamel matrix derivative liquid on osteoblast and periodontal ligament cell proliferation and differentiation. *J Periodontol* 2016;87:91–9.
131. Miron RJ, Bosshardt DD, Laugisch O, et al. In vitro evaluation of demineralized freeze-dried bone allograft in

- combination with enamel matrix derivative. *J Periodontol* 2013;84:1646–54.
132. Koop R, Merheb J, Quirynen M. Periodontal regeneration with enamel matrix derivative in reconstructive periodontal therapy: a systematic review. *J Periodontol* 2012; 83:707–20.
 133. Nevins M, Kim S-W, Camelo M, et al. A prospective 9-month human clinical evaluation of Laser-Assisted New Attachment Procedure (LANAP) therapy. *Int J Periodontics Restorative Dent* 2014;34:21–7.
 134. Nevins ML, Camelo M, Schupbach P, et al. Human clinical and histologic evaluation of laser-assisted new attachment procedure. *Int J Periodontics Restorative Dent* 2012;32: 497–507.
 135. Mills MP, Rosen PS, Chambrone L, et al. American Academy of Periodontology best evidence consensus statement on the efficacy of laser therapy used alone or as an adjunct to non-surgical and surgical treatment of periodontitis and peri-implant diseases. *J Periodontol* 2018;89:737–42.
 136. Cohen RE. Research, Science and Therapy Committee, American Academy of Periodontology. Position paper: periodontal maintenance. *J Periodontol* 2003;74:1395–401.
 137. Surveillance Report 2018 – Dental Checks. Intervals between Oral Health Reviews (2004) NICE Guideline CG19. London: National Institute for Health and Care Excellence (UK). Available from: <http://www.ncbi.nlm.nih.gov/books/NBK551810/>. Accessed January 4, 2020.
 138. Wilson TG, Glover ME, Malik AK, et al. Tooth loss in maintenance patients in a private periodontal practice. *J Periodontol* 1987;58:231–5.
 139. Wang H-L, Greenwell H, Fiorellini J, et al. Periodontal regeneration. *J Periodontol* 2005;76:1601–22.
 140. Atieh MA, Alsabeeha NHM, Faggion CM, et al. The frequency of peri-implant diseases: a systematic review and meta-analysis. *J Periodontol* 2013;84:1586–98.
 141. Levin L, Ofec R, Grossmann Y, et al. Periodontal disease as a risk for dental implant failure over time: a long-term historical cohort study. *J Clin Periodontol* 2011;38:732–7.
 142. Ferreira SD, Silva GLM, Cortelli JR, et al. Prevalence and risk variables for peri-implant disease in Brazilian subjects. *J Clin Periodontol* 2006;33:929–35.
 143. Renvert S, Aghazadeh A, Hallström H, et al. Factors related to peri-implantitis - a retrospective study. *Clin Oral Implants Res* 2014;25:522–9.
 144. Swierkot K, Lottholz P, Flores-de-Jacoby L, et al. Mucositis, peri-implantitis, implant success, and survival of implants in patients with treated generalized aggressive periodontitis: 3- to 16-year results of a prospective long-term cohort study. *J Periodontol* 2012;83:1213–25.
 145. Cho-Yan Lee J, Mattheos N, Nixon KC, et al. Residual periodontal pockets are a risk indicator for peri-implantitis in patients treated for periodontitis. *Clin Oral Implants Res* 2012;23:325–33.
 146. Kwon T, Bain PA, Levin L. Systematic review of short- (5–10 years) and long-term (10 years or more) survival and success of full-arch fixed dental hybrid prostheses and supporting implants. *J Dent* 2014;42:1228–41.
 147. Clark D, Levin L. In the dental implant era, why do we still bother saving teeth? *Dent Traumatol* 2019;35:368–75.
 148. Monsarrat P, Blaizot A, Kémoun P, et al. Clinical research activity in periodontal medicine: a systematic mapping of trial registers. *J Clin Periodontol* 2016;43:390–400.
 149. Williams RC, Offenbacher S. Periodontal medicine: the emergence of a new branch of periodontology. *Periodontol* 2000 2000;23:9–12.
 150. Sanz M, Ceriello A, Buysschaert M, et al. Scientific evidence on the links between periodontal diseases and diabetes: consensus report and guidelines of the joint workshop on periodontal diseases and diabetes by the International Diabetes Federation and the European Federation of Periodontology. *J Clin Periodontol* 2018;45:138–49.
 151. Lamster IB, Pagan M. Periodontal disease and the metabolic syndrome. *Int Dent J* 2017;67:67–77.
 152. Beck JD, Slade G, Offenbacher S. Oral disease, cardiovascular disease and systemic inflammation. *Periodontol* 2000 2000; 23:110–20.