

Diagnostic Needle Arthroscopy and Partial Medial Meniscectomy Using Small Bore Needle Arthroscopy



Ryan Quinn, M.S., Sarah D. Lang, M.Ed., A.T.C., O.T.C., and Brian B. Gilmer, M.D.

Abstract: As resolution and image quality improve, several potential advantages make needle arthroscopy (NA) appealing for broader therapeutic applications in the operating room. The smaller camera size and weight allow for a minimally invasive approach with smaller incisions than standard arthroscopy and decreased arthroscopic fluid use. Differences in the technology, such as a 0-degree optic and less rigid instrumentation necessitate a novel technique to accommodate thorough diagnostic arthroscopy as well as new approaches to therapeutic procedures. This manuscript introduces our preferred approach to diagnostic arthroscopy and partial medial meniscectomy with NA and small-bore instruments. The minimally invasive nature of this technology may decrease postoperative pain and improve return of comfort and function.

Diagnostic needle arthroscopy (NA) has been gaining popularity as a cost-effective alternative to magnetic resonance imaging.¹⁻⁵ Typically, NA is used as an in-office, diagnostic procedure.^{6,7} As resolution and image quality improve, however, several potential advantages make NA appealing for broader therapeutic applications in the operating room.

The smaller camera size (2 mm) and weight allow for a minimally invasive approach with smaller incisions than standard arthroscopy. The smaller camera sheath results in decreased arthroscopy fluid use, which may reduce postoperative swelling.

The size of NA instruments makes them inherently more malleable than standard arthroscopic equipment; therefore, they cannot tolerate gross movements that may result in bending the instruments. Furthermore,

NA uses a 0-degree view, which may be unfamiliar to many surgeons. These differences in the technology necessitate novel technique to accommodate thorough diagnostic arthroscopy as well as new approaches to therapeutic procedures. This manuscript and video will introduce our preferred approach to diagnostic arthroscopy and partial medial meniscectomy with NA and small-bore instruments.

Surgical Technique

Patient Positioning, Equipment, and Setup

The patient is positioned supine on the operative table with a lateral post 2 finger breadths above the superior pole of the patella. A well-padded tourniquet is applied and an impervious stockinette is applied to the leg distal to the tibial tuberosity. The patient positioning and preparation is the same as with standard arthroscopy. An examination under anesthesia is recommended to evaluate for patellar stability, range of motion, and ligamentous stability.

The NA set (Nanoscope, Arthrex, Naples, FL) includes a 0-degree arthroscope with power cord, monitor, sharp and blunt trochars with corresponding sheaths including inflow portals, and assorted instruments including a retractable probe, meniscal biters, and a 2.0-mm shaver (Fig 1). Using sterile technique, the cords are attached and the monitor can be relayed to overhead monitors in the operating theater via a standard HDMI cable. After marking portal sites and anatomic landmarks, including the inferior pole of the patella and the medial and lateral borders of the patellar tendon,

From the Mammoth Orthopedic Institute, Mammoth Hospital, Mammoth Lakes, California, U.S.A.

The authors report the following potential conflicts of interest or sources of funding: B.G. reports personal fees (consultant and institutional support) from Arthrex; institutional support from Pacific Medical, Stryker, and Synthes; research support from Smart Medical Devices; and holds stock in ROM3, outside the submitted work. Full ICMJE author disclosure forms are available for this article online, as [supplementary material](#).

Received October 15, 2019; accepted January 14, 2020.

Address correspondence to Brian Gilmer, M.D., Mammoth Orthopedic Institute, Mammoth Hospital, 85 Sierra Park Rd. PO Box 660, Mammoth Lakes, CA 93546 U.S.A. E-mail: Brian.Gilmer@mammothhospital.com

© 2020 by the Arthroscopy Association of North America. Published by Elsevier. This is an open access article under the CC BY-NC-ND license (<http://creativecommons.org/licenses/by-nc-nd/4.0/>).

2212-6287/191271

<https://doi.org/10.1016/j.eats.2020.01.018>

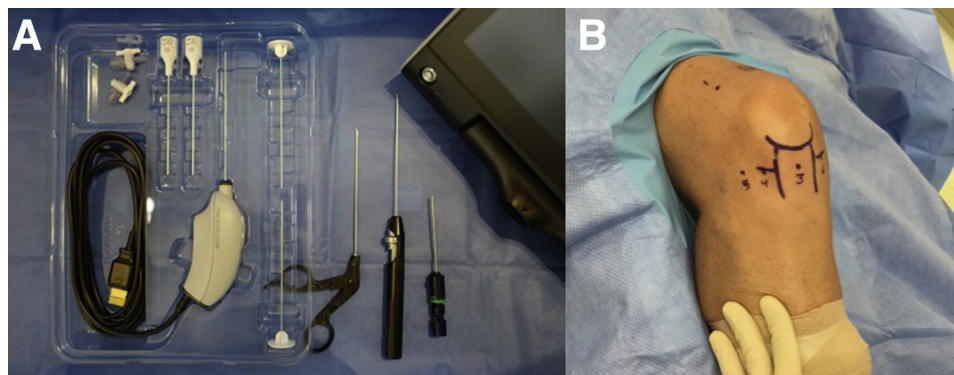


Fig 1. (A) The NA set (Nanoscope, Arthrex Inc) includes a 0° arthroscope with power cord, monitor, sharp and blunt trochars with corresponding sheaths including inflow portals and assorted instruments including a retractable probe, meniscal biters, and a 2.0 mm shaver. (B) Arthroscopic portals are indicated from a lateral external view of a right knee: 1, superior lateral portal; 2, superior medial portal (not visible); 3, medial portal; 4, lateral portal; 5, far lateral portal; 6, medial portal; and 7, far lateral (not visible).

the tourniquet is inflated in preparation for diagnostic arthroscopy.

Suprapatellar Pouch, Patella, Trochlea, Medial and Lateral Gutters

Diagnostic arthroscopy begins with the lateral post down to allow access to the distal femur. Using the sharp trochar, the sheath is introduced into the suprapatellar pouch via a standard anterolateral approach. The inflow fluid pump pressure should be set to 20 mm Hg and the fluid line connected to the camera sheath.

The superior pole of the patella is palpated with 1 hand and the sheath is introduced in a lateral to medial direction to ensure iatrogenic damage to the chondral surface is avoided. The trochar can then be removed, and the stop cock on the camera sheath is then turned to allow gentle insufflation. Allowing a brief pause for insufflation before insertion of the camera is inserted

because the small diameter of the sheath does not allow significant inflow after the camera is inserted.

From this position, the superior aspect of the patella and the trochlea can be visualized. This can be facilitated by lifting the patella with the opposite hand. The camera is then brought alongside the lateral femur to view the lateral gutter and then moved to the medial gutter (Fig 2). The remainder of the trochlea and inferior aspect of the patella will be visualized from distally.

If the medial gutter cannot be adequately visualized, the procedure may be reversed using a superior medial portal as necessary. Alternatively, if loose bodies are present, a small arthroscopic grasper can be used from the superior medial portal.

When visualization of the suprapatellar pouch is satisfactory, the arthroscope and sheath are removed. Alternatively, the sheath may be left in place to provide inflow while the second sheath is used for visualization with the camera in the anterior compartment.

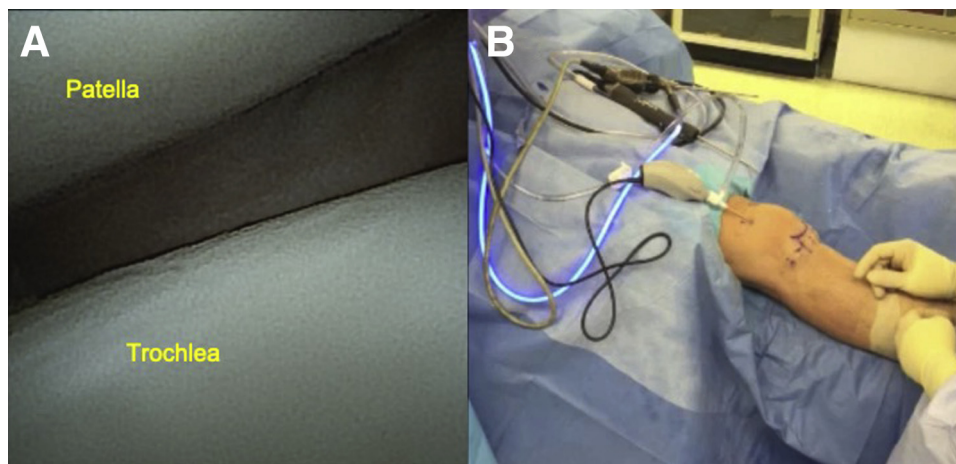
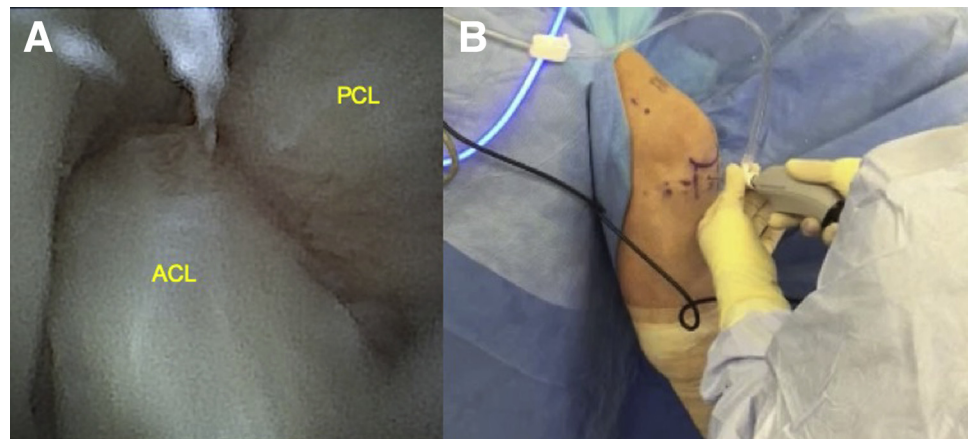


Fig 2. (A) Arthroscopic view, right knee, superior lateral portal, articular surface of the patella, and trochlea. (B) External view depicting camera sheath inserted into superior lateral portal.

Fig 3. (A) Arthroscopic view, right knee, central portal, depicting intercondylar notch including anterior cruciate ligament (ACL) and posterior cruciate ligament (PCL). (B) External view, right knee, depicting needle arthroscope in central (transpatellar) portal while visualizing the intercondylar notch.



Central Portal and Lateral Compartment

The knee is then flexed off the side of the bed to 90°. Three additional portals are planned in addition to standard medial and lateral portals. These are the central (transpatellar tendon) portal, a far medial portal, and a far lateral accessory portal.

The sharp trochar is returned to the sheath and a direct approach is performed through the central portal accessing the intercondylar notch. It is important to enter directly in line to avoid transecting fibers of the patellar tendon with the sharp trochar. Once placed centrally, the trochar is removed and the camera is introduced.

Inflow, if previously removed from the suprapatellar pouch, is resumed by opening the stop cock. The anterior cruciate ligament (ACL) and the posterior cruciate ligament (PCL) are examined (Fig 3).

The camera is then directed laterally and the knee is brought carefully into a figure of 4 position. An 18-gauge spinal needle is used to localize the trajectory for a standard lateral portal entering just superior to the anterior horn of the lateral meniscus. This position is

typically 1 to 2 mm distal to the inferior pole of the patella and 1 to 2 mm lateral to the lateral border of the patellar tendon.

Once optimized, the spinal needle is removed and the trajectory is noted. If therapeutic procedures are required in the lateral compartment, a small skin incision is created to allow access for instrumentation. Spreading of tissues with a blunt snap can facilitate access through the fat pad. If no therapeutic procedure is indicated, the skin may be incised just 2 mm to allow the blunt trochar and second camera sheath to be placed into the lateral compartment directed at the midpoint of the posterior horn of the lateral meniscus. The retractable probe may then be inserted through the sheath to thoroughly examine the posterior horn of the lateral meniscus, the body, and anterior horn of the lateral meniscus. By slowly flexing and extending the knee, the chondral surface of the lateral femoral condyle and the tibial plateau can be examined (Fig 4).

If desired, the posterior lateral knee can be visualized by passing the camera in line just lateral to the ACL and

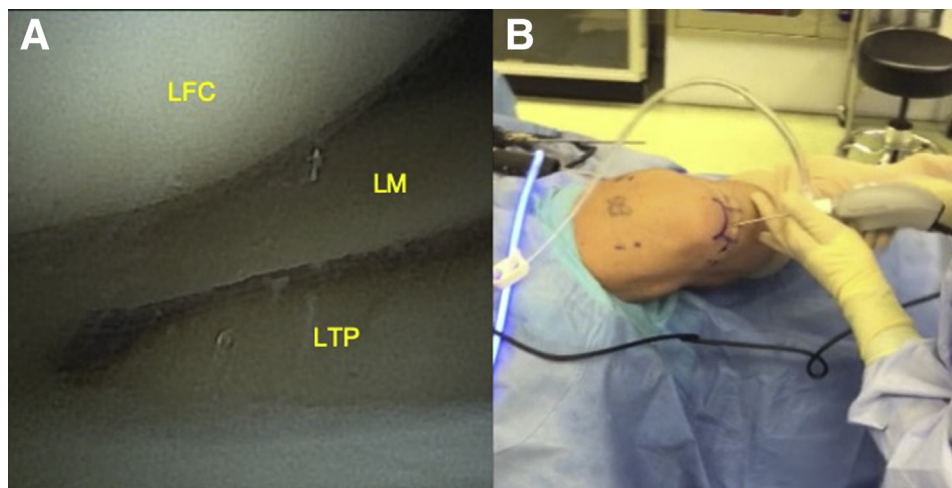


Fig 4. (A) Arthroscopic view, right knee, central portal of the lateral compartment including lateral femoral condyle (LFC), lateral meniscus (LM), and lateral tibial plateau (LTP). (B) External view, right knee, demonstrating the needle arthroscope in the central portal while visualizing the lateral compartment.

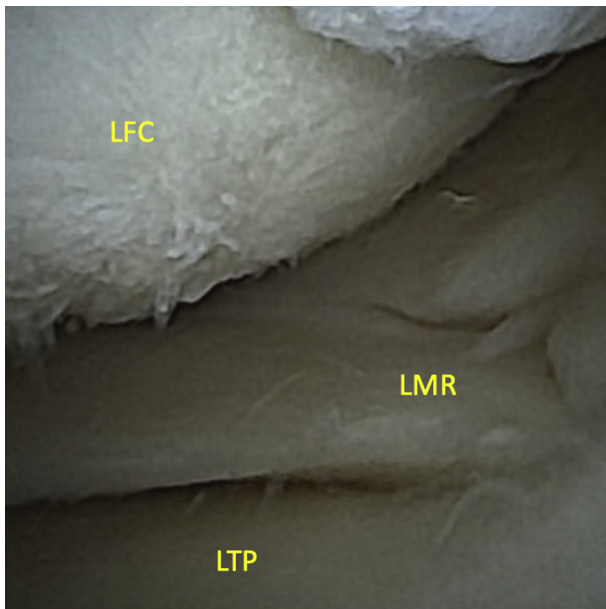


Fig 5. Arthroscopic view, right knee, far lateral portal, visualizing the lateral meniscal root (LMR), lateral femoral condyle (LFC), and lateral tibial plateau (LTP). Because of the 0-degree optic, the far lateral approach provides the best visualization of the lateral meniscal root while allowing the lateral portal to remain available for instrumentation. Externally, the far lateral portal is 3 to 4 mm lateral to the standard anterior lateral portal to obtain this view. The knee is in a figure of four position (knee flexed to 90° and the hip externally rotated).

superior to the lateral meniscal root. If more detailed posterior examination is required, this may be done from a posterolateral approach.

Of importance, the lateral meniscal root cannot be well visualized from the central position because of the 0-degree nature of the optic. Moving the camera from the central cannula to the lateral portal will allow visualization but will not a probing this area. Therefore, a far lateral portal 3 to 4 mm lateral to the lateral portal is first localized with a spinal needle directed toward the meniscal root. The spinal needle is removed and a small 2 mm incision is created. The sheath from the lateral portal can then be moved to the far lateral portal using the blunt trochar. The probe is inserted into the lateral portal and clear visualization and palpation of the meniscal root can be performed (Fig 5).

Notch Examination and Medial Compartment

Returning the camera to the central portal sheath with the probe still in the lateral portal, the knee is gently returned from the figure of 4 position to a neutral position in 90° of flexion. The probe may now be used to thoroughly examine the ACL and PCL. Attention is then turned to the medial compartment.

The camera is directed medially and the knee is brought into valgus with pressure against the lateral post in approximately 30 to 45° of flexion. A spinal needle is used to localize the trajectory for a standard medial portal entering just superior to the anterior horn of the medial meniscus. This position is typically even with the inferior pole of the patella and 1 to 2 mm medial to the medial border of the patellar tendon.

Once optimized, the needle is removed and the trajectory is noted. If therapeutic procedures are required in the medial compartment, a small skin incision is

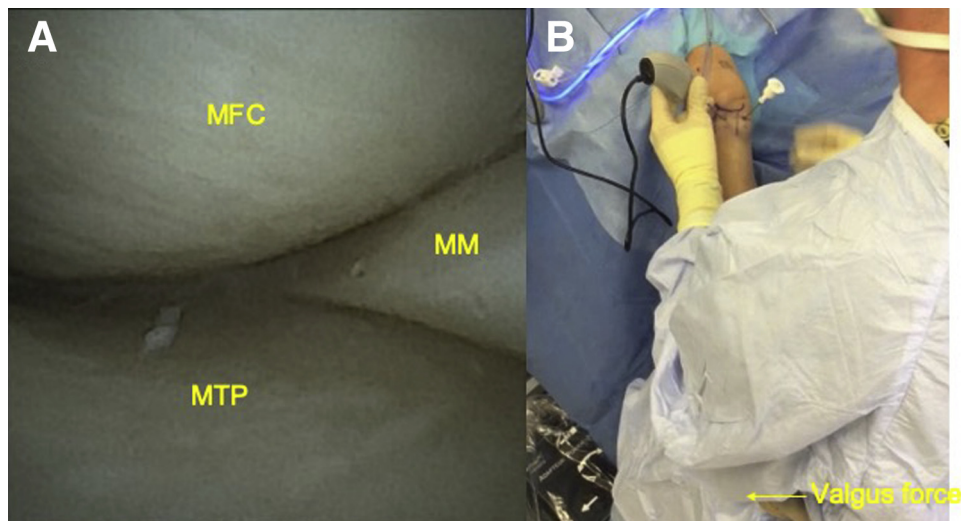


Fig 6. (A) Arthroscopic view, right knee, central portal visualizing the medial compartment including the medial femoral condyle (MFC), medial tibial plateau (MTP), and medial meniscus (MM). (B) External view, right knee, depicting the needle arthroscope in central portal and cannula in the medial portal for visualization of the medial compartment. The camera is directed medially in the central portal sheath and a valgus force is applied from the physician's hip against the lateral post with 30° to 45° of knee flexion to open up the medial knee compartment. A blunt trochar is demonstrated in the medial portal.

Table 1. Portal Utilization for Medial Meniscectomy

	Central	Medial	Far Medial	Lateral	Far Lateral
Posterior horn	Camera	Biter	Shaver		
Body	Camera	Shaver		Biter	
Anterior horn		Shaver		Camera	Biter
Root		Biter/shaver	Camera		

Instrument and camera locations for a partial medial meniscectomy based on location of pathology.

created to allow access for instrumentation. Spreading of tissues with a blunt snap can facilitate access through the fat pad. If no therapeutic procedures are planned in the medial compartment, the skin may be incised just 2 mm to allow the blunt trochar and a second camera sheath to be placed into the medial compartment directed at the midpoint of the posterior horn of the medial meniscus. The retractable probe may then be inserted to examine the posterior horn of the medial meniscus, the body, and anterior horn of the medial meniscus. By slowly flexing and extending the knee the chondral surface of the medial femoral condyle and the tibial plateau can be examined (Fig 6).

Similar to the lateral meniscal root, the medial meniscal root cannot be well visualized from the central position because of the 0° nature of the optic. Moving the camera from the central cannula to the medial portal will allow visualization, but will not allow probing this area, which is critical to identifying occult root tears. Therefore, a far medial portal 3 to 4 mm medial to the standard medial portal is first localized with a spinal needle directed toward the meniscal root. The spinal needle is removed and a small 2 mm incision is created. The sheath from the medial portal can then be moved to the far medial portal using the blunt trochar. The probe is inserted into the medial portal and clear visualization and palpation of the meniscal root can be performed.

If desired, the posterior medial knee can be visualized by passing the camera in line just medial to the PCL and superior to the medial meniscal root. If more detailed posterior examination is required, this may be done from a posteromedial approach. This completes the diagnostic arthroscopy.

Diagnostic arthroscopy with this technique can be safely performed in less than 10 minutes using only 150 mL of arthroscopic fluid.

Partial Medial Meniscectomy

Therapeutic procedures can be performed in a “2-handed” fashion by maintaining the camera in its sheath with the help of an assistant to maintain the camera in place. This frees the surgeon to use both hands for instrumentation. The following example will

illustrate a partial medial meniscectomy performed in this fashion. Because of the need for an inline approach to the pathology, the technique is modified from standard arthroscopic technique.

If the 2 mm meniscal biter and shaver (Arthrex) are used then, no incision larger than 2 mm is required. Cannulas of various lengths (Arthrex) are commercially available to allow easy passage of instruments between working portals if desired. Otherwise, portals may be increased in size and dilated with a hemostat as needed to facilitate instrumentation. In general, it may be beneficial to increase the pump pressure to 30 mm Hg to accommodate for fluid lost to suction.

Working portals for meniscectomy will vary depending on the location of the tear and pattern. These are summarized in Table 1.

Posterior Horn

With the camera in the central portal, stabilized by an assistant, the biter may be introduced via the medial portal and the shaver via the far medial portal. The shaver may collect meniscal fragments as they are created by the biter.

Body

The camera may remain in the central portal while the meniscal biter enters from the lateral portal and the shaver is used from the medial portal.

Anterior Horn

The camera is placed in the lateral portal, and the biter enters from the far lateral portal while the shaver is in the medial portal.

Table 2. Pearls and Pitfalls

Pearls
<ul style="list-style-type: none"> • Familiarization with the 0° optic before surgery will improve the surgeon experience. • NA favors an in-line approach and large sweeping motions should be avoided. • Use of inflow on a separate sheath from the camera may improve visualization because of less restriction of flow. • Use of far medial and lateral portals allows open access to standard portals for instrumentation such as probes, biters, or shavers.
Pitfalls
<ul style="list-style-type: none"> • The camera uses a 0° view that may have a learning curve for surgeons. • NA instruments are more malleable than standard arthroscopic equipment because of their size, which can cause breaking and/or bending of the instruments. • During diagnostic NA, a surgeon may find indication to use the standard arthroscopy versus NA leading to potential increased cost. • The learning curve for needle arthroscopy carries the increased risk of iatrogenic chondral damage until the surgeon becomes more facile with the instrumentation.

NA, needle arthroscopy.

Meniscal Root

As noted previously, the best visualization of the root is provided from the far medial portal. Therefore, approaching the meniscal root will require moving the camera to the far medial portal and alternately using the shaver and biter via the medial portal.

A partial medial meniscectomy of the posterior horn and body such as is commonly encountered clinically may be performed in approximately 15 minutes using 250 mL of arthroscopy fluid using the described technique.

Closure

Portals are closed with inverted absorbable suture and 2-octyl cyanoacrylate (Dermabond, Johnson & Johnson, New Brunswick, NJ) glue. Because there is minimal soft-tissue swelling, there is low risk of drainage. Portals created by the sheath only do not require suture and may be closed with Dermabond glue alone. Simple adhesive dressings are placed over incisions at the conclusion of the procedure and the tourniquet is deflated. [Video 1](#) demonstrates the complete procedure.

Discussion

The cost-effectiveness and diagnostic accuracy of in-office NA has been previously reported, and examples of clinical situations in which NA provided diagnostic accuracy in cases of unexplained pain have been reported.^{2,8} However, a recent systematic review suggested promise for NA also highlighted limitations including the need for clearer diagnostic protocols to expand applications and widespread clinical use.⁹

Although descriptions of intraoperative diagnostic arthroscopy have been previously provided,^{6,7} they focus mostly on the tibiofemoral compartment and do not detail instrumentation or portal placement for therapeutic applications such as partial meniscectomy or chondroplasty. Furthermore, these descriptions describe significant manipulations of the camera, which can be technically challenging because of the flexible nature of the arthroscope when passing through larger soft-tissue envelopes. This manuscript reviews a technique for direct, in-line visualization of all structures and the portal locations for instruments and probes. Pearls and pitfalls of this procedure are listed in [Table 2](#).

McMillan et al.¹⁰ previously evaluated the risks and complications associated with in-office needle arthroscopy and found no major complications in 1,419 cases and minor complication rates less than 2%. Use of smaller incisions may further reduce the already low risk of infection after knee arthroscopy. Furthermore, lower arthroscopic fluid requirements may result in a decreased risk of wound drainage and less post-operative swelling compared with standard arthroscopy.

Finally, diagnostic NA has shown the capacity to deliver significant cost savings compared with standard magnetic resonance imaging.¹¹ Similar cost savings may be realized in the therapeutic setting because NA requires less instrumentation and equipment and can be potentially performed without general or spinal anesthesia. This may provide opportunities to move knee arthroscopy out of the operating room into a procedure room, which may further reduce costs and necessary personnel as well as saving time.

In conclusion, we describe a technique using needle arthroscopy for diagnostic and therapeutic procedures. We described the technique for direct, in-line visualization of all structures and the portal locations for instrument and probes as well as the technique for a partial medial meniscectomy using a needle arthroscopy.

References

1. Amin N, McIntyre L, Carter T, Xerogeanes J, Voigt J. Cost-effectiveness analysis of needle arthroscopy versus magnetic resonance imaging in the diagnosis and treatment of meniscal tears of the knee. *Arthroscopy* 2019;35:554-562.
2. Chapman GL, Amin NH. The benefits of an in-office arthroscopy in the diagnosis of unresolved knee pain. *Case Rep Orthop* 2018;2018.
3. Deirmengian CA, Dines JS, Vernace JV, et al. Use of a small-bore needle arthroscope to diagnose intra-articular knee pathology: comparison with magnetic resonance imaging. *Am J Orthop* 2018;47.
4. Gill TJ, Safran M, Mandelbaum B, et al. A prospective, blinded, multicenter clinical trial to compare the efficacy, accuracy, and safety of in-office diagnostic arthroscopy with magnetic resonance imaging and surgical diagnostic arthroscopy. *Arthroscopy* 2018;34:2429-2435.
5. McIntyre LF. Editorial Commentary: what you see is what you get—is in-office needle arthroscopy ready for prime time? *Arthroscopy* 2019;2722-2723.
6. McMillan S, Saini S, Alyea E, Ford E. Office-based needle arthroscopy: a standardized diagnostic approach to the knee. *Arthrosc Techniques* 2017;6:e1119-e1124.
7. Patel KA, Hartigan DE, Makovicka JL, Dulle DL III, Chhabra A. Diagnostic evaluation of the knee in the office setting using small-bore needle arthroscopy. *Arthrosc Techniques* 2018;7:e17-e21.
8. West JA, Amin NH. In-office arthroscopy for the evaluation of chronic knee pain: a case report. *Open Med Case Rep* 2017;5:2050313X17740992.
9. Zhang K, Crum RJ, Samuelsson K, Cadet E, Ayeni OR. In-office needle arthroscopy: a systematic review of indications and clinical utility. *Arthroscopy* 2019;35:2709-2721.
10. McMillan S, Chhabra A, Hassebrock JD, Ford E, Amin NH. Risks and complications associated with intra-articular arthroscopy of the knee and shoulder in an office setting. *Orthop J Sports Med* 2019;7:2325967119869846.
11. McMillan S, Schwartz M, Jennings B, Faucett S, Owens T, Ford E. In-office diagnostic needle arthroscopy: understanding the potential value for the US healthcare system. *Am J Orthop* 201;46:252-256.