



Contents lists available at ScienceDirect

International Journal of Surgery Case Reports

journal homepage: www.casereports.com

First bilateral non-invasive follicular thyroid neoplasm with papillary-like nuclear features (NIFTP) co-occurring with bilateral papillary thyroid microcarcinoma. Case report and literature review

Mohamed S. Al Hassan^a, Walid El Ansari^{b,c,d,*}, Abdallah Elshafeey^e, Mahir Petkar^f, Abdelrahman Abdelaal^a

^a Department of General Surgery, Hamad General Hospital, Doha, Qatar

^b Department of Surgery, Hamad General Hospital, Doha, Qatar

^c College of Medicine, Qatar University, Doha, Qatar

^d School of Health and Education, University of Skövde, Skövde, Sweden

^e Weill Cornell Medicine – Qatar, Doha, Qatar

^f Department of Laboratory Medicine & Pathology, Hamad General Hospital, Doha, Qatar

ARTICLE INFO

Article history:

Received 28 November 2020

Accepted 30 November 2020

Available online 2 December 2020

Keywords:

NIFTP

Case report

Thyroid nodule

Management

Papillary thyroid microcarcinoma

Bilateral

ABSTRACT

INTRODUCTION: Non-invasive follicular thyroid neoplasm with papillary-like features (NIFTP) is a recently characterized lesion with very low malignant potential. This has allowed for less aggressive management of this tumor subtype. Papillary thyroid carcinoma (PTC) has malignant potential and requires different considerations in management.

PRESENTATION OF CASE: A 33-year-old woman presented to our Thyroid Surgery Clinic with a left neck swelling slowly enlarging over 4 years, and recent right-sided neck pain. Neck ultrasound and fine needle aspiration for cytology found bilateral thyroid nodules, labelled as ‘follicular lesion of undetermined significance’ (FLUS). Final pathology report after total thyroidectomy identified four distinct tumors: bilateral NIFTP lesions and bilateral papillary microcarcinomas.

DISCUSSION: Management of NIFTP comprises partial or total thyroidectomy without further intervention. Management of PTC is the same but with the possible addition of radioactive ablation due to the increased malignant potential. This is the first report of bilateral NIFTP lesions and bilateral papillary microcarcinomas co-occurring together in the same patient, so management was challenging. The decision was made to give the patient low dose radioactive iodine ablation and continue monitoring. Ultrasound of the neck follow up 6 months later showed no residual thyroid tissue or local recurrence.

CONCLUSION: Although rare, NIFTP can co-occur with PTC. Bilateral NIFTP with bilateral PTC is extremely rare. Surgeons and pathologists need to be aware of this rare entity that can co-occur in both thyroid lobes. Total thyroidectomy is the definitive treatment. Post-surgery surveillance is important and follow up needs to be watchful for any recurrence or metastasis.

© 2020 The Author(s). Published by Elsevier Ltd on behalf of IJS Publishing Group Ltd. This is an open access article under the CC BY-NC-ND license (<http://creativecommons.org/licenses/by-nc-nd/4.0/>).

1. Introduction

Thyroid cancer is an increasingly important due to the dramatic increase in diagnosed cases during the last 30 years [1]. Even though the 5-year survival rate is 97.8 % [1], thyroid cancer has significant impact, where in the USA alone, \$1.6 billion has been spent on the management of thyroid cancer during 1985–2014 [2]. Extensive efforts have been made to appropriately classify thyroid tumors based on their potential for malignancy in order to manage benign lesions less aggressively. In 2017, the WHO released a

new classification for thyroid tumors to further classify previously misunderstood lesions [3].

Most well differentiated thyroid tumors can be classified into the broad follicular and papillary categories based on the histological characteristics. Follicular tumors (10–15 % prevalence of all thyroid cancers) comprise follicular cells lined by cuboidal epithelium and are further characterized based on their invasive behavior [4,5]. Follicular tumors that do not invade the capsule are follicular adenomas, and those that show evidence of invasion are follicular carcinomas [4]. Papillary thyroid cancer (PTC, the most common type of thyroid tumors) is an epithelial type tumor, carries the best prognosis, and is differentiated from the follicular subtype by its unique nuclear features [5].

A very unique and recently characterized thyroid lesion is the non-invasive follicular thyroid neoplasm with papillary-like

* Corresponding author at: Department of Surgery, Hamad General Hospital, Doha, Qatar.

E-mail address: welansari9@gmail.com (W. El Ansari).

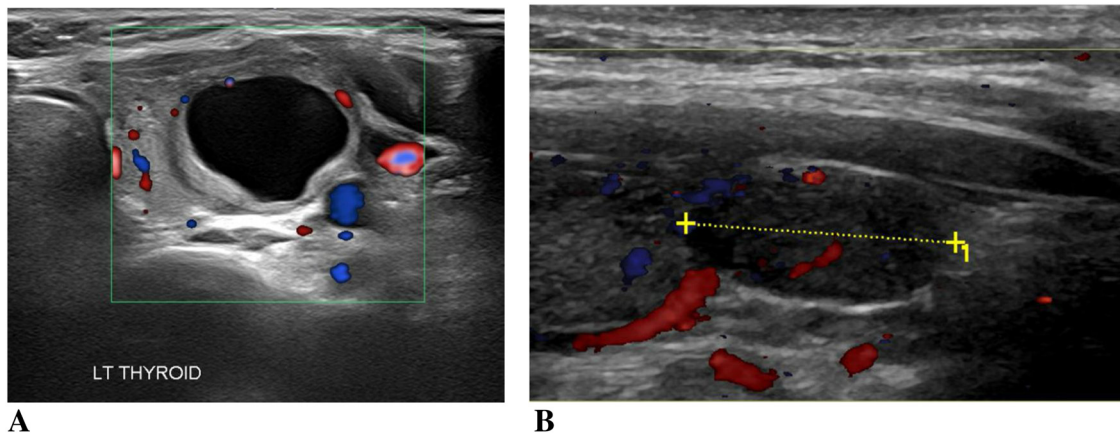


Fig. 1. US of the left thyroid nodule.

features (NIFTP). This type has distinct histopathological and clinical characteristics. Formerly known as noninvasive encapsulated follicular variant of papillary thyroid carcinoma, NIFTP behaves differently from the classic PTC. Most importantly, NIFTP has a very indolent course and rarely exhibits malignant potential [6], making it important to distinguish from other more malignant tumors. A study of 108 patients showed that NIFTP exhibited no recurrence 1–10 years after simple lobectomy [7]. Diagnosis of NIFTP is made after complete resection and confirmation of criteria such as the full encapsulation of the tumor, nuclear feature of PTC, follicular pattern of growth with no psammoma bodies, no capsular or vascular invasion, and no evidence of necrosis [7]. Molecular testing is a major part of the diagnosis due to the unique genetic makeup of NIFTP that includes markers like an activating mutation in one of the RAS genes (NRAS most common, 36–67%), PAX8-PARG rearrangement (4–22%), and THADA fusions (22%) [8].

We present a patient with a left sided neck swelling that, after total thyroidectomy, was found to have bilateral NIFTPs in addition to bilateral papillary thyroid microcarcinoma. To the best of our knowledge, this is the first case report of this nature. We report this case in line with the updated consensus-based surgical case report (SCARE) guidelines [9].

2. Case presentation

A 33-year-old Egyptian female patient presented at our Thyroid Surgery Outpatient Clinic at Hamad General Hospital in Doha, Qatar with a 4-year history of left neck swelling. She also complained of a recent feeling of some discomfort and neck pain on the right side, but no change of voice. Her past medical, social and family history were unremarkable. She had no history of chronic medical conditions and her only surgical history was a lower segment cesarian section a few months before her current index presentation. She did not smoke, never consumed alcohol and was not on long-term medications. There was no family history of thyroid cancer, and no past history of neck irradiation. Physical examination revealed a left thyroid lobe enlargement, about 3 × 3 cm, that moved with swallowing. The right thyroid lobe was not palpable. The rest of the physical examination was unremarkable.

Blood work up on presentation showed normal TSH and free T3 and T4. Initial ultrasound (US) of the thyroid gland at a secondary hospital showed enlargement of the left lobe (5.3 × 2.2 × 3.5 cm), as well as a complex nodule (4.2 × 1.8 × 2.2 cm) that occupied most of the left lobe, containing a cyst with a thick irregular wall and clear contents with peripheral vascularity and no internal vascularity. Both submandibular and parotid glands were unremarkable, and there was no cervical lymphadenopathy.

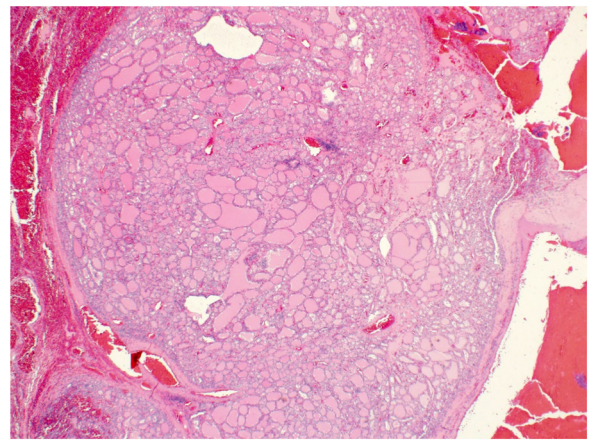


Fig. 2. Left lobe NIFTP with well circumscribed and thin capsule. H and E x 2.

She was referred to our Thyroid Surgery Outpatient Clinic at the tertiary hospital for US guided fine-needle aspiration for cytology (FNAC) (Fig. 1). We undertook FNAC biopsy of this left lobe nodule. During the FNAC procedure, the US showed another solid nodule in the right lobe that was also aspirated. The aspirate from both nodules showed high cellularity comprised of follicular cells arranged in an altered architectural background, suggesting the histopathologic diagnosis of the two nodules as ‘follicular lesion of undetermined significance’ (FLUS). The case was discussed at our thyroid multi-disciplinary meeting (MDT) and the decision was to undertake total thyroidectomy. The surgery was undertaken by an experienced thyroid surgeon and was uneventful.

The thyroidectomy specimen weighed 23 gm. The right lobe measured 4 × 1.5 × 1.5 cm, whereas the left lobe measured 5 × 2.5 × 2.5 cm. There was a well demarcated nodule in the right lobe measuring 1.3 cm in maximum dimension and a similar, but larger, thinly encapsulated nodule, measuring 3 cm in maximum dimension, in the left lobe. Microscopically, both nodules displayed features of NIFTP. The neoplasms had a follicular architecture with lesional cells exhibiting nuclear clearing and prominent grooves. HBME1 immunostain was strongly and diffusely positive, while staining for B Raf V600 E was negative. In addition, there were two separate foci of papillary microcarcinoma, located in the right and left lobes, measuring 0.8 cm and 0.3 cm respectively, demonstrating typical nuclear characteristics (nuclear clearing, overlapping and grooves) with areas of papillary morphology. Background lymphocytic thyroiditis and adenomatoid nodules were also noted (Figs. 2–6).

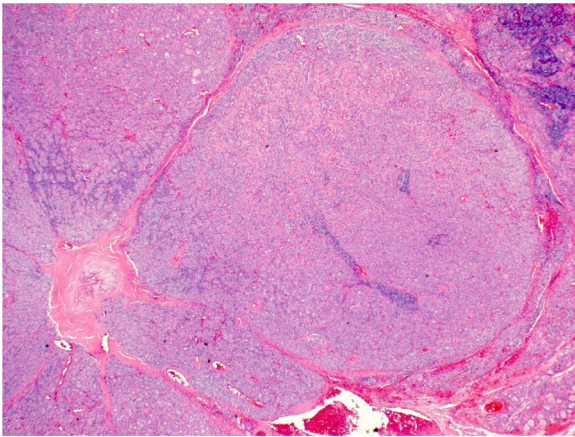


Fig. 3. Right lobe NIFTP with characteristic well circumscribed architecture. H and E x 2.

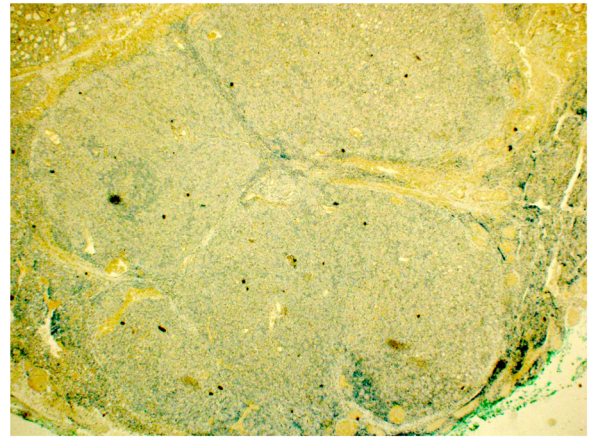


Fig. 6. Negative Braf V600 E immunostain in the NIFTP.

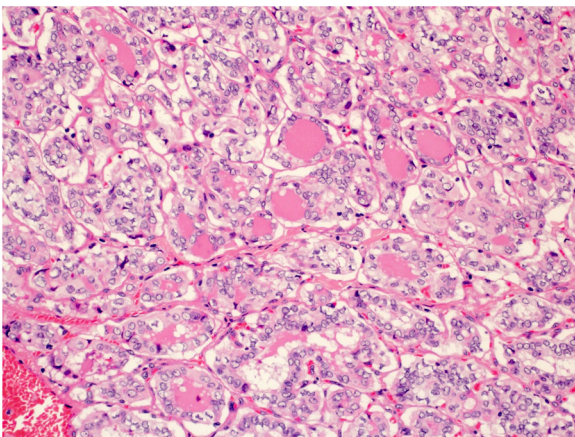


Fig. 4. Papillary microcarcinoma with tumor cells showing typical nuclear features including overlapping, clearing and grooves. H and E x 20.

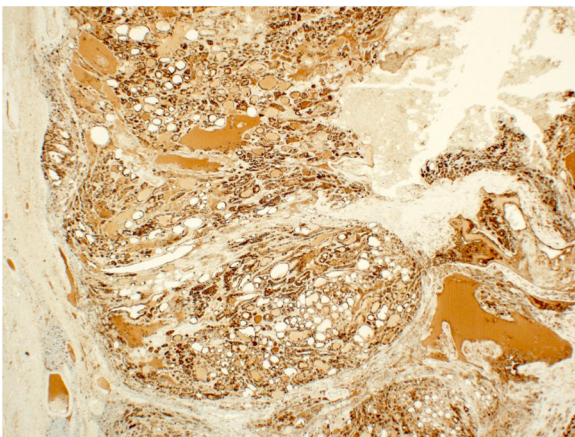


Fig. 5. NIFTP demonstrating strong HBME1 staining.

Two weeks after the surgery, non-stimulated thyroglobulin (TG) was <0.1 ng/mL, and TG antibodies was positive (133.5 IU/mL). Hence, MDT recommended low-dose radioactive iodine therapy (oral intake of 869 MBq of radioactive I-131 capsule), followed by whole body scan which showed a small amount of activity in the thyroid bed. There was no evidence of distant abnormal uptake (Fig. 7). Three months later, the blood test showed TG level of 0.1 ng/mL, and the TG antibodies exhibited a drop from 133 IU/mL

to 36.9 IU/mL. The patient was put on suppressive levothyroxine therapy, and scheduled for follow up every 6 months by US of the neck, and thyroglobulin tumor markers. The most recent follow up US 6 months later showed no definite residual thyroid tissue or local recurrence.

3. Discussion

To the best of our knowledge, this is the first reported case of bilateral NIFTPs with simultaneous bilateral papillary thyroid microcarcinoma. Hence, we were unable to find other similar published cases with which we can directly compare our findings with. We provide a literature review of the 4 published case reports of NIFTP. Despite that are many cases of NIFTP reported in literature as part of bigger trials or systematic review of trials, we report these 4 cases along with ours, due to the unique features of each of them. One of the cases occurred in a 10-year-old child, two cases had spindle cell metaplasia within the lesion, and lastly, one of the lesions occurred within a Hurthle cell adenoma (Table 1).

To date, there have been 1430 reported cases of unilateral NIFTP [7], but to the best of our knowledge, no reports of bilateral NIFTP. In addition, none of these 1430 reported cases had associated microcarcinoma, and none had bilateral associated microcarcinomas. Hence the current case is very unique and presents some challenges in the management that have not been described before.

NIFTP has been recently characterized as a thyroid tumor that exhibits an indolent behavior. Such characterization allows clinicians to approach NIFTP in a less aggressive way than before, limiting the need for extensive therapy and unnecessary side effects associated with aggressive measures [6]. A recent review that examined 11 NIFTP studies with large patient populations observed no deaths due to NIFTP and only 1 case of pulmonary metastasis [7]. Given the mortality and metastatic evidence that this review provided, the paradigm for management of NIFTP shifted considerably and now centers around simple lobectomy for the NIFTP instead of adding radioactive iodine as well [6].

In terms of presentation, our review of the literature (Table 1) shows that most NIFTP cases presented asymptotically with either a fully enlarged thyroid or enlargement of a single lobe. We are in agreement, our patient presented with left thyroid enlargement which can be considered a classical presentation of thyroid nodules. However, the table also shows that one patient had an unusual presentation [10], with upper extremity numbness which is not normally a symptom of thyroid nodules unless they involve the parathyroid gland and influence calcium homeostasis. However, our patient also complained of recent right sided neck pain.

Table 1
Review of literature of case reports of unique NIFTP.

| Report | Age | G | Laterality | Presentation | NIFTP | Other tumor | TFT | Ultrasound | FNAC | Surgical Tx | Radioactive iodine | Follow up |
|------------------------------|-----|---|---------------|--|--|------------------------------------|-----------|---|---|--|--------------------|------------------|
| Current Case Qatar 2020 | 33 | F | Bilateral | L neck swelling, recent neck pain on Rt side | Bilateral NIFTP | Bilateral papillary microcarcinoma | Euthyroid | Complex cystic nodule in L, solid nodule in Rt thyroid lobe | Follicular lesion of undetermined significance (FLUS) | Total thyroidectomy | Yes | 6 m, no R or Mt |
| Abdou [12] Egypt 2020 | 10 | F | Unilateral Rt | Enlarged thyroid observed by mother | Two NIFTP lesions on R side | N | Euthyroid | Two suspicious nodules on Rt side | Sheets of follicular epithelial cells | Total thyroidectomy | No | 12 m, no R or Mt |
| Pigac [16] Croatia 2018 | 42 | F | ^b | Slightly enlarged tender thyroid | NIFTP lesion within a Hurthle cell adenoma | N | Euthyroid | Enlarged both lobes, hypoechoic structure in Rt lobe | Hurthle cells | Rt hemithyroidectomy switched to total thyroidectomy | No | N |
| Al Rasheed [10] USA 2017 | 76 | F | ^a | Upper extremity numbness. Multinodular goiter | NIFTP with spindle cell metaplasia | N | Euthyroid | Multinodular goiter, Dominant nodule in Rt upper pole. No microcalcifications | Follicular and Hurthle cells | Total thyroidectomy | No | 2 m no R or Mt |
| Arnoux [11] Switzerland 2017 | 37 | F | Unilateral L | Large nodule in L thyroid enlarging since 2005 | NIFTP with focal spindle cell metaplasia | N | Euthyroid | Isoechogenic nodule in L thyroid lobe | FNA 12 years earlier showed benign findings | L lobe-isthmectomy | No | N |

Due to space limitations, only the first author is cited; ^a Patient had multiple nodules throughout the thyroid, but the case report only commented on the NIFTP lesion; ^b On ultrasound two lesions were found, one on the right and one on the left but the case report did not comment on the left-sided lesion; FNAC: Fine Needle Aspiration for Cytology; G: Gender; L: Left; Mt: metastasis; m: months; N: no; NIFTP: non-invasive follicular thyroid neoplasm with papillary-like features; R: recurrence; Rt: Right; TFT: Thyroid Function Tests.

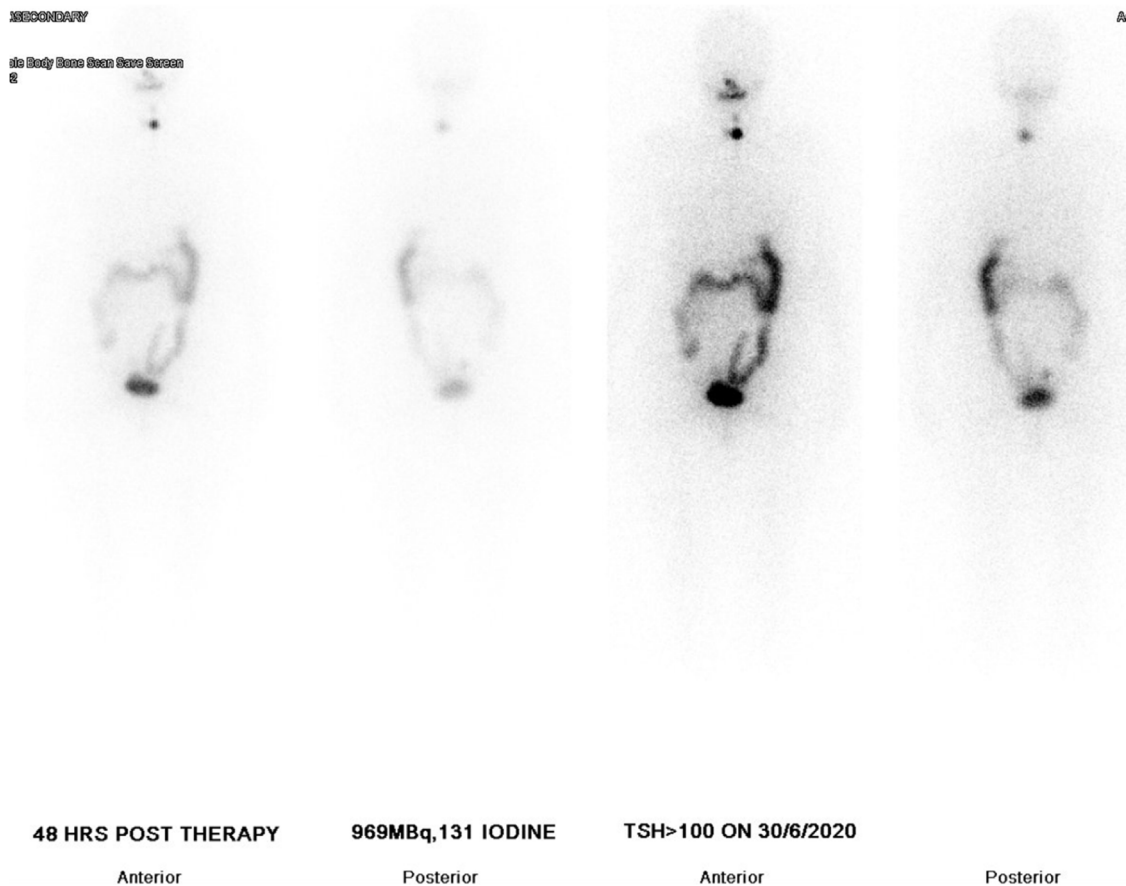


Fig. 7. Post low-dose radioactive iodine therapy whole body scan showing small amount of activity in the thyroid bed.

As regards to thyroid involvement, [Table 1](#) depicts some variation in terms of the extent of the involvement of the thyroid. While one case had multinodular enlargement of the gland [10], others [11,12] presented with enlargement of only one half of the gland. Given such an extent of variation, there seems to be no fixed set of physical examination findings or presentation that can provide an indication to the surgical team as to nature of the lesions.

In terms of investigations, thyroid function tests (TFTs) are required to determine the activity of the thyroid gland. [Table 1](#) shows that in all the cases reviewed, the patients were euthyroid indicating that the nodules were not active [10–12,16]. We are in agreement, our patient was euthyroid, although the patient had delivered around one month before the first set of TFTs which could cause unexpected endocrine fluctuations. Such fluctuations have been shown to occur in around 5 % of women following delivery [13].

As for imaging, [Table 1](#) depicts that the US findings differed considerably between cases that our review identified. The published cases we reviewed exhibited variable echogenicity on US scan. Such hypoechoic, hyperechoic or isoechogenic US findings [11,14,16] are supported by others who described NIFTP lesions as well-circumscribed with widely variable echogenicity [14]. In addition, initial US only showed the left sided complex cystic nodule; only on US guided FNA was the second nodule on the right side identified and aspirated. US findings are operator dependent, and there could be some limitations of US when employed for the assessment of thyroid nodules, where nodules that are too small might not be identified with great accuracy. Hence US findings of the thyroid should be interpreted with caution because it does not have perfect sensitivity [15].

As for the US guided FNAC, [Table 1](#) shows that all the cases that our review identified exhibited follicular cells in a background of colloid or benign cells. Some of the studies also found Hurthle cells [10,16]. In our case, FNAC of both right and left nodules showed an abundance of follicular cells in an altered architecture suggesting FLUS. A limitation of FNAC is that it does not provide information regarding invasion of the capsule which is essential in the diagnosis of NIFTP [6].

In terms of management, based on our combined US and FNAC results, after MDT meeting, the decision was to undertake total thyroidectomy. This was undertaken by an experienced surgeon. The final histopathologic examination found that the two masses identified on imaging were both NIFTP, and also reported two additional small masses of papillary microcarcinomas.

Such presence of four separate tumors presented a huge dilemma to the team as to the best way forward with this patient's management. On the one hand, NIFTP is established as a relatively benign lesion with almost no chance of recurrence after resection. [Table 1](#) shows that all the NIFTP cases that our review identified were managed by simple resection of the involved thyroid gland and subsequent follow up. On the other hand, contrary to all the other cases in [Table 1](#), our patient had two NIFTPs and two papillary microcarcinomas. In addition, the patient had elevated tumor marker thyroglobulin suggesting some malignant potential, probably of the papillary microcarcinomas. The decision, after MDT meeting, was to give the patient low dose radioactive iodine ablation, both as a diagnostic measure (to identify any residual thyroid tissue) and also therapeutic.

In terms of recurrence and metastasis, US follow up of our patient at 6 months showed no evidence of either. The patient, however, remains being monitored every 6 months in order to assess

any recurrence. As for prognosis, NIFTP is relatively benign and shows no malignant potential, whilst papillary microcarcinomas are generally viewed to have malignant potential and can sometimes be discovered with metastasis [17].

4. Conclusion

This unique case report is of a woman with bilateral NIFTP and bilateral papillary microcarcinomas of the thyroid. Such diagnosis of combinations of different thyroid lesion of benign and potentially malignant nature harbors lessons regarding management. FNA does not provide information about the invasion of the capsule. Post excision histopathology provides the definitive diagnosis. Surgeons and pathologists need to have a high index of suspicion and awareness that the presence of NIFTP of the thyroid does not exclude the co-occurrence of other papillary microcarcinomas lesions.

Conflicts of interest

Nothing to declare.

Sources of funding

Nothing to declare.

Ethical approval

Approved by Medical Research Center, Hamad Medical Corporation reference number (MRC-04-20-1090).

Consent

Written informed consent was obtained from the patient for publication of this case report and accompanying images. A copy of the written consent is available for review by the Editor-in-Chief of this journal on request.

Author contribution

Mohamed S. Al Hassan: Conceptualization, Data curation, Investigation, Writing -review & editing. **Walid El Ansari:** Conceptualization, Data curation, Investigation, Methodology, Project administration, Writing- original draft, Writing - review & editing. **Abdallah Elshafeey:** Data curation, Investigation, Methodology, Writing- original draft, Writing - review & editing. **Mahir Petkar:** Laboratory data, Writing - review & editing. **Abdelrahman Abdelaal:** Data curation, Writing - review & editing.

All authors critically reviewed, revised and contributed to the final article. All authors read and approved the final manuscript.

Registration of research studies

researchregistry6272 available at: <https://www.researchregistry.com/browse-the-registry#home/registrationdetails/5fba4ae0d3b0b1001e41b262/>.

Open Access

This article is published Open Access at [sciencedirect.com](https://www.sciencedirect.com). It is distributed under the [IJSCR Supplemental terms and conditions](#), which permits unrestricted non commercial use, distribution, and reproduction in any medium, provided the original authors and source are credited.

Guarantor

Prof Dr Walid El Ansari.

Provenance and peer review

Not commissioned, externally peer-reviewed

Acknowledgements

The authors wish to acknowledge the patient included in this report.

References

- [1] Q.T. Nguyen, E.J. Lee, M.G. Huang, Y.I. Park, A. Khullar, R.A. Plodkowski, Diagnosis and treatment of patients with thyroid cancer, *Am. Health Drug Benefits* 8 (2015) 30–40.
- [2] C.C. Lubitz, C.Y. Kong, P.M. McMahon, G.H. Daniels, Y. Chen, K.P. Economopoulos, G.S. Gazelle, M.C. Weinstein, Annual financial impact of well-differentiated thyroid cancer care in the United States, *Cancer* 120 (2014) 1345–1352.
- [3] D. Sanita, E. Al, WHO Classification of Tumours of Endocrine Organs, International Agency for Research On Cancer PP - Lyon, 2017.
- [4] D. Ashorobi, P.P. Lopez, Follicular Thyroid Cancer, StatPearls Publishing, Treasure Island (FL), 2020 [Updated 2020 Aug 26]. StatPearls [Internet]. January.
- [5] F. Limaiei, A. Rehman, T. Mazzoni, Papillary Thyroid Carcinoma, StatPearls Publishing, Treasure Island (FL), 2020 [Updated 2020 Oct 16]. StatPearls [Internet]. January.
- [6] Y.E. Nikiforov, R.R. Seethala, G. Tallini, Z.W. Baloch, F. Basolo, L.D.R. Thompson, J.A. Barletta, B.M. Wenig, A. Al Ghuzlan, K. Kakudo, T.J. Giordano, V.A. Alves, E. Khanafshar, S.L. Asa, A.K. El-Naggar, W.E. Gooding, S.P. Hodak, R.V. Lloyd, G. Maytal, O. Mete, M.N. Nikiforova, V. Nosé, M. Papotti, D.N. Poller, P.M. Sadow, A.S. Tischler, R.M. Tuttle, K.B. Wall, V.A. Livolsi, G.W. Randolph, R.A. Ghossein, Nomenclature revision for encapsulated follicular variant of papillary thyroid carcinoma, *JAMA Oncol.* 2 (2016) 1023.
- [7] P.W. Rosario, G.F. Mourão, Noninvasive follicular thyroid neoplasm with papillary-like nuclear features (NIFTP): a review for clinicians, *Endocrine-Related Cancer* 26 (2019) R259–R266.
- [8] M. Pusztaszeri, M. Bongiovanni, The impact of non-invasive follicular thyroid neoplasm with papillary-like nuclear features (NIFTP) on the diagnosis of thyroid nodules, *Gland Surg.* 8 (2019) S86–S97.
- [9] R.A. Agha, T. Franchi, C. Sohrabi, G. Mathew, A. Kerwan, SCARE Group, The SCARE 2020 guideline: updating consensus Surgical Case REport (SCARE) guidelines, *Int. J. Surg.* (2020), <http://dx.doi.org/10.1016/j.ijss.2020.10.034>, S1743-9191(20)30771-8. Epub ahead of print.
- [10] M.R. Haroon Al Rasheed, A. Acosta, G. Tarjan, Encapsulated follicular variant of papillary thyroid carcinoma/noninvasive follicular thyroid neoplasm with papillary-like nuclear features with Spindle Cell Metaplasia: case report and review of literature, *Pathol. - Res. Pract.* 213 (2017) 416–421.
- [11] G. Arnoux, M. Pusztaszeri, "Noninvasive follicular thyroid neoplasm with papillary-like nuclear features" with focal spindle cell metaplasia, *Int. J. Surg. Pathol.* 26 (2017) 261–265.
- [12] A.G. Abdou, H. Aiad, N. Asaad, Case Report: multifocal non-invasive follicular thyroid neoplasm with papillary-like nuclear features presenting in a female child, *F1000Research* 9 (2020) 645.
- [13] A. Smith, J. Eccles-Smith, M. D'Emden, K. Lust, Thyroid disorders in pregnancy and postpartum, *Aust. Prescr.* 40 (2017) 214–219.
- [14] K. Zajkowska, J. Koczyński, S. Gózdź, A. Kowalska, Noninvasive follicular thyroid neoplasm with papillary-like nuclear features: a problematic entity, *Endocr. Connect.* 9 (2020) R47–R58.
- [15] K. Rahim Durr-e-Sabih, Thyroid nodule imaging, status and limitations, *Asia Ocean. J. Nucl. Med. Biol.* 3 (2015) 50–57.
- [16] B. Pigac, S. Masic, Z. Hutinec, V. Masic, Rare occurrence of incidental finding of noninvasive follicular thyroid neoplasm with papillary-like nuclear features in hurthle cell adenoma, *Med. Arch.* 72 (2018) 367.
- [17] S. Dideban, A. Abdollahi, A. Meysamie, S. Sedghi, M. Shahriari, Thyroid papillary microcarcinoma: etiology, clinical manifestations, diagnosis, follow-up, histopathology and prognosis, *Iran. J. Pathol.* 11 (2016) 1–19.