



RESEARCH ARTICLE

REVISED TMD symptoms and vertical mandibular symmetry in young adult orthodontic patients in North Sumatra, Indonesia: a cross-sectional study [version 2; referees: 3 approved]

Ervina Sofyanti ^{1,2}, Trelia Boel³, Benny Soegiharto⁴, Elza I. Auerkari ⁵

- ¹Doctoral Program, Faculty of Dentistry, Universitas Sumatera Utara, Medan, Indonesia
- ²Department of Orthodontics, Faculty of Dentistry, Universitas Sumatera Utara, Medan, Indonesia
- ³Department of Dentomaxillofacial Radiography, Faculty of Dentistry, Universitas Sumatera Utara, Medan, Indonesia
- ⁴Department of Orthodontics, Faculty of Dentistry, Universitas Indonesia, Jakarta, Indonesia
- ⁵Department of Oral Biology, Faculty of Dentistry, Universitas Indonesia, Jakarta, Indonesia

v2 First published: 04 Jun 2018, 7:697 (doi: [10.12688/f1000research.14522.1](https://doi.org/10.12688/f1000research.14522.1))
 Latest published: 16 Jul 2018, 7:697 (doi: [10.12688/f1000research.14522.2](https://doi.org/10.12688/f1000research.14522.2))

Abstract

Background: Temporomandibular joint disorder (TMD) includes symptoms of pain and dysfunction in the muscles of mastication and the temporomandibular joint. Differences in vertical condylar height, observed in the assessment of mandibular asymmetry, is a structural alteration that represents a risk factor for TMD. The study aimed to evaluate the association between TMD symptoms and vertical mandibular symmetry in young adult orthodontic patients in North Sumatra, Indonesia.

Methods: The cross-sectional study included 18-25-year-old (mean ± SD, 21.9 ± 2.0 years) old orthodontic patients admitted to the Dental Hospital of Universitas Sumatera Utara, Medan, between June 2016 and March 2017. Vertical mandibular asymmetry was assessed from all 106 subjects using Kjellberg's technique from pre-treatment panoramic radiographs. The TMD symptoms were assessed by structural interviews using modified questionnaires based on Temporomandibular Disorder Diagnostic Index and Fonseca's Anamnestic Index.

Results: Of the 106 subjects, 26 (24.5% of the total) with vertical mandibular symmetry and 39 (36.8%) with vertical mandibular asymmetry were positive for TMD symptoms. By contrast, 17 patients (16.0% of the total) with vertical condylar symmetry and 24 patients (22.6%) with vertical mandibular asymmetry were regarded negative for TMD symptoms. There was no significant difference (p=0.520) in TMD symptoms based on vertical mandibular symmetry.

Conclusion: The results from this studied Sumatran population indicate that there are common TMD symptoms in young adult orthodontic patients, but there is no significant association between vertical mandibular asymmetry and TMD symptoms. Further study on the development of TMD, mandibular asymmetry and treatment planning for growing patients is suggested, using longitudinal and transitional approaches.

Keywords

vertical mandibular asymmetry; temporomandibular disorder

Open Peer Review

Referee Status:

	Invited Referees		
	1	2	3
REVISED			
version 2 published 16 Jul 2018			
version 1 published 04 Jun 2018	 report	 report	 report

- 1 **Ida Bagus Narmada**, Airlangga University, Indonesia
- 2 **Farhad B. Naini**, St George's NHS Foundation Trust, UK
Ashraf Messiha, St George's Hospital & Medical School, UK
- 3 **Ashok Karad**, Smile Care, India

Discuss this article

Comments (0)

Corresponding author: Elza I. Auerkari (eauekari@yahoo.com)

Author roles: **Sofyanti E:** Conceptualization, Data Curation, Formal Analysis, Investigation, Methodology, Project Administration, Resources, Software, Supervision, Visualization, Writing – Original Draft Preparation, Writing – Review & Editing; **Boel T:** Formal Analysis, Supervision, Validation, Visualization; **Soegiharto B:** Methodology, Supervision; **Auerkari EI:** Conceptualization, Project Administration, Supervision, Writing – Review & Editing

Competing interests: No competing interests were disclosed.

Grant information: The author(s) declared that no grants were involved in supporting this work.

Copyright: © 2018 Sofyanti E *et al.* This is an open access article distributed under the terms of the [Creative Commons Attribution Licence](#), which permits unrestricted use, distribution, and reproduction in any medium, provided the original work is properly cited. Data associated with the article are available under the terms of the [Creative Commons Zero "No rights reserved" data waiver](#) (CC0 1.0 Public domain dedication).

How to cite this article: Sofyanti E, Boel T, Soegiharto B and Auerkari EI. **TMD symptoms and vertical mandibular symmetry in young adult orthodontic patients in North Sumatra, Indonesia: a cross-sectional study [version 2; referees: 3 approved]** *F1000Research* 2018, 7:697 (doi: [10.12688/f1000research.14522.2](https://doi.org/10.12688/f1000research.14522.2))

First published: 04 Jun 2018, 7:697 (doi: [10.12688/f1000research.14522.1](https://doi.org/10.12688/f1000research.14522.1))

REVISED Amendments from Version 1

The changes that were made are primarily in the material and method sections, especially related to the measurement procedures based on the Kjellberg technique. The referees' suggestion was added to the discussion phrase in relation to the results of the study and future study related to the complexity of TMD and mandibular asymmetry.

See referee reports

Introduction

The goal of orthodontics for young patients is to provide a functional occlusion to give harmony in the dental arrangement, the anatomy of temporomandibular joints, and the activity of the masticatory muscles in later adulthood¹. The assessment of symmetry is important in comprehensive orthodontic treatment, as well as in malocclusions and dental evaluation; it is related to this aforementioned goal of orthodontic treatment, especially the functional and aesthetic evaluation of the craniofacial region^{2,3}. The asymmetries in human facial structures affect the skeleton, muscles and corresponding attached facial tissues. The prevalence of mandibular asymmetry is highest when compared to asymmetry of cranial base and maxillary arch in the human skull⁴. In orthodontic assessment, it is also important to consider whether the development of mandibular asymmetry could affect jaw, head and even shoulder movement, creating problems that should not occur in healthy subjects⁵⁻⁷.

According to a study on 8–30-year-old subjects in Jakarta, Indonesia, based on questionnaires and posteroanterior radiography, the main risk factor of mandibular asymmetry is temporomandibular joint disorder (TMD)⁸. Asymmetry in the vertical dimension, based on posteroanterior radiography, was significantly correlated with temporomandibular joint internal derangement in a study on 187 Japanese subjects with pre-orthodontic mandibular asymmetry and a mean age of 23.9 years⁹.

The etiology, diagnosis and management of mandibular asymmetries focuses particularly on developmental asymmetries. Increasing mandibular asymmetry with bilateral asymmetry of morphological traits causes malfunctions in developmental homeostasis, associated with environmental and/or genetic stresses. The development of morphological asymmetry may serve as a risk factor for disorders of developmental origin if these stresses are involved. The biopsychosocial model is hypothesized to be the most accepted theory for developmental asymmetry and complexity of TMD^{5,10}. Studies concerning TMD and the relevance of orthodontic treatment suggest that the achievement of a balanced in the dynamic occlusion is necessarily related to the development of mandibular symmetry as a part of the successful management of TMD^{2,10-13}.

Panoramic radiography is commonly used to assess the extent of mandibular asymmetry, as bilateral information is provided in routine dental practice. The asymmetry indices of mandibular height based on the ratio of condylar height (CH) and ramus height (RH) asymmetry, according to Habets' method and Kjellberg's technique, correlated significantly between TMD and

non-TMD patients^{14,15}. However, Kjellberg's technique is easier in terms of identifying the points and measurements and compares both sides because the measurement of CH from the highest point of condylar head to the mandibular notch; this differs from Habets' method, which uses the distance from the highest point of the condyle to the most lateral point of the condyle¹⁶. A previous study of 100 patients with TMD in the Seoul National University Dental Hospital between 2009 and 2011 found that asymmetry resulting in more than a 4.37% difference between mandibular heights may increase the risk of TMD and was positively correlated with the incidence of arthritic change in the temporomandibular joint of patients with TMD, although this does not necessarily indicate a direct cause-and-effect relationship⁷. By contrast, there was no statistically significant difference found between the severity of signs and symptoms of TMD based on vertical mandibular asymmetry, assessed using Habets' method and Kjellberg's techniques in 12–65-year-old patients¹⁷. Since TMD and mandibular asymmetry are complex issues that cover a large variety of symptoms, this study aims to analyze the association between TMD symptoms and vertical mandibular asymmetry measured using Kjellberg's technique in young adults that sought orthodontics treatment at the Dental Hospital in Universitas Sumatera Utara, Medan, Indonesia.

Methods

This cross-sectional study was conducted at the Dental Hospital of the Faculty of Dentistry, Universitas Sumatera Utara between June 2016 and March 2017. The Health Research Ethical Committee of the Medical Faculty, Universitas Sumatera Utara (100/DATE/KEPK FK USU-RSUP HAM/2017) approved the study. All 106 subjects were 18–25-year-old patients that attended the orthodontic clinic for a consultation, with following eligibility criteria: no previous orthodontic treatment, no history of traumatic facial injury or congenital disease. Patients who attended the orthodontic clinic had been informed that if they provided written informed consent, they would be included in a survey. In compliance with the Declaration of Helsinki, the consenting participants were asked to fill in the questionnaire on the Temporomandibular Disorder Diagnostics Index (TMD-DI; [Table 1](#)) at the Orthodontics clinic, Dental hospital Faculty of Dentistry, Universitas Sumatera Utara. The assessment of TMD symptoms were based on TMD-DI with categories of TMD-positive or TMD-negative¹⁸. The assessment of stress ([Table 2](#)) was using questions for a modified Fonseca's Anamnestic Index, related to bruxism, joint noise and nervousness¹⁹.

Subjects were referred to take panoramic radiography with exposure parameters (80 kV, 15 mA, 12 seconds) in the Pramita Clinic and laboratory, Medan, North Sumatera, Indonesia. [Figure 1](#) shows the classification of vertical mandibular height symmetry. A percentage symmetry of 93.7% or lower was defined as vertical mandibular asymmetry based on Kjellberg's technique¹⁷. [Figure 2](#) showed the measurement of vertical mandibular symmetry manually on tracing paper. [Figure 1](#) showed the points in measuring the vertical mandibular symmetry as follows: CH is defined as the distance from CO (the highest point of the condylar head) to the mandibular notch (the deepest point between the coronoid process and the condylar

Table 1. Temporomandibular Disorder-Diagnostic Index (TMD-DI).

Number	Questions	Code	Filling instructions
1	Do you have headache?		Fill in code with 0=never 1=sometimes 2=often 3=always
2	Do you feel pain when closing and opening mouth?		
3	Do you have joint trismus when getting up in the morning?		
4	Do you feel pain around neck?		
5	Do you have tinnitus?		
6	Do you clench your teeth when worried?		
7	Do you clench your teeth when in anger?		
8	Do you clench your teeth when concentrating?		
<i>Total score</i> Total score: 0–24 Total score ≤3: TMD symptom code = 0 (TMD negative) Total score >3: TMD code = 1 (TMD positive)			

Table 2. The modified Fonseca’s Anamnestic Index.

Number	Questions	Code	Filling instructions
1	Have you noticed noise in your temporomandibular joints while chewing or opening your mouth?		Fill in code with 0=never 1=sometimes 2=often 3=always
2	Do you have habits of clenching or grinding your teeth?		
3	On whether you consider yourself a tense (nervous) person, please answer the following questions:		
	A. Do you sweat excessively (e.g. sweaty hands) even when it is not hot, or without physical activity?*		
	B. Do you feel changes in cardiac activity even without physical activity (e.g. increased or weakened heart rate)?*		
	C. Will you become easily angry because of trivial things?*		
	D. Will you become impatient when experiencing delays (e.g. in traffic jams or when waiting for something)?*		

*Modification to questionnaires to assess stress.

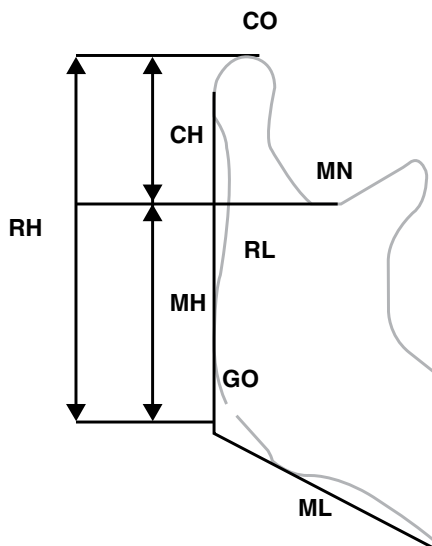


Figure 1. Landmark points of vertical mandibular symmetry according to Kjellberg’s technique.

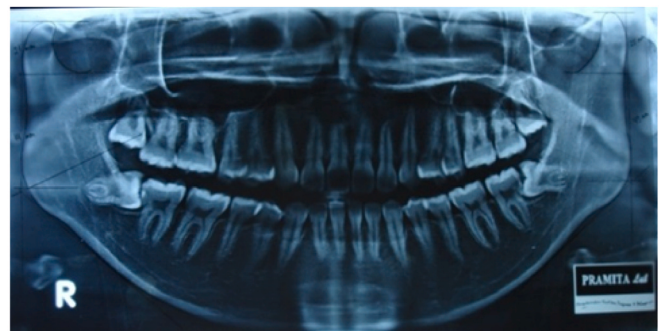

Figure 2. The measurement of panoramic radiograph that used in this study.

process). RH is the distance from CO to the Go’ (the reflection of subdivision tangent from ramus and corpus mandibular to the ramus borderline). In order to obtain vertical mandibular symmetry based on the ratio of condylar and ramus height (Kjellberg’s technique), the numerator should be smaller

than the value resulting from the division of CH and RH/MH regardless of whether it corresponds to the right or left joint. The formula is as follows:

$$\text{Kjellberg symmetry index} = \frac{\left(\frac{\text{CH}}{\text{RH}_A}\right)}{\left(\frac{\text{CH}}{\text{RH}_B}\right)}$$

To determine the random error, inter-rater (T.B. and E.S.) and intra-rater (E.S. under supervised of T.B.) measurements of variables in this study were randomly done from 20 panoramic radiographs. The validity and reliability, measured using Cohen’s κ , showed moderate agreement for inter-rater measurements between T.B and E.S ($\kappa=0.538$) whilst intra-rater measurements from E.S that repeated the measurements 1 week after the first examination and blinded to the initial values ($\kappa=0.674$). Finally, this study used intra-rater measurement as reference data for assessing vertical mandibular symmetry. Cronbach’s alpha analysis was used to provide reliability measurements of questionnaires in analysing items and total scores in the modified Fonseca’s Anamnestic Index ($p>0.05$). However, the point related to clenching or grinding was omitted as it failed to show the validity and reliability of criteria ($p=0.023$). Then any information regarding FAI was only collected for additional information and the TMD-DI used as early screening for analyzing the TMD symptom^{20,21}. Significance of association between TMD symptoms and vertical mandibular symmetry (or asymmetry) was evaluated using a chi-squared test, with assumed significance at $p < 0.05$. All statistical analyses were performed using SPSS, version 18.0 (SPSS, Inc., Chicago, IL, USA).

Results

From 106 young adult orthodontic patients (mean \pm SD, 21.9 \pm 2.0 years old), TMD symptoms were present in 24.53% (n=26) of patients with vertical mandibular symmetry and in 36.79% (n=39) with vertical mandibular asymmetry. On the other hand, 16.04% (n=17) of patients with vertical mandibular symmetry and 22.64% (n=24) with vertical mandibular asymmetry had no TMD symptoms (Table 3). There was no significant difference ($p=0.520$) in the occurrence of TMD symptoms based on vertical mandibular symmetry (Table 3).

Dataset 1. All radiographic images taken of the patients

<http://dx.doi.org/10.5256/f1000research.14522.d205359>

Answers to the original Indonesian language questionnaire are also present.

Table 3. The difference in temporomandibular joint disorder (TMD) symptoms based on vertical mandibular symmetry.

Vertical mandibular symmetry $\leq 93.7\%$	TMD		P-value
	Negative	Positive	
Symmetry	17 16.04%	26 24.53%	0.520
Asymmetry	24 22.64%	39 36.79%	

Dataset 2. Vertical mandibular symmetry measurements using Kjellberg’s technique, alongside responses to each questionnaire

<http://dx.doi.org/10.5256/f1000research.14522.d205360>

A key is present in the “Questionnaires” sheet.

Discussion

The most frequent TMD symptoms include joint noises, followed by reduced mandibular mobility, muscular pain and joint pain. TMJ status is an important factor to consider in orthodontic diagnosis because related to imbalance occlusion and the development of mandibular asymmetry^{3,7}. A previous study suggested that MRI or arthrography could be used as a valuable radiographic assessment in analyzing condylar hyperplasia or discus displacement in mandibular asymmetry and TMJ²². The assessment of posteroanterior cephalometric variables could be used as a key factor for evaluating the presence of unilateral TMD²³. TMD signs and symptoms with multifactorial etiologies have been reported as a risk factor in patients with mandibular asymmetry that had menton deviations in Indonesia based on postero-anterior radiography^{8,20}. In the early detection of mandibular asymmetry related to TMJ disharmony, panoramic radiography is routinely used in the clinic for orthodontic purposes, compared to bilateral tomography of TMJ and postero-anterior radiography. This technique allows a bilateral view and adequate information on vertical and horizontal measurements as early diagnostic evaluation of mandibular asymmetry because it focus mainly on intercondylar asymmetries and gonial angle measurements^{24–28}. Previous studies about panoramic radiography reported that horizontal measurements of anatomic landmarks in the panoramic radiograph tend to be particularly unreliable because of the nonlinear variation in magnification at different object depths, whereas vertical and angular measurements are acceptable, provided the patient’s head is positioned properly^{24,25,28,29}. This study used Kjellberg’s technique because it is easier to identify the condylar height using this technique than Habets’ method in vertical mandibular symmetry assessment. Habets’ method is more complicated when making reference points of the most lateral point of the condyle due to variation in the condylar anatomy^{16,17,29}.

Early detection of TMD in malocclusion, especially related to mandibular asymmetry before establishing orthodontic therapy, is mandatory for interdisciplinary approaches for any dentofacial treatment nowadays^{2,11,30,31}. Some questionnaires can be used as a tool to achieve early detection of TMD. Fonseca’s Anamnestic Index has frequently been used to classify individuals according to TMD severity category, from no TMD to mild, moderate and severe TMD, to screen TMDs in Brazilian women with regards to anxiety as a stress factor¹⁹. The TMD-DI was developed by Himawan *et al.* in 2006, has been applied in the study the characteristics of TMD and other risk factors in the Indonesian society^{8,18,20,21}. In our study, we modify the questions regarding anxiety as stress factor to detect the severity of TMD symptom. In validity and reliability analysis, There was a question regarding clenching and grinding habit was eliminated due to no significant difference in validity and reliability analysis, so this study executed to analyze the TMD symptom based on FAI data. Eventhough this study only used the TMD-DI, there were a higher prevalence of TMDs in both

of symmetry and asymmetry vertical mandibular of these young adult orthodontic patients (mean age \pm SD, 21.9 \pm 2.0 years old). Based on the aforementioned goal of orthodontic treatment, the clinician should be aware of TMD symptoms in orthodontic treatment related to functional efficiency. However, the differences in pain threshold might be a distraction factor while answering the questions to assess TMD symptom. Then, the proper clinical examination of the temporomandibular joint should be considered in orthodontic patients.

Fundamentally, orthodontic treatment should create a balanced and stomatognathic system, especially the temporomandibular joint. One element of this balance is craniofacial symmetry, which is frequently subject to discussion between clinicians and is the subject of multiple different studies in the last decades^{2,11,12}. Although perfect craniofacial symmetry does not exist in nature, gross abnormalities in symmetry are considered as a major cause of non-dental pain in the orofacial pain region^{10,12,32}. The distribution of TMD symptoms is higher than that of non-TMD symptoms in orthodontic patients with and without vertical mandibular symmetry. However, there was no significant difference ($p=0.502$) in TMD symptoms based on the presence or absence of vertical mandibular symmetry (Table 3) since TMD the etiology of TMD is multidimensional³³ and asymmetry of condylar width, height and length as common features in TMD based on 3D-computed tomography^{34,35}. Indonesia, as a developing country, still uses panoramic digital radiography as initial evidence for planning early orthodontic intervention and avoiding the progression of asymmetries³⁶.

According to McNamara, orthodontic treatment performed during adolescence does not alter TMD risk, as TMD with mandibular asymmetry may increase with age, with no evidence originating during orthodontic treatment³¹. This condition is due to the asymmetrical function and activity of the jaws, and the different development of the right and left sides of the mandible. The morphology of the condyle on the deviated side differs from the non-deviated side in mandibular asymmetry, indicating the association between asymmetrical jaw function and joint remodeling, based on 3D-cone beam computerized tomography^{34,35}. The present cross-sectional study concerning mandibular symmetry and TMD in young adult orthodontic patients in North Sumatra indicates that asymmetry has been an adaptive response to functional demands because the mandible adapts to mandibular deviations. The modelling of condyle and glenoid fossae, as well as higher appositional growth in the gonion region during jaw function, will influence skeletal and dental pattern in later adulthood.

It is vital for any clinician who is involved in altering the patient's dentofacial appearance and stomatognathic function to consider the mandibular symmetry and TMJ function, whether through orthodontics, facial growth modification, corrective jaw surgery or any aesthetic dentistry. In the future, although the result in Table 3 showed a non-significant correlation, the TMD-DI as early screening for TMD might require panoramic radiography with postero-anterior radiography or 3D-cone beam computerized tomography to analyze the complexity of TMD development and mandibular asymmetry. In this study, the orthodontic patients presented with complex

stomatognathic problems, such as missing posterior teeth which regardless the missing duration. This condition could affect the development of TMD symptoms and vertical mandibular asymmetry; this matches the study by Halicioglu *et al.*, which reported a slight difference in the vertical mandibular symmetry index was found in patients with early unilateral mandibular first molar extractions³⁷.

Mandibular asymmetry and TMD are two common features associated with increased bilateral asymmetry in morphological traits which might involve environmental and/or genetic stresses as etiologies in breakdown in developmental homeostasis. The etiopathogenesis of TMD, which is a common feature in mandibular asymmetry, is poorly understood, because the complexity of biomechanical, neuromuscular, bio-psychosocial and biological factors has contributed to this disorder^{6,33}. Clinicians should note that the complexity of dentofacial variation in orthodontic patients indicates in part why most treatment approaches for malocclusions with TMD are directed to the symptoms rather than to etiology. However, a combination of questionnaires (as diagnostic indexes) and radiography analysis of predominantly vertical or horizontal mandibular asymmetries indicates that susceptibility to fluctuating asymmetry is increasing³². In the future, some translational approaches with the identification of molecular regulators of cell proliferation in the condylar cartilage, coupled with these phenomena, might carry this finding into the clinical setting. Expanding the fields of phenomics and genomic medicine to understand why asymmetric function occurs is required to achieve personalized orthodontic treatment in young orthodontic patients³⁸. Stress might also have a role in the appearance of developmental disorders and required comprehensive diagnostic tools^{11,19,33}.

Conclusions

TMD symptoms appear common in the studied young adult orthodontic patients from North Sumatra, but no significant association was observed between vertical mandibular asymmetry and symptoms of TMD. Further studies on the development of TMD, mandibular asymmetry and treatment planning for growing patients are suggested, using longitudinal and transitional approaches.

Data availability

Dataset 1. All radiographic images taken of the patients. Answers to the original Indonesian language questionnaire are also present. DOI: [10.5256/f1000research.14522.d205359](https://doi.org/10.5256/f1000research.14522.d205359)³⁹.

Dataset 2. Vertical mandibular symmetry measurements using Kjellberg's technique, alongside responses to each questionnaire. A key is present in the "Questionnaires" sheet. DOI: [10.5256/f1000research.14522.d205360](https://doi.org/10.5256/f1000research.14522.d205360)⁴⁰.

Competing interests

No competing interests were disclosed.

Grant information

The author(s) declared that no grants were involved in supporting this work.

Acknowledgements

The authors wish to thank all the participants in the study, and Derek Diong and Tommy Kwan for their technical

assistance in organizing the samples of the study, as well as Dr Putri Eyaner of Faculty of Medicine, Universitas Sumatera Utara, for the statistical analysis.

References

- Ingevall B: **Functionally optimal occlusion: the goal of orthodontic treatment.** *Am J Orthod.* 1976; **70**(1): 81–90.
[PubMed Abstract](#) | [Publisher Full Text](#)
- Conti AC, Olttramari PV, Navarro Rde L, *et al.*: **Examination of temporomandibular disorders in the orthodontic patient: a clinical guide.** *J Appl Oral Sci.* 2007; **15**(1): 77–82.
[PubMed Abstract](#) | [Publisher Full Text](#) | [Free Full Text](#)
- Agrawal M, Agrawal JA, Nanjannawar L, *et al.*: **Dentofacial Asymmetries: Challenging Diagnosis and Treatment Planning.** *J Int Oral Health.* 2015; **7**(7): 128–31.
[PubMed Abstract](#) | [Free Full Text](#)
- Severt TR, Proffit WR: **The prevalence of facial asymmetry in the dentofacial deformities population at the University of North Carolina.** *Int J Adult Orthodon Orthognath Surg.* 1997; **12**(3): 171–176.
[PubMed Abstract](#)
- Naugler CT, Ludman MD: **Fluctuating asymmetry and disorders of developmental origin.** *Am J Med Genet.* 1996; **66**(1): 15–20.
[PubMed Abstract](#) | [Publisher Full Text](#)
- Dong Y, Wang XM, Wang MQ, *et al.*: **Asymmetric muscle function in patients with developmental mandibular asymmetry.** *J Oral Rehabil.* 2008; **35**(1): 27–36.
[PubMed Abstract](#) | [Publisher Full Text](#)
- Noh JY, Lee JY: **Relationship between Mandibular Asymmetry and Temporomandibular Disorders.** *J Oral Med Pain.* 2014; **39**(3): 100–106.
[Publisher Full Text](#)
- Purbianti M, Purwanegara MK, Kushandy L, *et al.*: **Prediction of Mandibulofacial Asymmetry using Risk Factor Index and Model of Dentocranofacial Morphological Pattern.** *J Int Dent Med Res.* 2016; **9**(3): 195–201.
[Reference Source](#)
- Buranastidporn B, Hisano M, Soma K: **Temporomandibular joint internal derangement in mandibular asymmetry. What is the relationship?** *Eur J Orthod.* 2006; **28**(1): 83–88.
[PubMed Abstract](#) | [Publisher Full Text](#)
- Bhat S: **Etiology of temporomandibular disorders: the journey so far.** *Int Dent SA.* 2010; **12**(4): 88–92.
[Reference Source](#)
- Bourzgui F, Aghoutan H, Diouy S: **Craniomandibular disorders and mandibular reference position in orthodontic treatment.** *Int J Dent.* 2013; **2013**: 890942.
[PubMed Abstract](#) | [Publisher Full Text](#) | [Free Full Text](#)
- Sharma S, Gupta DS, Pal US, *et al.*: **Etiological factors of temporomandibular joint disorders.** *Natl J Maxillofac Surg.* 2011; **2**(2): 116–9.
[PubMed Abstract](#) | [Publisher Full Text](#) | [Free Full Text](#)
- Sugiaman DH, Himawan LS, Fardaniah S: **Relationship of Occlusal Schemes with the occurrence of Temporomandibular disorders.** *J Dent Indones.* 2011; **18**(3): 63–67.
[Publisher Full Text](#)
- Habets LL, Bezuur JN, Naeiji M, *et al.*: **The Orthopantomogram, an aid in diagnosis of temporomandibular joint problems. II. The vertical symmetry.** *J Oral Rehabil.* 1988; **15**(5): 465–71.
[PubMed Abstract](#) | [Publisher Full Text](#)
- Kjellberg H, Ekstutbe A, Kiliaridis S, *et al.*: **Condylar height on panoramic radiographs. A methodologic study with a clinical application.** *Acta Odontol Scand.* 1994; **52**(1): 43–50.
[PubMed Abstract](#) | [Publisher Full Text](#)
- Fuentes R, Engelke W, Bustos L, *et al.*: **Reliability of Two Techniques for Measuring Condylar Asymmetry with X-Rays.** *Int J Morphol.* 2011; **29**(3): 694–701.
[Publisher Full Text](#)
- Iturriaga V, Navarro P, Cantin M, *et al.*: **Prevalence of Vertical Condylar Asymmetry of the Temporomandibular Joint in Patients with Signs and Symptoms of Temporomandibular Disorders.** *Int J Morphol.* 2012; **30**(1): 315–321.
[Publisher Full Text](#)
- Himawan LS, Kusdhany L, Ismail I: **Diagnostic index for temporomandibular disorder in Indonesia.** *Thai J Oral Maxillofac Surg.* 2006; **20**(2): 104–110.
- Campos JA, Carrascosa AC, Bonafé FS, *et al.*: **Severity of temporomandibular disorders in women: validity and reliability of the Fonseca Anamnestic Index.** *Braz Oral Res.* 2014; **28**(1): 16–21.
[PubMed Abstract](#) | [Publisher Full Text](#)
- Boel T, Sofyanti E, Sufarnap E: **Analyzing Menton Deviation in Posteroanterior Cephalogram in Early Detection of Temporomandibular Disorder.** *Int J Dent.* 2017; **2017**: 5604068.
[PubMed Abstract](#) | [Publisher Full Text](#) | [Free Full Text](#)
- Tanti I, Himawan LS, Kusdhany L: **Development of Questionnaire to Determine the Etiology of Temporomandibular Disorders.** *Int J Clin Prev Dent.* 2014; **10**(2): 103–108.
[Publisher Full Text](#)
- Westesson PL, Tallents RH, Katzberg RW, *et al.*: **Radiographic assessment of asymmetry of the mandible.** *AJNR Am J Neuroradiol.* 1994; **15**(5): 991–999.
[PubMed Abstract](#)
- Almășan OC, Băciuț M, Hedeșiu M, *et al.*: **Posteroanterior cephalometric changes in subjects with temporomandibular joint disorders.** *Dentomaxillofac Radiol.* 2013; **42**(1): 20120039.
[PubMed Abstract](#) | [Publisher Full Text](#) | [Free Full Text](#)
- Kambylafkas P, Murdock E, Gilda E, *et al.*: **Validity of panoramic radiographs for measuring mandibular asymmetry.** *Angle Orthod.* 2006; **76**(3): 388–393.
[PubMed Abstract](#)
- Van Elslande DC, Russett SJ, Major PW, *et al.*: **Mandibular asymmetry diagnosis with panoramic imaging.** *Am J Orthod Dentofacial Orthop.* 2008; **134**(2): 183–192.
[PubMed Abstract](#) | [Publisher Full Text](#)
- Hazan-Molina H, Molina-Hazan V, Schendel SA, *et al.*: **Reliability of panoramic radiographs for the assessment of mandibular elongation after distraction osteogenesis procedures.** *Orthod Craniofacial Res.* 2011; **14**(1): 25–32.
[PubMed Abstract](#) | [Publisher Full Text](#)
- Silvestrini-Biavati F, Ugolini A, Laffi N, *et al.*: **Early diagnostic evaluation of mandibular symmetry using orthopantomogram.** *Indian J Dent Res.* 2014; **25**(2): 154–9.
[PubMed Abstract](#) | [Publisher Full Text](#)
- Akcam MO, Altioğ T, Özdiğer E: **Panoramic radiographs: a tool for investigating skeletal pattern.** *Am J Orthod Dentofac Orthop.* 2003; **123**(2): 175–181.
[PubMed Abstract](#) | [Publisher Full Text](#)
- Hirpara N, Jain S, Hirpara VS, *et al.*: **Comparative Assessment of Vertical Facial Asymmetry Using Posteroanterior Cephalogram and Orthopantomogram.** *J Biomed Sci.* 2017; **6**(1).
[Publisher Full Text](#)
- Almășan OC, Băciuț M, Almășan HA, *et al.*: **Skeletal pattern in subjects with temporomandibular joint disorders.** *Arch Med Sci.* 2013; **9**(1): 118–126.
[PubMed Abstract](#) | [Publisher Full Text](#) | [Free Full Text](#)
- McNamara JA Jr: **Orthodontic treatment and temporomandibular disorders.** *Oral Surg Oral Med Oral Pathol Oral Radiol Endod.* 1997; **83**(1): 107–117.
[PubMed Abstract](#) | [Publisher Full Text](#)
- Chia MSY, Naini FB, Gill DS: **The Aetiology, Diagnosis and Management of Mandibular Asymmetry.** *Orthod Updat.* 2008; 44–52.
[Reference Source](#)
- Chisnoiu AM, Picos AM, Popa S, *et al.*: **Factors involved in the etiology of temporomandibular disorders - a literature review.** *Clujul Med.* 2015; **88**(4): 473–8.
[PubMed Abstract](#) | [Publisher Full Text](#) | [Free Full Text](#)
- Yáñez-Vico RM, Iglesias-Linares A, Torres-Lagares D, *et al.*: **Association between condylar asymmetry and temporomandibular disorders using 3D-CT.** *Med Oral Patol Oral Cir Bucal.* 2012; **17**(5): e852–8.
[PubMed Abstract](#) | [Publisher Full Text](#) | [Free Full Text](#)
- Lin H, Zhu P, Lin Y, *et al.*: **Mandibular asymmetry: a three-dimensional quantification of bilateral condyles.** *Head Face Med.* 2013; **9**: 42.
[PubMed Abstract](#) | [Publisher Full Text](#) | [Free Full Text](#)
- Lemos AD, Katz CR, Heimer MV, *et al.*: **Mandibular asymmetry: A proposal of radiographic analysis with public domain software.** *Dental Press J Orthod.* 2014; **19**(3): 52–58.
[PubMed Abstract](#) | [Publisher Full Text](#) | [Free Full Text](#)
- Halicioğlu K, Celikoglu M, Buyuk SK, *et al.*: **Effects of early unilateral mandibular first molar extraction on condylar and ramal vertical asymmetry.** *Eur J Dent.* 2014; **8**(2): 178–183.
[PubMed Abstract](#) | [Publisher Full Text](#) | [Free Full Text](#)
- Moreno Uribe LM, Miller SF: **Genetics of the dentofacial variation in human malocclusion.** *Orthod Craniofac Res.* 2015; **18** Suppl 1: 91–99.
[PubMed Abstract](#) | [Publisher Full Text](#) | [Free Full Text](#)
- Sofyanti E, Boel T, Soegiharto B, *et al.*: **Dataset 1 in: Analyzing of TMD symptom and Vertical Mandibular Symmetry in Young Adult Orthodontic Patients at Dental Hospital Universitas Sumatera Utara.** *F1000Research.* 2018.
[Data Source](#)
- Sofyanti E, Boel T, Soegiharto B, *et al.*: **Dataset 2 in: Analyzing of TMD symptom and Vertical Mandibular Symmetry in Young Adult Orthodontic Patients at Dental Hospital Universitas Sumatera Utara.** *F1000Research.* 2018.
[Data Source](#)

Open Peer Review

Current Referee Status:



Version 1

Referee Report 18 June 2018

doi:10.5256/f1000research.15809.r34686



Ashok Karad

Smile Care, Mumbai, Maharashtra, India

Temporomandibular disorders (TMD) in many patients constitute one of the most frequent causes of non-dental pain in the orofacial region. It is universally accepted that the etiology of TMD is multifactorial, including the structural factors such as mandibular asymmetry. However, a mild degree of asymmetry in the craniofacial region is common in humans, including in individuals with a normal facial appearance. These patients often present with complain of impaired facial appearance and occlusal malfunction, which underlines the importance of this subject. The literature shows that the Temporomandibular joint internal derangement is also associated with mandibular asymmetry. Nevertheless, how skeletal discrepancies in mandibular asymmetry relate to TMJ disorders is still debatable.

This article by Ervina Sofyanti et al is a great step towards evaluating the association between TMD symptoms and vertical mandibular asymmetry in 106 young adult orthodontic patients in North Sumatra, Indonesia. The results of this study show that there is no significant correlation between vertical mandibular asymmetry and TMD symptoms.

For better clarity and understanding, especially for the readers who are new to this subject, it would be appropriate if the authors could provide more details on Kjellberg's technique in the 'Methods' section. To enhance it further, it should include the exclusion criteria as well.

Modern dental practice is focused on individualized diagnosis and treatment planning. Considering extreme variations in morphological and functional characteristics of an individual patient, it would be interesting to design a study involving these factors to fine-tune the results. This is because presence or absence of functional disturbances determines the discrepancy at the joint level in sagittal, vertical and transverse planes.

The authors have done well in this interesting research work.

Is the work clearly and accurately presented and does it cite the current literature?

Yes

Is the study design appropriate and is the work technically sound?

Yes

Are sufficient details of methods and analysis provided to allow replication by others?

Yes

If applicable, is the statistical analysis and its interpretation appropriate?

Yes

Are all the source data underlying the results available to ensure full reproducibility?

Yes

Are the conclusions drawn adequately supported by the results?

Yes

Competing Interests: No competing interests were disclosed.

I have read this submission. I believe that I have an appropriate level of expertise to confirm that it is of an acceptable scientific standard.

Author Response 23 Jun 2018

Ervina Sofyanti, Department of Orthodontics, Faculty of Dentistry, Indonesia

Dear Dr. Karad,

Thank you very much for your kind assistance in reviewing our manuscript and valuable insight for our future work. As Dr. Narmada's comment also about the *Kjellberg's* technique, we will revise and update the material and method section.

Competing Interests: No competing interests were disclosed

Referee Report 12 June 2018

doi:[10.5256/f1000research.15809.r34685](https://doi.org/10.5256/f1000research.15809.r34685)



Farhad B. Naini¹, **Ashraf Messiha**²

¹ St George's NHS Foundation Trust, London, UK

² St George's Hospital & Medical School, London, UK

The article by Sofyanti et al. regarding the potential correlation between symptoms of temporomandibular joint dysfunction/disorder (TMD) and vertical mandibular symmetry is timely. 106 young adults referred for orthodontic treatment were questioned formally about TMD symptoms, and their responses correlated with objective evaluation of their orthopantomographs (OPTs). Of the 63 patients confirmed as having some degree of vertical mandibular asymmetry, and presumably requiring orthodontic treatment, 39 presented with symptoms of TMD, and 24 did not have any symptoms of TMD. The conclusion of the study was that there does not appear to be a significant association between vertical mandibular asymmetry and TMD symptoms.

The conclusion of this investigation is not surprising. All else being equal, mandibular asymmetries without functional problems would logically not lead to any greater likelihood of TMD symptoms than the rest of the population. Though TMD may be multifactorial in origin, psychosocial stress appears to be a common thread. Patients with excellent dental occlusions may develop TMD, particularly during stressful periods in their lives, whereas many patients with quite complex malocclusions may never develop TMD.

Nevertheless, malocclusions linked to parafunctional activities or leading to functional occlusal problems may demonstrate a higher preponderance to TMD. As such, it would be very interesting to repeat this study looking at the effects of mandibular lateral displacements (functional shifts) and any potential correlations with TMD. True skeletal asymmetries without lateral mandibular displacements are less likely to lead to TMD, but lateral displacements and associated functional problems may be of greater concern. Additionally, it would be potentially interesting to evaluate the prevalence of TMD comparing patients with predominantly vertical mandibular asymmetries (hemimandibular hyperplasia) and those with predominantly horizontal mandibular asymmetries (hemimandibular elongation).

Another interesting question is the correlation of the variety of TMD symptoms in relation to specific malocclusions, whether dental or skeletal. Different TMD symptoms point to different aetiological factors. For example, with TM joint noises, clicking tends to be a sign of disc displacement/internal derangement, whereas crepitus may be due to arthritic-type changes. In the same way, myogenic pain, or trismus, may have diverse aetiology. It is worth exploring the potential links of dentoskeletal malocclusions not only to TMD as an all-encompassing diagnosis, but to the different symptoms comprising the diagnosis of TMD.

It should also be noted that there is improved clinical awareness, and enhanced imaging availability, with t1 or t2-weighted magnetic resonance imaging (MRI) used to establish more accurately the aetiology and nature of a dysfunctioning joint. Therefore, in cases where asymmetry directly results from previous trauma, or with developmental, congenital, and hypermobility disorders, it is disc position that seems to be the determining factor in the overall stability of the mechanics of the joint. Disruption, or disc displacement, leads to various degrees of arthrogenic and neurogenic symptoms of TMD, as opposed to myogenic TMD that seems to be a common symptom amongst the anxious and stressed TMD sufferer.

The authors should be congratulated on a thought-provoking article.

Is the work clearly and accurately presented and does it cite the current literature?

Yes

Is the study design appropriate and is the work technically sound?

Yes

Are sufficient details of methods and analysis provided to allow replication by others?

Yes

If applicable, is the statistical analysis and its interpretation appropriate?

Yes

Are all the source data underlying the results available to ensure full reproducibility?

Yes

Are the conclusions drawn adequately supported by the results?

Yes

Competing Interests: No competing interests were disclosed.

Referee Expertise: FN: Facial aesthetic analysis, orthognathic and craniofacial surgery, complex orthodontics. AM: TMJ surgery, including TMJ replacements, orthognathic surgery , surgery for obstructive sleep apnoea , dynamic and static facial reanimation, full range of surgery for facial deformity and facial aesthetic surgery

We have read this submission. We believe that we have an appropriate level of expertise to confirm that it is of an acceptable scientific standard.

Author Response 23 Jun 2018

Ervina Sofyanti, Department of Orthodontics, Faculty of Dentistry, Indonesia

Dear Dr Farhad and Dr. Messiha,

Thank you very much for your kind assistance in reviewing our manuscript and providing us with valuable advices for the manuscript itself as well as for our future work. To respond with the reviews that have been provided, please allow us to comment as follows:

1. **"It would be very interesting to repeat this study looking at the effects of mandibular lateral displacements (functional shifts) and any potential correlations with TMD. True skeletal asymmetries without lateral mandibular displacements are less likely to lead to TMD, but lateral displacements and associated functional problems may be of greater concern"**.

Thank you very much for this valuable insight. The authors have noted the concern of the presence of lateral displacement to the occurrence of TMD for our future work. This was not included in this project as this was just an initial pilot project.

2. **"It would be potentially interesting to evaluate the prevalence of TMD comparing patients with predominantly vertical mandibular asymmetries (hemimandibular hyperplasia) and those with predominantly horizontal mandibular asymmetries (hemimandibular elongation)"**.

We thank you again for this valuable insight and definitely will be considered in our future work.

3. **"Therefore, in cases where asymmetry directly results from previous trauma, or with developmental, congenital, and hypermobility disorders, it is disc position that seems to be the determining factor in the overall stability of the mechanics of the joint"**.

In this study, the possible influence of any history of traumatic facial injury as well as congenital disease have been eliminated. And with regards to the position of the disc, this was not considered in this study but will surely be considered for our future work. The possible use of CBCT may perhaps assist our future work in determining disc position.

Competing Interests: No competing interests were disclosed

Referee Report 11 June 2018

doi:10.5256/f1000research.15809.r34688

**Ida Bagus Narmada**

Faculty of Dental Medicine, Airlangga University, Surabaya, Indonesia

Overall your paper is very good and well done, but here are some minor suggestions:

- Could you please state more about the Kjellberg's technique, it is not well described in the methods section of your paper?
- Could you please inform about the study design (descriptive or analytic study)?
- Could you please inform about the sampling method and how to determine the sample size?
- You only mention the inclusion criteria, what about the exclusion criteria? Please mention it.
- Please mention and inform who examined the patient? How to examine the patient? Please explain.
- How about the competency of the examiner? How many people? How to calibrate each examiner's perception. Please mention also who is in charge for radiographic image interpretation?

Is the work clearly and accurately presented and does it cite the current literature?

Yes

Is the study design appropriate and is the work technically sound?

Yes

Are sufficient details of methods and analysis provided to allow replication by others?

Yes

If applicable, is the statistical analysis and its interpretation appropriate?

Yes

Are all the source data underlying the results available to ensure full reproducibility?

Yes

Are the conclusions drawn adequately supported by the results?

Yes

Competing Interests: No competing interests were disclosed.

I have read this submission. I believe that I have an appropriate level of expertise to confirm that it is of an acceptable scientific standard.

Author Response 23 Jun 2018

Ervina Sofyanti, Department of Orthodontics, Faculty of Dentistry, Indonesia

Dear Dr. Narmada,

Thank you very much for your kind assistance in reviewing our manuscript. According to your some minor suggestions, we have revised within material and method section.

This is descriptive analytic study with cross-sectional approach and selection of sample with simple random sampling. In radiography analysis, we did inter-rater and intra-rater examiner.

TB : the consultant in dentomaxillofacial radiograph. ES did the radiographic image interpretation under supervised of TB. We traced the radiography manually according *Kjellberg's* technique as

followed : CH is defined as the distance from CO (the highest point of the condylar head) to the mandibular notch (the deepest point between the coronoid process and the condylar process). RH is the distance from CO to the GO' (the reflection of subdivision tangen from ramus and corpus mandibular to the ramus borderline). In order to obtain vertical mandibular symmetry based on the ratio of condylar and ramus height (Kjellberg's technique).

Competing Interests: No competing interests were disclosed

The benefits of publishing with F1000Research:

- Your article is published within days, with no editorial bias
- You can publish traditional articles, null/negative results, case reports, data notes and more
- The peer review process is transparent and collaborative
- Your article is indexed in PubMed after passing peer review
- Dedicated customer support at every stage

For pre-submission enquiries, contact research@f1000.com

F1000Research