

Original Article

Evaluating systemic administration effect of propranolol on osseointegration around titanium implants: A histomorphometric study in dogs

Mohammad Tavakoli¹, Mohammad Jafari Farshami², Nakisa Torabinia³, Jaber Yaghini¹, Samaneh Shams⁴

¹Dental Implant Research Center, Department of Periodontology, Dental Research Institute, Isfahan University of Medical Sciences, Isfahan, ²Department of Periodontics, Faculty of Dentistry, Qazvin University of Medical Sciences, Qazvin, ³Dental Materials Research Center, Department of Oral and Maxillofacial Pathology, Dental Research Institute, Isfahan University of Medical Sciences, Isfahan, ⁴Dental Research Center, Dental Research Institute, Isfahan University of Medical Sciences, Isfahan, Iran

ABSTRACT

Background: Dental implants are known as a widely accepted and predictable method to replace missing teeth. Many factors, including using a class of drugs, such as β -blockers, can improve the osseointegration of dental implants. This study aimed to investigate the relationship between administering propranolol and osseointegration in dental implants.

Materials and Methods: This experimental animal study was performed on four native male street dogs of 11–13 kg of weight and 16–20 months of age. The specimens underwent teeth extraction. After that, the dogs were randomly divided into two groups. The first group contains two control dogs which would receive oral saline. The second contains two dogs which would receive oral tablets of propranolol daily. After a period of healing, three titanium implants were inserted in each of specimens' left mandibular quadrant, and treatment was resumed with propranolol and saline administration in case and control group, respectively. After 4 weeks, one of control group dogs and one of case group were anesthetized, and dental implants were removed alongside the peripheral bone marrow using a trephine drill. Meanwhile, the other two dogs (1 control and 1 propranolol administered dogs) were anesthetized after 9 weeks of implant placement, and the same procedure was carried out.

Results: Due to the histomorphometric assessment, the mean score of bone implant contact (BIC) in week 4 was significantly higher in case group compared to control one (68.33% vs. 20.22%). In week 9, the mean BIC score was higher in case group compared to control group (68.60% vs. 50.17%); meanwhile, in contrast to week 4, it was not statistically significant. In both case and control groups, the formation of woven and lamellar bone was more significant in week 4 rather than week 9.

Conclusion: Administration of systemic β -blockers can improve dental implants osseointegration process.

Key Words: Beta antagonists, dental implants, osseointegration

Received: 23-Jun-2020
Revised: 27-Feb-2021
Accepted: 01-Jul-2021
Published: 27-Apr-2022

Address for correspondence:
Dr. Jaber Yaghini,
Department of
Periodontology, Dental
Implant Research Center,
School of Dentistry, Isfahan
University of Medical
Sciences, Isfahan, Iran.
E-mail: j_yaghini@dnt.mui.
ac.ir

Access this article online



Website: www.drj.ir
www.drjjournal.net
www.ncbi.nlm.nih.gov/pmc/journals/1480

This is an open access journal, and articles are distributed under the terms of the Creative Commons Attribution-NonCommercial-ShareAlike 4.0 License, which allows others to remix, tweak, and build upon the work non-commercially, as long as appropriate credit is given and the new creations are licensed under the identical terms.

For reprints contact: WKHLRPMedknow_reprints@wolterskluwer.com

How to cite this article: Tavakoli M, Farshami MJ, Torabinia N, Yaghini J, Shams S. Evaluating systemic administration effect of Propranolol on osseointegration around titanium implants: A histomorphometric study in dogs. *Dent Res J* 2022;19:37.

INTRODUCTION

Dental implant is an accepted technique for the treatment of patients with partial or complete edentulism.^[1] Osseointegration of the implant is known as the final goal of implant surgery which is considered one of the long-term implant success factors.^[2] When an implant is inserted into bone cavity, the recovery process will continue to osseointegration point.^[3,4]

Several factors can either enhance or disrupt the osseointegration process.^[5] Factors that enhance the osseointegration process include implant design, chemical composition, implant surface topography, material, shape, and diameter of the implant,^[6] the status of host bone and its intrinsic healing potential,^[7] the mechanical stability and loading conditions,^[8] and pharmacological agents such as simvastatin and bisphosphonate.^[9,10]

Nonspecific β -blockers are a type of systemic drugs with the ability to induce the osseointegration process. Propranolol is a commonly used nonselective β -adrenergic receptor antagonist used to treat hypertension, angina, anxiety, cardiac arrhythmia, hyperthyroidism, essential tremor, and as prophylaxis against migraine, variceal bleeding, and myocardial infarction.^[11]

Intravenous propranolol resulted in significant decreases in cardiac output (-25%) and heart rate (-14%) and increases in total peripheral resistance (28%) and renal vascular resistance (37%).^[12]

Propranolol suppresses bone resorption by inhibiting RANKL-mediated osteoclastogenesis,^[13] resulting in increased bone mass accrual and bone mineral density and reduced risk of osteoporotic fractures.^[14]

Propranolol appears to have significant effects on normal bone and endochondral bone formation in the defect model. Biomechanical studies on nonsurgical animals showed increased strength in propranolol compared to saline-treated rats. Propranolol may systemically stimulate bone metabolism or directly affect osteoblasts through β -adrenergic or membrane-stabilizing mechanisms. This may result from the disinhibition of an osseous metabolic pathway.^[15]

The suppression of β -receptors by β -blockers improves bone accrual by downregulating

osteoclastic proliferation while enhancing collagen production and mineralization.^[13] Moreover, while adrenergic stimulation through β -receptors enhances RANKL and suppresses OPG expression,^[16] β -blockers (i.e., propranolol) have the opposite effect, thus dampening osteoclast differentiation.^[13]

Propranolol enhanced collagen synthesis in bone defects. It could be other reason behind the accelerated bone healing in propranolol-treated rats since collagen production is crucial for bone healing,^[17] and it can be related to the fact that β -antagonists upregulate collagen synthesis through the cAMP-dependant pathway.^[18]

Propranolol increases intestinal absorption and decreases urinary secretion of calcium, phosphorous, and magnesium,^[19] resulting in increased calcium serum levels.^[13]

It was observed that propranolol-treated rats had fewer osteoclasts in their bone defects than saline-treated ones. Propranolol enhanced collagen synthesis in bone defects; meanwhile, it increased mineralization in those defects.^[20]

In an animal study conducted on white albino rats, it was concluded propranolol administration seems to act positively on the osseointegration procedure of stainless-steel bone implants, albeit in a nonstatistically significant manner.^[21]

Other study carried out on rats showed though there were no significant differences in biochemical parameters (alkaline phosphatase, calcium, and phosphor) of groups ($P > 0.05$), yet bone implant connection (BIC) ratios were detected higher in propranolol-treated animals compared to the controls ($P < 0.05$).^[22]

Considering the lack of detailed studies on β -blockers' systemic effect on the osseointegration of titanium implants in the canine jaw, we were inspired to study propranolol's effect on osseointegration around implants in the canine jaw by histomorphometric measures.

MATERIALS AND METHODS

The present study was an experimental animal study performed on dogs. Four native nondomestic street male dogs with 11–13 kg of weight and 16–20 months of age were selected for the study. The dogs were generally healthy with no preexisting systemic

conditions. The inclusion criteria contain systemic health and the absence of any systemic disease. The exclusion criteria included the risk of the dog's life being at stake during the study. This animal study was approved by research and ethics committee of Isfahan university of medical sciences code: (396884). First, the necessary experiments were performed to confirm the dogs' health make sure that the dogs do not suffer from diseases such as rabies. Due to the standard protocol of the veterinarian of Research Center, dogs were vaccinated 2 weeks before the onset of the experiments. The animals were kept in separate cages for 10 days to help them get used to life in confinement. The shed at the dentistry faculty of Isfahan University of Medical Sciences had been washed and disinfected regularly and was equipped with ventilation and sewage facilities. A veterinarian measured the animals' health daily, and in case, the animals' life was at risk, they were excluded from the study for treatment.

Surgical protocol, Stage 1

In the first surgery, the dogs were sedated and subsequently anesthetized. Acepromazine 1% (0.2 cc/kg), ketamine 10% (10 mg/kg), and atropine 0.04 mg/kg were used for anesthetization. Halothane was administered to keep the animals in an anesthetized state. At first, a full-thickness flap was elevated under the left quadrant of the mandibular-premolar region (from the first to the fourth premolar), and the second, third, and fourth premolar teeth were sectioned buccolingually. The roots were extracted individually using periostom to avoid any damage to the bone walls. Finally, the flap was repositioned and sutured with 4-0 nonabsorbable suture. The dogs were randomly divided into two groups: saline administrated group (control) and propranolol administrated group (case). Administration of propranolol oral tablet was initiated in two case dogs (0.2 mg/kg). For two control dogs, oral saline was administered. After a 2-month recovery period, ceftriaxone and oral metronidazole were systemically administered one night before surgery to provide the ground for the second stage of surgery; the placement of implants. This dose of antibiotics provides a 4-day coverage, so the next dose was administered 4 days later to maintain the coverage until the 8th day.

Surgical protocol, Stage 2

In the second stage of surgery, after sedation and administration of anesthesia, a horizontal crestal incision was made at the left mandibular premolar region of each animal, and three identical bone level

implants (SNUCON, Korea) with 4 mm in diameter and 10 mm in length were placed.

Twelve implants were inserted in all dogs (three implants in each one). The flaps were sutured with nonabsorbable suture, and implants were submerged. The animals were then subjected to a soft diet for 14 days, and after that period, the sutures were pulled out. The gingival healing was periodically evaluated, and the remaining teeth were cleaned with ultrasound.

Sample preparation and statistical analysis

Treatment was resumed with the administration of propranolol and saline in the case and control groups, respectively. After 4 and 9 weeks, the dogs were anesthetized, and dental implants were removed alongside the peripheral bone using a 6-mm trephine drill. Samples were immediately stored in 10% formalin solution and subsequently mounted in acrylic blocks. Hard-tissue section tools are used for longitudinal incision with a diameter of 50–200 μ . Samples are mounted and painted on a Lam. The samples were then examined at $\times 40$ magnification by an optical microscope.

BIC of samples was histomorphometrically analyzed using Nillo pathology analyzer software. Two-way ANOVA with a 95% confidence interval was used to compare the data.

RESULTS

The two-way ANOVA test was used to determine the effect of treatment types and the effect of postintervention time interval on BIC. Considering the effect of group treatment, results concluded that treatment type had a significant effect on BIC ($P < 0.001$). As for the effect of postoperative time interval, it was observed that time had a significant effect on mean BIC ($P = 0.022$). Meanwhile, the bilateral effect of treatment type and postoperative elapsed time was also significant. Table 1 presents the mean and standard deviation of BIC(%) at week 4 and 9 respectively.

Due to the significance of the bilateral effect of treatment type and postoperative elapsed time and due to nonnormal distribution of data in each group, the Mann–Whitney test was used. The results as it can be observed in table 2, showed that there is a significant difference among four groups. In the next stage, the four groups were separately compared.

Due to histological evaluation, newly formed bone was mostly of woven type in all samples and

groups at week 4 and mostly of lamellar type in all samples and groups at week 9. Figure 1 demonstrates the comparison between microscopic images of control specimens at week 4 and 9, while figure 2 demonstrates the comparison between microscopic images of case specimens at week 4 and 9.

The overall variation of BIC in the two groups over time is presented in Figure 3.

Figure 4 shows the mean BIC in propranolol treated dogs in both groups.

DISCUSSION

Due to the histomorphometric assessment, the mean score of bone-implant contact (BIC) in week 4 was significantly higher in the case group compared to control one (68.33% vs. 20.22%). In week 9, the mean BIC score was higher in case group compared to control one (68.60% vs. 50.17%) though it was not statistically significant.

Due to histomorphometric evaluation, in all samples and groups, newly formed bone at week 4 was mostly containing woven bone but altered to lamellar type at week 9. This finding is consistent to Berglundh's histologic findings on dogs.^[23]

β_2 -adrenergic has a negative effect on bone modeling; thus, inhibiting this process will have a favorable effect. Pierroz *et al.*^[24] observed mice deficient in β_2 -receptors present decreased bone resorption and increased bone formation. The concomitant absence of β_1 - and β_2 -adrenergic signaling leads to low bone mass and low cancellous and cortical microarchitecture.

Minkowitz *et al.*^[15] showed the beneficial effect of propranolol on bone in a fractured rat model. They concluded that 9 weeks of low-dose propranolol treatment (0.1 mg/kg/day) increased bone formation parameters, and the process occurred at the periosteum and endosteum compartments.

Takeda *et al.*^[25] indicated that propranolol could prevent the loss of vertebral trabecular bone induced by central leptin infusion and ovariectomized (OVX) in young/growing mice. They observed positive expression of $\text{Adr}\beta_2\text{R}$ on rat osteoblasts in $\text{Adr}\beta_2\text{R}$ -deficient mice. Bonnet *et al.* (2008)^[26] compared the effects of low (0.1 mg/kg/day), medium (5 mg/kg/day), or high (20 mg/kg/day) doses of propranolol given 5 days/week for 10 weeks in OVX rats. They observed low-dose propranolol

Table 1: Mean and standard deviation of bone implant contact percent at 4 and 9 weeks postoperatively

Dependent variable: BIC1				
Drug	Time	Mean	SD	n
Propranolol (weeks)	4	68.3333	12.11060	6
	9	68.6000	10.94532	5
	Total	68.4545	11.01239	11
Control (weeks)	4	20.2222	16.32313	9
	9	50.1667	18.99912	6
	Total	32.2000	22.62173	15
Total (weeks)	4	39.4667	28.28141	15
	9	58.5455	17.91850	11
	Total	47.5385	25.85998	26

BIC: Bone implant contact; SD: Standard deviation

Table 2: Mann-Whitney test result

Group (weeks)	Group (weeks)	P
Case 4	Control 4	0.002
Case 4	Case 9	0.854
Case 4	Control 9	0.077
Control 4	Case 9	0.003
Control 4	Control 9	0.009
Case 9	Control 9	0.096

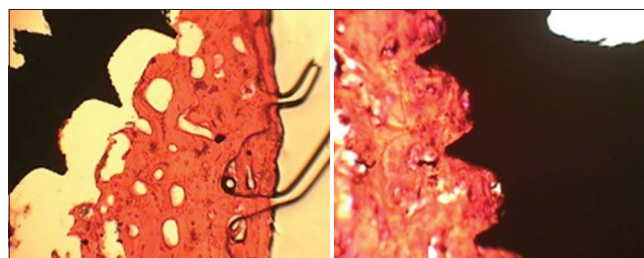


Figure 1: Microscopic images of control specimens at week 4 (left) and week 9 (right) week.




Figure 2: Microscopic images of case specimens at week 4 (left) and week 9 (right).

prevented OVX-induced bone loss by increasing bone formation (+30% of MAR vs. placebo, $P = 0.01$) and decreasing bone resorption (-52% of osteoclast surface on the bone surface vs. placebo, $P = 0.01$). In contrast, medium and high doses of propranolol had a negative effect on heart functions, no significant protective effects on bone mass in OVX rats.

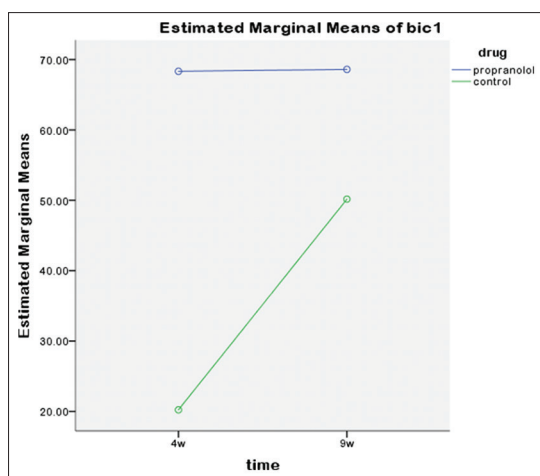


Figure 3: BIC percent variations in case and control groups.

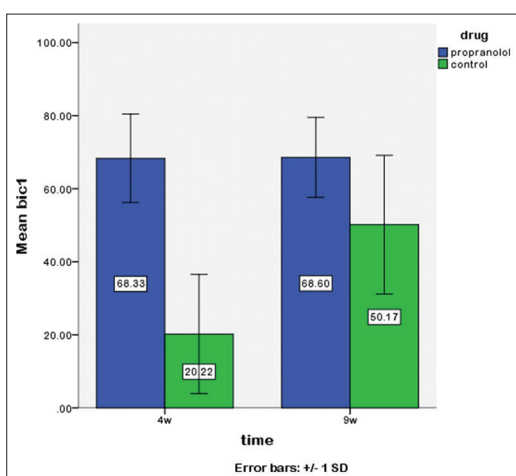


Figure 4: The mean BIC percent in case and control groups at week 4 and 9.

In a study by Al-Subaie *et al.*,^[20] on 24 Sprague–Dawley rats, a unicortical defect was created in the right tibial metaphysis of each rat, and a custom-made titanium implant was placed in the left tibia. Then, animals were assigned into two groups ($n = 12$, each group) and treated daily with either propranolol (5 mg/kg: subcutaneous) or saline for 2 weeks. Then, after killing, the volume of cortical defects (mm^3) and the percentages of newly formed bone in the defects were assessed with microcomputed tomography; bone-implant contact percentage and peri-implant bone volume/tissue volume were assessed by histomorphometry. The results showed 2-week administration of propranolol increased osseointegration by almost 50%, from 42.5% in controls to 73.8% among propranolol-treated ones, which is over two folds higher than the improvements reported for Bone

Morphogenetic Proteins (BMPs) and parathyroid therapy, two drugs that have been used to enhance osseointegration.

In an experimental study by Karanassos *et al.*,^[21] aimed to assess potential positive effect of administrating propranolol on the osseointegration procedure of stainless-steel bone implants, a custom-designed screw was implanted in tibia of 30 adult male albino rats on day 0. Starting on the 1st postoperative day, case group animals (15 rats) received 2.5 mg/kg (1 mg/ml) of propranolol daily intraperitoneally. The control group (15 rats) received the same volume of saline. On day 29, all animals were euthanized, both tibias from each animal were harvested, and the implants' pullout-strength and removal torque were assessed. Propranolol administration seems to act positively on the osseointegration procedure of stainless-steel bone implants, albeit in a nonstatistically significant manner.

The present study also resulted in a significant increase in osseointegration around titanium implants in the propranolol administrated group compared to control one after 4 weeks of implant placement; though after 9 weeks, the difference between the two groups was not significant, probably indicating the decrease of propranolol's effect on osseointegration over time. Due to this result, administrating low-dose propranolol can be beneficial when the clinician plans for early loading of the dental implant.

The present study is the first study conducted to investigate the association of β -blockers with osteointegration in the canine jaw, as an animal model comparable to humans; therefore, the possibility of generalizing the results of the study to human groups was investigated. Besides, propranolol was administered due to the usual treatment protocol, and its effects were studied and compared to the effects of preimplant and postimplant administration of drug in prospective studies.

As with all similar studies, the study at hand has certain limitations as well. A limitation of the study is the fact that an animal model was used. However, regarding the evaluation of bone implant contact of implants in clinical studies is difficult and has several limitations, the animal model chosen in this study, seems as a useful alternative.

CONCLUSION

The results of this study confirmed that administration of low-dose propranolol could have a positive effect

on the mean bone-implant contact, especially in earlier rather than later phases of osseointegration which can be critical in immediate loading of dental implants or in patients with suspicious bone formation.

It is true that the canine bone model shares similarities with the human bone; nonetheless, results derived from experimental studies should be interpreted with caution. It is highly recommended to conduct clinical studies to confirm this relationship and further explore the relevant mechanisms.

Financial support and sponsorship

Nil.

Conflicts of interest

The authors of this manuscript declare that they have no conflicts of interest, real or perceived, financial or nonfinancial in this article.

REFERENCES

- Chrcanovic BR, Albrektsson T, Wennerberg A. Reasons for failures of oral implants. *J Oral Rehabil* 2014;41:443-76.
- Tricio J, Laohapand P, van Steenberghe D, Quirynen M, Naert I. Mechanical state assessment of the implant-bone continuum: A better understanding of the periotest method. *Int J Oral Maxillofac Implants* 1995;10:43-9.
- Raikar S, Talukdar P, Kumari S, Panda SK, Oommen VM, Prasad A. Factors affecting the survival rate of dental implants: A retrospective study. *J Int Soc Prev Community Dent* 2017;7:351-5.
- el Askary AS, Meffert RM, Griffin T. Why do dental implants fail? Part I. *Implant Dent* 1999;8:173-85.
- el Askary AS, Meffert RM, Griffin T. Why do dental implants fail? Part II. *Implant Dent* 1999;8:265-77.
- Jemt T. Failures and complications in 391 consecutively inserted fixed prostheses supported by Brånemark implants in edentulous jaws: A study of treatment from the time of prosthesis placement to the first annual checkup. *Int J Oral Maxillofac Implants* 1991;6:270-6.
- Misch CE. *Contemporary Implant Dentistry*. Amsterdam, Netherlands: Elsevier Health Sciences; 2008.
- Barewal RM, Oates TW, Meredith N, Cochran DL. Resonance frequency measurement of implant stability *in vivo* on implants with a sandblasted and acid-etched surface. *Int J Oral Maxillofac Implants* 2003;18:641-51.
- Morris HF, Ochi S, Crum P, Orenstein IH, Winkler S. AICRG, Part I: A 6-year multicentered, multidisciplinary clinical study of a new and innovative implant design. *J Oral Implantol* 2004;30:125-33.
- Niklaus P, Lang and Jan Lindhe. *Clinical Periodontology and Implant Dentistry*. 6th ed. New Jersey, United States: Wiley-Blackwell; 2015.
- Pantziarka P, Bouche G, Sukhatme V, Meheus L, Rooman I, Sukhatme VP. Repurposing Drugs in Oncology (ReDO)-Propranolol as an anti-cancer agent. *Ecancermedalscience* 2016;10:680.
- Nies AS, McNeil JS, Schrier RW. Mechanism of increased sodium reabsorption during propranolol administration. *Circulation* 1971;44:596-604.
- Rodrigues WF, Madeira MF, da Silva TA, Clemente-Napimoga JT, Miguel CB, Dias-da-Silva VJ, *et al.* Low dose of propranolol down-modulates bone resorption by inhibiting inflammation and osteoclast differentiation. *Br J Pharm* 2012;165:2140-51.
- Bonnet N, Pierroz D, Ferrari SL. Adrenergic control of bone remodeling and its implications for the treatment of osteoporosis. *J Musculoskelet Neuronal Interact* 2008b; 8:94-104.
- Minkowitz B, Boskey AL, Lane JM, Pearlman HS, Vigorita VJ. Effects of propranolol on bone metabolism in the rat. *J Orthop Res* 1991;9:869-75.
- Togari A, Arai M. Pharmacological topics of bone metabolism: The physiological function of the sympathetic nervous system in modulating bone resorption. *J Pharmacol Sci* 2008;106:542-6.
- Bunyaratavej P, Wang HL. Collagen membranes: A review. *J Periodontol* 2001;72:215-29.
- Berg RA, Moss J, Baum BJ, Crystal RG. Regulation of collagen production by the β -adrenergic system. *J Clin Invest* 1981;67:1457.
- Wang X, Wu H, Chao C. Effect of propranolol on calcium, phosphorus, and magnesium metabolic disorders in Graves' disease. *Metabolism* 1992;41:552-5.
- Al-Subaie AE, Laurenti M, Abdallah MN, Tamimi I, Yaghoubi F, Eimar H, *et al.* Propranolol enhances bone healing and implant osseointegration in rats tibiae. *J Clin Periodontol* 2016;43:1160-70.
- Karanassos M, Tsatsalis D, Taitzoglou I, Sarris I, Papadopoulos P, Sayegh F, *et al.* Propranolol administration has a non-statistically significant positive effect on the osseointegration procedure of stainless-steel implants. *International Journal of Mental Health Systems* 2020;10:882-7.
- Tuba TY, Serkan D, Alihan B, Tahir K, Samet T, Onur Evren K. Evaluation of the effects of β -adrenergic receptor-propranolol on osseointegration of the titanium implants. *J Craniofac Surg* 2020;32:783-6.
- Lang NP, Lindhe J, editors. *Clinical Periodontology and Implant Dentistry*. Vol. 2. New Jersey, United States: John Wiley and Sons; 2015.
- Pierroz DD, Bonnet N, Bianchi EN, Boussein ML, Baldock PA, Rizzoli R, *et al.* Deletion of beta-adrenergic receptor 1, 2, or both leads to different bone phenotypes and response to mechanical stimulation. *J Bone Miner Res* 2012;27:1252-62.
- Takeda S, Eleftheriou F, Levasseur R, Liu X, Zhao L, Parker KL, *et al.* Leptin regulates bone formation via the sympathetic nervous system. *Cell* 2002;111:305-17.
- Bonnet N, Benhamou C, Malaval L, Goncalves C, Vico L, Eder V, *et al.* Low dose beta-blocker prevents ovariectomy-induced bone loss in rats without affecting heart functions. *J Cell Physiol* 2008a; 217:819-27.