

# Neuro-Behçet's syndrome with a severe ocular lesion

Dan Han<sup>1</sup>, Bo Ma<sup>3</sup>, Peng Liu<sup>1</sup>, Guogang Luo<sup>2</sup>  
and Wenfeng Song<sup>2</sup>

## Abstract

Behçet's syndrome (BS) is an idiopathic, chronic, relapsing, multisystem, vascular-inflammatory disease. Neuro-Behçet's syndrome (NBS) is a subtype of BS that mainly involves the central nervous system. Because of the heterogeneous involvement of NBS and the limited yearly numbers of new cases of NBS, estimating its course, prognosis, and treatment effect is difficult. Therefore, the efficacy of treatment for any form of NBS is unclear. We experienced a male patient with NBS and severe right uveitis. He received high-dose intravenous methylprednisolone (1000 mg/day) pulse therapy for 3 days. Intravenous injection of cyclophosphamide (400 mg, twice a day) and oral administration of prednisone (40 mg in the morning, 20 mg in the evening) were applied. Uveitis was treated with retrobulbar injection of triamcinolone acetonide (40 mg per week). The patient's response was rapid with improved symptoms and signs. The therapeutic regimen of patients with BS has greatly advanced, leading to evidence-based guidelines. Methylprednisolone pulse therapy is important in treatment of BS. Novel therapeutic options are currently being examined to improve the prognosis of BS. These efforts will undoubtedly shed new light on this complex syndrome.

## Keywords

Neuro-Behçet's syndrome, uveitis, methylprednisolone pulse therapy, maintenance treatment, central nervous system, visual acuity

Date received: 9 October 2018; accepted: 1 March 2019

## Introduction

Behçet's disease, also known as the "Silk Route disease," was first proposed by Hulusi Behçet in 1937.<sup>1</sup> This disease affects multiple systems, including oral aphthae, genital ulcerations, uveitis, vasculitis, neural

<sup>1</sup>Department of Cardiology, The First Affiliated Hospital of Xi'an Jiaotong University, Xi'an, China

<sup>2</sup>Department of Neurology, The First Affiliated Hospital of Xi'an Jiaotong University, Xi'an, China

<sup>3</sup>Department of Ophthalmology, The First Affiliated Hospital of Xi'an Jiaotong University, Xi'an, China

### Corresponding author:

Wenfeng Song, Department of Neurology, No. 277 Yanta West Road, The First Affiliated Hospital of Xi'an Jiaotong University, Xi'an 710061, China.

Email: [wenfeng\\_song@163.com](mailto:wenfeng_song@163.com)



system involvement, and others. Because of the diverse clinical manifestations, the term Behçet's syndrome (BS), rather than a particular disease, is preferred.<sup>2</sup>

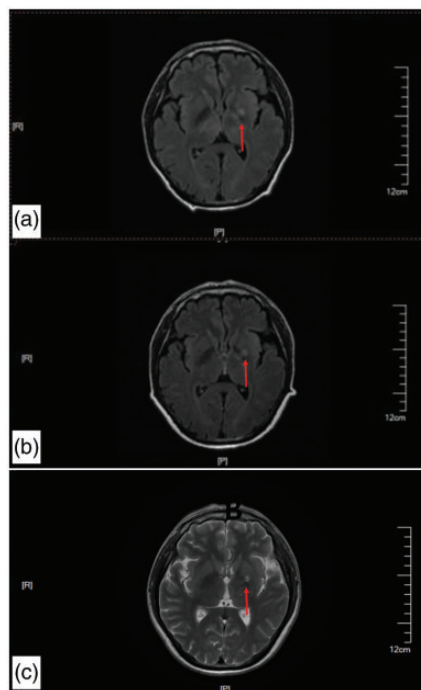
The epidemiology of BS involves geographic spatial variation, and it appears more commonly along the Silk Route extending from the Mediterranean basin to the Far East. BS usually occurs in the third or fourth decade of life, with almost equal sex distribution.<sup>3</sup>

Neuro-Behçet's syndrome (NBS) is a subtype of BS, with a prevalence ranging from 3% to 9%. Patients with NBS manifest with numerous neurological symptoms mainly encompassing cerebral venous sinus thrombosis, central nervous system (CNS) parenchymal involvement, the neuro-psycho-Behçet variant, and others.<sup>4</sup> Cranial magnetic resonance imaging (MRI) is the first-line choice for showing reversible inflammatory parenchymal lesions. Lesions are generally located within the brainstem, sometimes extend to the diencephalon, and occasionally are found within the periventricular and subcortical white matter.<sup>5</sup>

Because of the heterogeneous involvement of NBS and the limited yearly numbers of new cases, evaluating its course, prognosis, and treatment effects is difficult. Therefore, a large challenge remains for reaching criteria for diagnosis and treatment of NBS. We report a patient with NBS and severe right uveitis who responded well to therapeutic regimens. We hope to provide evidence to promote treatment of NBS.

## Case report

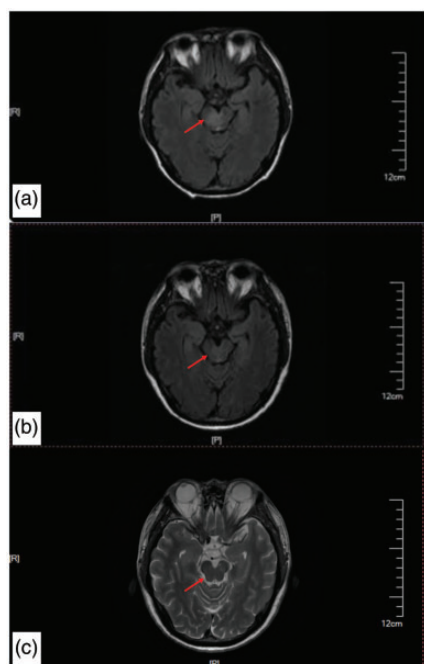
A 41-year-old man presented with recurrent small mucocutaneous lesions with oral and genital involvement over the past year. He complained of intermittent fever and headache, especially throbbing pain at the parietal and occipital areas, over the



**Figure 1.** Initial cranial magnetic resonance imaging of our patient shows a patch-like, slightly low-density shadow at the left basal ganglia area (red arrow).

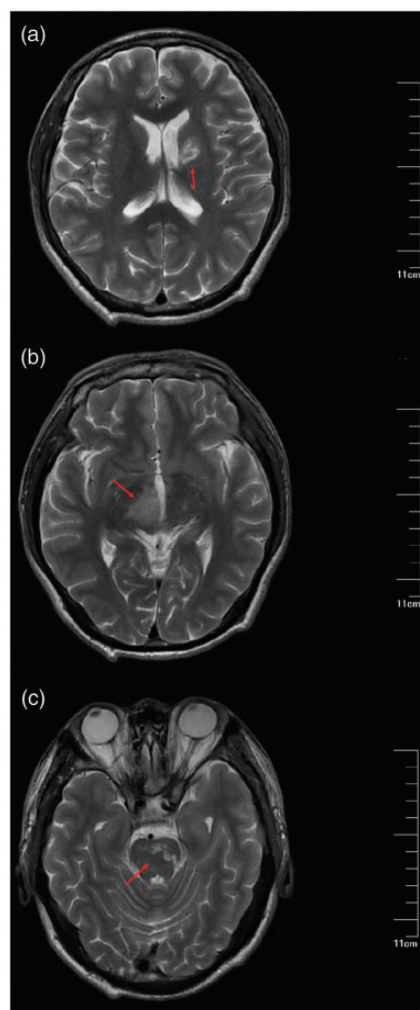
past 6 months. Cranial magnetic resonance imaging (MRI) (Figure 1) showed a patch-like, slightly low-signal shadow at the left basal ganglia area. He suffered from aggravating fever and headache with new-onset slight weakness and numbness of the right side of the body over the past 4 months. Cranial MRI showed expanded inflammatory lesions involving the right thalamus, right mesencephalon, and right pons (Figure 2), which accounted for his symptoms. Cerebrospinal fluid (CSF) testing showed a pressure of 125 mmH<sub>2</sub>O, the CSF was colorless and transparent, and there was a karyocyte count of  $50 \times 10^6/L$  with a mononuclear predominance. A CSF biochemical examination was normal.

Over 2 weeks before admission, he was in low spirits and felt drowsiness, which



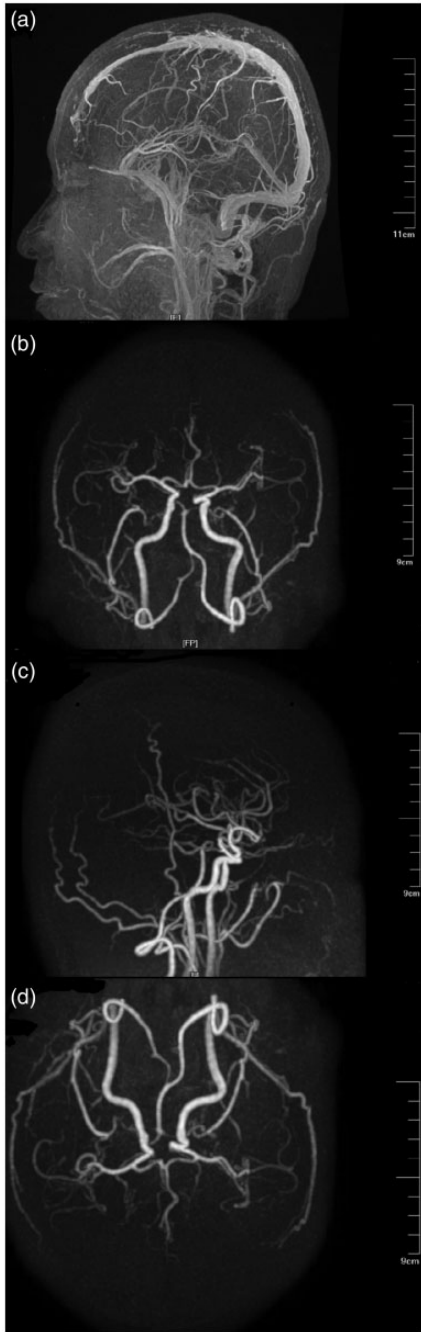
**Figure 2.** Cranial magnetic resonance imaging shows expanded inflammatory lesions involving areas of the right thalamus, right mesencephalon, and right pons (red arrow).

suggested cognitive impairment. He also felt progressive weakness and numbness of the right side of the body, had dysphagia, and had a choking cough. Furthermore, there was a sharp decline in his left vision with a best corrected visual acuity of 20/33 and blurred vision of the right eye with a best corrected visual acuity of 20/100. A physical examination showed central facial palsy and positive Babinski's sign. Cranial MRI showed expanded lesions, including multiple spot and patch-like inflammatory lesions involving the left basal ganglia, right thalamus, and brainstem (Figure 3). Magnetic resonance venography showed no obvious venous thrombosis (Figure 4). The CSF pressure was 100 mmH<sub>2</sub>O, and oligoclonal bands and elevated white blood cells were detected. Ocular ultrasound showed bilateral vitreous

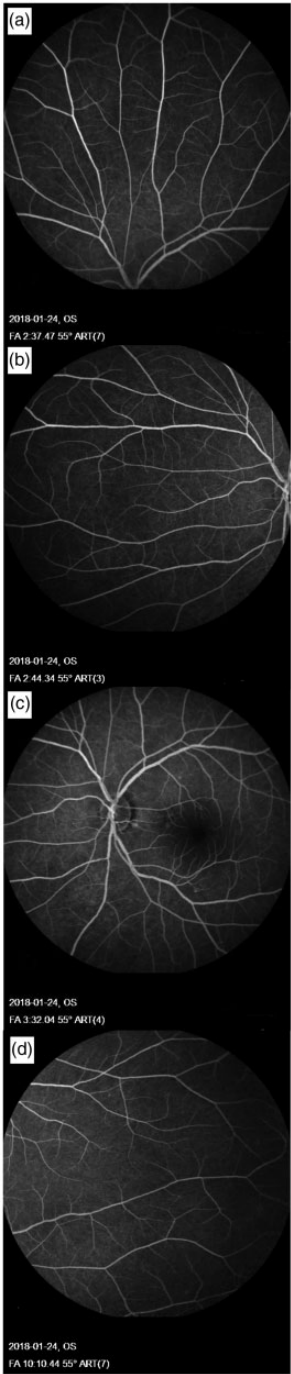


**Figure 3.** Cranial magnetic resonance imaging shows expanded lesions, including multiple spot and patch-like inflammatory lesions involving the left basal ganglia (a), right thalamus (b), and brain-stem (c) (red arrow).

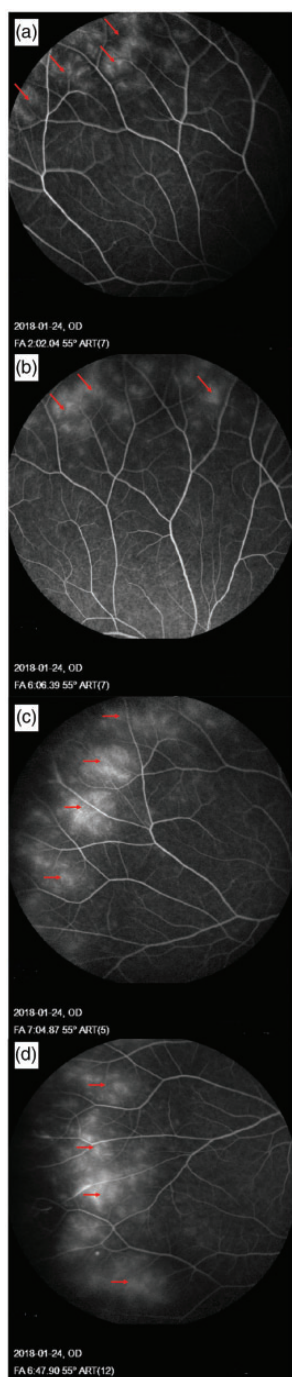
opacity. Fundus fluorescein angiography of the left eye showed no obvious changes (Figure 5). Fluorescein leakage of the peripheral vessels in the right eye indicated increased permeability of blood vessels and activity of the disease. This suggested right retinal vasculitis and right uveitis, consistent with the pathological changes of BS



**Figure 4.** Cranial magnetic resonance venography shows no obvious vascular thrombosis.



**Figure 5.** Fundus fluorescein angiography shows no obvious alterations of the peripheral vessels in the left eye.



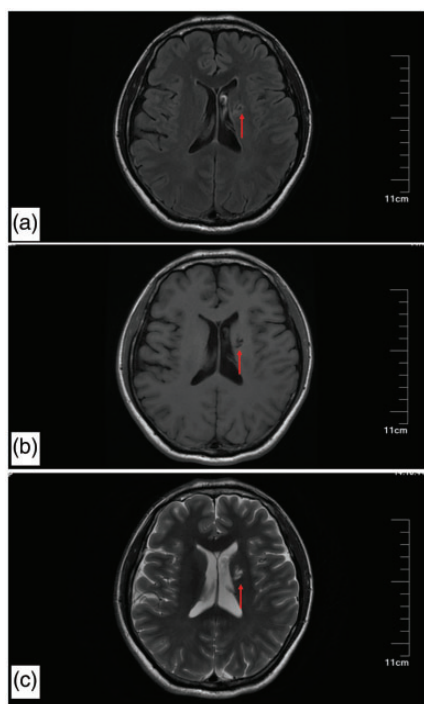
**Figure 6.** Fundus fluorescein angiography shows fluorescein leakage of the peripheral vessels in the right eye (red arrow).

(Figure 6). According to the International Study Group's classification for Behçet disease<sup>6</sup> and the patient's clinical manifestations, he was diagnosed with NBS.

In addition to symptomatic and supportive treatments, high-dose intravenous methylprednisolone (1000 mg, per day) pulse therapy was used for 3 days. Intravenous injection of cyclophosphamide (400 mg, twice a day) and oral administration of prednisone (40 mg in the morning, 20 mg in the evening) were applied. Uveitis was treated with retrobulbar injection of triamcinolone acetonide (40 mg/week). The patient's response was rapid, with improved neurological symptoms, including better feeling in the right side of the body and improvement of central facial palsy. The right eye's best corrected visual acuity improved to 20/50, while that of the left eye was 20/33. Oral administration of prednisolone (40 + 20 mg/day) was sustained after discharge until the most recent visit. Follow-up was conducted 1 month after discharge. At this time, the patient's symptoms were alleviated with improved neurological signs and bilateral vision. The right eye's best corrected visual acuity improved to 20/40, while that of the left eye was 20/33. Fundus fluorescein angiography was suggested, but the patient refused. Oral administration of prednisolone was changed to 35 mg in the morning and 15 mg in the evening. A recent follow-up that was conducted 1 year after discharge showed nearly normal neurological signs, but there was no improvement of binocular vision compared with the last follow-up. Cranial MRI showed remarkable improvement of the inflammatory parenchymal lesions with the left basal ganglia manifested as malacia (Figure 7). Laboratory test results remained within the normal range.

This case report was approved by the First Affiliated Hospital of Xi'an Jiaotong University Ethics Committee and





**Figure 7.** Cranial magnetic resonance imaging shows remarkable improvement of the inflammatory parenchymal lesions with the left basal ganglia manifested as malacia (red arrow).

conformed with the principles of the Declaration of Helsinki. Verbal and written informed consent was obtained from the patient before submission. The case report contains no direct patient identifiers and no relevant indirect identifiers (as specified in the journal policy). However, the patient was explicitly and adequately informed by the corresponding author regarding the potential publication of this case and the photographs used in the report.

## Discussion

Our patient manifested with classic characteristics of NBS. He suffered from a sudden decline in bilateral vision because his retinal vasculitis resulted in vitreous opacity, which

showed a poor curative effect. Findings from our case indicate that patients with NBS manifesting various neurological manifestations and diverse types of ocular inflammation may have a poor long-term prognosis, especially poor vision. Therefore, early diagnosis and timely adjustment of treatment are imperative for controlling the recurrence rate and minimizing irreversible outcomes, such as sudden vision loss.

Neurological involvement of BS is a significant cause of morbidity and mortality, and approximately one half of patients with NBS are moderately to severely disabled within 10 years of its occurrence. This dilemma is in part due to difficulty in predicting the prognosis and formulating an appropriate therapeutic strategy. Siva et al.<sup>7</sup> evaluated the neurological disabilities of patients with NBS on the basis of the Expanded Disability Status Scale of Kurtzke (EDSS), which was initially designed for multiple sclerosis-associated disabilities. During a 10-year follow-up, 78.2% of the patients developed mild disability (EDSS score = 3), and 45.1% progressed to moderate to severe disabilities (EDSS score = 6). However, the EDSS score is sometimes inconsistent with neurological examinations. An example of this inconsistency is that patients with cerebral venous sinus thrombosis have EDSS scores of either 1 or 2 (minimal disability).<sup>7</sup> The overall morbidity and mortality is still remarkable in this group because of the increased prevalence of systemic large vessel disease. Therefore, a more comprehensive scoring system is required for prognosis of NBS.

In previous studies with a large cohort of patients with BS, the all-cause mortality rate remained at 9.8%, and the mortality rate due to neurological involvement was up to 12%.<sup>8</sup> Patients who died were predominantly male and had a significantly higher frequency of vascular (mainly

arterial) involvement and more severe disease requiring a higher frequency of corticosteroid and immunosuppressant use. Additionally, onset with cerebellar symptoms, a progressive course, an elevated protein level, and pleocytosis in the CSF have also been reported to be associated with a poor prognosis.<sup>9–11</sup>

As mentioned above, a large challenge remains for reaching a conclusion on the efficacy of treatment for any form of NBS. Similar to many chronic relapsing inflammatory diseases, the treatment options in NBS comprise relapse treatment, long-term attack-preventing treatment, and symptomatic treatment. Studies have suggested that in the acute episode of CNS involvement in NBS, patients should be treated with high-dose intravenous methylprednisolone (1000 mg/day) for 7 to 10 days or by oral prednisolone (1 mg/kg for up to 4 weeks, or until improvement is observed).<sup>12,13</sup> Both forms of treatment should be followed with an oral tapering dose of glucocorticoids over 2–3 months to prevent early relapses. There is no apparent difference between the two regimens theoretically, but the high-dose intravenous methylprednisolone regimen is associated with earlier improvement, which is in accordance with our observation.

After pulse therapy, long-term maintenance treatment with an immunosuppressant should be considered in patients with NBS and parenchymal CNS involvement. This is because this type of NBS may follow a recurrent progressive course, and may cause significant physical and cognitive disorders, resulting in neurological disabilities. Akman-Demir et al<sup>14</sup> reported that thalidomide was helpful in erythema nodosum-like skin damage. These authors also found that colchicine was effective in mucocutaneous lesions. Furthermore, azathioprine, cyclosporine, interferon- $\alpha$  or  $\beta$ , and anti-tumor necrosis factor agents were effective alternatives in BS uveitis, and

cyclophosphamide was effective in major vascular involvement. Usual practice involves adding an immunosuppressant drug, such as azathioprine or cyclophosphamide, to glucocorticoids in patients who are diagnosed with progressive NBS. The effect of such a combination is supported by findings in our case. Recently, azathioprine was considered as the first-line choice in patients with relapsing NBS together with initial high-dose steroid pulse therapy, followed by low-dose steroid maintenance therapy.<sup>15</sup> A high-dose steroid pulse associated with mycophenolate mofetil (1 g daily) and infliximab (5 mg/kg/day) is effective in treating NBS associated with severe retinal vasculitis.<sup>16</sup> However, none of the above-mentioned studies showed powerful evidence concerning the potential effect in preventing CNS involvement. The severity of the initial NBS event, systemic manifestations of BS, and estimation of prognosis affect management strategies, which should be considered together with the patient's clinicians.

## Conclusion

BS is becoming an increasingly recognized disorder by clinicians. Currently, the therapeutic regimen of patients with BS has greatly advanced, leading to evidence-based guidelines. However, large, well-designed, multicenter trials are urgently required to improve our knowledge of this syndrome. Translational research endeavors to identify more accurate biomarkers for clinical diagnosis. Novel therapeutic options for BS, including infliximab, tocilizumab, and hematopoietic stem cell transplantation, are currently underway. These efforts will undoubtedly shed new light on this complex syndrome.

## Guarantor

The corresponding author guarantees the accuracy of the data and the article.

## Declaration of conflicting interest

The authors declare that there is no conflict of interest.

## Funding

This research received no specific grant from any funding agency in the public, commercial, or not-for-profit sectors.

## References

1. Saip S, Akman-Demir G and Siva A. Neuro-Behçet syndrome. *Handb Clin Neurol* 2014; 121: 1703–1723.
2. Kalayciyan A and Zouboulis C. An update on Behçet's disease. *J Eur Acad Dermatol Venereol* 2007; 21: 1–10.
3. Kim DK, Chang SN, Bang D, et al. Clinical analysis of 40 cases of childhood-onset Behçet's disease. *Pediatr Dermatol* 1994; 11: 95–101.
4. Al-Araji A and Kidd DP. Neuro-Behçet's disease: epidemiology, clinical characteristics, and management. *Lancet Neurol* 2009; 8: 192–204.
5. Kocer N, Islak C, Siva A, et al. CNS involvement in neuro-Behçet syndrome: an MR study. *AJNR Am J Neuroradiol* 1999; 20: 1015–1024.
6. Criteria for diagnosis of Behçet's disease. International Study Group for Behçet's disease. *Lancet* 1990; 335: 1078–1080.
7. Siva A, Kantarci OH, Saip S, et al. Behçet's disease: diagnostic and prognostic aspects of neurological involvement. *J Neurol* 2001; 248: 95–103.
8. Saadoun D, Wechsler B, Desseaux K, et al. Mortality in Behçet's disease. *Arthritis Rheum* 2010; 62: 2806–2812.
9. Scherrer MAR, Rocha VB and Garcia LC. Behçet's disease: review with emphasis on dermatological aspects. *An Bras Dermatol* 2017; 92: 452–464.
10. Uygunoglu U and Siva A. Nervous system involvement in Behçet's syndrome. *Curr Opin Rheumatol* 2019; 31: 32–39.
11. Hatemi G, Seyahi E, Fresko I, et al. One year in review 2017: Behçet's syndrome. *Clin Exp Rheumatol* 2017; 35: 3–15.
12. Uygunoglu U and Siva A. Behçet's syndrome and nervous system involvement. *Curr Neurol Neurosci Rep* 2018; 18: 35.
13. Davatchi F, Sadeghi Abdollahi B, Shams H, et al. Combination of pulse cyclophosphamide and azathioprine in ocular manifestations of Behçet's disease: longitudinal study of up to 10 years. *Int J Rheum Dis* 2014; 17: 444–452.
14. Akman-Demir G, Serdaroglu P and Tasci B. Clinical patterns of neurological involvement in Behçet's disease: evaluation of 200 patients. The Neuro-Behçet Study Group. *Brain* 1999; 122: 2171–2182.
15. Urruticoechea-Arana A, Cobo-Ibáñez T, Villaverde-Garcia V, et al. Efficacy and safety of biological therapy compared to synthetic immunomodulatory drugs or placebo in the treatment of Behçet's disease associated uveitis: a systematic review. *Rheumatol Int* 2019; 39: 47–58.
16. Ferreira BFA, Rodriguez EEC, Prado LLD, et al. Frosted branch angiitis and cerebral venous sinus thrombosis as an initial onset of neuro-Behçet's disease: a case report and review of the literature. *J Med Case Rep* 2017; 11: 104.