

Ruptured basilar artery perforator aneurysm: a novel mechanism of pure subarachnoid hemorrhage in moyamoya disease. Illustrative case

Kazuaki Okamura, MD, Taro Higuchi, MD, Tsuyoshi Izumo, MD, PhD, Ryotaro Takahira, MD, Eisaku Sadakata, MD, Michiharu Yoshida, MD, PhD, Susumu Yamaguchi, MD, PhD, Yoichi Morofuji, MD, PhD, Shiro Baba, MD, PhD, Takeshi Hiu, MD, PhD, and Takayuki Matsuo, MD, PhD

Department of Neurosurgery, Nagasaki University Graduate School of Biomedical Sciences, Nagasaki, Japan

BACKGROUND Pure subarachnoid hemorrhage (SAH) in patients with moyamoya disease is a rare occurrence. Three underlying mechanisms have been described previously, except for ruptured aneurysm of the circle of Willis. Herein, the authors describe a novel mechanism: rupture of a perforator aneurysm in moyamoya disease.

OBSERVATIONS A 51-year-old man experienced sudden onset of severe headache and vomiting. Computed tomography showed diffuse SAH. Digital subtraction angiography (DSA) showed unilateral moyamoya disease without remarkable etiology of SAH. The patient underwent conservative management with antihypertensive agents. The second DSA on day 17 revealed a slow-filling aneurysm emerging from the basilar top perforating artery. The diagnosis of SAH due to unknown origin was changed to ruptured basilar artery perforator aneurysm (BAPA). The third follow-up DSA on day 159 revealed the resolution of BAPA.

LESSONS In the case of pure SAH, it is crucial to consider the possibility of perforator aneurysms due to hemodynamic stress caused by moyamoya disease. Repeated DSA is essential for detecting the lesion.

<https://thejns.org/doi/abs/10.3171/CASE22238>

KEYWORDS basilar artery perforator aneurysm; moyamoya disease; subarachnoid hemorrhage

Basilar artery perforator aneurysms (BAPAs) are defined as aneurysms wherein the neck is located entirely on a perforating artery without directly involving the basilar trunk.¹ Since they were first described by Ghogawala et al.² in 1996, the number of case reports of subarachnoid hemorrhage (SAH) due to ruptured BAPA has been increasing. BAPAs are a rare cause of SAH; therefore, the diagnosis and treatment strategy remain controversial. The detection of ruptured BAPAs on the initial digital subtraction angiography (DSA) is complex, and repeated DSA is needed to confirm the diagnosis. Herein, we report a rare case of moyamoya disease–related ruptured BAPA in a patient who showed good outcomes with conservative management.

Illustrative Case

A 51-year-old man with no past medical or surgical history was brought to our hospital because of sudden onset of severe headache

and vomiting. Computed tomography (CT) of the head showed Fisher group 3 diffuse SAH, slightly dense in the prepontine cistern (Fig. 1A). CT angiography revealed occlusion in the terminal portion of the internal carotid artery and slight contrast in the peripheral middle cerebral artery but no aneurysm. DSA showed severe stenosis of the left internal carotid artery and basal moyamoya vessels (Fig. 1B–E). At this point, the patient was diagnosed with pure SAH associated with moyamoya disease. He underwent conservative treatment with close imaging follow-up. Cerebral vasospasm management was performed for 2 weeks, and no neurological deficit was noted. On the 17th day, the second DSA revealed a slow contrast-filling aneurysm emerging from the thalamoperforating artery branching from basilar bifurcation (Fig. 2). The final diagnosis for the patient was pure SAH due to ruptured BAPA. We administered conservative treatment in anticipation of natural thrombosis. He was discharged after 25 days, when his modified Rankin Scale score

ABBREVIATIONS BAPA = basilar artery perforator aneurysm; CT = computed tomography; DAPT = dual antiplatelet therapy; DSA = digital subtraction angiography; FD = flow diverter; SAH = subarachnoid hemorrhage.

INCLUDE WHEN CITING Published August 22, 2022; DOI: 10.3171/CASE22238.

SUBMITTED May 26, 2022. **ACCEPTED** June 22, 2022.

© 2022 The authors, CC BY-NC-ND 4.0 (<http://creativecommons.org/licenses/by-nc-nd/4.0/>).

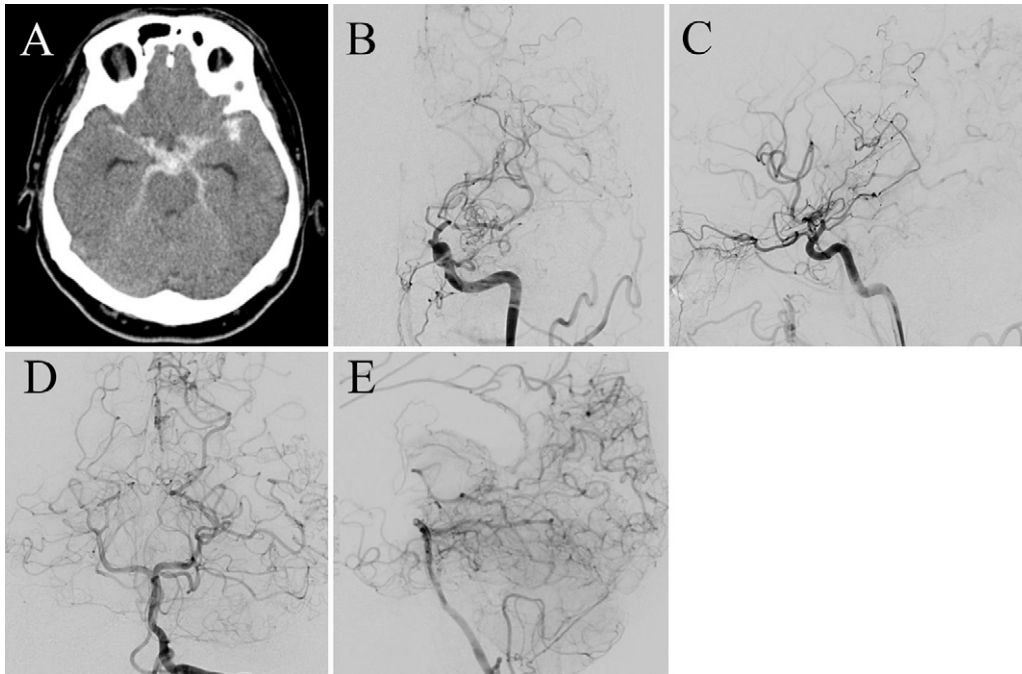


FIG. 1. CT and DSA on admission. CT (A) shows diffuse SAH, slightly dense in the prepontine cistern. Left internal carotid angiography, anteroposterior (B) and lateral (C) views, shows severe left internal carotid artery stenosis and basal moyamoya vessels. Left vertebral angiography, anteroposterior (D) and lateral (E) views, shows collateral circulation from the posterior cerebral artery to anterior and middle cerebral arteries.

was 0 without rebleeding events. His postdischarge clinical course was uneventful. In the follow-up DSA performed on day 159, the aneurysm had resolved (Fig. 3).

Discussion

Observations

We present a case of pure SAH due to a ruptured BAPA with unilateral moyamoya disease. Pure SAH in patients with moyamoya disease without aneurysms is extremely rare. The Japan Adult Moyamoya trial revealed that only 3.8% of the patients developed pure SAH.³ There are two leading causes of intracranial bleeding in patients with moyamoya disease: rupture of dilated, fragile moyamoya vessels and rupture of saccular aneurysms in the circle of Willis.⁴ The former causes intraparenchymal hemorrhage and intraventricular hemorrhage, whereas the latter causes SAH. The common cause of intracranial bleeding in moyamoya disease is collateral circulation failure. Regarding the mechanisms underlying SAH onset, (1) rupture of the peripheral artery aneurysm,⁵ (2) rupture of the transdural anastomosis,⁶ and (3) rupture of the dilated collateral arteries on the brain surface⁷ have been reported to date. We found a novel cause of pure SAH onset in moyamoya disease (i.e., rupture of the BAPA), which, to the best of our knowledge, has not yet been reported. In this case, it was presumed that the collateral circulation from the posterior cerebral artery had developed, and hemodynamic stress occurred on the basilar artery trunk. Hemodynamic stress plays an essential role in the formation of perforator aneurysms. Therefore, in the case of pure SAH onset due to moyamoya disease, it is necessary to consider the possibility of ruptured perforator aneurysms.

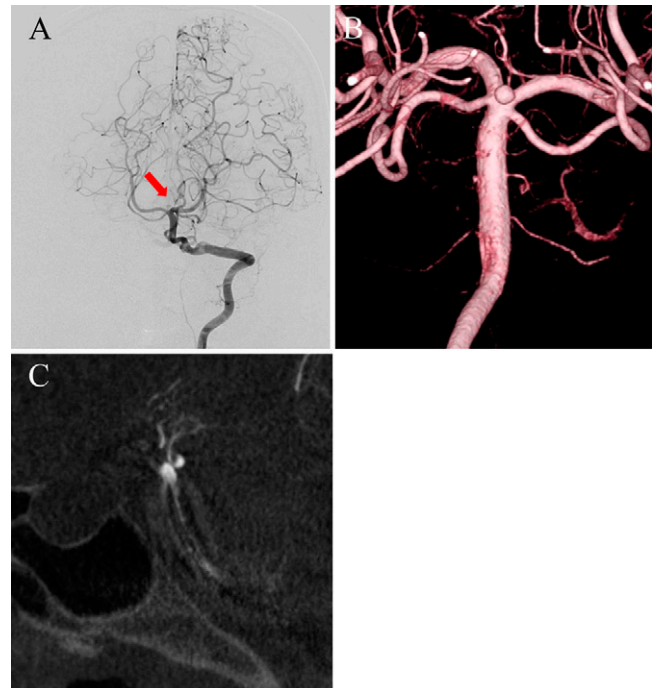


FIG. 2. Second DSA on day 17. A: Left vertebral angiography shows a slow-filling aneurysm arising from the basilar top perforating artery (red arrow). B: Three-dimensional rotational angiography shows a 2.5-mm perforator aneurysm. C: Maximum-intensity projection shows basilar top perforator artery and slowly contrasted aneurysm without directly involving the basilar trunk.

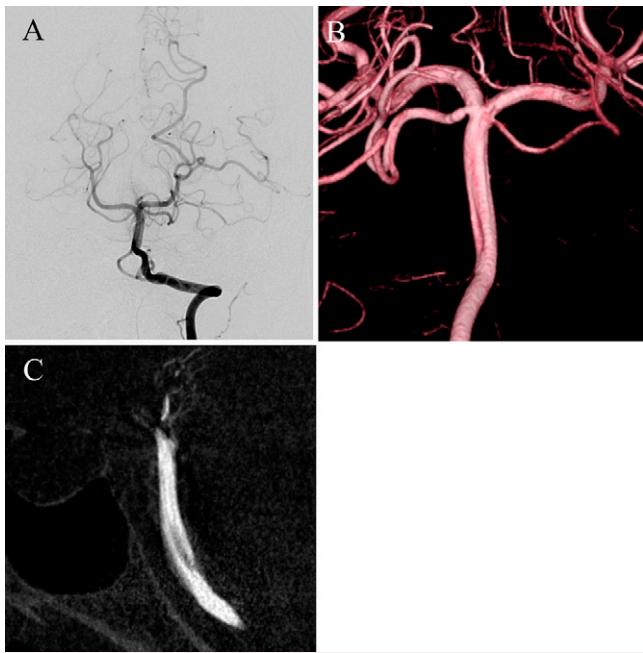


FIG. 3. DSA on day 159. **A and B:** Left vertebral angiography and three-dimensional rotational angiography show complete resolution of the basilar artery perforator aneurysm. **C:** Maximum-intensity projection shows that basilar artery perforator aneurysm resolved, and the perforator artery is preserved.

BAPAs are rare and may lead to severe SAH. Additionally, BAPAs are extremely small, with diameters ranging from 0.5 to 7 mm (mean 2.5 mm) and commonly located in the middle to distal part of the basilar artery.^{8,9} Moreover, distal perforating artery aneurysms are sporadic, unlike proximal perforating artery aneurysms.¹⁰ The perforator angle from the basilar artery is upward to horizontal in the middle and distal perforators; in contrast, the slope is downward in the proximal perforators.¹¹ These angles may affect hemodynamic stress and may lead to the formation of the perforator aneurysms.

The diagnosis of BAPAs is challenging and can be overlooked in many cases. In a single-center study, Buell et al.¹¹ reported that only 22% of ruptured aneurysms were visualized on initial imaging. Sanchez-Mejia et al.¹⁰ found that perforator aneurysms were difficult to detect through imaging studies because they were slow to fill, did not have opacity in the arterial phases like other aneurysms, and were best visualized by scrolling through images on the computer monitor. The interval between repeated cerebral angiography was in accordance with our institutional protocol based on a past report.¹² In the present case, the perforator aneurysm was not observed on the initial DSA, and the second DSA on the 17th day was visualized from the late stage of the arterial phase. Stagnation of the contrast medium was also observed in the venous phase. Thus, in cases of nonaneurysmal pure SAH, repeated DSA is crucial for detecting the lesion.

The treatment for ruptured BAPAs remains controversial, including surgical treatment, endovascular treatment, and conservative management. Surgical treatment of BAPAs may be feasible in specific cases.^{10,13–17} Direct surgery is often performed in the

subtemporal or anterior-petrosal approach because BAPAs are usually located in the middle to distal part of the basilar perforator artery. Therefore, we should be aware of complications, such as cranial nerve injury and obstruction of the surrounding perforator artery. BAPAs may not be amenable to standard clip occlusion because of the absence of a true neck; therefore, the placement of a surgical clip may also impede the perforator.¹⁰ In the reported cases treated surgically, only 25% of the parent vessel perforators were preserved.¹³ The indications for surgical treatment should be carefully considered.

Endovascular treatment comprises coiling, overlapping stents, liquid embolization, and placement of a flow diverter (FD). Simple coiling of BAPAs is difficult because the diameter of the perforator artery is small, and catheter access is not possible. In such cases, dual antiplatelet therapy (DAPT) may be administered, and overlapping stents are used. In recent years, with the advent of FD, reports of endovascular treatment are increasing.^{8,18,19} There are reports of good embolization of aneurysms preserving the perforator; however, cases of perforator occlusion despite DAPT have also been reported. Enomoto et al.⁹ reported that the rate of resolution of the aneurysm without complications was 58.3% in the stent/FD group. In Japan, stents and FDs in the acute phase are available for off-label use. Moreover, the stent/FD is potentially hazardous in the acute phase because of DAPT, and their efficacy remains uncertain.

The natural history of the BAPAs is not well known. Forbrig et al.²⁰ reported that conservative management causes at least 60% of spontaneous thrombosis. On average, 137 days are required for spontaneous thrombosis with a 15% risk of rebleeding.²¹ Enomoto et al.⁹ in their literature review, reported that among 23 patients who received conservative management, the aneurysm was occluded spontaneously without complications in 12 patients (52.2%), and 2 patients (8.7%) experienced rebleeding; therefore, they strongly recommended conservative management. In our case, the aneurysm occurred from the thalamoperforating artery. Because the parent artery is a small and vulnerable perforator, it was concerning that treatment with aneurysm clipping surgery or endovascular coil embolization caused cerebral infarction due to the vessel occlusion, resulting in severe neurological sequelae.²² Thus, we selected conservative management for this patient, which led to a good outcome. Therefore, in cases of ruptured BAPA associated with moyamoya disease, conservative treatment should be provided along with performing diagnostic imaging by close follow-up.

Lessons

SAH due to ruptured BAPAs is extremely rare and often undiagnosed in the early stages, requiring repeated imaging tests. Hence, it is essential to identify the perforator aneurysms due to pathological hemodynamic stress in cases of SAH of unknown origin. SAH in patients with moyamoya disease is rare, and follow-up DSA is recommended because of the possibility of the development of late-onset perforator aneurysms.

Acknowledgments

We thank Editage for English language editing.

References

1. Aboukais R, Zairi F, Estrade L, Quidet M, Leclerc X, Lejeune JP. A dissecting aneurysm of a basilar perforating artery. *Neurochirurgie*. 2016;62(5):263–265.

2. Ghogawala Z, Shumacher JM, Ogilvy CS. Distal basilar perforator artery aneurysm: case report. *Neurosurgery*. 1996;39(2):393–396.
3. Miyamoto S, Yoshimoto T, Hashimoto N, et al. Effects of extracranial-intracranial bypass for patients with hemorrhagic moyamoya disease: results of the Japan Adult Moyamoya Trial. *Stroke*. 2014;45(5):1415–1421.
4. Kuroda S, Houkin K. Moyamoya disease: current concepts and future perspectives. *Lancet Neurol*. 2008;7(11):1056–1066.
5. Kuroda S, Houkin K, Kamiyama H, Abe H. Effects of surgical revascularization on peripheral artery aneurysms in moyamoya disease: report of three cases. *Neurosurgery*. 2001;49(2):463–468.
6. Wan M, Han C, Xian P, Yang WZ, Li DS, Duan L. Moyamoya disease presenting with subarachnoid hemorrhage: clinical features and neuroimaging of a case series. *Br J Neurosurg*. 2015;29(6):804–810.
7. Osanai T, Kuroda S, Nakayama N, Yamauchi T, Houkin K, Iwasaki Y. Moyamoya disease presenting with subarachnoid hemorrhage localized over the frontal cortex: case report. *Surg Neurol*. 2008;69(2):197–200.
8. Finitis S, Derelle AL, Tonnelet R, Anxionnat R, Bracard S. Basilar perforator aneurysms: presentation of 4 cases and review of the literature. *World Neurosurg*. 2017;97:366–373.
9. Enomoto N, Shinno K, Tamura T, Shikata E, Shono K, Takase K. Ruptured basilar artery perforator aneurysm: a case report and review of the literature. *NMC Case Rep J*. 2020;7(3):93–100.
10. Sanchez-Mejia RO, Lawton MT. Distal aneurysms of basilar perforating and circumferential arteries. Report of three cases. *J Neurosurg*. 2007;107(3):654–659.
11. Buell TJ, Ding D, Raper DMS, et al. Posterior circulation perforator aneurysms: a proposed management algorithm. *J Neurointerv Surg*. 2018;10(1):55–59.
12. Komatsu Y, Yasuda S, Shibata T, Ono Y, Hyodo A, Nose T. Management for subarachnoid hemorrhage with negative initial angiography. Article in Japanese. *No Shinkei Geka*. 1994;22(1):43–49.
13. Bhogal P, AlMatter M, Hellstern V, et al. Basilar artery perforator aneurysms: report of 9 cases and review of the literature. *J Clin Neurosci*. 2019;63:122–129.
14. Hamel W, Grzyska U, Westphal M, Kehler U. Surgical treatment of a basilar perforator aneurysm not accessible to endovascular treatment. *Acta Neurochir (Wien)*. 2005;147(12):1283–1286.
15. Mathieson CS, Barlow P, Jenkins S, Hanzely Z. An unusual case of spontaneous subarachnoid haemorrhage - a ruptured aneurysm of a basilar perforator artery. *Br J Neurosurg*. 2010;24(3):291–293.
16. Gross BA, Puri AS, Du R. Basilar trunk perforator artery aneurysms. Case report and literature review. *Neurosurg Rev*. 2013;36(1):163–168.
17. Sivakanthan S, Carlson AP, van Loveren H, Agazzi S. Surgical clipping of a basilar perforator artery aneurysm: a case of avoiding perforator sacrifice. *J Neurol Surg A Cent Eur Neurosurg*. 2015;76(1):79–82.
18. Peschillo S, Caporlingua A, Cannizzaro D, et al. Flow diverter stent treatment for ruptured basilar trunk perforator aneurysms. *J Neurointerv Surg*. 2016;8(2):190–196.
19. Chalouhi N, Jabbour P, Starke RM, et al. Treatment of a basilar trunk perforator aneurysm with the pipeline embolization device: case report. *Neurosurgery*. 2014;74(6):E697–E701.
20. Forbrig R, Eckert B, Ertl L, et al. Ruptured basilar artery perforator aneurysms—treatment regimen and long-term follow-up in eight cases. *Neuroradiology*. 2016;58(3):285–291.
21. Chau Y, Sachet M, Sédat J. Should we treat aneurysms in perforator arteries from the basilar trunk? Review of 49 cases published in the literature and presentation of three personal cases. *Interv Neuroradiol*. 2018;24(1):22–28.
22. Hochman MS, Sowers JJ, Bruce-Gregorios J. Syndrome of the mesencephalic artery: report of a case with CT and necropsy findings. *J Neurol Neurosurg Psychiatry*. 1985;48(11):1179–1181.

Disclosures

The authors report no conflict of interest concerning the materials or methods used in this study or the findings specified in this paper.

Author Contributions

Conception and design: Izumo, Okamura, Matsuo. Acquisition of data: Okamura, Higuchi, Sadakata. Analysis and interpretation of data: Izumo. Drafting the article: Izumo, Okamura, Higuchi. Critically revising the article: Izumo, Takahira, Yoshida, Yamaguchi, Morofuji, Baba. Reviewed submitted version of manuscript: Izumo, Okamura, Takahira, Yoshida, Yamaguchi, Morofuji, Baba, Hiu. Approved the final version of the manuscript on behalf of all authors: Izumo. Study supervision: Izumo.

Correspondence

Tsuyoshi Izumo: Nagasaki University Graduate School of Biomedical Sciences, Nagasaki, Japan. go-izumo@hotmail.co.jp.