

Review

Role of Diagnostic and Therapeutic Endoscopic Ultrasonography in Benign Pancreatic Diseases

Vikas Singla, Pramod Kumar Garg*

Department of Gastroenterology, All India Institute of Medical Sciences, New Delhi, India

Abstract

Standard imaging of pancreas is generally obtained by computed tomography and magnetic resonance imaging. However endoscopic ultrasound (EUS) has become an indispensable tool for the diagnosis of various pancreatic diseases. Because of the close proximity of the EUS probe to the pancreas, EUS provides excellent images of the pancreas. In this review, we discuss the role of EUS in the clinical management of patients with benign pancreatic diseases, i.e., various forms of pancreatitis.

Keywords: endoscopic ultrasonography; diagnostic; therapeutic; pancreatic disease; benign

Singla V, Garg PK. Role of Diagnostic and Therapeutic Endoscopic Ultrasonography in Benign Pancreatic Diseases. *Endosc Ultrasound* 2013; 2(3): 134-141

INTRODUCTION

Pancreas has long been shrouded in mystery, primarily due to its inaccessible location for both morphological and pathological examination. Therefore, the complex pathophysiological mechanisms of the pancreatic disorders have remained ill-understood. Cross-sectional imaging is the mainstay of diagnosing various pancreatic diseases. The limitations of transabdominal ultrasound for imaging the pancreas are well-known. Standard imaging of pancreas is generally obtained by computed tomography (CT) and magnetic resonance imaging (MRI). Rapid advances in these two cross-sectional imaging have indeed resulted in excellent resolution and much greater anatomical details through multiple thin slicing and newer developments in software protocols particularly for MRI. However, the advances in CT and MRI have been mainly incremental. Paradigm shift in imaging the pancreas in fact took place with the development and refinement of endoscopic ultrasound (EUS). EUS has of late become an indispensable tool for the diagnosis of various pancreatic diseases. Because of the close proximity of the EUS probe to the pancreas, EUS provides excellent

images of the pancreas. Initially, its role was limited to staging gastrointestinal malignancies, but the clinical applications of EUS have expanded over time. This review focuses on the role of EUS in the clinical management of patients with benign pancreatic diseases, i.e., various forms of pancreatitis.

IMAGING THE PANCREAS BY EUS: TECHNICAL NOTES

Pancreas can be imaged well both by the radial scanning echoendoscope or the linear scanning echoendoscope. For diagnostic purposes, either of the two is sufficient and provides excellent imaging of the pancreas and its adjacent structures. In addition to imaging the pancreas, one often needs to examine the biliary system not only due to their intricate anatomical relationship, but also because either a biliary pathology is the cause of pancreatitis or vice versa. The various parts of the pancreas, i.e., the head, uncinate process, genu, body and tail can be imaged from different locations in the stomach and duodenum (also termed as imaging stations). EUS has the ability to image both parenchymal and the ductal changes in the pancreas, which aid in arriving at a diagnosis. Peripancreatic changes might be of importance too. The head of the pancreas is most frequently involved in pancreatic pathologies be it pancreatitis or cancer. It can be imaged well from the duodenal bulb. While using the radial echoendoscope as the scope is introduced into the duodenal bulb, the pancreatic head is visualized between the scope and the portal vein on

Video Available on: www.eusjournal.com

*To whom correspondence should be addressed.

E-mail: pkgarg@aiims.ac.in

Received: 2013-06-26; Accepted: 2013-07-20

DOI: 10.7178/eus.06.004

the left side of the screen from 6 O' clock to 11 O' clock position (Video 1). For the uncinate process, the scope is further introduced into the third part of the duodenum and while withdrawing the scope, one can see the aorta and superior mesenteric vessels. The uncinate process lies in between the aorta and the superior mesenteric vessels. It often appears as hypoechoic compared with the dorsal pancreas. The genu and body of the pancreas are best examined from the stomach after withdrawing the scope to the proximal body and fundus. The tail of the pancreas is imaged while further withdrawing the scope with a clockwise rotation. A part of the head of pancreas may also be visualized from the stomach.

While using the linear echoendoscope, it is better to image the pancreas from the stomach first. In our personal opinion, the first structure, which should be focused, is the confluence of the superior mesenteric, portal and splenic veins from the body of the stomach while rotating the scope in a clockwise direction. Once the confluence is focused, a part of the head of pancreas, genu and proximal body come into view. Starting with the confluence as the initial landmark, the body of the pancreas can be traced along the splenic vein toward the tail of the pancreas up to the splenic hilum, by simultaneous withdrawal and clockwise rotation of the echoendoscope (Video 2). The pancreatic duct (PD) can be easily traced throughout the pancreas in this manner by slight adjustment of the scope position. After examining from the stomach, the scope should be introduced into the duodenal bulb and the head of the pancreas comes into view with slight rotation of the scope to the right and up. To image the uncinate process and the remaining part of the head of the pancreas, the scope is advanced into the second part of the duodenum beyond the ampulla of Vater and slowly withdrawn. The important landmark in this location is aorta that comes into view in its longitudinal section close to the transducer at about 6 O'clock position. Further withdrawal of the scope brings the pancreas and the ampulla into view. The lower ends of bile and PDs, converging at the ampulla, are seen well in this position. Both ducts can be traced proximally by withdrawing the scope to the duodenal bulb where the orientations of the bile duct changes. The body and tail of the pancreas should be re-examined when the scope is withdrawn back into the stomach. For performing a fine needle aspiration (FNA) from a mass lesion in the head of pancreas, the best site is duodenal bulb, because the needle tract is included in the subsequent pancreatoduodenectomy specimen thus avoiding any risk of seeding.

INDICATIONS OF EUS IN BENIGN PANCREATIC DISORDERS

EUS examination is indicated in the following benign disorders of the pancreas: (1) Acute pancreatitis, (2) recurrent acute pancreatitis (RAP), (3) chronic pancreatitis

(CP), (4) autoimmune pancreatitis, (5) pancreatic pseudocyst and walled-off pancreatic necrosis (WON), (6) celiac plexus block (CPB)/neurolysis.

Role of EUS in acute pancreatitis

EUS has a limited role in the evaluation of patients with acute pancreatitis for assessing disease severity although a few studies have reported some correlation between EUS findings and the outcome. In a study of 36 patients with acute gallstone pancreatitis, Chak *et al.* showed that patients with peripancreatic fluid collections on EUS, had a longer duration of hospital stay, but it was not statistically significant (9.2 d *vs.* 5.7 d).¹ In another recent study, peripancreatic edema on EUS correlated with the severity of AP with a sensitivity, specificity and accuracy of 65.8%, 75.7% and 72.2%, respectively.² However, pancreatic necrosis could not be diagnosed, which is a major determinant of severity of acute pancreatitis. The most important indication of EUS is to diagnose common bile duct (CBD) stone in acute gallstone pancreatitis to decide about the need for endoscopic retrograde cholangiopancreatography (ERCP). In a study of 123 patients with suspected biliary pancreatitis, EUS diagnosed CBD stones in 27% of patients who underwent ERCP with low complications.³ In another study of 100 patients, EUS was performed within 24 h and it ruled out choledocholithiasis in 65 of 66 patients (specificity: 98%).⁴ In a randomized controlled trial, 140 patients with suspected acute biliary pancreatitis were randomized to EUS or ERCP within 24 h of admission.⁵ CBD stones were missed in 6 patients in the ERCP group. None of the patients in the EUS group who had no CBD stones had any recurrence of pancreatitis during follow-up. Four patients in the ERCP group had post-sphincterotomy bleeding. However, overall there was no difference in the morbidity or mortality between the two groups. Thus, EUS can be used to prevent unnecessary ERCP and its associated complications. However, there are no definite guidelines to recommend the use of EUS in the acute setting to detect CBD stones and the decision should be guided by the clinical setting.

Another important indication of EUS in acute pancreatitis is to determine the etiology in idiopathic cases. The common causes of acute pancreatitis are gallstones, alcohol abuse, post-ERCP, trauma, drugs, viral infection etc. The cause of acute pancreatitis is evident after standard investigations in about 60%-80% of patients during or after the first attack. Gallstones are the cause of acute pancreatitis in about 45%, alcohol in about 20%-25%, post-ERCP in about 5%-7% and miscellaneous in about 5% of cases. Thus, the cause is not evident in 20%-30% of patients who are labeled as having idiopathic acute pancreatitis.⁶ Idiopathic pancreatitis constitutes a subgroup in which the etiology of acute pancreatitis cannot be found out after initial evaluation. The standard initial evaluation includes a detailed history and physical examination and investigations such as liver function tests, lipid profile, serum calcium and imaging. The role of EUS

for the etiology of pancreatitis is discussed below in the section dealing with RAP.

RAP

Most patients, who have had an attack of acute pancreatitis, are at risk of having a recurrence of pancreatitis if the offending cause/agent is not removed. Of the common causes of acute pancreatitis, gallstones and alcohol are the most likely to cause recurrent pancreatitis. Thus, the risk of recurrence is often predictable and there is a window for treating the cause to prevent recurrence. Fortunately, most causes of pancreatitis can be eliminated/treated e.g., gallstones, alcohol, drugs, trauma, ERCP etc. However, the risk of recurrence in patients with idiopathic pancreatitis is difficult to predict. In general, about 20%-30% of patients have idiopathic acute pancreatitis and run the risk of recurrence of pancreatitis. The indication for EUS in patients with idiopathic recurrent acute pancreatitis (IRAP) is to find out the etiology in the idiopathic group to prevent further attacks by specific treatment of the cause. The common causes of IRAP include biliary microlithiasis, bilioPDal abnormalities, sphincter of Oddi dysfunction, occult tumors and early chronic pancreatitis (CP).⁸ Although patients with IRAP requires extensive evaluation, EUS plays an important role in the diagnostic work-up. In patients with idiopathic acute pancreatitis, EUS is an important tool for the detection of biliary sludge/microlithiasis. Ortega *et al.*⁹ evaluated 49 patients with idiopathic acute pancreatitis prospectively with EUS and magnetic resonance cholangiopancreatography (MRCP). EUS could detect etiology in a higher proportion of patients than MRCP (51% *vs.* 20%, $P = 0.001$). Cholelithiasis and biliary sludge (24%) were the most frequent EUS diagnosis and pancreas divisum (8%) was the most frequent MRCP diagnosis. The yield of EUS was lower in patients who had had previous cholecystectomy. Of the various causes of IRAP, the most common cause is said to be occult biliary microlithiasis in up to 73% of patients with IRAP.¹⁰ EUS is about 96% sensitive in diagnosing gallstones including microlithiasis.¹¹ A study has shown that EUS detected biliary microlithiasis in 16% of patients with RAP.¹² Direct visualization of microliths is a much better proof that microliths indeed are present and may be the cause of RAP compared with the microscopic examination of bile for biliary crystals, which is only an indirect evidence of microlithiasis. In addition to biliary microlithiasis, EUS can also diagnose other causes of IRAP such as pancreas divisum, occult tumors, biliary ascariasis etc.

Patients with IARP might have features of underlying CP. A substantial number of patients with IRAP (42%-45%) indeed have evidence of CP.¹³ The reason could be that recurrent attacks of pancreatitis might have led to CP. A similar pathogenetic mechanism has been suggested for patients with hereditary and alcoholic pancreatitis who develop CP after repeated attacks of pancreatitis according to the so-called necrosis — fibrosis hypothesis.¹⁴ The presence of features suggestive of CP on EUS in patients with IRAP indicates that

patients destined to develop CP presented clinically as IRAP.

When should EUS be done in patients with idiopathic pancreatitis? The question regarding the timing of EUS in patients with idiopathic pancreatitis was answered by a study, which compared the diagnostic role of EUS in patients with one or more attacks of idiopathic acute pancreatitis. The study found similar yield in the two groups and the authors suggested that EUS should be done even after one attack of idiopathic acute pancreatitis;¹⁵ however, it should be done preferably after 6-8 weeks of the acute attack to prevent misdiagnosis of CP in the presence of changes of resolving acute pancreatitis. Another recent study compared the yield of EUS and MRCP in 41 patients with idiopathic acute pancreatitis done 2 months after the first attack.¹⁶ EUS diagnosed the cause of pancreatitis more often than MRCP (29% *vs.* 10.5%) and the two modalities combined found a cause in 50% of patients. Thus, it is recommended that all patients with idiopathic acute and RAP should have EUS examination at an appropriate time.

CP

EUS has the ability to detect even the early changes in both pancreatic parenchyma and PD, unlike other imaging tests, which generally detect either parenchymal or ductal abnormalities or that too only in an advanced stage of the disease. EUS plays an important role in the management of CP. The most useful role of EUS is to diagnose early CP in patients who have presented with RAP and do not show evidence of chronicity on other imaging modalities such as CT scan or MRCP. The changes suggestive of CP include both parenchymal (hyperechoic foci, hyperechoic strands, parenchymal lobularity and calcification) and ductal changes (PD dilatation, PD irregularity, hyperechoic PD walls and visible pancreatic side branches) (Fig. 1). Since EUS is quite sensitive to pick up subtle changes in the parenchyma, there is a possibility of over diagnosis of CP by EUS. The sensitivity and specificity of EUS varies with the number of minimum criteria that is used as a cut-off for the diagnosis of CP. In a histological correlation study on surgically resected specimens in 71 patients, three or more EUS criteria provided the best balance of sensitivity (83.3%) and specificity (80%) for predicting pancreatic fibrosis.¹⁷ Other studies have suggested four or more criteria to diagnose early CP. Because histological examination of the pancreas is usually difficult, other gold standards have been used to establish the optimum number of EUS criteria for the diagnosis of CP. EUS has been compared with ERCP and secretin test. In a study of 80 consecutive patients with recurrent pancreatitis, CP was classified as absent/mild/moderate/severe based on EUS/ERCP/secretin stimulation testing.¹⁸ EUS diagnosed the maximum cases of CP. Secretin test had 100% agreement for normal and severe CP patients diagnosed by EUS criteria, but the agreement was poor for mild (13%) and moderate (50%) disease. The agreement between ERCP and EUS specific criteria was excellent for normal (100%), moderate (92%) and severe (100%) CP and are poor for mild (17%)

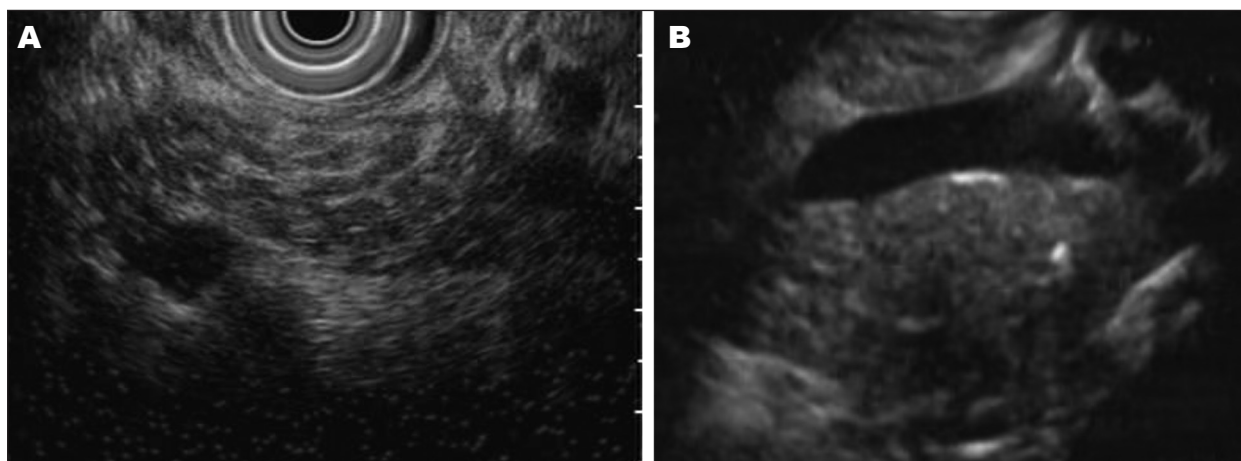


Figure 1. Changes of chronic pancreatitis seen on endoscopic ultrasound imaging; A: Hyperechoic strands and lobularity in pancreatic body; B: Microcalcification in pancreatic body (arrow).

disease. Excellent agreement in severe pancreatitis and in patients without CP highlights the role of EUS in avoiding invasive ERCP for the diagnosis of CP as well as ruling out CP. However, the usefulness of EUS for diagnosing mild disease needs further validation by the long-term follow-up of these patients. Two retrospective studies have reported the follow-up data in such patients. In the first study, 37 patients who had negative CT results and secretin function testing were diagnosed as early CP by means of EUS. During the next 8.5 years, 67% of these patients developed signs of CP on CT or secretin function testing.¹⁹ In the second study, 32 patients with normal ERCP and slightly abnormal EUS was followed-up; 69% of them developed features of CP after a mean duration of 18 months.²⁰

The limitation of EUS is a lack of specificity as some of the features of CP have been found also in elderly people, males, alcoholics, smokers and those with a history of acute pancreatitis.²¹⁻²⁶ One study found five or more features of CP in 39% of patients with dyspepsia and three or more features in 34% of the control group, which highlights its propensity for false positives. Accuracy of EUS can be improved by rational application of this valuable test, interpretation of EUS findings in the clinical context and keeping in mind the results of other imaging tests. Conditions where the suspicion of CP is low, increasing the minimum number of criteria required for the diagnosis, can increase its accuracy.

As EUS is a subjective test, there is bound to be variation in interpretation of its findings, especially among the endosonographers with limited experience. The inter-observer variation is different for various criteria to diagnose CP.²⁷ To improve the diagnostic accuracy and reproducibility, a set of criteria for the EUS diagnosis of CP have been laid down recently based upon the consensus of 32 internationally recognized endosonographers, known as Rosemont criteria.²⁸ Hyperechoic foci with shadowing, main PD calculi and lobularity with honeycombing have been defined as major criteria while the minor criteria for CP include cysts, dilated duct ≥ 3.5 mm, irregular PD

contour, dilated side branches ≥ 1 mm, hyperechoic duct wall, strands, nonshadowing hyperechoic foci and lobularity with noncontiguous lobules. On this basis of these criteria, the findings are classified as “consistent with CP,” “suggestive of CP,” “indeterminate for CP” or “normal.” In a recent multicenter study, 14 experts evaluated 50 recorded videos using the standard 9 EUS criteria (diagnostic: >4 criteria) and the Rosemont criteria (diagnostic: Suggestive of CP or consistent with CP). The inter-observer agreement for the Rosemont classification ($\kappa = 0.65$) was substantial, but moderate for the standard classification ($\kappa = 0.54$); the difference however was not significant. This study used CT and endoscopic pancreatic function test as the gold standard for the diagnosis of CP, without histology. Patients were correctly classified as “definite CP” in 91.2% (standard scoring) and 83.5% (Rosemont scoring); as “mild CP” in 50% (standard scoring) and 42.9% (Rosemont scoring); and “no CP” in 83.3% and 95.2% of cases, on the basis of standard and Rosemont criteria respectively.²⁹ Another recent single center study in 61 patients found moderate inter-observer agreement between classical and Rosemont criteria and suggested that either could be used.³⁰ Thus, keeping in mind the possibility of over-diagnosis of CP by EUS, it will be prudent to use either the Rosemont criteria or take at least four criteria to diagnose CP in the appropriate clinical context.

In patients with established CP, the role of EUS is to diagnose complications of CP such as biliary obstruction, pseudocyst, pseudoaneurysm and malignancy.³¹ One of the most challenging problem is the presence of a mass lesion in patients with CP that could either be inflammatory or malignant in nature. This dilemma cannot be resolved entirely by imaging studies such as CT scan or MRI. EUS is very useful to characterize the mass lesion and offers an opportunity of FNA. Hence, it is quite useful to perform a EUS in patients with CP and a mass lesion. The differentiating features distinguishing inflammatory mass from cancer are: (1) The PD traverses through the benign lesions while cancer causes ductal obstruction, (2) uniform

enlargement of the head of pancreas in the case of an inflammatory mass as opposed to distinct mass lesion due to cancer, (3) smooth obstruction of the bile duct in benign lesions and irregular obstruction due to malignant lesions and (4) vascular and lymph nodal involvement in malignant lesion.³² If however, the findings are equivocal, a FNA should be done. In a study by Ardengh *et al.*³³ based on EUS criteria alone without FNA, 24.1% pseudotumoral masses were misdiagnosed as cancers and 36.4% cancers were erroneously diagnosed as pseudotumoral masses. Cytopathology correctly classified 72.7% malignancies and all benign cases. The sensitivity, specificity, positive and negative predictive values and the diagnostic accuracy of EUS-FNA were 72.7%, 100%, 100%, 95.1% and 95.7%, respectively. Similar low sensitivity, but high specificity of FNA in the setting of CP was reported by Varadarajulu *et al.*³⁴ Overall, EUS coupled with FNA is an ideal test in this difficult clinical situation.

Autoimmune pancreatitis

Two types of autoimmune pancreatitis have been described — type 1 and type 2. Type 1 autoimmune pancreatitis is characterized by onset usually in 6th decade of life, male predominance, raised serum immunoglobulin G4 (IgG4) levels, lymphoplasmacytic infiltration with fibrosis and associated other autoimmune diseases such as retroperitoneal fibrosis, parotitis, autoimmune cholangitis, Sjogren syndrome etc.³⁵ Type 2 autoimmune pancreatitis has recently been defined. It was initially described from Italy and later from other countries.³⁶ It is also known as idiopathic duct centric pancreatitis. It is not an IgG4 related disease.

Type 1 AIP is one of the diseases associated with raised IgG4 levels. It is part of a disorder known as IgG4 related diseases. It is considered as a type of lymphoproliferative disorder of the IgG4 producing cells.³⁷ Serum IgG4 levels are elevated in 70%-80% of patients with autoimmune pancreatitis.³⁸ The radiological features of autoimmune pancreatitis include a diffusely or focal enlargement of pancreas on cross-sectional imaging giving an appearance of a mass lesion, no calcification, a typically sausage shaped pancreas as seen on a CT scan and a narrow main PD on ERCP or MRCP.^{39,40} However, the radiological features are not specific for autoimmune pancreatitis. The most important differential diagnosis of AIP is pancreatic cancer. It is at times very difficult to differentiate the two on cross-sectional imaging. EUS may help in such a differentiation. EUS imaging of AIP shows diffuse hypoechoic enlargement of the pancreas with hypoechoic spots.⁴¹ At times, the enlargement may be segmental and in that case the differentiation between AIP and pancreatic cancer may be even more difficult. The important features on EUS that help differentiate AIP from pancreatic cancer include: (1) non-dilated main PD, (2) duct traversing through the “mass” such as lesion, (3) absence of vascular involvement and (4) associated bile duct involvement in the form of smooth narrowing with significant diffuse wall thickening. Lymphoplasmacytic infiltration with typical inter-lobular

fibrosis is the hallmark of autoimmune pancreatitis.⁴² Immunohistochemistry for IgG4 positive cells is another very specific finding for autoimmune pancreatitis. The most useful role of EUS is to provide an opportunity for tissue diagnosis. EUS guided FNA provides insufficient material for histology, but a recent study has shown good results with EUS-FNA using a 22G needle.⁴³ EUS guided Trucut biopsy is considered to be a very good method of getting pancreatic tissue, but requires expertise, multiple attempts and cost.⁴⁴

THERAPEUTIC EUS IN BENIGN PANCREATIC DISORDERS

EUS is increasingly being used for therapy of patients with benign pancreatic diseases. These include CP, pseudocysts drainage and CPB.

Role of therapeutic EUS in CP

Therapeutic application of EUS has of late been reported in patients with CP. In patients with ductal obstruction due to calculi and/or stricture, endoscopic therapy is generally preferred. If however, the duct cannot be accessed *via* the papilla either due to failed cannulation during ERCP or the obstruction is non-negotiable, the PD can be accessed under EUS guidance for drainage. However, it is a technically demanding procedure because the access to the PD is difficult due to poor orientation with an acute angle between the needle and the PD and thick fibrotic pancreatic parenchyma, which makes the dilatation of the tract across the gastric wall difficult. Although success rates of 68%-71% have been reported, the complication rates were high (5%-43%) and included perforations, bleeding, pancreatitis etc.^{45,46} This procedure should be reserved only in a desperate situation and that too in expert hands. Another probably easier technique is to perform a EUS guided rendezvous procedure. In this procedure, a guidewire is passed into the PD after transgastric puncture of the PD with a 19G needle. The guidewire is maneuvered into the duodenum across the papilla and then the echoendoscope is exchanged for a standard side viewing endoscope. The guidewire is brought out of the biopsy channel of the scope for standard endotherapy to be completed over the wire. A few case series have demonstrated the feasibility and success varying from 25% to 100%, but most were small case series.⁴⁷

EUS guided drainage of pseudocysts and “WON”

Endoscopic drainage of pancreatic pseudocyst has become a standard treatment for the past 20 years or so. Many studies have shown its feasibility, success and safety. The most important pre-requisite for effective endoscopic pseudocyst drainage is a large pseudocyst that is bulging into the gastroduodenal lumen. One of the major complications of endoscopic drainage is bleeding due to puncture of a

vessel in the intervening tract due to the blind nature of the procedure. An important limitation of endoscopic drainage is non-bulging cysts. EUS has been increasingly used for guided drainage of pancreatic pseudocysts. EUS facilitates puncture of the cyst under direct vision, helps avoid blood vessels and is extremely useful in non-bulging cysts. It also differentiates between pseudocyst and other cystic lesions of the pancreas such as cystic neoplasms. In a study of 32 patients referred for endoscopic cystogastrostomy EUS altered management in 37.5% of patients because of various reasons such as the absence of pseudocyst, the lesion was unlikely to be a pseudocyst, significant distance between the gut wall and the cyst, the presence of varices or normal pancreatic parenchyma between the cyst and the gut.⁴⁸ A number of studies have shown EUS guided drainage of pseudocyst to be successful in >90% of cases with minimal complications. Two randomized controlled trials between EUS guided and non-guided endoscopic drainage methods have been reported. Varadarajulu *et al.*⁴⁹ randomized 30 patients to undergo either EUS guided pseudocyst drainage ($n = 15$) or direct endoscopic drainage ($n = 15$). One patient was excluded from the EUS group because of an alternative diagnosis of biliary cystadenoma; all the remaining 14 patients underwent successful drainage (100%). On the other hand, the procedure was technically successful in only 5 of 15 patients (33%) randomized to endoscopic group ($P < 0.001$). All the 10 patients who failed endoscopic drainage underwent successful drainage of the pseudocyst after crossover to EUS. Major procedure-related bleeding was encountered in two patients in whom endoscopic drainage was attempted; one resulted in death and the other necessitated a blood transfusion. Although this study clearly showed superiority of EUS guided drainage of the pseudocyst, the limitations of this study were small sample size, smaller size of the pseudocyst and non-bulging cysts, which are generally not amenable to endoscopic drainage. Another study of 60 patients by Park *et al.*,⁵⁰ showed that the technical success of the EUS guided drainage was significantly higher than that of conventional transmural drainage (94% *vs.* 72%, $P = 0.039$). In cases where conventional drainage failed ($n = 8$) because of nonbulging cysts, EUS guided drainage could be successfully performed in all these patients. However, the success was comparable in patients with bulging pseudocysts. Thus, EUS has proved to be very useful for guided endoscopic drainage of the pseudocysts, especially in non-bulging cysts and should be used whenever possible.

In addition to pseudocysts, EUS guided drainage is being employed for drainage and necrosectomy in patients with WON. The standard management of infected pancreatic necrosis is considered to be necrosectomy. However, it has been recently shown that many patients with infected pancreatic necrosis can be treated conservatively.⁵¹ Those who fail to respond, require necrosectomy, which should preferably be done by a minimally invasive technique.⁵² It has been shown in a few case series that EUS guided drainage and necrosectomy is effective in patients with infected

WON.^{53,54} In such patients with infected or sterile WON, the initial procedure is similar to EUS guided pseudocyst drainage. Subsequently, most patients require multiple sessions of standard endoscopic necrosectomy.

CPB/neurolysis

CPB has long been used for control of pain in patients with pancreatic cancer and CP. Earlier, this was accomplished during surgery or percutaneously under fluoroscopy or CT guidance. EUS has been used for placement of neurolytic agents/blocking agent into the celiac ganglia nerve complex. The celiac artery trunk is easily identified as it exits the aorta using a linear array echoendoscope. A 22-gauge needle is passed through the biopsy channel and under real-time guidance, is advanced through the gastric wall into the area adjacent to celiac trunk. Bupivacaine (0.25%) followed by either ethyl alcohol (98%) or triamcinolone (40 mg) are injected for celiac plexus neurolysis or block respectively. Efficacy of the EUS guided block is better than with fluoroscopic technique. Santosh *et al.*⁵⁵ compared the fluoroscopic and EUS guide CPB in patients with CP. Improvement in pain scores was seen in 70% of subjects undergoing EUS-CPB and 30% in percutaneous block group ($P = 0.044$). Gress *et al.*⁵⁶ compared EUS guided CPB with CT guided CPB for pain relief in CP in a randomized trial and showed that EUS guided block was better than CT guided block. A recent analysis of 9 studies by Kaufman *et al.*⁵⁷ revealed that EUS-guided CPB was effective in 51.4% of patients for managing chronic abdominal pain in CP, whereas EUS-guided CPN was 72.54% effective in managing pain due to pancreatic cancer. In a study of 160 patients, Sahai *et al.*⁵⁸ compared the short-term safety and efficacy of central *vs* bilateral CPB/neurolysis. Bilateral CPB/N was more effective than central CPB/N (mean percent pain reduction 70.4% [61.0-80.0] *vs.* 45.9% [32.7-57.4]; $P = 0.0016$); one patient in bilateral group had laceration of adrenal artery. A recent randomized controlled trial in 40 patients with CP showed that adding triamcinolone did not result in better pain relief following CPB.⁵⁹ EUS guided CPB/neurolysis is a safe procedure and the reported complication rate in a large study was only 1.6% for CPB and 3.2% for celiac plexus neurolysis.⁶⁰ Thus, EUS guided CPB/N has become the preferred mode of celiac ganglion ablation for pain relief in CP and pancreatic cancer. However, it must be realized that CPB should be used sparingly and only as a temporizing measure in patients with CP.

CONCLUSION

EUS is an excellent tool for the evaluation of pancreas. In acute pancreatitis, although EUS has a limited role in the acute setting for predicting prognosis, it is quite useful to diagnose CBD stone before contemplating ERCP. It is of paramount importance in patients with idiopathic acute and RAP to find out the etiology especially to diagnose biliary

microlithiasis and occult tumors. EUS can diagnose early CP with about 80% sensitivity and specificity, especially in the clinical context of recurrent pancreatitis. In patients with established CP, EUS is helpful in diagnosing complications particularly to differentiate inflammatory from malignant mass lesions. EUS and guided FNA are also helpful in diagnosing autoimmune pancreatitis with its ability to rule out cancer, more so if immunohistochemistry for IgG4 is available. From a therapeutic standpoint, it is a very good modality for guided drainage of pseudocyst especially if there is no bulge into the gastric/duodenal lumen. EUS guided CPB is effective albeit in short-term for managing intractable pain due to CP. Thus, besides its established role in patients with pancreatic cancer, EUS is extremely useful in various forms of benign pancreatic diseases both for diagnostic as well as for therapeutic purposes.

REFERENCES

- Chak A, Hawes RH, Cooper GS, *et al.* Prospective assessment of the utility of EUS in the evaluation of gallstone pancreatitis. *Gastrointest Endosc* 1999; 49: 599-604.
- Sotoudehmanesh R, Hooshyar A, Kolahdoozan S, *et al.* Prognostic value of endoscopic ultrasound in acute pancreatitis. *Pancreatol* 2010; 10: 702-6.
- Prat F, Edery J, Meduri B, *et al.* Early EUS of the bile duct before endoscopic sphincterotomy for acute biliary pancreatitis. *Gastrointest Endosc* 2001; 54: 724-9.
- Liu CL, Lo CM, Chan JK, *et al.* Detection of choledocholithiasis by EUS in acute pancreatitis: A prospective evaluation in 100 consecutive patients. *Gastrointest Endosc* 2001; 54: 325-30.
- Liu CL, Fan ST, Lo CM, *et al.* Comparison of early endoscopic ultrasonography and endoscopic retrograde cholangiopancreatography in the management of acute biliary pancreatitis: A prospective randomized study. *Clin Gastroenterol Hepatol* 2005; 3: 1238-44.
- Banks S, Indaram A. Causes of acute and recurrent pancreatitis. Clinical considerations and clues to diagnosis. *Gastroenterol Clin North Am* 1999; 28: 571-89.
- Levy MJ, Geenen JE. Idiopathic acute recurrent pancreatitis. *Am J Gastroenterol* 2001; 96: 2540-55.
- Baillie J. What should be done with idiopathic recurrent pancreatitis that remains 'idiopathic' after standard investigation? *JOP* 2001; 2: 401-5.
- Ortega AR, Gómez-Rodríguez R, Romero M, *et al.* Prospective comparison of endoscopic ultrasonography and magnetic resonance cholangiopancreatography in the etiological diagnosis of "idiopathic" acute pancreatitis. *Pancreas* 2011; 40: 289-94.
- Ros E, Navarro S, Bru C, *et al.* Occult microlithiasis in 'idiopathic' acute pancreatitis: Prevention of relapses by cholecystectomy or ursodeoxycholic acid therapy. *Gastroenterology* 1991; 101: 1701-9.
- Dahan P, Andant C, Lévy P, *et al.* Prospective evaluation of endoscopic ultrasonography and microscopic examination of duodenal bile in the diagnosis of cholecystolithiasis in 45 patients with normal conventional ultrasonography. *Gut* 1996; 38: 277-81.
- Tandon M, Topazian M. Endoscopic ultrasound in idiopathic acute pancreatitis. *Am J Gastroenterol* 2001; 96: 705-9.
- Coyle WJ, Pineau BC, Tarnasky PR, *et al.* Evaluation of unexplained acute and acute recurrent pancreatitis using endoscopic retrograde cholangiopancreatography, sphincter of Oddi manometry and endoscopic ultrasound. *Endoscopy* 2002; 34: 617-23.
- Comfort MW, Gambill EE, Baggenstoss AH. Chronic relapsing pancreatitis: A study of 29 cases without associated disease of the biliary or gastrointestinal tract. *Gastroenterology* 1946; 6: 376-408.
- Yusoff IF, Raymond G, Sahai AV. A prospective comparison of the yield of EUS in primary *vs.* recurrent idiopathic acute pancreatitis. *Gastrointest Endosc* 2004; 60: 673-8.
- Thevenot A, Bournet B, Otal P, *et al.* Endoscopic ultrasound and magnetic resonance cholangiopancreatography in patients with idiopathic acute pancreatitis. *Dig Dis Sci* 2013 [Epub ahead of print].
- Varadarajulu S, Eltoun I, Tamhane A, *et al.* Histopathologic correlates of noncalcific chronic pancreatitis by EUS: A prospective tissue characterization study. *Gastrointest Endosc* 2007; 66: 501-9.
- Catalano MF, Lahoti S, Geenen JE, *et al.* Prospective evaluation of endoscopic ultrasonography, endoscopic retrograde pancreatography, and secretin test in the diagnosis of chronic pancreatitis. *Gastrointest Endosc* 1998; 48: 11-7.
- Catalano MF, Kaul V, Pezanoski J, *et al.* Long term outcome of endosonographically detected minimum criteria for chronic pancreatitis when conventional imaging and functional testing are normal. *Gastrointest Endosc* 2007; 65: AB120.
- Kahl S, Glasbrenner B, Leodolter A, *et al.* EUS in the diagnosis of early chronic pancreatitis: A prospective follow-up study. *Gastrointest Endosc* 2002; 55: 507-11.
- Wiersema MJ, Hawes RH, Lehman GA, *et al.* Prospective evaluation of endoscopic ultrasonography and endoscopic retrograde cholangiopancreatography in patients with chronic abdominal pain of suspected pancreatic origin. *Endoscopy* 1993; 25: 555-64.
- Bhutani MS. Endoscopic ultrasonography: Changes of chronic pancreatitis in asymptomatic and symptomatic alcoholic patients. *J Ultrasound Med* 1999; 18: 455-62.
- Yusoff IF, Sahai AV. A prospective, quantitative assessment of the effect of ethanol and other variables on the endosonographic appearance of the pancreas. *Clin Gastroenterol Hepatol* 2004; 2: 405-9.
- Rajan E, Clain JE, Levy MJ, *et al.* Age-related changes in the pancreas identified by EUS: A prospective evaluation. *Gastrointest Endosc* 2005; 61: 401-6.
- Sahai AV, Zimmerman M, Aabakken L, *et al.* Prospective assessment of the ability of endoscopic ultrasound to diagnose, exclude, or establish the severity of chronic pancreatitis found by endoscopic retrograde cholangiopancreatography. *Gastrointest Endosc* 1998; 48: 18-25.
- Wallace MB, Hawes RH, Durkalski V, *et al.* The reliability of EUS for the diagnosis of chronic pancreatitis: Interobserver agreement among experienced endosonographers. *Gastrointest Endosc* 2001; 53: 294-9.
- Stevens T, Zuccaro G Jr, Dumot JA, *et al.* Prospective comparison of radial and linear endoscopic ultrasound for diagnosis of chronic pancreatitis. *Endoscopy* 2009; 41: 836-41.
- Catalano MF, Sahai A, Levy M, *et al.* EUS-based criteria for the diagnosis of chronic pancreatitis: The Rosemont classification. *Gastrointest Endosc* 2009; 69: 1251-61.
- Stevens T, Lopez R, Adler DG, *et al.* Multicenter comparison of the interobserver agreement of standard EUS scoring and Rosemont classification scoring for diagnosis of chronic pancreatitis. *Gastrointest Endosc* 2010; 71: 519-26.
- Del Pozo D, Poves E, Tabernero S, *et al.* Conventional *vs.* Rosemont endoscopic ultrasound criteria for chronic pancreatitis: Interobserver agreement in same day back-to-back procedures. *Pancreatol* 2012; 12: 284-7.
- Falodia S, Garg PK, Bhatia V, *et al.* EUS diagnosis of a left gastric artery pseudoaneurysm and aneurysmogastic fistula seen with a massive GI hemorrhage (with video). *Gastrointest Endosc* 2008; 68: 389-91.
- Brugge WR, Lee MJ, Kelsey PB, *et al.* The use of EUS to diagnose malignant portal venous system invasion by pancreatic cancer. *Gastrointest Endosc* 1996; 43: 561-7.

33. Ardengh JC, Lopes CV, Campos AD, *et al.* Endoscopic ultrasound and fine needle aspiration in chronic pancreatitis: Differential diagnosis between pseudotumoral masses and pancreatic cancer. *JOP* 2007; 8: 413-21.
34. Varadarajulu S, Tamhane A, Eloubeidi MA. Yield of EUS-guided FNA of pancreatic masses in the presence or the absence of chronic pancreatitis. *Gastrointest Endosc* 2005; 62: 728-36.
35. Okazaki K, Kawa S, Kamisawa T, *et al.* Clinical diagnostic criteria of autoimmune pancreatitis: Revised proposal. *J Gastroenterol* 2006; 41: 626-31.
36. Zamboni G, Lüttges J, Capelli P, *et al.* Histopathological features of diagnostic and clinical relevance in autoimmune pancreatitis: A study on 53 resection specimens and 9 biopsy specimens. *Virchows Arch* 2004; 445: 552-63.
37. Masaki Y, Kurose N, Umehara H. IgG4-related disease: A novel lymphoproliferative disorder discovered and established in Japan in the 21st century. *J Clin Exp Hematop* 2011; 51: 13-20.
38. Morselli-Labate AM, Pezzilli R. Usefulness of serum IgG4 in the diagnosis and follow up of autoimmune pancreatitis: A systematic literature review and meta-analysis. *J Gastroenterol Hepatol* 2009; 24: 15-36.
39. Sahani DV, Kalva SP, Farrell J, *et al.* Autoimmune pancreatitis: Imaging features. *Radiology* 2004; 233: 345-52.
40. Sugumar A, Levy MJ, Kamisawa T, *et al.* Endoscopic retrograde pancreatography criteria to diagnose autoimmune pancreatitis: An international multicentre study. *Gut* 2011; 60: 666-70.
41. Kamisawa T, Anjiki H, Takuma K, *et al.* Endoscopic approach for diagnosing autoimmune pancreatitis. *World J Gastrointest Endosc* 2010; 2: 20-4.
42. Chari ST, Smyrk TC, Levy MJ, *et al.* Diagnosis of autoimmune pancreatitis: The mayo clinic experience. *Clin Gastroenterol Hepatol* 2006; 4: 1010-6.
43. Kanno A, Ishida K, Hamada S, *et al.* Diagnosis of autoimmune pancreatitis by EUS-FNA by using a 22-gauge needle based on the international consensus diagnostic criteria. *Gastrointest Endosc* 2012; 76: 594-602.
44. Mizuno N, Bhatia V, Hosoda W, *et al.* Histological diagnosis of autoimmune pancreatitis using EUS-guided trucut biopsy: A comparison study with EUS-FNA. *J Gastroenterol* 2009; 44: 742-50.
45. Tessier G, Bories E, Arvanitakis M, *et al.* EUS-guided pancreatogastrostomy and pancreatobulbostomy for the treatment of pain in patients with pancreatic ductal dilatation inaccessible for transpapillary endoscopic therapy. *Gastrointest Endosc* 2007; 65: 233-41.
46. Kahaleh M, Hernandez AJ, Tokar J, *et al.* EUS-guided pancreaticogastrostomy: Analysis of its efficacy to drain inaccessible pancreatic ducts. *Gastrointest Endosc* 2007; 65: 224-30.
47. Itoi T, Kasuya K, Sofuni A, *et al.* Endoscopic ultrasonography-guided pancreatic duct access: Techniques and literature review of pancreatography, transmural drainage and rendezvous techniques. *Dig Endosc* 2013; 25: 241-52.
48. Fockens P, Johnson TG, van Dullemen HM, *et al.* Endosonographic imaging of pancreatic pseudocysts before endoscopic transmural drainage. *Gastrointest Endosc* 1997; 46: 412-6.
49. Varadarajulu S, Christein JD, Tamhane A, *et al.* Prospective randomized trial comparing EUS and EGD for transmural drainage of pancreatic pseudocysts (with videos). *Gastrointest Endosc* 2008; 68: 1102-11.
50. Park DH, Lee SS, Moon SH, *et al.* Endoscopic ultrasound-guided vs conventional transmural drainage for pancreatic pseudocysts: A prospective randomized trial. *Endoscopy* 2009; 41: 842-8.
51. Garg PK, Sharma M, Madan K, *et al.* Primary conservative treatment results in mortality comparable to surgery in patients with infected pancreatic necrosis. *Clin Gastroenterol Hepatol* 2010; 8: 1089-94.e2.
52. Mouli VP, Sreenivas V, Garg PK. Efficacy of conservative treatment, without necrosectomy, for infected pancreatic necrosis: A systematic review and meta-analysis. *Gastroenterology* 2013; 144: 333-40.e2.
53. Schrover IM, Weusten BL, Besselink MG, *et al.* EUS-guided endoscopic transgastric necrosectomy in patients with infected necrosis in acute pancreatitis. *Pancreatol* 2008; 8: 271-6.
54. Giovannini M, Pesenti C, Rolland AL, *et al.* Endoscopic ultrasound-guided drainage of pancreatic pseudocysts or pancreatic abscesses using a therapeutic echo endoscope. *Endoscopy* 2001; 33: 473-7.
55. Santosh D, Lakhtakia S, Gupta R, *et al.* Clinical trial: A randomized trial comparing fluoroscopy guided percutaneous technique vs. endoscopic ultrasound guided technique of coeliac plexus block for treatment of pain in chronic pancreatitis. *Aliment Pharmacol Ther* 2009; 29: 979-84.
56. Gress F, Schmitt C, Sherman S, *et al.* A prospective randomized comparison of endoscopic ultrasound- and computed tomography-guided celiac plexus block for managing chronic pancreatitis pain. *Am J Gastroenterol* 1999; 94: 900-5.
57. Kaufman M, Singh G, Das S, *et al.* Efficacy of endoscopic ultrasound-guided celiac plexus block and celiac plexus neurolysis for managing abdominal pain associated with chronic pancreatitis and pancreatic cancer. *J Clin Gastroenterol* 2010; 44: 127-34.
58. Sahai AV, Lemelin V, Lam E, *et al.* Central vs. bilateral endoscopic ultrasound-guided celiac plexus block or neurolysis: A comparative study of short-term effectiveness. *Am J Gastroenterol* 2009; 104: 326-9.
59. Stevens T, Costanzo A, Lopez R, *et al.* Adding triamcinolone to endoscopic ultrasound-guided celiac plexus blockade does not reduce pain in patients with chronic pancreatitis. *Clin Gastroenterol Hepatol* 2012; 10: 186-91, 191.e1.
60. O'Toole TM, Schmulewitz N. Complication rates of EUS-guided celiac plexus blockade and neurolysis: Results of a large case series. *Endoscopy* 2009; 41: 593-7.