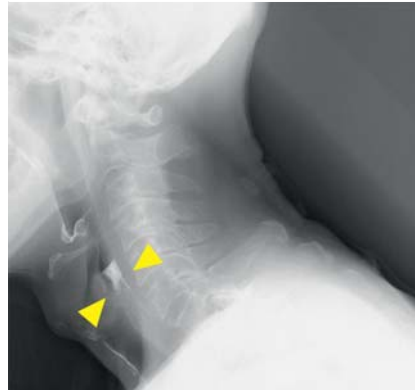


## Fluoroscopic balloon dilatation with antegrade and retrograde endoscopes is useful for complete pharyngoesophageal obstruction after radiation therapy

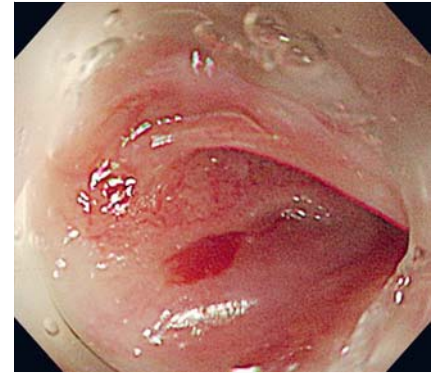


Radiation therapy for pharyngoesophageal cancer can lead to severe esophageal stricture in the irradiation field [1]. Balloon dilation is often the primary mode of treatment [2]; however, in cases with severe stenosis, dilation using antegrade and retrograde endoscopes is useful [3, 4]. However, it may also increase the risk of esophageal perforation [5]. Herein we report a case of fluoroscopic balloon dilation with double endoscopes that was successful for dilating a complete pharyngoesophageal obstruction due to chemoradiation therapy.

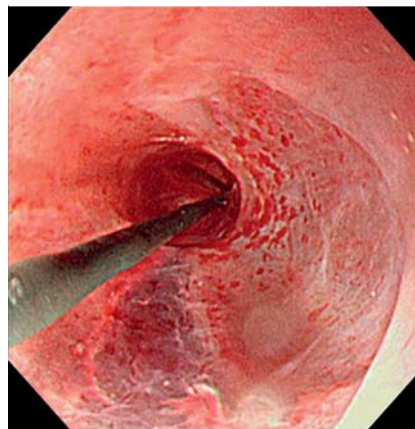
A 74-year-old man underwent chemoradiation therapy (total 7 Gy) for pharyngeal (cStage IVA) and esophageal (cStage I) cancers. Two months later, he became aware of dysfunction in swallowing. Esophageal contrast examination showed complete disruption of the influx of the contrast medium into the pharynx and esophagus (► Fig. 1, ► Fig. 2). Surgical resection was not indicated in this case because the stenosis was located in the upper esophagus and because of the risk of anastomotic insufficiency. Therefore, we performed retrograde endoscopy with percutaneous endoscopic gastrostomy (PEG) for the esophageal obstruction (► Fig. 3). We measured the length and direction of the esophageal obstruction using fluoroscopy. We used oral endoscopy to confirm the insertion of the guidewire, which was inserted through the retrograde endoscope via PEG. The guidewire was then grabbed with biopsy forceps using an oral endoscope and dilation of the stenosis was successful (► Fig. 4, ► Video 1). Furthermore, there were no complications, such as perforation or bleeding, after performing the procedure under fluoroscopy. No recurrence of obstruction was reported for 6 months after the dilation procedure, and the patient could consume food orally.



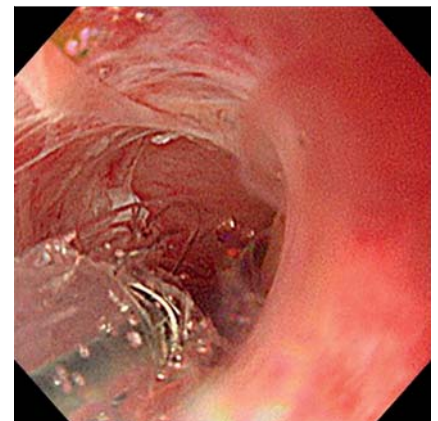
► Fig. 1 Fluoroscopy depicting the contrast agents remaining in the upper esophagus.



► Fig. 2 The esophagoscopy showed the complete esophageal obstruction.



► Fig. 3 The mucosa on the anal side was more vulnerable than the stenosis of the esophagus. This was because there was no passage of food and drink for a long time.



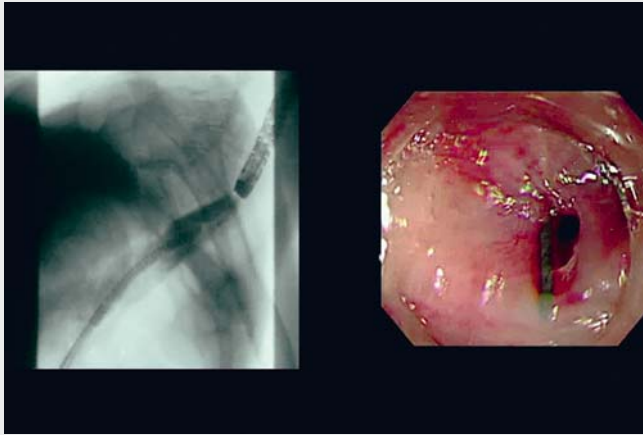
► Fig. 4 Upon balloon dilation of the esophageal stenosis, perforation was prevented by using a combination of fluoroscopy and anal endoscopy.

In conclusion, fluoroscopic balloon dilation using double endoscopes is useful for dilation in the case of complete pharyngoesophageal obstruction.

Endoscopy\_UCTN\_Code\_TTT\_1AO\_2AN

### Competing interests

The authors declare that they have no conflict of interest.



**Video 1** Fluoroscopic balloon dilatation using double endoscopes is useful for dilation in the case of complete pharyngoesophageal obstruction.

## The authors

**Gozo Fukushi**, **Ai Fujimoto**, **Kenzo Hara**,  
**Yusuke Nishikawa**, **Takahisa Matsuno**,  
**Takahisa Matsuda**, **Yoshinori Igarashi**

Division of Gastroenterology and Hepatology,  
Toho University Omori Medical Center, Tokyo,  
Japan

## Corresponding author

### **Ai Fujimoto, MD**

Division of Gastroenterology and  
Hepatology, Toho University Omori Medical  
Center, 6-11-1 Omorinishi, Ohta-ku, Tokyo  
143-8541, Japan  
Fax: +81-3-3248-2463  
ai.fujimoto@med.toho-u.ac.jp

## References

[1] Tuna Y, Koçak E, Dinçer D et al. Factors affecting the success of endoscopic bougia dilatation of radiation-induced esophageal stricture. *Dig Dis Sci* 2012; 57: 424–428. doi:10.1007/s10620-011-1875-8

[2] Hu H-T, Shin JH, Kim JH et al. Fluoroscopically guided balloon dilation for pharyngoesophageal stricture after radiation therapy in patients with head and neck cancer. *AJR Am J Roentgenol* 2010; 194: 1131–1136. doi:10.2214/AJR.09.3345

[3] Lew RJ, Shah JN, Chalian A et al. Technique of endoscopic retrograde puncture and dilatation of total esophageal stenosis in patients with radiation-induced strictures. *Head Neck* 2004; 26: 179–183. doi:10.1002/hed.10365

[4] Bueno R, Swanson SJ, Jaklitsch MT et al. Combined antegrade and retrograde dilation: a new endoscopic technique in the management of complex esophageal obstruction. *Gastrointest Endosc* 2001; 54: 368–372. doi:10.1067/mge.2001.117517

[5] Dellon ES, Cullen NR, Madanick RD et al. Outcomes of a combined antegrade and retrograde approach for dilatation of radiation-induced esophageal strictures (with video). *Gastrointest Endosc* 2010; 71: 1122–1129. doi:10.1016/j.gie.2009.12.057

## Bibliography

*Endoscopy* 2022; 54: E931–E932

DOI 10.1055/a-1858-4558

ISSN 0013-726X

published online 5.7.2022

© 2022. The Author(s).

This is an open access article published by Thieme under the terms of the Creative Commons Attribution-NonDerivative-NonCommercial License, permitting copying and reproduction so long as the original work is given appropriate credit. Contents may not be used for commercial purposes, or adapted, remixed, transformed or built upon. (<https://creativecommons.org/licenses/by-nc-nd/4.0/>)

Georg Thieme Verlag KG, Rüdigerstraße 14,  
70469 Stuttgart, Germany



## ENDOSCOPY E-VIDEOS

<https://eref.thieme.de/e-videos>



*Endoscopy E-Videos* is an open access online section, reporting on interesting cases

and new techniques in gastroenterological endoscopy. All papers include a high quality video and all contributions are freely accessible online. Processing charges apply (currently EUR 375), discounts and waivers acc. to HINARI are available.

This section has its own submission website at

<https://mc.manuscriptcentral.com/e-videos>