




OPEN ACCESS

Campylobacter jejuni pancolitis complicated by toxic megacolon in an immunocompetent host

Syed Wajih Ul Hassan ¹, Sheena Nadeem Alam ¹, Nazar Ulla Syed ²,
Muhammad Ismail³

¹General Medicine, Blackpool Victoria Hospital, Blackpool, UK
²Infectious Diseases, Blackpool Teaching Hospitals NHS Foundation Trust, Blackpool, UK
³Infectious Diseases, Blackpool Victoria Hospital, Blackpool, UK

Correspondence to
Dr Syed Wajih Ul Hassan;
syed.hassan25@nhs.net

Accepted 25 July 2022

SUMMARY

This is an unusual case of a middle-aged, immunocompetent man who developed toxic megacolon (TM) secondary to infection with a normally harmless bug, *Campylobacter jejuni*. He presented with diarrhoea, fever and abdominal pain. Faecal cultures were positive for *C. jejuni*. However, the patient did not show significant improvement after a trial of intravenous antibiotics. Bowel segment dilation on a CT scan combined with systemic signs (fever) led to the diagnosis of TM. A subtotal colectomy was planned but an unexpected positive response to conservative therapy deferred the surgery. Our case emphasises the crucial role that bowel rest and good nutritional support play in treating TM of infectious aetiology and how it can help avoid the need for a life-altering subtotal colectomy and ileostomy. For such presentations we also highlight how empirical steroid therapy or diagnostic sigmoidoscopy for suspected underlying ulcerative colitis can be detrimental to patient outcomes.

BACKGROUND

Campylobacter is the leading cause of bacterial diarrhoea worldwide, affecting approximately 25–30 per 100 000 people.¹ In the UK alone, it accounts for an estimated 500 000 cases annually.² Most of these cases follow a typical clinical course; an acute diarrhoeal illness which is usually self-limiting.³ Immunosuppressed individuals experience a severe or prolonged disease course.⁴ We present an unusual case of *Campylobacter jejuni*-induced toxic megacolon (TM) in an immunocompetent individual which responded to conservative treatment.

TM is defined as non-obstructive segmental or total colonic distension of ≥ 5.5 cm in the presence of systemic toxicity.⁵ It typically arises as a complication of inflammatory bowel disease (IBD) or *Clostridium difficile*-associated colitis⁶ and cases associated with *Campylobacter* are quite rare. There are only 14 case reports describing TM in the setting of *Campylobacter* infection and most were published before 2000.^{7,8} Over half of these cases were treated surgically, in contrast to our patient, who improved with conservative therapies.

This case demonstrates the benefits of close monitoring of a patient infected with a normally harmless organism, and emphasises the need to consider bowel rest and parenteral nutrition early in cases refractory to optimum medical management, as it may potentially help avoid more invasive and life-altering procedures.

CASE PRESENTATION

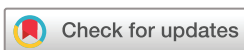This is the case of a middle-aged man who presented with diarrhoea, abdominal cramps, lethargy, loss of appetite and weight loss for the past 12 days. He denied recent antibiotic use or travel to forests, lakes or abroad; however, he did eat out frequently. Medical, family and drug history was unremarkable. On inspection, he looked pale and sick but was oriented to time, place and person. He was feverish (38.4°C), with a respiratory rate of 22 breaths per minute, but was otherwise vitally stable. Peripheries were cold and he appeared dehydrated. Abdominal examination revealed tenderness and guarding in the left lower quadrant and hyperactive bowel sounds. No per rectal bleed was noted. All other systemic examinations were unremarkable.

INVESTIGATIONS

On presentation, he had high inflammatory markers (white blood cell count $16.0 \times 10^9/L$ and C-reactive protein 429.8 mg/L), an electrolyte imbalance (Na 124 mmol/L), low creatinine (56 $\mu\text{mol/L}$) and low albumin (28 g/L). An abdominal X-ray revealed a dilated transverse and descending colon with no air-fluid levels. Chest X-ray showed normal lung fields with no gas under the diaphragm. CT abdomen-pelvis was suggestive of modest pancolitis with no complicating features. Faeces culture grew *C. jejuni*. Other common pathogens such as *Shigella*, *Salmonella* and *Escherichia coli* O157 were excluded using various faeces culture media. Stool microscopy excluded *Entamoeba*. Combined enzyme immunoassays excluded *Giardia* and *Cryptosporidium* antigens in stool. *Clostridium difficile* was also excluded on three consecutive stool enzyme-linked immunosorbent assays. He tested negative for HIV. Both blood and urine cultures showed no bacterial growth after 48 hours of incubation.

DIFFERENTIAL DIAGNOSIS

The top differential diagnosis to exclude was IBD. Faecal calprotectin could not be tested as the stools were so frequent and loose that the gut transit time was insufficient to allow the protein to collect to a detectable level in the stool. A careful clinical assessment was made of the ocular, oral, musculoskeletal and dermatological systems to look for extraintestinal manifestations of IBD. The patient was noted to have developed symmetrical, erythematous, non-blanching patches on the lower limbs (see figure 1). The rash resolved by itself; however, it begged the question of whether this was an extraintestinal manifestation of IBD or of *Campylobacter*



© BMJ Publishing Group Limited 2022. Re-use permitted under CC BY-NC. No commercial re-use. See rights and permissions. Published by BMJ.

To cite: Hassan SWU, Alam SN, Syed NU, et al. *BMJ Case Rep* 2022;**15**:e249801. doi:10.1136/bcr-2022-249801

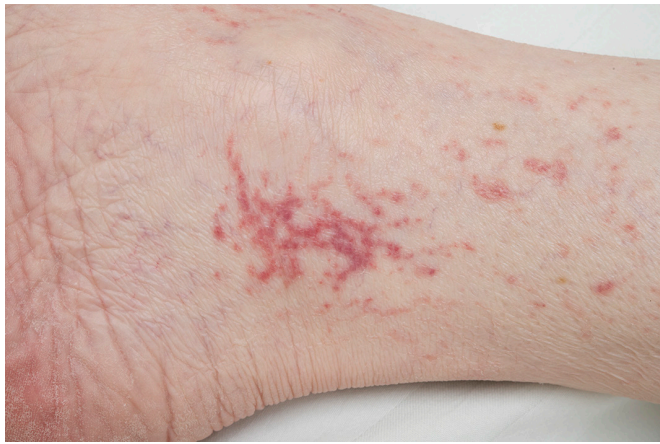

Figure 1 An erythematous, non-blanching patch on the right ankle.

infection. Given the high risk of perforation, a sigmoidoscopy was not attempted and hence IBD could not be fully excluded during the acute phase of the illness. The growth of *Campylobacter* on stool culture provided evidence for infective colitis and other common organisms were also excluded. Finally, the patient was not on medications that might have resulted in TM and potassium levels remained within normal range throughout admission.

TREATMENT

He received a single dose of intravenous amoxicillin, metronidazole and gentamicin as empiric therapy, along with intravenous crystalloids to correct his hydration status and symptomatic treatment for his fever, nausea and abdominal pain. Intravenous clarithromycin 500 mg two times a day was initiated as empiric treatment for severe *Campylobacter enteritis* but no significant clinical improvement was observed after 6 days. Antibiotics were changed to intravenous ertapenem 1 g once a day, but this too did not bring about significant improvement and was stopped after 7 days.

His temperature spiked on day 8 of admission (38.2°C). Repeat abdominal X-ray was suggestive of colitis and dilation in the transverse colon, suspicious of TM. A subsequent CT abdomen-pelvis showed a dilation of 7 cm of the transverse colon. This, combined with signs of systemic toxicity, confirmed the diagnosis of TM. He was immediately kept nil by mouth for a day. A significant drop in CRP was observed over 24 hours from 218.3 mg/L to 128.6 mg/L. Considering this improvement, the surgical team deferred surgical intervention and restarted his feed.

His temperature spiked again on day 16 of admission and he developed excruciating left-sided abdominal pain. CT abdomen-pelvis on the 16th day showed a segmental bowel loop dilation of 9.3 cm (see figure 2). Medical therapy was declared to have failed, and a subtotal colectomy with end ileostomy was planned as a fast-track elective procedure. He was kept on bowel rest and total parenteral nutrition (TPN) was initiated through a peripherally inserted central catheter (PICC) with a 6 g nitrogen bag at 35 mL/hour. However, a significant improvement in clinical and biochemical parameters (CRP dropped from 248.3 mg/L to 87.2 mg/L) was observed over the next 72 hours. CT abdomen-pelvis showed a reduction in the size of bowel segments for the first time since admission (transverse colon calibre 6.2 cm).

On day 23 of admission, the patient again spiked a fever (38.8°C) and became hypotensive (70/40 mm Hg). He was

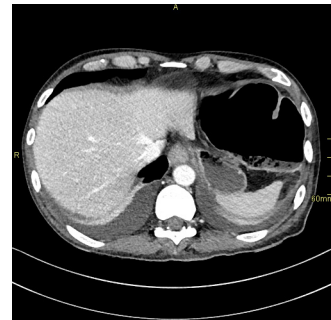

Figure 2 A CT image of the dilated transverse colon.

resuscitated with intravenous crystalloids and given an empirical dose of intravenous teicoplanin for suspected catheter-related bloodstream infection. Central and peripheral blood cultures confirmed the growth of coagulase-negative *Staphylococcus* species. The PICC was removed and regular linezolid 600 mg two times a day was given. An echocardiogram did not show evidence of infective endocarditis. Linezolid was stopped after 10 days when follow-up blood cultures were negative for growth of any organisms after 48 hours of incubation.

OUTCOME AND FOLLOW-UP

A repeat CT abdomen-pelvis on day 31 of admission showed an improvement in the transverse colon which was now 4 cm in calibre. Subsequently, flexible sigmoidoscopy was attempted and revealed a normal mucosa from anus to distal descending colon. The biopsy showed no signs of IBD or dysplasia. The patient was now eating a regular diet and bowel movements had settled. He was discharged with no medications to take home and was planned to be followed up in 6 weeks.

DISCUSSION

C. jejuni is a major public health problem in England, with a rising incidence despite food hygiene awareness efforts made by national organisations.⁹ While hydration and electrolyte correction remain the cornerstone of therapy for most, some clinical situations warrant the use of antibiotics. In our case, the patient had a protracted 12-day history of severe symptoms that fit the criteria for antibiotic use. The first-line antibiotic for confirmed *C. jejuni* infection as per the latest NICE guidelines is clarithromycin.^{10 11} However, we changed to ertapenem after poor initial response to the macrolide, which had the additional advantage of once-a-day dosing. A fluoroquinolone was not used out of fear of antibiotic resistance.¹²

While TM is a potential complication of any inflammatory condition of the colon, it is usually associated with severe IBD or *Clostridium difficile* pseudomembranous colitis.^{6 13 14} It has a frightening overall mortality rate of 19%, and 41% in cases of perforation.¹⁵ While individuals with comorbidities like renal failure and hypertension are at higher risk of progressing to TM,¹⁶ our patient did not have any of these. Interestingly, neither did most of the other known cases of TM secondary to *Campylobacter*. It is postulated that TM results from a loss of smooth muscle tone in the colon, which commonly results from the transmural spread of acute mucosal inflammation. One of the implicated chemical mediators is nitric oxide.¹⁷ It is differentiated from other pathologies that may precipitate colonic dilation, like Ogilvie syndrome, by the presence of systemic toxicity.⁶ In addition to having a transverse colon diameter of 9.3 cm, our patient suffered from fever, anaemia, leucocytosis,

hypotension, electrolyte imbalance and low albumin, fitting the diagnostic criteria for TM.¹⁸

An obvious differential diagnosis to exclude in this case was IBD. In addition to the clinical context, an endoscopic and histological evaluation is necessary to rule out Crohn's and ulcerative colitis.¹⁹ However, given the radiological evidence of bowel loop dilation we felt it was unsafe to scope the patient for diagnostic purposes due to the risk of impending perforation. Empirical steroids were avoided because of the risk of masking peritoneal signs; an indicator for surgical intervention. We noted worse outcomes in previous similar cases where empirical steroids were used.^{20–23} Instead, we used serial CT scans and frequent clinical re-evaluation to monitor for perforation and progressive bowel loop dilation. A flexible sigmoidoscopy was attempted after the patient had shown significant reduction in bowel diameter and definitively excluded IBD after histological examination of biopsy specimens.

Indications for surgical intervention include perforation, progressive bowel loop dilation and clinical deterioration.²⁴ The latter two were present on two occasions during the clinical course of this patient and a surgical evaluation was completed for subtotal colectomy with end ileostomy. However, both times the patient showed significant clinical and biochemical improvement after being kept on bowel rest. Such a sustained improvement with bowel rest and TPN was unique to our case compared with all the previous known case reports where parenteral nutrition was used.^{8 21 23} While the literature is rich in dietary interventions for IBD, the effect of bowel rest and TPN in cases of infective colitis complicated by TM refractory to medical treatment has not been thoroughly researched. We theorise that bowel rest allowed for effective decompression of the colon, reducing the risk of perforation and the TPN helped to nutritionally replenish the patient.

Cutaneous lesions are rare in *C. jejuni* infections. The pathophysiology behind these skin lesions is unknown but may be distinct for every lesion. According to Roberts *et al*,²⁵ erythema nodosum and cellulitis were commonly associated with *Campylobacter* infection. However, the rash seen in our patient was not a typical pattern for either of those. We speculate it could have been the result of immunological sequelae of severe *Campylobacter* infection, particularly a leucocytoclastic vasculitis. However, due to lack of an in-house dermatology facility we were unable to investigate this further.

Like previous similar cases, the development of TM in our patient was preceded by a prolonged course of diarrhoeal illness. But unlike most of these cases, he did not require surgical intervention for complete recovery. A common recurring theme in all cases that required surgical intervention was the use of empiric steroids and the decision to go for either colonoscopy or sigmoidoscopy. However, the clinical course of our patient was complicated by the development of PICC-associated sepsis. The systemic upset resulting from this line sepsis was difficult to differentiate from worsening toxicity from the megacolon. The growth of coagulase-negative *Staphylococci* on blood cultures and quick response to pathogen-directed therapy allowed differentiation between the two. Catheter-related bloodstream infections are one of the few risks associated with TPN^{26 27} and should be taken into consideration so as not to wrongfully attribute systemic toxicity to treatment failure instead of a treatable iatrogenic cause.

Acknowledgements We would like to thank Dr Nazar Ulla Syed (Consultant Infectious Diseases) for being the clinical lead in managing this case. His evidence-based approach and clinical judgement led to a very successful outcome for this

Learning points

- ▶ *Campylobacter*-associated diarrhoea is a self-limiting illness in most cases; however, life-threatening toxic megacolon should be considered as a possible sequela in all patients unresponsive to initial medical therapy.
- ▶ The use of empiric steroids with an infective aetiology can lead to worse outcomes and should be avoided till there is evidence suggestive of an inflammatory cause.
- ▶ Diagnostic scoping of a patient with dilated bowel loops on radiology leads to worse outcomes and should be avoided till response to therapy is evident.
- ▶ The use of extended bowel rest and total parenteral nutrition preoperatively can allow for effective decompression and nutritional repletion, leading to better outcomes.
- ▶ Skin rashes are a rare manifestation of severe *Campylobacter* infection which warrant the prolonged use of antibiotics.

complex case. We would also like to acknowledge the efforts of our gastroenterology and surgery teams and thank them for their support. Finally, we extend our gratitude to the entire multidisciplinary team that helped care for this patient and played a valuable role in improving his outcome.

Contributors SWUH and SNA are joint first authors and were equally responsible for the planning and design of this case report. Acquisition of patient data from the case notes was performed by SWUH and MI. An extensive literature search was conducted by SNA. The case presentation was written by SWUH, NUS wrote the summary while SNA wrote the background. The discussion was authored by SWUH and SNA. NUS and MI played a supervisory role in writing up the case report. All four authors proofread the report for any errors and omissions.

Funding The authors have not declared a specific grant for this research from any funding agency in the public, commercial or not-for-profit sectors.

Competing interests None declared.

Patient consent for publication Consent obtained directly from patient(s).

Provenance and peer review Not commissioned; externally peer reviewed.

Open access This is an open access article distributed in accordance with the Creative Commons Attribution Non Commercial (CC BY-NC 4.0) license, which permits others to distribute, remix, adapt, build upon this work non-commercially, and license their derivative works on different terms, provided the original work is properly cited and the use is non-commercial. See: <http://creativecommons.org/licenses/by-nc/4.0/>.

Case reports provide a valuable learning resource for the scientific community and can indicate areas of interest for future research. They should not be used in isolation to guide treatment choices or public health policy.

ORCID iDs

Syed Wajih Ul Hassan <http://orcid.org/0000-0001-7265-6816>
Sheena Nadeem Alam <http://orcid.org/0000-0003-3032-1481>
Nazar Ulla Syed <http://orcid.org/0000-0003-0087-0762>

REFERENCES

- 1 Azer SA, Tuma F. Infectious Colitis. In: *StatPearls*. Treasure Island: StatPearls Publishing, 2022. <https://www.ncbi.nlm.nih.gov/books/NBK544325/>
- 2 Tam CC, Rodrigues LC, Viviani L, *et al*. Longitudinal study of infectious intestinal disease in the UK (IID2 study): incidence in the community and presenting to general practice. *Gut* 2012;61:69–77.
- 3 Fitzgerald C. *Campylobacter*. *Clin Lab Med* 2015;35:289–98.
- 4 Barker CR, Painsent A, Swift C, *et al*. Microevolution of *Campylobacter jejuni* during long-term infection in an immunocompromised host. *Sci Rep* 2020;10:e10109.
- 5 Harbord M, Eliakim R, Bettenworth D. Third European evidence-based consensus on diagnosis and management of ulcerative colitis. Part 2: current management. *J Crohns Colitis* 2017;11:769–784. Erratum in: *J Crohns Colitis* 2017;11:1512.
- 6 Autenrieth DM, Baumgart DC. Toxic megacolon. *Inflamm Bowel Dis* 2012;18:584–91.
- 7 Kwok M, Maurice A, Lisek C, *et al*. *Campylobacter* colitis: rare cause of toxic megacolon. *Int J Surg Case Rep* 2016;27:141–3.
- 8 Clark CLT, Murray EV. *Campylobacter colitis* leads to toxic megacolon and multiple organ failure. *BMJ Case Rep* 2020;13:e233373.

- 9 Public Health England. Research and analysis: Campylobacter data 2008 to 2017, 2017. Available: <https://www.gov.uk/government/publications/campylobacter-infection-annual-data/campylobacter-data-2008-to-2017>
- 10 National Institute of Health and Care Excellence. Summary of antimicrobial prescribing guidance - managing common infections, 2020. Available: <https://cks.nice.org.uk/topics/gastroenteritis/management/adult-gastroenteritis/>
- 11 Public Health England. Recommendations for the public health management of gastrointestinal infections 2019. principles and practice. London PHE publications; 2020. https://assets.publishing.service.gov.uk/government/uploads/system/uploads/attachment_data/file/861382/management_of_gastrointestinal_infections.pdf
- 12 Allos BM. Campylobacter jejuni infections: update on emerging issues and trends. *Clin Infect Dis* 2001;32:1201–6.
- 13 Ausch C, Madoff RD, Grant M, *et al*. Aetiology and surgical management of toxic megacolon. *Colorect Dis* 2006;8:195–201.
- 14 Martin JSH, Monaghan TM, Wilcox MH. Clostridium difficile infection: epidemiology, diagnosis and understanding transmission. *Nat Rev Gastroenterol Hepatol* 2016;13:206–16.
- 15 Gan SI, Beck PL. A new look at toxic megacolon: an update and review of incidence, etiology, pathogenesis, and management. *Am J Gastroenterol* 2003;98:2363–71.
- 16 Doshi R, Desai J, Shah Y, *et al*. Incidence, features, in-hospital outcomes and predictors of in-hospital mortality associated with toxic megacolon hospitalizations in the United States. *Intern Emerg Med* 2018;13:881–7.
- 17 Mourelle M, Casellas F, Guarner F, *et al*. Induction of nitric oxide synthase in colonic smooth muscle from patients with toxic megacolon. *Gastroenterology* 1995;109:1497–502.
- 18 Jalan KN, Sircus W, Card WI, *et al*. An experience of ulcerative colitis. *Gastroenterology* 1969;57:68–82.
- 19 Matsuoka K, Kobayashi T, Ueno F, *et al*. Evidence-Based clinical practice guidelines for inflammatory bowel disease. *J Gastroenterol* 2018;53:305–53.
- 20 Anderson JB, Tanner AH, Brodribb AJM. Toxic megacolon due to Campylobacter colitis. *Int J Colorectal Dis* 1986;1:58–9.
- 21 Jackson TL, Young RL, Thompson JS, *et al*. Toxic megacolon associated with Campylobacter jejuni colitis. *Am J Gastroenterol* 1999;94:280–2.
- 22 Pockros PJ, Weiss JB, Strum WB. Toxic megacolon complicating Campylobacter enterocolitis. *J Clin Gastroenterol* 1986;8:318–9.
- 23 Vyas SK, Law NN, Hill S, *et al*. Toxic megacolon with late perforation in Campylobacter colitis - a cautionary tale. *Postgrad Med J* 1993;69:322–4.
- 24 Desai J, Elnaggar M, Hanfy AA, *et al*. Toxic megacolon: background, pathophysiology, management challenges and solutions. *Clin Exp Gastroenterol* 2020;13:203–10.
- 25 Roberts SC, Stone SM, Sutton SH, *et al*. Cutaneous manifestations of Campylobacter jejuni infection: A case report and review of the literature. *Infect Dis Clin Pract* 2020;28:61–3.
- 26 Peter JV, Moran JL, Phillips-Hughes J. A metaanalysis of treatment outcomes of early enteral versus early parenteral nutrition in hospitalized patients. *Crit Care Med* 2005;33:213–20.
- 27 Singer P, Berger MM, Van den Bergh G, *et al*. ESPEN guidelines on parenteral nutrition: intensive care. *Clin Nutr* 2009;28:387–400.

Copyright 2022 BMJ Publishing Group. All rights reserved. For permission to reuse any of this content visit <https://www.bmj.com/company/products-services/rights-and-licensing/permissions/>
 BMJ Case Report Fellows may re-use this article for personal use and teaching without any further permission.

Become a Fellow of BMJ Case Reports today and you can:

- ▶ Submit as many cases as you like
- ▶ Enjoy fast sympathetic peer review and rapid publication of accepted articles
- ▶ Access all the published articles
- ▶ Re-use any of the published material for personal use and teaching without further permission

Customer Service

If you have any further queries about your subscription, please contact our customer services team on +44 (0) 207111 1105 or via email at support@bmj.com.

Visit casereports.bmj.com for more articles like this and to become a Fellow