

The Combined Use of a Non-Invasive Skin-Stretching Device and the Negative-Pressure Wound Therapy Technique in the Treatment of Postoperative Diabetic Foot

Liangchen Wang*

Chenrui Wang*

Hongmei Chen

Ying Chen

Juan Li

Li Xiao

Di Zhu

Caizhe Yang

Department of Endocrinology, Air Force Medical Center, PLA, Beijing, 100142, People's Republic of China

*These authors contributed equally to this work

Objective: The present study explored the effectiveness of using a non-invasive skin-stretching device (NSSD) combined with negative-pressure wound therapy (NPWT) for the postoperative wound repair of diabetic foot (DF) gangrene.

Methods: The treatment group in this study involved 42 patients with Wagner grade 3–4 DF and undergone concomitant toe amputation or debridement, who were given NPWT combined with the use of a NSSD. The control group comprised 42 patients with similar trauma areas ($\pm 20\%$) that were matched at a ratio of 1:1. Following surgery, these patients received NPWT combined with the use of conventional dressings. A comparison was made of the postoperative wound healing rates and wound healing times of the two groups, with Kaplan–Meier survival analysis being used to compare the healing rate over time.

Results: The three-month wound healing rate was higher in the treatment group than in the control group (38 of 42 [90.5%] vs 25 of 42 [59.5%], $p = 0.002$), and the wound healing time was shorter in the treatment group (44 days [95% CI 40.0–48.0]) than that in the control group (76 days [95% CI 63.0–89.0], $p = 0.000$). Taking the end of the final NPWT as the starting point, the comparison of wound healing time revealed that this period was shorter in the treatment group than that in the control group and the difference was statistically significant (11 days [95% CI 9.0–13.0] vs 42 days [95% CI 23.0–ND], $p = 0.000$).

Conclusion: The use of the NPWT technique combined with a NSSD can shorten the wound healing time and improve the wound healing rate of DF gangrene patients during the postoperative wound repair period.

Keywords: diabetic foot, negative-pressure wound therapy, wound healing, skin-stretching device

Introduction

Diabetic foot (DF) is a serious complication of diabetes, and 15–25% of diabetic patients will develop this condition during their lifetime, with 11–24% of them requiring partial amputation of the foot or lower extremity.^{1,2} The two-year postoperative survival rate among patients with an amputation above the ankle is 48%, which is significantly lower than the 80% survival rate among patients treated with limb preservation.³ Accordingly, for the management of DF, limb preservation therapy should be the first option as frequently as possible to improve the postoperative survival rate among patients. However, due to various factors, such as occlusive arteriosclerosis, multi-drug resistant

Correspondence: Caizhe Yang
Department of Endocrinology, Air Force Medical Center, PLA, Beijing, 100142, People's Republic of China
Tel/Fax +86 1066928242
Email caizheyang06@outlook.com

bacterial infections, neuropathy, and inappropriate methods of debridement and dressing change, limb salvage treatment in *DF* cases has resulted in delayed wound healing, prolonged treatment cycles, and a heavy economic burden on families and society.^{4–6} Improving the healing rate and shortening the healing time of *DF* wounds has been a key issue in the treatment of the condition. Implementing guideline-based optimal care for *DF* is likely to be cost-effective within a health resource-limited setting.⁷ Although negative-pressure wound therapy (NPWT) is costly, the International Working Group on the Diabetic Foot (IWGDF, 2019) guidelines for the prevention and management of *DF* recommend considering the use of NPWT to reduce wound size, in addition to best standard of care after surgery. NPWT appears to stimulate granulation tissue formation and contraction of the wound.⁸ In addition to NPWT, the IWGDF also recommends that moisturized dressings, sucrose-octasulfate impregnated dressings, and autologous combined leucocyte, platelet, and fibrin patches be considered during the wound repair phase alongside the best standard of care.⁹ However, the current guidelines for the management of *DF* do not recommend a skin-stretching device (SSD) to promote wound healing during wound repair in the case of *DF*.^{9,10} These SSDs are primarily used in skin defect wounds with avoidance of skin grafts or skin flap grafts.^{11,12} Recent studies have shown that invasive SSDs can shorten the healing time of wounds in *DF* cases.¹³ However, this technique may also cause further injury to the tissue, and excessive tension may cause normal tissue injury and an increased risk of necrosis.¹⁴ Fortunately, an adhesive non-invasive skin-stretching device (NSSD) has a low risk of causing necrosis of the surrounding wound tissue.¹⁵ Currently, no studies have been conducted on using adhesive NSSDs combined with NPWT for the treatment of *DF*. Therefore, the present study aims to provide relevant evidence for clinical application by observing the efficacy and advantages of the combination of these two techniques during the process of postoperative wound repair of *DF*.

Materials and Methods

Study Subjects

In the present retrospective study, the data of 42 patients treated with NPWT and NSSD were collected. They were known as the treatment group. These patients were aged between 30–80 years old and had been hospitalized in our hospital between May 2017 and November 2020 with Wagner grade 3–4 *DF* gangrene and undergone toe amputation or debridement. Forty-two other patients were matched

with them based on their similar postoperative wound area ($\pm 20\%$) to form the control group. Both groups had *DF* wounds that were not suitable for the application of primary surgery suture. The reasons for this non-suitability were large wound defects, high wound tension following evaluation, or dead space in a deep wound after suture. In both groups, the wound depth was 0.5–2.5 cm, and there was no obvious necrotic tissue in the postoperative wound. The ankle-brachial index in the affected foot was ≥ 0.6 , and there was no severe infection (based on the IWGDF/Infectious Diseases Society of America classification criteria).¹⁶ Diabetic foot wounds with osteomyelitis required surgical resection of the infected bone, and anti-infection therapy was given for one week after surgery. The inclusion and exclusion criteria are shown in Table 1.

Secretions from deep or bone tissue were taken from all enrolled patients, placed in sterilized test tubes, and sent for examination within one hour. Specimens were inoculated on Columbia blood-based agar plates and incubated for 18–24 h at 35–37°C. Quality control procedures, such as sterility assay and efficacy testing, were performed before conducting the experiment. The VITEK[®] 2 Compact automatic bacterial identification fractionator and special bacterial identification

Table 1 Inclusion and Exclusion Criteria

Inclusion Criteria	Exclusion Criteria
Age 30–80 years old	The use of corticosteroids, immunosuppressive medications, or chemotherapy
ABI ≥ 0.6	The use of hyperbaric oxygen therapy
Wagner grade 3–4 <i>DF</i>	The use of recombinant or autologous growth factor products
After concomitant toe amputation or debridement	The use of skin and dermal substitutes within 30 days of the study start
Not suitable for the application of primary surgery suture	The use of any enzymatic and biologic debridement treatments
No obvious necrotic tissue in the postoperative wound	With severe cardiac, hepatic, and renal insufficiency or other systemic diseases
Clinical classification of infection (IWGDF/IDSA classification) grade 1–3	Pregnant or lactating females
	With psychiatric disorders and who exhibited poor self-management
	Patients who could not consistently avoid weight-bearing on the affected foot

card (bioMérieux, France) were used for bacterial isolation and identification; mixed infection with multiple bacteria was identified separately. Multidrug resistance organisms (MDRO) are bacteria that are resistant to three or more classes of commonly used sensitive antimicrobial drugs.¹⁷

Basic Treatment

Basic treatment, including anti-hyperglycemia, vasodilation, anti-infection, nerve nutrition, pressure-lowering, lipid regulation, and foot bracing, was given to patients depending on their condition. Based on the redness, swelling, heat, pain, wound discharge, and systemic conditions around the wound (peri-wound), combined with a secretion and drug sensitivity test culture, a comprehensive judgment of the infection situation was considered to develop the anti-infection treatment plan. Debridement was carried out for all the patients, and incision and drainage were applied to abscesses. Toe amputation was performed depending on the condition of the affected foot, and any bone with osteomyelitis was removed. The study was initiated on the first day after debridement, open drainage for abscess, toe amputation, and osteomyelitis osteotomy.

NPWT Treatment

The negative-pressure closed drainage devices were purchased from Shandong WEGO Co. (the foam material was polyurethane [PU]) and Wuhan VSD Co. (the foam material was polyvinyl alcohol [PVA]). This study used a vacuum-assisted closure NPWT system (provided by Shandong WEGO Company (PU) and Wuhan VSD Medical Science Technology Company (PVA)). Before beginning the NPWT, any necrotic tissue was completely removed from the wound surface. If any bone was exposed, the surface bone cortex was removed, and NPWT could only be initiated after blood flow was visible in the bone. The dressing was trimmed appropriately (according to the size of the wound), and deeper wounds were filled with dressing at the bottom of the cavity. The negative pressure for the PU material was set at -80 to -150 mmHg, and the negative pressure for the PVA material was set at -300 to -400 mmHg, with a therapeutic course lasting 4–5 days.

NSSD Application

The adhesive NSSD (L7) was purchased from Henan Huibo Medical Co., China. The average horizontal tension provided by the medical tape needed to be ≥ 1 N per 1 cm of width. The indications for using the adhesive NSSD were as

follows: only wounds that had controlled infection; granulation tissue covered the exposed bone; the wounds exhibited fresh granulation tissue; the width of the wound was < 2.5 cm; and there was no dead space in the wound after application of the device. During the application of the NSSD, the peri-wound skin was kept clean and dry to ensure that the adhesive surface of the device adhered firmly to the skin. The device was numbered according to the size of the wound and was selected accordingly. Then, the tape portion of both ends of the device was placed precisely on both sides of the wound, gentle pressure was applied on the tape to tightly bond it to the skin, and the locking strips were pulled on both sides to close or narrow the wound. If the wound edge was too tightly closed, the upper part of the lock was lifted and the degree of closure adjusted. The dressing was used to cover the outside of the wound to prevent contamination following the closure of the wound, so the wound was kept under observation, and the dressing was changed once every one to two days. The wound was kept clean, and the device was removed once the wound had healed, as shown in [Figures 1 and 2](#).

Wound Progression

The two groups of patients were given negative pressure sealing drainage treatment immediately after inclusion of the study. When fresh granulation tissue covered the exposed bone stump and there was no redness, swelling, heat, or pain around the wound, and there was no purulent secretion in the wound, the adhesive NSSD was applied in the treatment group, while the control group was given a standard dressing change as shown in [Figure 2](#).

The standard dressing change comprised the following: sterile gauze soaked with 0.1% ethacridine was locally applied as a wet dressing, covered with oil gauze, and bandaged with at least four layers of sterile gauze dressing. The dressing was changed every one to two days.

Wound Surface Measurement

The patient's wound was photographed using a digital camera prior to the first dressing and from then onwards every week until either the wound had healed or the three-month post-surgery observation took place. When photographing the wound, a medical width sticker was attached to the wound surface to determine its actual length. In this study, the wound depth was measured when changing the dressing, and the trauma surface area was calculated using the ImageJ 1.48v software package.

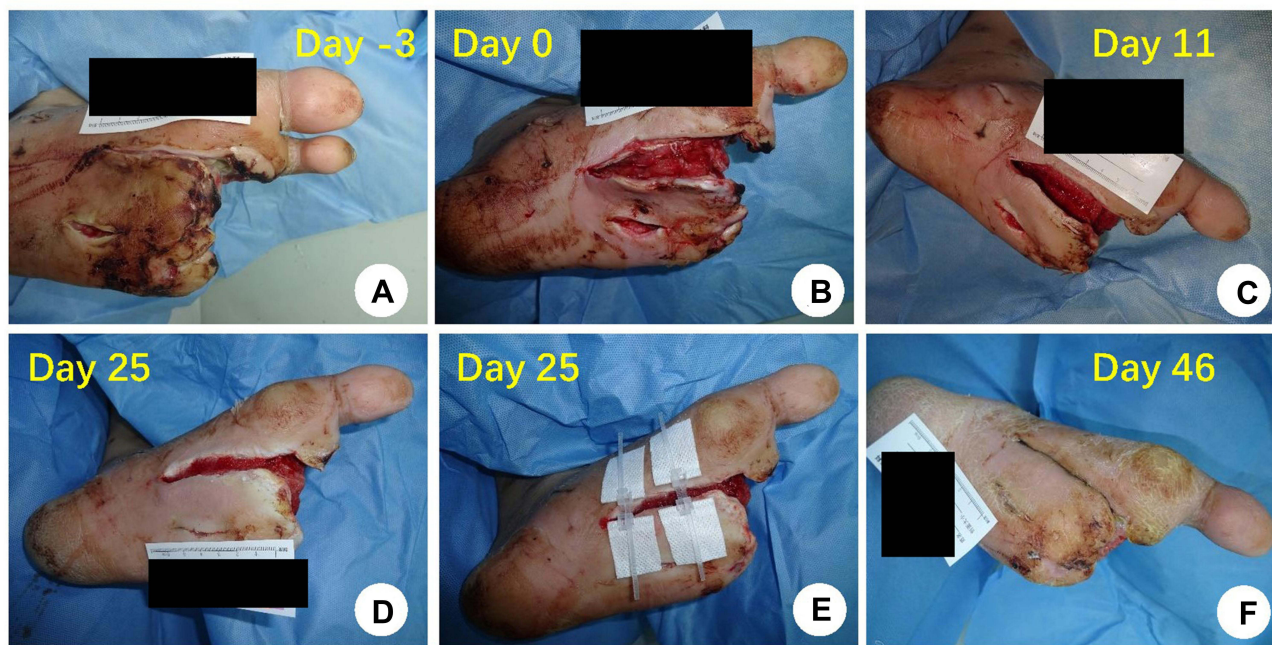

Figure 1 The comparison of one patient in the treatment group before and after treatment. (A) At admission; (B) before enrollment, no obvious necrotic tissue on the wound after debridement; (C) after the second cycle of negative-pressure wound therapy (NPWT); (D) after the fourth cycle of NPWT; (E) the application of the adhesive non-invasive skin stretching device; (F) wound healing.

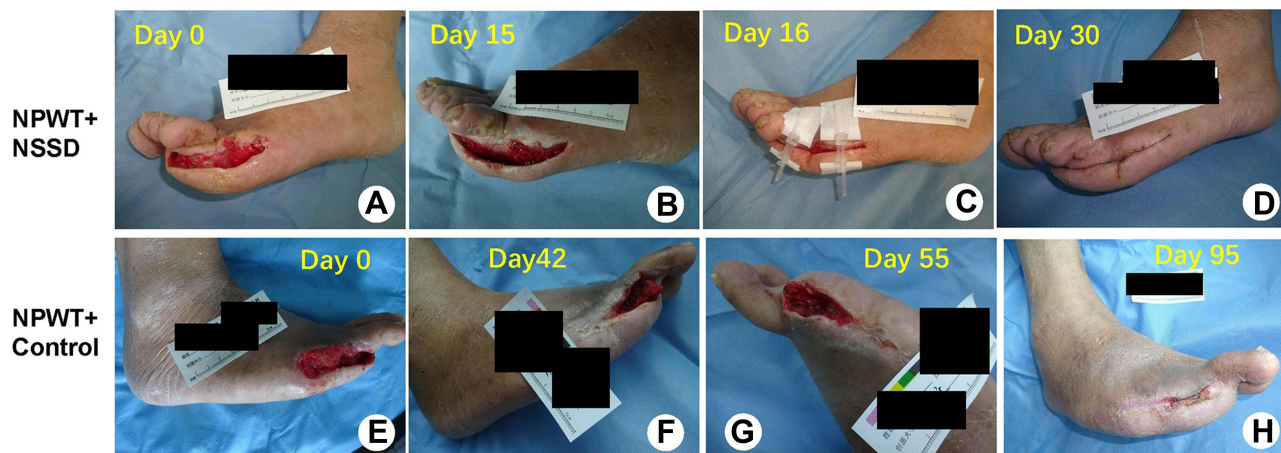


Figure 2 (A–D) A comparison of one patient in the negative-pressure wound therapy (NPWT) + non-invasive skin stretching device (NSSD) group before and after treatment. (A) Before enrollment, no obvious necrotic tissue on the wound after debridement; (B) after NPWT; (C) application of the adhesive NSSD; (D) wound healing. (E–H) A comparison of one patient in the NPWT + Control group before and after treatment; (E) before enrollment, no obvious necrotic tissue on the wound after debridement; (F) during the NPWT; (G) after the NPWT; (H) wound healing.

Endpoint

The primary efficacy endpoint was the incidence of complete wound closure. This endpoint was reached when the wound had healed at the end of three months, and the secondary endpoints were the postoperative wound healing rate, wound healing time and whether the wound had healed after six weeks of treatment (taking the end of the previous negative-pressure closed drainage as the time starting point).

Complete ulcer closure was defined as skin closure (100% reepithelization) without drainage or dressing requirements.

Statistical Analysis

The SPSS Statistics 19.0 software package was used to conduct the data analysis. Categorical data were expressed as counts (percentages) and Pearson's chi square test and Fisher's exact test were used to compare

the results of the two groups. The measurement data were tested for normality using the Kolmogorov–Smirnov test. If the data obeyed normal distribution, the data were expressed as means and standard deviations. The independent sample *t*-test was used for comparison between the groups. If the data were non-normally distributed, the data were expressed as a median (upper and lower quartiles). The non-parametric Mann–Whitney *U*-test was used for comparison between the groups. The wound healing rates over time in both groups were analyzed using Kaplan–Meier survival analysis; $p < 0.05$ was considered statistically significant.

Results

Table 2 shows the relevant clinical data concerning a total of 84 patients from the two groups, who all attended our hospital between May 2017 and November 2020. The results show that both groups have similar characteristics except for the use of vasodilators, which is higher in the control group.

In the present study, the patients in the control group were selected according to the matching condition of a similar wound area ($\pm 20\%$). The results also showed no statistical difference in the wound area between the two patient groups. Although wound depth was not matched in the present study,

Table 2 Comparison Between Treatment Groups of Patient and Wound Demographics, Comorbidities, and Medications [$\bar{x} \pm s$ or Median (The Upper and Lower Quartiles) or Case (Composition Ratio)]

Characteristics	Treatment Group	Control Group	P
Age (years)	55.8±11.7	58.7±11.2	0.255
Male (%)	31 (73.8)	33 (78.6)	0.608
Diabetes duration (years)	13.6±8.7	13.7±8.1	0.969
Diabetic foot duration (months)	2.0 (1.0,2.0)	2.0 (1.0,3.0)	0.633
Smoking history (%)	16 (38.1)	18 (42.9)	0.657
Hypertension (%)	24 (57.1)	30 (71.4)	0.172
Coronary heart disease (%)	9 (21.4)	11 (26.2)	0.608
Dyslipidemia (%)	11 (26.2)	14 (33.3)	0.474
DN (%)	25 (59.5)	25 (59.5)	–
DPN (%)	42 (100)	42 (100)	–
MDRO infection (%)	12 (28.6)	14 (33.3)	0.637
BMI (kg/m ²)	25.6±3.8	24.9±5.2	0.481
FPG (mmol/L)	8.7±4.4	8.1±2.7	0.427
TG (mmol/L)	1.9±1.5	1.39±0.9	0.064
TC (mmol/L)	4.1±1.2	3.8±1.1	0.262
LDL-C (mmol/L)	2.4±0.9	2.1±0.9	0.153
HDL-C (mmol/L)	1.0±0.2	1.0±0.3	0.824
HbA _{1c} (%)	9.1±2.1	8.7±2.0	0.367
Hb (g/L)	111.1±21.7	112.1±25.1	0.850
Alb (g/L)	38.5±4.7	40.7±14.6	0.342
CRP (mg/L)	7.8±6.4	6.4±5.6	0.280
ABI	1.05±0.20	0.97±0.22	0.109
Wound area before treatment (cm ²)	6.75 (3.0,11.0)	6.0 (2.5,12.0)	0.982
Wound depth before treatment (cm)	1.0 (0.6,1.3)	1.0 (0.5,1.2)	0.181
Insulin (%)	41 (97.6)	39 (92.9)	0.608
Oral hypoglycemic drugs (%)	34 (81.0)	34 (81.0)	–
Vasodilators (%)	27 (64.3)	36 (85.7)	0.023
Antibiotics (%)	33 (78.6)	38 (90.5)	0.228
Antihypertensive drugs (%)	29 (69.0)	36 (85.7)	0.068
Statins (%)	31 (73.8)	29 (69.0)	0.629
Anti-platelet drugs (%)	31 (73.8)	37 (88.1)	0.095

Abbreviations: DN, diabetic nephropathy; DPN, diabetic peripheral neuropathy; MDRO infection, multi-drug resistant organism infection; BMI, body mass index; FPG, fasting blood glucose; TG, triglycerides; TC, total cholesterol; LDL-C, low-density lipoprotein cholesterol; HDL-C, high-density lipoprotein cholesterol; HbA_{1c}, glycated hemoglobin; Hb, hemoglobin; Alb, serum albumin; CRP, C-reactive protein; ABI, ankle-brachial index.

the results revealed no statistical difference in this regard between the two patient groups.

A Comparison of the Therapeutic Effects

The three-month wound healing rate was higher in the treatment group than in the control group (38 of 42 [90.5%] vs 25 of 42 [59.5%], $p = 0.002$), and there was no statistical difference between the two groups linked to the treatment time of NPWT (36.6 ± 22.3 vs 33.0 ± 18.3 d, $t = 0.807$, $p = 0.422$). At the end of three months, the Kaplan–Meier median estimate for wound healing time was shorter in the treatment group (44 days [95% CI 40.0–48.0]) than in the control group (76 days [95% CI 63.0–89.0], $p = 0.000$). The cumulative wound healing rate was significantly higher in the treatment group than in the control group over time ($p = 0.000$), as shown in Figure 3.

Selecting the end of the final negative-pressure closed drainage as the time-starting point, by the end of six weeks, the Kaplan–Meier median estimates for wound closure were

11 days (95% CI 9.0–13.0) for the treatment group and 42 days (95% CI 23.0–ND) for the control group ($p = 0.000$). The cumulative wound healing rate was significantly higher in the treatment group than in the control group over time ($p = 0.000$), as shown in Figure 4.

The Incidence of Adverse Reaction and Recurrence

In the treatment group, there was one case of skin allergy following the application of the adhesive NSSD, which manifested as pruritus at the adhesive area without obvious skin redness or spontaneous blistering. However, after removal of the device for three days, no further allergy occurred after reapplication. No skin margin necrosis or tears, and no skin allergy, blisters, or other adverse reactions were observed among the remaining patients in the group. Two patients in the treatment group had recurrence after one month of wound healing. One of these was due to

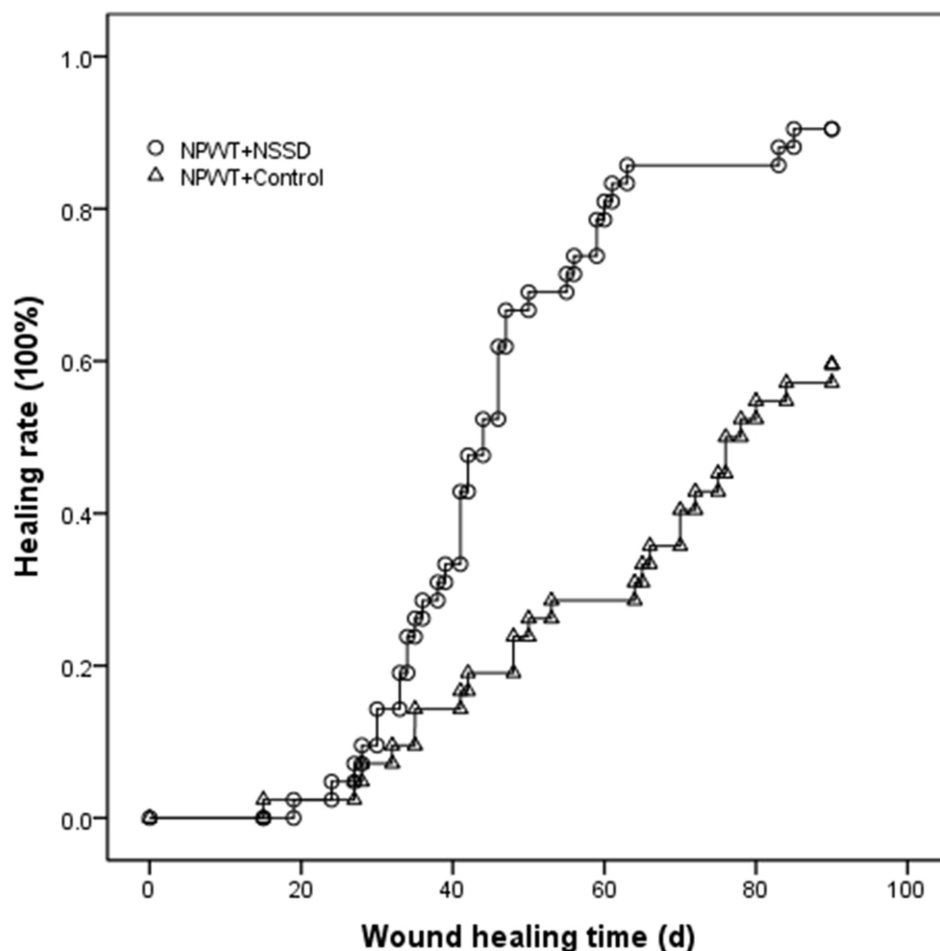


Figure 3 A comparison of the Kaplan–Meier healing curve between the two groups; $P < 0.01$.

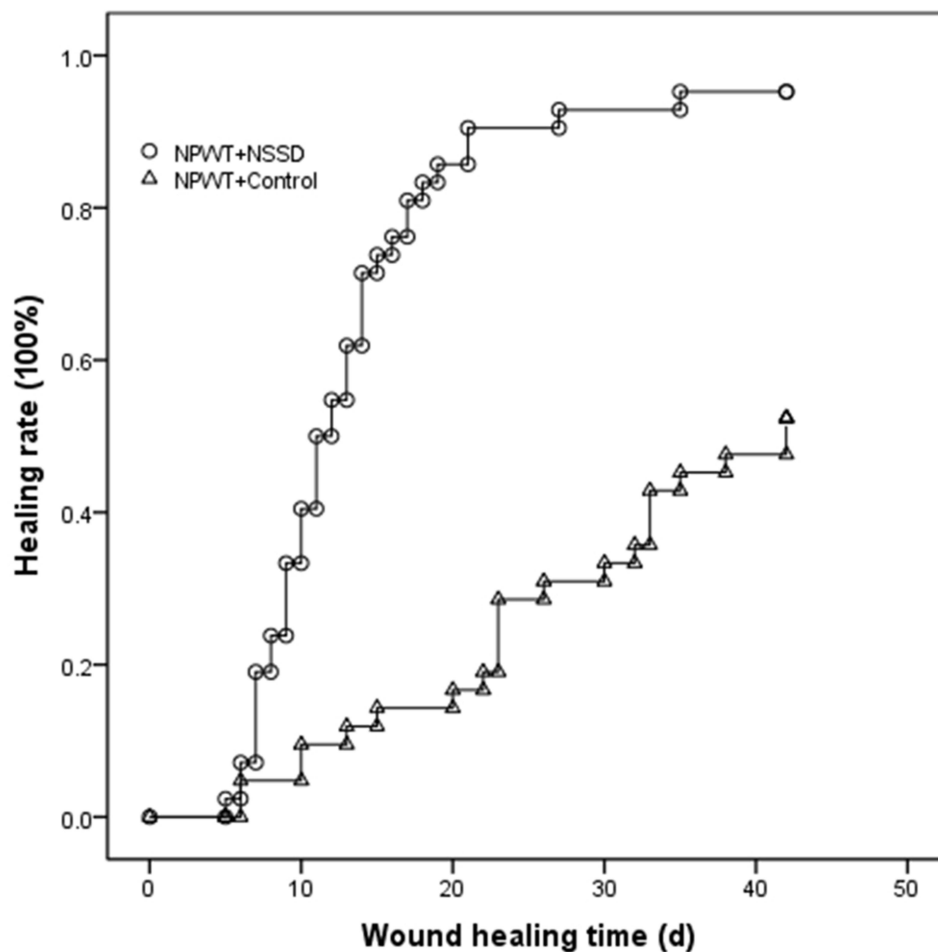


Figure 4 The time-healing Kaplan–Meier curves for both groups with the end of the final negative-pressure closed drainage as the time starting point; $P < 0.01$.

the presence of pseudo-healing with deep dead space in the wound, while the second case correlated with improper postoperative foot care. Two patients in the control group had a recurrence after one month of wound healing, both cases of which were correlated with improper postoperative foot care.

Discussion

The use of NPWT primarily promotes granulation tissue growth, and so it can be used for post-operative wound repair in cases of DF.⁹ However, NPWT is not suitable in the later stage of wound repair, including the epithelial tissue growth phase. Due to the special tissue structure of the foot, its subcutaneous tissue is not suitable for suturing in some DF. At the same time, the proportion of diabetic patients with combined peripheral arterial disease in the foot is as high as 47.5%,¹⁸ due to the poor blood supply of the extremity. Moreover, an uncontrolled postoperative infection may also occur. The reasons discussed above may cause a reduced

wound healing rate after first-stage suturing in DF surgery.¹⁹ Skin-stretching devices mainly include adhesive NSSDs and invasive SSDs, which are primarily used for treating skin defects that are not suitable for one-stage suturing and for avoiding skin grafting or flap grafting.^{11,12} Therefore, it is worth exploring and investigating whether NPWT combined with SSD therapy could be used in the postoperative period for the treatment of a DF. The results of the present study show that NPWT combined with a NSSD can shorten the post-operative wound healing time and increase the wound healing rate at three months after surgery compared with NPWT in combination with conventional dressing changes.

To clarify whether NPWT combined with NSSD could shorten the wound healing time and improve the wound-healing rate after DF surgery, NPWT + NSSD group and NPWT + conventional dressing change group were compared in the present study. The wound healing rate was found to be higher and the wound healing time shorter in the treatment group. Although the proportion of patients

with the administration of vasodilators was significantly higher in the control group compared with the treatment group, and vasodilators were beneficial for the improvement of wound blood supply and wound healing, the treatment group still had a higher wound healing rate and shorter wound healing time, and there were no specific adverse effects in the treatment group compared with the control group. These results indicate that NPWT combined with an adhesive NSSD is effective and safe to use in the repair phase of *DF* gangrene wounds and can shorten the wound healing time and improve the healing rate.

Skin-stretching devices are mainly developed based on the natural stress relaxation principles of skin¹¹ and the principle of mechanical creep.²⁰ This technique promotes microstructural changes in the skin, dermis, and subcutaneous tissue by continuously stretching the normal skin tissue around the wound, resulting in faster expansion of the skin and subcutaneous tissue, and facilitating the closure of basal granulation and epithelial tissue. Meanwhile, the technique also reduces the chance of wound infection by allowing early closure of the wound, which is beneficial for wound healing. It has been shown that invasive SSD can shorten wound healing time in *DF* wounds.^{13,21} However, invasive SSD can lead to injury, necrosis, and tears of the skin edge due to excessive local tissue tension,^{14,21} particularly when applied to ischemic wounds such as a *DF*, leading to an increased risk of the above conditions occurring. A NSSD can avoid these risks because it will not cause further tissue injury and has adjustable tension. The two main types of NSSDs are ZipLine and TopClosure. The former is not suitable for wounds with excessive tension,¹⁵ while the latter has the characteristics of bi-directional tensioning and reversible adjustment.²² TopClosure has been successfully used in the treatment of other skin defects of the extremities and trunk.^{23,24} The SSD applied in the present study was an adhesive NSSD type that had bi-directional retraction and reversible adjustment characteristics. Thus, it could be adjusted over time according to the granulation and epithelial tissue growth and the blood supply to the skin edge during its application to the *DF* wounds. This study also showed that, compared with a conventional dressing change, the use of a NSSD can significantly shorten the wound healing time and improve the wound healing rate of the wound surface of diabetic foot after NPWT treatment when the granulation tissue covers the deep tissue. These results suggest that an adhesive NSSD may facilitate wound healing for cases of *DF*.

Before applying the adhesive NSSD for *DF* wound repair, the trauma area must be adequately cleaned, necrotic

tissue must be removed, and the trauma infection must be effectively controlled. Failing to meet the above requirements and premature application of the NSSD can cause further aggravation of the infection and an increase in necrotic tissue. In the present study, for *DF* wounds with co-infection and many tissue defects, antibiotics combined with negative-pressure drainage were used initially. Once the wound infection was controlled and the deep tissue was covered by granulation tissue, an adhesive NSSD was used to close the wound. Using this method, the three-month wound healing rate increased in the treatment group.

Complications that may occur when using an adhesive NSSD for wound closure include skin allergies, blister formation, skin necrosis, skin wound dehiscence following stretch closure, and scar hypersensitivity after wound healing.²² After wound healing, the formation of dead space may cause a recurrence of infection. In the present study, only one case in the treatment group experienced a skin allergy at the patch site, which suggests that the use of NSSDs has few adverse reactions. Another case of recurrence after healing may have been due to dead space in the deep wound following wound closure. As such, NSSDs should only be used for the repair of *DF* gangrene wounds when the following conditions are met: any infection is controlled; granulation tissue covers exposed bone; there is fresh granulation tissue; the width of the wound is <2.5 cm; and there is no dead space in the wound after the application of the device. During the application of SSDs, it is necessary to closely observe the blood supply of the skin edge of the wound to prevent skin edge ischemia and necrosis. The application of the device should be avoided or discontinued in the event of the following contraindications: (1) the presence of necrotic tissue in the wound; (2) the presence of redness, swelling, or heat around the wound; (3) the presence of a purulent discharge from the wound; (4) the skin margin being ischemic after closing the wound; (5) the width of the wound being ≥ 2.5 cm; or (6) the device failing to adhere firmly to the skin due to the local structure of the foot.

The NPWT technique involves the application of a wound dressing through which continuous or intermittent negative pressure is applied, allowing tissue fluid or wound secretion to drain away from the wound and collect in a canister. The NPWT technique results in two types of tissue deformation, namely, macro-deformation, such as wound contraction, and micro-deformation, which occurs at the microscopic level. Both stimulate a wound healing cascade that includes tissue granulation promotion, vessel proliferation, neo-angiogenesis, epithelialization, and excess

extracellular fluid removal. At the molecular level, NPWT results in an alteration towards more pro-angiogenic and anti-inflammatory conditions. It increases the expression of several key growth factors including vascular endothelial growth factor and fibroblast growth factor 2, while the expression of inflammatory cytokines is reduced. The application of NPWT also alters the presence and function of matrix metalloproteinases.⁸ This type of therapy can facilitate the control of *DF* wound infection through the drainage of wound secretions and the secretion of anti-inflammatory factors.²⁵ Clinical studies of diabetic foot ulcer (DFU) patients showed the superiority of NPWT over standard therapy in terms of efficacy outcomes, primarily wound healing, and amputation rate, without a rise in adverse events.^{26,27} International guidelines indicate NPWT to be an important adjuvant therapy in post-operative DFU, the use of which is expected to increase.⁹ In the present study, postoperative treatment with NPWT was first conducted to ensure the healthy development of granulation tissue on the wound's surface, as well as coverage of exposed bone, tendon, and fascial tissue, together with controlling wound infection. Following these steps establishes a good foundation for the subsequent application of either a NSSD or conventional dressing to the wound.

Some *DF* wounds develop infections that cannot be effectively controlled, for example, exposed bone stumps, a lack of subcutaneous tissue that prohibits sutures, and dead cavity formation following suturing. These cases of *DF* are not suitable for one-stage suturing. Under these *DF* conditions, we would recommend the use of NPWT combined with a NSSD for wound repair and the promotion of wound closure post-surgery.

This study has some limitations that are mainly linked to the two types of materials used in the NPWT. This is a retrospective study, and, during the period that the research covers, the material used in the NPWT was updated and changed from PVA to PU. However, there was no statistical difference between the two groups with respect to the proportion of patients with which either of the two NPWT materials was used. As such, the choice of NPWT material did not affect the results. Moreover, patients in the control group were selected according to the postoperative wound area $\pm 20\%$, but the wound depth limited by the number of cases could not be matched according to $\pm 20\%$, nor could other variables be matched. However, we limited the depth of the wound to 0.5–2.5cm, which minimized the bias.

Conclusion

In summary, the adhesive NSSD used in the present study demonstrated obvious advantages in the repair of *DF* wounds, i.e., no secondary trauma, no destruction of the peri-wound skin, simple operation, and low therapeutic cost. With continuous retraction of the skin at the wound's edge, the wound area can continuously be reduced and the wound healing time shortened, factors which are undoubtedly welcomed by patients. The present study confirmed that the combination of an adhesive NSSD and NPWT can effectively improve the healing rate and shorten the wound healing time of postoperative *DF* wounds, and, therefore, its use has good prospects.

Ethics Statement

This study was conducted with approval from the Ethics Committee of Air Force Medical Center, PLA.

This study was conducted in accordance with the declaration of Helsinki.

Written informed consent was obtained from all participants.

Funding

Beijing Municipal Science and Technology Project: 2018 Clinical characteristics and Application Research of Capital. (Z181100001718025). PLA Youth Training Project for Medical Science (15QNP040).

Disclosure

The authors report no conflicts of interest in this work.

References

1. Singh N, Armstrong DG, Lipsky BA. Preventing foot ulcers in patients with diabetes. *JAMA*. 2005;293(2):217–228. doi:10.1001/jama.293.2.217
2. Van Netten JJ, Price PE, Lavery LA, et al.; International Working Group on the Diabetic Foot. Prevention of foot ulcers in the at-risk patient with diabetes: a systematic review. *Diabetes Metab Res Rev*. 2016;32(Suppl 1):84–98. doi:10.1002/dmrr.2701
3. Evans KK, Attinger CE, Al-Attar A, et al. The importance of limb preservation in the diabetic population. *J Diabetic Complications*. 2011;25(4):227–231. doi:10.1016/j.jdiacomp.2011.02.001
4. Raghav A, Khan ZA, Labala RK, Ahmad J, Noor S, Mishra BK. Financial burden of diabetic foot ulcers to world: a progressive topic to discuss always. *Ther Adv Endocrinol Metab*. 2018;9(1):29–31. doi:10.1177/2042018817744513
5. Driver VR, Fabbi M, Lavery LA, Gibbons G. The costs of diabetic foot: the economic case for the limb salvage team. *J Vasc Surg*. 2010;52(3 Suppl):17S–22S. Erratum in: *J Vasc Surg*. 2010 Dec;52(6):1751. doi:10.1016/j.jvs.2010.06.003
6. Gershater MA, Löndahl M, Nyberg P, et al. Complexity of factors related to outcome of neuropathic and neuroischaemic/ischaemic diabetic foot ulcers: a cohort study. *Diabetologia*. 2009;52(3):398–407. doi:10.1007/s00125-008-1226-2

7. Wu B, Wan X, Ma J. Cost-effectiveness of prevention and management of diabetic foot ulcer and amputation in a health resource-limited setting. *J Diabetes*. 2018;10(4):320–327. doi:10.1111/1753-0407.12612
8. Borys S, Hohendorff J, Frankfurter C, Kiec-Wilk B, Malecki MT. Negative pressure wound therapy use in diabetic foot syndrome—from mechanisms of action to clinical practice. *Eur J Clin Invest*. 2019;49(4):e13067. doi:10.1111/eci.13067
9. Rayman G, Vas P, Dhataria K, et al.; International Working Group on the Diabetic Foot (IWGDF). Guidelines on use of interventions to enhance healing of chronic foot ulcers in diabetes (IWGDF 2019 update). *Diabetes Metab Res Rev*. 2020;36(Suppl 1):e3283. doi:10.1002/dmrr.3283
10. Chinese Medical Association, Diabetes Division, Infectious Diseases Branch of Chinese Medical Association, Chinese Medical Association Tissue Repair and Regeneration Branch. Chinese guideline on prevention and management of diabetic foot (2019 edition) (II). *Chin J Diabetes*. 2019;11(3):161–189. Chinese.
11. Topaz M, Carmel NN, Topaz G, Li M, Li YZ. Stress-relaxation and tension relief system for immediate primary closure of large and huge soft tissue defects: an old-new concept: new concept for direct closure of large defects. *Medicine (Baltimore)*. 2014;93(28):e234. doi:10.1097/MD.0000000000000234
12. Song M, Zhang Z, Liu T, et al. EASApprox[®] skin-stretching system: a secure and effective method to achieve wound closure. *Exp Ther Med*. 2017;14(1):531–538. doi:10.3892/etm.2017.4539
13. Gao L, Wang S, Wang L, Wang J. [Application of skin stretching device in repair of diabetic foot wound]. *Zhongguo Xiu Fu Chong Jian Wai Ke Za Zhi*. 2018;32(5):591–595. Chinese.
14. Marek DJ, Copeland GE, Zlowodzki M, Cole PA. The application of dermatotraction for primary skin closure. *Am J Surg*. 2005;190(1):123–126. doi:10.1016/j.amjsurg.2005.05.038
15. Gorsulowsky DC, Talmor G. A novel noninvasive wound closure device as the final layer in skin closure. *Dermatol Surg*. 2015;41(8):987–989. doi:10.1097/DSS.0000000000000399
16. Lipsky BA, Berendt AR, Cornia PB, et al.; Infectious Diseases Society of America. 2012 Infectious Diseases Society of America clinical practice guideline for the diagnosis and treatment of diabetic foot infections. *Clin Infect Dis*. 2012;54(12):e132–73.
17. Magiorakos AP, Srinivasan A, Carey RB, et al. Multidrug-resistant, extensively drug-resistant and pandrug-resistant bacteria: an international expert proposal for interim standard definitions for acquired resistance. *Clin Microbiol Infect*. 2012;18(3):268–281. doi:10.1111/j.1469-0691.2011.03570.x
18. Prompers L, Schaper N, Apelqvist J, et al. Prediction of outcome in individuals with diabetic foot ulcers: focus on the differences between individuals with and without peripheral arterial disease. The EURODIALE Study. *Diabetologia*. 2008;51(5):747–755. doi:10.1007/s00125-008-0940-0
19. Ahmed ME, Mohammed MS, Mahadi SI. Primary wound closure of diabetic foot ulcers by debridement and stitching. *J Wound Care*. 2016;25(11):650–654. doi:10.12968/jowc.2016.25.11.650
20. Hirshowitz B, Kaufman T, Ullman J. Reconstruction of the tip of the nose and ala by load cycling of the nasal skin and harnessing of extra skin. *Plast Reconstr Surg*. 1986;77(2):316–321. doi:10.1097/00006534-198602000-00029
21. Armstrong DG, Lavery LA. 1998 William J. Stickel Silver Award. Mechanically assisted, delayed primary closure of diabetic foot wounds. *J Am Podiat Med Assoc*. 1998;88(10):483–488. doi:10.7547/87507315-88-10-483
22. Topaz M, Carmel NN, Silberman A, Li MS, Li YZ. The TopClosure[®] 3S system, for skin stretching and a secure wound closure. *Eur J Plast Surg*. 2012;35(7):533–543. doi:10.1007/s00238-011-0671-1
23. Dan X, Hongfei J, Huahui Z, Chunmao H, Hang H. A skin-stretching wound closure system to prevent and manage dehiscence of high-tension flap donor sites: a Report of 2 Cases. *Ostomy Wound Manage*. 2015;61(8):35–40.
24. Dong Q, Gu G, Wang L, et al. [Application of modified adjustable skin stretching and secure wound-closure system in repairing of skin and soft tissue defect]. *Zhongguo Xiu Fu Chong Jian Wai Ke Za Zhi*. 2017;31(12):1481–1484. Chinese.
25. Cigna E, Fino P, Onesti MG, Amorosi V, Scuderi N. Diabetic foot infection treatment and care. *Int Wound J*. 2016;13(2):238–242. doi:10.1111/iwj.12277
26. Zhang J, Hu ZC, Chen D, Guo D, Zhu JY, Tang B. Effectiveness and safety of negative-pressure wound therapy for diabetic foot ulcers: a meta-analysis. *Plast Reconstr Surg*. 2014;134(1):141–151. doi:10.1097/PRS.0000000000000275
27. Liu S, He CZ, Cai YT, et al. Evaluation of negative-pressure wound therapy for patients with diabetic foot ulcers: systematic review and meta-analysis. *Ther Clin Risk Manag*. 2017;13:533–544. doi:10.2147/TCRM.S131193

Diabetes, Metabolic Syndrome and Obesity: Targets and Therapy

Dovepress

Publish your work in this journal

Diabetes, Metabolic Syndrome and Obesity: Targets and Therapy is an international, peer-reviewed open-access journal committed to the rapid publication of the latest laboratory and clinical findings in the fields of diabetes, metabolic syndrome and obesity research. Original research, review, case reports, hypothesis formation, expert opinion

and commentaries are all considered for publication. The manuscript management system is completely online and includes a very quick and fair peer-review system, which is all easy to use. Visit <http://www.dovepress.com/testimonials.php> to read real quotes from published authors.

Submit your manuscript here: <https://www.dovepress.com/diabetes-metabolic-syndrome-and-obesity-targets-and-therapy-journal>