

**New
Method**

Communication Site Ligation and Polyglycolic Acid Sheet Use for the Treatment of Hydrothorax in Patients Undergoing Continuous Ambulatory Peritoneal Dialysis

Hirotohi Kubokura, MD, PhD,¹ Junichi Okamoto, MD, PhD,¹
and Jitsuo Usuda, MD, PhD²

Introduction: Hydrothorax due to pleuroperitoneal communication (PPC) can occur in patients undergoing continuous ambulatory peritoneal dialysis (CAPD). We report our experiences of the safety and efficacy of the treatment of four patients with a novel video-assisted thoracoscopy method.

Methods: Single-port video-assisted thoracoscopic surgery (VATS) was performed with a mini-thoracotomy of 5 cm in length. The PPC site was identified on the diaphragm and ligated using an endoscopic loop. The diaphragm was then covered using a polyglycolic acid (PGA) sheet, over which adhesive chemicals (OK432 and tetracycline) were sprayed.

Results: We assessed the efficacy of our approach in four patients (one female and three males) aged 42–74 years (mean: 62.0 years). The hydrothoraxes were right sided in all the patients. The mean operation and postoperative drainage times were 92.5 min and 3.0 days, respectively. The hydrothoraxes did not recur in any patient during follow-up periods of 8–46 months.

Conclusion: Our suture- and staple-free technique is not only easy to perform but also appears to be safe and effective for the management of hydrothorax in patients receiving CAPD. Larger scale studies are now indicated.

Keywords: video-assisted thoracic surgery, hydrothorax, continuous ambulatory peritoneal dialysis, polyglycolic acid sheet

¹Department of Thoracic Surgery, Nippon Medical School Musashikosugi Hospital, Kawasaki, Kanagawa, Japan

²Department of Thoracic Surgery, Nippon Medical School Main Hospital, Tokyo, Japan

Received: March 13, 2018; Accepted: April 23, 2018

Corresponding author: Hirotohi Kubokura, MD, PhD. Department of Thoracic Surgery, Nippon Medical School Musashikosugi Hospital, 1-396 Kosugi-cho, Nakahara-ku, Kawasaki, Kanagawa 211-8533, Japan

Email: kubokura@nms.ac.jp

©2018 The Editorial Committee of *Annals of Thoracic and Cardiovascular Surgery*. This work is licensed under a Creative Commons Attribution-NonCommercial-NonDerivatives International License.

Introduction

Continuous ambulatory peritoneal dialysis (CAPD) is an effective treatment for patients with end-stage chronic kidney disease (CKD). However, hydrothorax due to pleuroperitoneal communication (PPC) through diaphragmatic defects or blebs is a well-recognized complication (**Fig. 1**), occurring in approximately 2% of these patients in Japan.¹⁾ Several nonsurgical treatments have been used to treat this complication, including autologous blood patches and chemical pleurodesis through a thoracic tube, but these fail in approximately 50% of

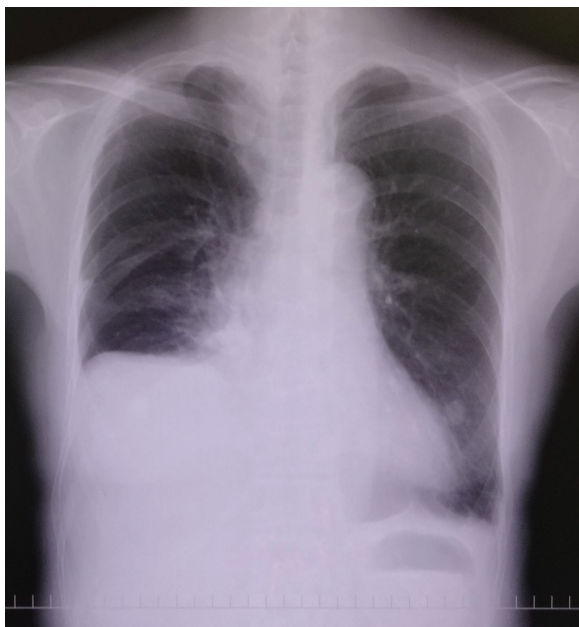


Fig. 1 Chest X-ray showing a right-sided hydrothorax due to PPC (Case 4). PPC: pleuroperitoneal communication

cases.²⁾ In these patients, CAPD should be converted to hemodialysis. However, there are some reports that surgical procedures have much higher success rates than nonsurgical treatments. Currently, available surgical approaches include direct suturing or stapling of the PPC sites, as well as mechanical pleurodesis under video-assisted thoracoscopic surgery (VATS) using a polyglycolic acid (PGA) sheet.

Methods

Study design

We assessed the safety and efficacy of a new method for treating PPC in patients with hydrothoraxes due to CAPD. In this approach, we used VATS and a PGA sheet with adhesive agents to achieve defect closure. This was a descriptive, exploratory study based on a small case series. No statistical analyses were performed.

Surgical procedure

VATS was performed under general anesthesia with double-lumen endobronchial intubation. One port site was used for the camera in the anterior axillary line of the fifth to seventh intercostal spaces, and a mini-thoracotomy was performed with an incision measuring less than 5 cm on the dorsal side of the sixth to eighth intercostal spaces.

Monitoring the diaphragm, we injected 1500–2000 mL of dialysis solution containing 10 mL of indigo carmine

into the abdominal cavity via the CAPD catheter. PPC sites on the diaphragm were visualized as inflated blebs stained blue, and were grasped using forceps before being ligated with an ENDOLOOP Ligature (Ethicon, Inc., Somerville, NJ, USA). Following ligation, the diaphragm was covered with a 15 × 15 cm PGA sheet (Vicryl Mesh, Ethicon, Inc.). Adhesive chemical agents (e.g., OK432 [picibanil] and tetracycline) were sprayed over the PGA sheet. Finally, a thoracic 19 French gage Spiral Drain (Redax, UK) was inserted between the base of the lower lung and the diaphragm and drained continuously at a suction level of -10 cm H₂O.

During admission, simple peritoneal dialysis (PD) was performed instead of CAPD, using a blood access catheter. The drain was removed when respiratory fluctuation ceased in the suction bag, and CAPD was typically resumed 2–4 weeks after surgery.

Ethical considerations

The use of OK432 for benign diseases is not permitted in Japan (for Japanese Insured Medical Treatment). Therefore, we ensured that informed consent was obtained from all patients before using OK432.

Results

We treated four patients (one female and three males) aged 42–74 years (mean: 62.0 years) (**Table 1**). All the treated hydrothoraxes occurred on the right side. Three patients were diagnosed with PPC based on the chemical component of the pleural effusion, but one patient was diagnosed based on clinical and radiological findings. The mean operation time was 92.5 min using the VATS procedure (range, 66–149 min), and the mean postoperative drainage time was 3.0 days (range, 2–5 days). None of the hydrothoraxes recurred during the observation period (range, 8–46 months). The procedures are illustrated in **Fig. 2**, using Case 1 as an example. Each case is described in detail in the following text.

Case 1

The first case was that of a 61-year-old female with CKD due to nephrosclerosis, who had a peritoneal catheter implanted at our hospital. Two months after starting CAPD, a chest X-ray revealed a massive right-sided pleural effusion. Thoracentesis indicated that the chemical component of the pleural fluid was very similar to that of the PD fluid; she was therefore diagnosed with PPC due to CAPD and referred for surgery.

Table 1 Patients' characteristics and outcome

	Case 1	Case 2	Case 3	Case 4	Mean
Age y/o/Sex	61 F	42 M	71 M	74 M	62.0
Side	Right	Right	Right	Right	
Diagnosed by	Thoracocentesis	Thoracocentesis	Thoracocentesis	Clinical findings + Images	
PPC sites	Blebs	A leakage site	A bleb & a leakage	A bleb & a leakage	
Adhesive agents					
Tetracycline/OK432	200 mg/10 KE	200 mg/2 KE	200 mg/2 KE	200 mg/2 KE	
Operation time (min)	149	66	76	79	92.5
Drain removed at POD	5	3	2	2	3.0
CAPD resumed at POD	28	26	14	12	20.0
Observation periods	46 M	22 M	23 M	8 M	24.8
Recurrence	-	-	-	-	
Others	P/O high fever	Renal transplantation		Converted to HD	

POD: postoperative day; M: months; P/O: postoperative; HD: hemodialysis; CAPD: continuous ambulatory peritoneal dialysis; PPC: pleuroperitoneal communication

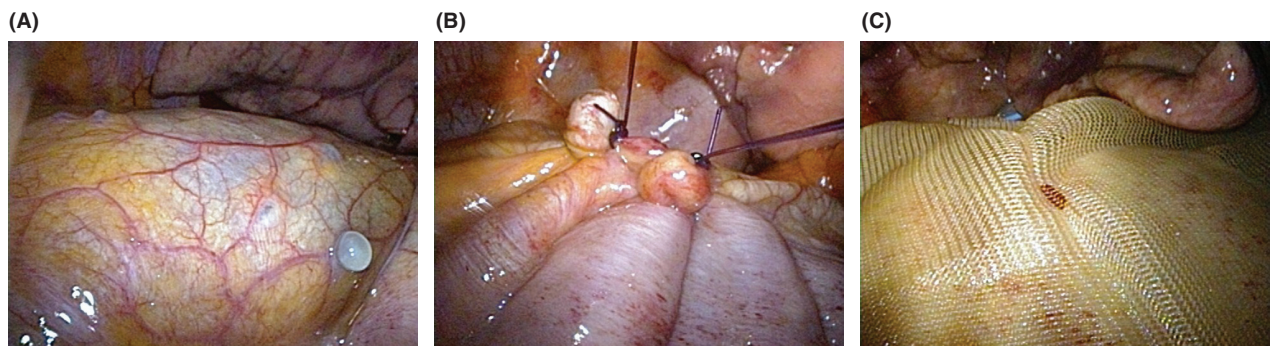


Fig. 2 Intraoperative findings in Case 1. The site of PPC on the diaphragm was visualized as inflated blebs with blue staining (A), at which point it was grasped using forceps and ligated (B). After ligation, the diaphragm was covered with a 15 × 15 cm PGA sheet (C), and adhesive chemical agents, such as OK432 and tetracycline, were sprayed over the polyglycolic acid sheet. PPC: pleuroperitoneal communication; PGA: polyglycolic acid

During surgery, we detected a couple of distended blebs at the central tendon of the diaphragm that leaked blue staining solution (**Fig. 2A**). The blebs were ligated using two ENDOLOOP ligatures (**Fig. 2B**). The diaphragm was then covered with a PGA sheet and sprayed with 20 mL of saline containing 200 mg of tetracycline and 10 clinical units (KE) of OK432 (**Fig. 2C**). The operation time was 149 min, the chest drain was removed on postoperative day 5, and CAPD was resumed on day 28. However, during the immediate postoperative period, she suffered from a high fever (39°C–40°C) and significant pleural effusion (100–200 mL/day). No recurrence was noted during a 46-month follow-up period.

Case 2

The second case was that of a 42-year-old male diagnosed with CKD of unknown etiology, who had a peritoneal catheter implanted at another hospital. Six months after starting CAPD, a chest X-ray revealed a massive right-sided pleural effusion. Thoracocentesis confirmed

PPC due to CAPD and he was transferred to our hospital for surgery.

During surgery, we identified a perforation at the central tendon of the diaphragm by leakage of the blue staining solution. The site was ligated using an ENDOLOOP ligature, the diaphragm was covered with a PGA sheet, and 20 mL of saline containing 200 mg of tetracycline and 2 KE of OK432 were sprayed. The lower dose of OK432 was used as the high fever and pleural effusion in Case 1 could have been caused by the OK432. The operation time was 66 min. The chest drain was removed on postoperative day 3 and CAPD was resumed on postoperative day 27. No recurrence was noted for 22 months, after which he underwent renal transplantation.

Case 3

The third case was that of a 71-year-old male with CKD due to nephrosclerosis, who had a peritoneal catheter implanted at another hospital. Two months after starting CAPD, a chest X-ray revealed a massive right-sided

pleural effusion, and he was diagnosed with PPC due to CAPD based on thoracentesis. Initial treatment with a blood patch failed twice, and he was therefore transferred to our hospital for surgery.

During surgery, we identified one bleb and one leakage site at the central tendon of the diaphragm, which we were able to ligate using two ENDOLOOPS each. The diaphragm was covered with a PGA sheet and sprayed with 10 mL of saline containing 200 mg of tetracycline and 2 KE of OK432. The operation time was 76 min, the chest drain was removed on postoperative day 2, and CAPD was resumed on postoperative day 14. No recurrence was noted for 22 months.

Case 4

The fourth case was that of a 74-year-old male with CKD due to nephrosclerosis, who had a peritoneal catheter that had been implanted at another hospital. Three months after starting CAPD, a chest X-ray revealed a massive right-sided pleural effusion, and he was diagnosed with PPC due to CAPD based on clinical, X-ray, and computed tomography findings (**Fig. 2**). Initial treatment using a blood patch failed once, and he therefore was transferred to our hospital for surgery.

During surgery, we identified one bleb and one leakage site at the central tendon of the diaphragm, which we ligated using two ENDOLOOPS each. The diaphragm was covered with a PGA sheet and sprayed with 10 mL of saline containing 200 mg of tetracycline and 2 KE of OK432. The operation time was 79 min, the chest drain was removed on postoperative day 2, and CAPD was resumed on postoperative day 12. No recurrence was noted for 8 months. He later converted to hemodialysis, but the rationale for this was not known to us.

Discussion

The repair or closure of PPC sites by suturing during VATS requires high surgical skill; however, stapling the diaphragm can risk anastomotic dehiscence. Moreover, ligation using an endoscopic loop offers a potentially easier and highly effective method of closure. Saito et al.³⁾ suggested that using talc powder to stimulate adhesion could be more effective than suturing or stapling, particularly in cases in which leakage had not been confirmed. In our four cases, only one or two endoscopic loops were used to close apparent PPC sites. However, it is possible that covering the repair sites with a PGA sheet and spraying adhesives complemented the repairs by adding extra protection against hydrothorax

and by promoting adhesion between the base of the lower lung lobe and the diaphragm.

The recommended dose of OK432 for pleurodesis in malignant pleural effusion is 5–10 KE in 50–100 mL of saline based on medical guidance in Japan. Although OK432 is not approved for the treatment of benign diseases in Japan, we obtained informed consent for its use from all the patients. In the first case, 10 KE of OK432 in 20 mL of saline was used; however, the patients developed postoperative fever (39°C–40°C) and pleural effusion (100–200 mL/day), which we thought could have been caused by this high dose. Therefore, we reduced the dose of OK432 from 10 KE to 2 KE in subsequent cases. This still achieved satisfactory adhesion, without inducing postoperative fever. Moreover, the thoracic drain could be removed within a shorter period because of the reduced discharge. We will be applying for our consent to our Institutional Review Board to perform procedures based on this regimen in future studies.

CAPD was resumed about 4 weeks after surgery in Cases 1 and 2, but within 2 weeks in Cases 3 and 4. Kumagai et al.⁴⁾ have suggested that the CAPD should normally be stopped for more than 2 weeks when pleurodesis is performed without a surgical procedure. By contrast, and as supported by our data, it may be possible to resume CAPD within the first week after VATS.

We conclude that our new suture- and staple-free method is not only easy to perform, but is also safe and effective for the management of hydrothorax in patients receiving CAPD. Larger scale studies are now indicated.

Disclosure Statement

No conflicts of interest are declared.

References

- 1) Nomoto Y, Suga T, Nakajima K, et al. Acute hydrothorax in continuous ambulatory peritoneal dialysis—a collaborative study of 161 centers. *Am J Nephrol* 1989; **9**: 363-7.
- 2) Shishido T, Ryuzaki M, Takimoto C, et al. A case of recurrent hydrothorax complicating continuous ambulatory peritoneal dialysis after video-assisted thoracoscopic surgery. *J Jpn Soc Dia Ther* 2010; **43**: 873-9. (in Japanese)
- 3) Saito M, Nakagawa T, Tokunaga Y, et al. Thoracoscopic surgical treatment for pleuroperitoneal communication. *Interact Cardiovasc Thorac Surg* 2012; **15**: 788-9.
- 4) Kumagai H, Watari M, Kuratsune M. Simple surgical treatment for pleuroperitoneal communication without interruption of continuous ambulatory peritoneal dialysis. *Gen Thorac Cardiovasc Surg* 2007; **55**: 508-11.