

V-shaped Internal Nasal Vestibular Flap for Reconstruction of Iatrogenic Columellar Defect

Sara Tanini, MD
Giulia Lo Russo, MD

Summary: Columella is an important structure in the center of the face, and its structural integrity has an important functional, social, and psychological role. Columella reconstruction can be very challenging for surgeons and the ideal technique remains elusive. This article describes a reconstruction technique in a young woman with columella necrosis due to nasal continuous positive airway pressure treatment. The method of reconstruction described here, with a V-shaped internal nasal vestibular flap and a cartilage grafts from lateral crura, is simple and easily reproducible, providing an optimal aesthetic result and in addition the donor site does not create a secondary deformity by disrupting normal anatomy. (*Plast Reconstr Surg Glob Open* 2018;6:e1604; doi: 10.1097/GOX.0000000000001604; Published online 12 January 2018.)

The nose is a complex structure that with its prominent and centered position in the face has an important functional and structural role. At the same time, partial defects of 1 of its components can lead to important psychological issues. The columella is the cover of the inferior portion of the cartilaginous nasal septum. It is the connecting structure between the nasal tip and the superior lip, that helps delimiting the face profile and provides an important esthetic line necessary for analyzing the naso labial angle. Although the columella is 1 of the smallest subunits of the nose, defects of this structure have important esthetic and structural implications.¹⁻³

Different can be the causes of nasal injury, but columella defects are often related to an ischemic injury caused by the placement of a nasogastric tube or nasal continuous positive airway pressure (nCPAP) required by premature babies at the time of birth.^{4,5} The main goal of reconstruction surgery is to restore the trilaminar composition of the columella.³ This is obtained by recreating a skin coverage and providing a cartilaginous structure to support a patent airway and restore integrity and harmony to the nasal pyramid. Despite the multiple techniques described in the literature for the restoring of other nasal structures, for an isolated defect of the columella an ideal technique

remains elusive.^{1,3} This article describes a reconstruction technique in a young woman with columella necrosis due to nCPAP treatment.

CASE

Our case regards the loss of the distal half of the columella due to a secondary ischemic damage related to the placement of a temporary nCPAP while hospitalized in neonatal intensive care. The patient came to our attention at the age of 14 years and had not been subjected to any previous attempt of reconstruction.

The physical examination revealed a partial absence of the nasal columella, from the nasal tip down to the base of columella, involving the medial crura of the alar cartilages and a boxy tip. The nose and the septum were otherwise well developed (Fig. 1). The target of reconstruction was to restore the trilaminar structure in the portion where it was missing. With an open approach, a cephalic trim of the lateral crura was performed, and 2 autogenous cartilage grafts were harvested (Fig. 2A). This lateral crural grafts were then placed and sutured on the caudal septum and fixed between them. To correct the boxy nasal tip, we also placed horizontal mattress transdomal sutures (Fig. 2C). To obtain a coverage, a V-shaped internal nasal vestibular flap was designed in the nasal floor (Fig. 2B). The flap was a random-pattern one consisting of 2 medial wings and a residual columella as a base (Fig. 3). The wings were raised and rotated cranially toward the midline to reconstruct the anterior surface of the newly formed columella. The flaps were sutured together with interrupted sutures (Fig. 2D-F). The patient's postoperative course was uneventful, with total flap survival. After

From the Department of Surgery and Translational Medicine, Plastic and Reconstructive Microsurgery, Careggi University Hospital, Florence, Italy.

Received for publication July 20, 2017; accepted October 18, 2017.

Copyright © 2018 The Authors. Published by Wolters Kluwer Health, Inc. on behalf of The American Society of Plastic Surgeons. This is an open-access article distributed under the terms of the Creative Commons Attribution-Non Commercial-No Derivatives License 4.0 (CCBY-NC-ND), where it is permissible to download and share the work provided it is properly cited. The work cannot be changed in any way or used commercially without permission from the journal.

DOI: 10.1097/GOX.0000000000001604

Disclosure: The authors have no financial interest to declare in relation to the content of this article. The Article Processing Charge was paid for by the authors.

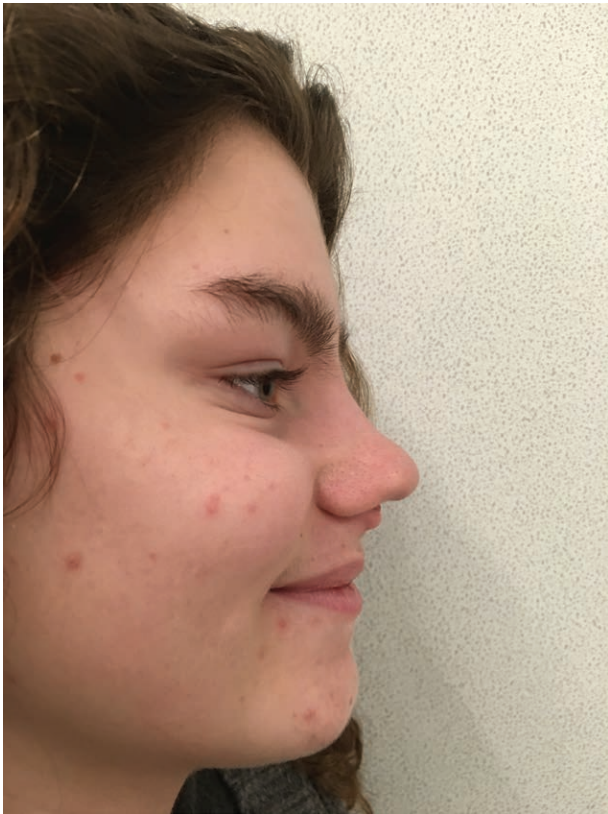

Fig. 1. Preoperative lateral view with a total absence of distal half of the nasal columella and a boxy tip.

3 months, it has been necessary to remodel the residual columella. This stage has been postponed to permit the autonomization of the 2 flaps and to act after the reduction of edema.

The final result was a columella of an excellent contour and no additional scar. This surgical procedure has led to an immediate reconstruction of the trilaminar structure of the columella, to an aesthetic improvement of the nose-tip, and especially it has left no secondary deformities in the areas of the graft's withdrawal due to their intranasal position (Fig. 4).

DISCUSSION

The nasal columella is an important functional and aesthetic unit in the mid face. Severe deformity can result from its defects or absence and create an important structural and aesthetic discomfort.^{1-3,6} The ideal technique should meet the aesthetic and functional needs of the patient without leaving additional healing results and distort the normal anatomy, should create a support structure for the nasal tip and external nasal valves, but also an aesthetically pleasing structure, with adequate projection to restore the nasolabial angle.³ Different techniques can be used for columella reconstruction, from direct primary closure and skin grafts to free flaps.^{1,3,7,8}

In our case, we opted for a reconstructive technique that allowed us not only to rebuild the missing columella portion but also to improve the aesthetics of the entire

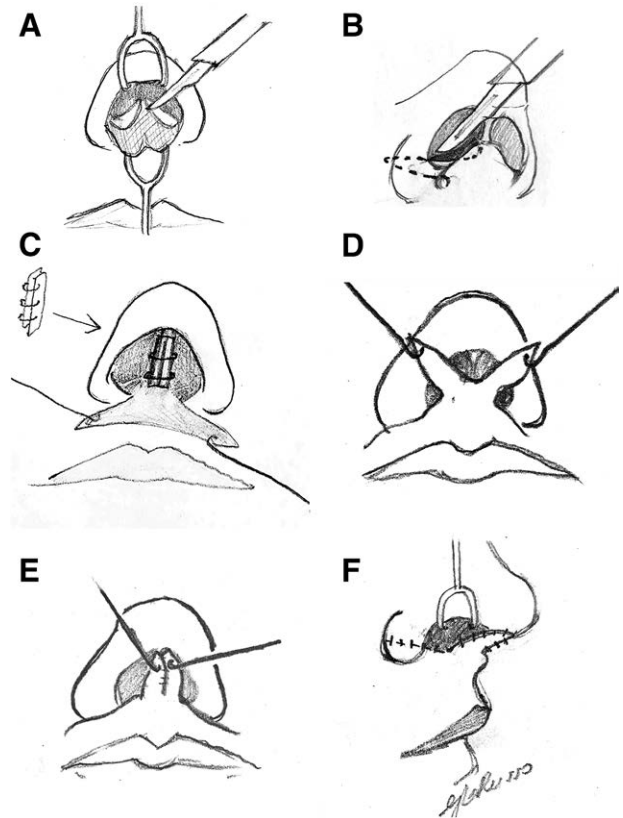


Fig. 2. Schematic drawing of technique. A, Harvesting of the cephalic portion of the lateral crura with open technique. B, Design of a V-shaped internal nasal vestibular flap in the nasal floor. C, Cartilage grafts fixed between them and sutured to the caudal septum. D, The 2 wings of the V-shaped internal nasal vestibular flap raised. E, Rotation of the wings cranially and sutured in the midline. F, Lateral view of the reconstructed columella.

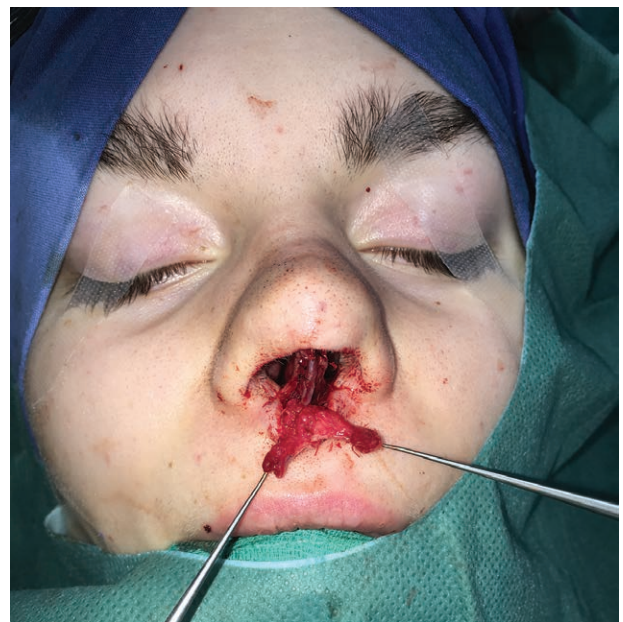

Fig. 3. Intraoperative view of V-shaped internal nasal vestibular flap. The flap was a random-pattern consisting of 2 medial wings and a residual columella as a base.



Fig. 4. Lateral postoperative view 1 year after surgery.

nose. Given the morphological characteristics of this patient's nose (boxy tip), we harvested a fragment of cartilage from the lateral crura and used it as a cartilage graft to give a solid support to the new columella, improving the shape of the nasal tip, and avoiding a further surgical site as it happens when harvesting an auricular composite graft.

To obtain a coverage, a V-shaped internal nasal vestibular flap was designed in the nasal floor. In our case, we used a flap in which the base was represented by the residual columella. A multitude of local flaps and their modifications have been described, designated most commonly by their donor site^{3,7,8}. Acceptable results have been ob-

tained with all these techniques, each with its advantages and drawbacks. The use of this kind of flap permits a good coverage and color match, eliminating the external additional facial scar, which can be disfiguring particularly in a young person.^{7,8} The ideal technique for reconstruction of the isolated columella defect remains elusive because of the unique anatomic features of the structure and the paucity of local donor sites that do not deform or scar native anatomy.³ We believe that treatment should be individualized, taking into consideration the patient's age, sex, previous operations, and whether or not a facial scar would be well tolerated by the subject.⁸ The key points of this reconstruction are the new integrity of the nasal pyramid, the improved aesthetics of the nose-tip, and no additional scars.

Giulia Lo Russo, MD

Department of Surgery and Translational Medicine
Plastic and Reconstructive Microsurgery
Careggi University Hospital
Florence, Italy
E-mail: giulialorusso70@gmail.com

REFERENCES

1. Bottini DJ, Galante V, Gentile P, et al. Description of columellar defects and its tridimensional remedial techniques. *Eur Rev Med Pharmacol Sci*. 2009;13:193–196.
2. Bouguila J, Zairi I, Yacoub K, et al. [Columella defects: yet a challenge!]. *Ann Chir Plast Esthet*. 2008;53:504–512.
3. Pan BS, Vu AT, Rapp SJ, et al. Reconstruction of the isolated columellar defect: a novel 2-stage technique and review of the literature. *J Oral Maxillofac Surg*. 2017;75:822–827.
4. Jayaratne YS, Zwahlen RA, Htun SY, et al. Columella pressure necrosis: a method of surgical reconstruction and its long-term outcome. *BMJ Case Rep*. 2014. doi: 10.1136/bcr-2013-203132.
5. Li Y, Sepulveda A, Buchanan EP. Late presenting nasal deformities after nasal continuous positive airway pressure injury: 33-year experience. *J Plast Reconstr Aesthet Surg*. 2015;68:339–343.
6. Agrawal KS, Shrotriya R, Pabari M. An innovative technique for columellar reconstruction using 'Flip-Over' buccal mucosa flap. *J Clin Diagn Res*. 2016;10:PD05–PD06.
7. Vecchione TR. Columella reconstruction using internal nasal vestibular flaps. *Br J Plast Surg*. 1980;33:399–403.
8. Mavili ME, Akyürek M. Congenital isolated absence of the nasal columella: reconstruction with an internal nasal vestibular skin flap and bilateral labial mucosa flaps. *Plast Reconstr Surg*. 2000;106:393–399.