

Eosinophilic Infiltration in Korea: Idiopathic?

Jae Hoon Lim, MD, Kyung Soo Lee, MD

Department of Radiology and Center for Imaging Science, Sungkyunkwan University School of Medicine, Seoul 135-710, Korea

Eosinophilia is defined as the presence of more than 500 eosinophils/ μ L in the peripheral blood, and may be accompanied by eosinophil infiltration in tissues. Focal eosinophilic infiltration in the lungs and liver is relatively common and is often associated with a parasitic infection, drug hypersensitivity, allergic diseases, collagen vascular diseases, and internal malignancies such as Hodgkin's disease, as well as cancer of the lung, stomach, pancreas or ovary. An eosinophilic abscess refers to a lesion of massive eosinophil infiltration and associated destroyed tissue, and an eosinophilic granuloma refers to a lesion consisting of central necrosis and mixed inflammatory cell infiltrates with numerous eosinophils, a number of neutrophils and lymphocytes, and a palisade of epithelioid histiocytes and/or giant cells.

The imaging findings of eosinophilic infiltration in the lungs and liver have mainly been reported by Korean investigators (1–9). There have only been a few case reports (10–13) from Western countries. It is unclear why this is the case and why eosinophilic disease appears to be prevalent only in Korea. Moreover, it is unclear if there are any particular parasitic, allergic, or malignant diseases prevalent in Korea only.

Korean authors have addressed the possible causes of eosinophilic infiltration such as idiopathic hypereosinophilia (1, 2, 4, 6) and malignant tumors through the tumor-associated eosinophilotactic factor (3, 5, 7–9), whereas some authors have offered no explanation (3, 9). Idiopathic hypereosinophilia is a grave disease that is characterized by persistent eosinophilia of 1,500 eosinophils/ μ L for more than six months, and death before six months due to congestive heart failure (14). However, the course of these patients in our clinical practice is invariably benign. Eosinophilic infiltration of the liver is often associated with cancer of the stomach, liver, etc, but only few of those patients have malignancies (3, 7, 9). Extensive investigations have been to determine if a parasitic infection is the cause of eosinophilic infiltration (9) including *Taenia solium* (cysticercosis), *Paragonimus wester-*

mani, *Clonorchis sinensis*, *Sparganum mansoni*, *Anisakis simplex*, *Fasciola hepatica*, *Schistosoma*, and *Toxoplasma gondi*. However none of their patients gave positive results.

The terminologies are variable and confusing, and include "focal eosinophilic infiltration", "focal eosinophilic necrosis", "focal eosinophilic abscess", "eosinophilic granuloma", and "foci of eosinophil-related necrosis", etc. However, these terms do not refer to a disease entity but to the histopathologic findings of some diseases with an unknown etiology. Moreover, it is unclear if the phenomenon is idiopathic or a syndrome caused by various etiologies.

Chang et al., in a study of eosinophilic infiltrative disease of the liver and lung, reported that a *Toxocara canis* larval infection is the cause of the hepatic or pulmonary eosinophilic infiltration in dog ascaris (15). Of 103 patients with peripheral eosinophilia, 70 were diagnosed with a *Toxocara canis* infection based on an enzyme linked immunoabsorbent assay (ELISA). Of these 70 patients, 54 (77%) showed evidence of a hepatic abnormality on sonography or CT, and 42 (60%, 42/70) had a history of ingesting uncooked cow liver, which is known to be a reservoir of the encapsulated larva of *Toxocara canis*. The CT and sonographic findings were the same as previous reported by Korean investigators (1–8), appearing as multiple, small, oval or round, ill-defined nodules on the sonography, CT and MR images (Fig. 1).

A human infection of *Toxocara canis* occurs in two ways, by ingesting eggs in soil or by eating uncooked animal liver containing encapsulated larvae. Dog hair and soil contains infective stage eggs, and an infection occurs when eggs containing fully developed larva are swallowed. After hatching in the human intestine, the larva penetrate the intestinal wall, flow through the portal vein, and reach the liver, lungs, orbit and brain. Some larvae move slowly in the liver (visceral larva migrans) or become encapsulated and remain in that state with no further growth for an indefinite period (16). Children who come in contact

Eosinophilic Infiltration in Korea

with infected dogs are prone to be infected in this way (17).

Alternatively, adults can be infected by eating uncooked animal liver, mainly cow liver, containing encapsulated larvae (15, 18). After swallowing the uncooked liver, the encapsulated larvae are released in the human intestine. The larvae penetrate the intestinal wall and reach the liver through the portal vein. From there, they migrate to the lungs, and other parts of the body. Toxocariasis is usually asymptomatic and self-limiting in a light infection and does not require treatment. In severe infections due to the heavy worm burden, anthelmintic treatment is effective. The administration of steroid hormone may be deleterious to patients.

Some ethnic populations have a custom of eating raw

animal tissue. Many Koreans and Japanese eat raw seafood, and some prefer to eat raw freshwater fish, which is the route of a *Clonorchis sinensis* infection. Others have a habit of eating raw cow, pig, goat, chicken or goose liver, which is based on the belief that it is a "health-promoting food." Slices of cow liver served as a gratis are a popular dish in meat restaurants. Uncooked cow (15, 18), pig (19), lamb (20), and chicken (21) liver are a source of human *Toxocara canis* infections. The association between toxocariasis and malignant tumors in some patients may be explained by the propensity of those patients to eat "health-promoting food." Some people believe that animal liver is a good supply of nutrients for those with malignant diseases, and families or neighbors persuade these patients eat these foods.

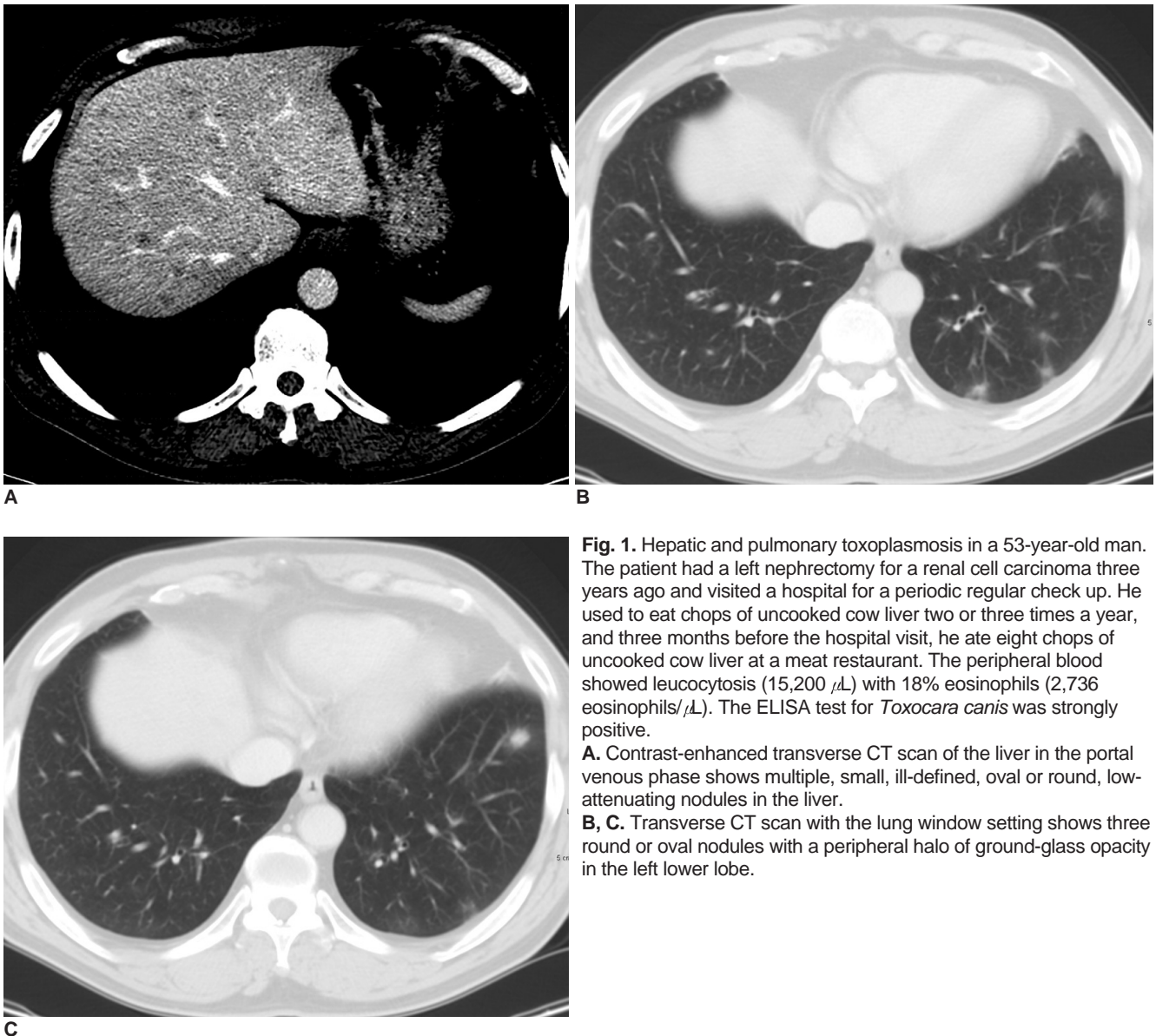


Fig. 1. Hepatic and pulmonary toxoplasmosis in a 53-year-old man. The patient had a left nephrectomy for a renal cell carcinoma three years ago and visited a hospital for a periodic regular check up. He used to eat chops of uncooked cow liver two or three times a year, and three months before the hospital visit, he ate eight chops of uncooked cow liver at a meat restaurant. The peripheral blood showed leucocytosis (15,200 μL) with 18% eosinophils (2,736 eosinophils/ μL). The ELISA test for *Toxocara canis* was strongly positive.
A. Contrast-enhanced transverse CT scan of the liver in the portal venous phase shows multiple, small, ill-defined, oval or round, low-attenuating nodules in the liver.
B, C. Transverse CT scan with the lung window setting shows three round or oval nodules with a peripheral halo of ground-glass opacity in the left lower lobe.

In summary, many patients suffering from peripheral eosinophilia with eosinophilic infiltration in the lungs and liver have toxocariasis caused by the ingestion of uncooked liver, mainly cow liver. A diagnosis of toxocariasis is made by a serologic test for the *Toxocara* excretory/secretory antigen (ELISA test) because the histological proof of *Toxocara* larva in tissue is extremely difficult. However, an ELISA kit for this disease is not widely available. The clinical triad of toxocariasis is unexplained eosinophilia, liver or lung nodules on the imaging studies, and a history of eating animal liver. Based on the clinical diagnosis, physicians may try a conservative approach, thereby reducing the necessity of expensive diagnostic tests such as MR (9) or PET imaging (22), which are used for differentiation from a metastatic tumor, thus obviating unnecessary diagnostic procedures such as biopsy or surgery (23), and aggressive treatment.

References

- Kim GB, Kwon JH, Kang DS. Hypereosinophilic syndrome: imaging findings in patients with hepatic involvement. *AJR Am J Roentgenol* 1993;161:577-580
- Cha SH, Park CM, Cha IH, Kim HJ, Lee DH, Baek SY, et al. Hepatic involvement in hypereosinophilic syndrome: value of portal venous phase imaging. *Abdom Imaging* 1998;23:154-157
- Lee WJ, Lim HK, Lim JH, Kim SH, Choi SH, Lee SJ. Foci of eosinophil-related necrosis in the liver: imaging findings and correlation with eosinophilia. *AJR Am J Roentgenol* 1999;172:1255-1261
- Nam KJ, Jung WJ, Choi J-C, Koo BS, Park BH, Lee KN, et al. Hepatic involvement in hypereosinophilia: sonographic findings. *J Ultrasound Med* 1999;18:475-479
- Won JH, Kim MJ, Kim BM, Ji H, Chung JJ, Yoo HS, et al. Focal eosinophilic infiltration of the liver: a mimick of hepatic metastasis. *Abdom Imaging* 1999;24:369-372
- Lim JH, Lee WJ, Lee DH, Nam KJ. Hypereosinophilic syndrome: CT findings in patients with hepatic lobar or segmental involvement. *Korean J Radiol* 2000;1:98-103
- Jang HJ, Lee WJ, Lee SJ, Kim SH, Lim HK, Lim JH. Focal eosinophilic necrosis of the liver in patients with underlying gastric or colorectal cancer: CT differentiation from metastasis. *Korean J Radiol* 2002;3:240-244
- Yoo SY, Han JK, Kim YH, Kim TK, Choi BI, Han MC. Focal eosinophilic infiltration in the liver: radiologic findings and clinical course. *Abdom Imaging* 2003;28:326-332
- Kim Y-K, Kim JS, Moon WS, Cho B-H, Lee SY, Lee JM. MRI findings of focal eosinophilic liver disease. *AJR Am J Roentgenol* 2005;184:1541-1548
- Jain R, Sawhney S, Bharava DK, Panda SK, Berry M. Hepatic granulomas due to visceral larva migrans in adults: appearance on US and MRI. *Abdom Imaging* 1994;19:253-256
- Rayes A, Teixeira D, Nobre V, Serufo JC, Goncalves R, Valadares L, et al. Visceral larva migrans syndrome complicated by liver abscess. *Scand J Infect Dis* 1999;31:324-325
- Kaplan KJ, Goodman ZD, Ishak KG. Eosinophilic granuloma of the liver: a characteristic lesion with relationship to visceral larva migrans. *Am J Surg Pathol* 2001;25:1316-1321
- Hartleb M, Januszewski K. Severe hepatic involvement in visceral larva migrans. *Eur J Gastroenterol Hepatol* 2001;13:1245-1249
- Chusid MJ, Dale DC, West BC, Wolff SM. The hypereosinophilic syndrome: analysis of fourteen cases with review of the literature. *Medicine* 1975;54:1-27
- Chang S, Lim JH, Choi D, Park CK, Kwon N-H, Cho S-Y, et al. Hepatic visceral larva migrans of *Toxocara canis*: CT and sonographic findings. *AJR Am J Roentgenol* 2006 (in press)
- Beaver PC, Jung RC, Cupp EW. *Clinical parasitology*, 9th ed. Lea & Febiger, Philadelphia, PA, 1984
- Schantz PM, Glickman LT. Toxocara visceral larva migrans. *N Engl J Med* 1978;23:436-439
- Aragane K, Akao N, Matsuyama T, Sugita M, Natsuaki M, Kitada O. Fever, cough, and nodules on ankles. *Lancet* 1999;354:1872
- Fan CK, Lan HS, Hung CC, Chung WC, Weilliao C, Du W-Y, et al. Seroepidemiology of *Toxocara canis* infection among mountain aboriginal adults in Taiwan. *Am J Trop Med Hyg* 2004;71:216-221
- Salem G, Schantz P. Toxocara visceral larva migrans after ingestion of raw lamb liver. *Clin Infect Dis* 1992;15:743-744
- Nakagura K, Tachibana H, Kaneda Y, Kato Y. Toxocariasis possibly caused by ingesting raw chicken. *J Infect Dis* 1989;160:735-736
- Kim TJ, Lee KW, Kim HY, Lee JH, Kim EA, Kim SK, et al. Simple pulmonary eosinophilia evaluated by means of FDG PET: the findings of 14 cases. *Korean J Radiol* 2005;6:208-213
- Byun JH, Yang DH, Yoon SE, Won HJ, Shin YM, Jeong YY, Jang SJ. Contrast-enhancing hepatic eosinophilic abscess during the hepatic arterial phase: a mimic of hepatocellular carcinoma. *AJR Am J Roentgenol* 2006;186:168-173